International Journal of General Medicine

Dovepress
open access to scientific and medical research

Open Access Full Text Article

ORIGINAL RESEARCH

Alteration Trend and Overlap Analysis of Positive Features in Different-Sized Benign and Malignant Thyroid Nodules: Based on Chinese Thyroid Imaging Reporting and Data System

Chen Qu[1,*], Hong-jian Li[2,*], Qi Gao[3], Jun-chao Zhang[1], Wei-min Li[1]

[1]Department of Ultrasonography, Affiliated Hospital of Jiangnan University, Wuxi, Jiangsu, People's Republic of China; [2]Department of Ultrasonography, Huai'an Cancer Hospital, Huai'an, Jiangsu, People's Republic of China; [3]Department of Ultrasonography, Zhongda Hospital Southeast University, Nanjing, Jiangsu, People's Republic of China

*These authors contributed equally to this work

Correspondence: Wei-min Li, Department of Ultrasonography, Affiliated Hospital of Jiangnan University, Wuxi, Jiangsu, 214000, People's Republic of China, Tel +8613912362309, Email 1005342597@qq.com

International Journal of General Medicine downloaded from https://www.dovepress.com/
For personal use only.

Purpose: This study aimed to investigate the alteration trends and overlaps of positive features in benign and malignant thyroid nodules of different sizes based on the Chinese Thyroid Imaging Reporting and Data System (C-TIRADS).

Patients and Methods: 1337 patients with 1558 thyroid nodules were retrospectively recruited from November 2021 to December 2023. These nodules were divided into three groups according to maximum diameter: A (≤10 mm), B (10–20 mm), and C (≥20 mm). C-TIRADS positive features were compared between benign and malignant thyroid nodules of different sizes. In addition, the trends of positive features with changes in nodule size among malignant thyroid nodules were analyzed.

Results: The incidence of positive features in malignant thyroid nodules was higher than that in benign. As benign nodules grow, the incidence of all positive features showed a linear decreasing trend (Z values were 72.103, 101.081, 17.344, 33.909, and 129.304, P values < 0.001). With the size of malignant thyroid nodules increased, vertical orientation, solid, marked hypoechogenicity, and ill-defined/irregular margins/extrathyroidal extension showed a linear decreasing trend (Z = 148.854, 135.378, 8.590, and 69.239, respectively; P values < 0.05), while suspicious microcalcifications showed a linear increasing trend (Z = 34.699, P<0.001). In terms of overlapping characteristics, group A had a significantly higher overlapping rate than the other two groups, and the overlapping rate of solid indicators remained the highest among all three groups (P < 0.05).

Conclusion: Differences in positive features were observed between thyroid nodules of different sizes. Except for suspicious microcalcifications, the incidence of other four positive features decreased with increasing nodule size. In addition, a negative correlation was observed between the overlap rate and nodule size. These results may provide a basis for sonographers to upgrade or downgrade thyroid nodules based on their own experience.

Keywords: size, thyroid, C-TIRADS, ultrasound

The thyroid gland, consisting of two connected lobes, is one of the largest endocrine glands in the human body, weighing 20–30 g in adults. Thyroid lesions are often found on the gland, with a prevalence of 4%–7%. Most of them are asymptomatic, and thyroid hormone secretion is normal.[1] Approximately 19–68% of the general population has thyroid nodules worldwide, most of which are benign, and malignant nodules account for about 7–15%.[2–5] Studies have shown that the global incidence of thyroid cancer is growing,[5,6] mainly due to the detection of papillary thyroid carcinoma (PTC) with the increasing application of ultrasound in thyroid examination.

With the advantages of convenience and high resolution, the value of ultrasound in the detection and evaluation of thyroid nodules has gradually been recognized, thus becoming the preferred examination modality in clinical settings. To

Received: 7 March 2024
Accepted: 22 April 2024
Published: 6 May 2024

© 2024 Qu et al. This work is published and licensed by Dove Medical Press Limited. The full terms of this license are available at https://www.dovepress.com/terms.php and incorporate the Creative Commons Attribution – Non Commercial (unported, v3.0) License (http://creativecommons.org/licenses/by-nc/3.0/). By accessing the work you hereby accept the Terms. Non-commercial uses of the work are permitted without any further permission from Dove Medical Press Limited, provided the work is properly attributed. For permission for commercial use of this work, please see paragraphs 4.2 and 5 of our Terms (https://www.dovepress.com/terms.php).

standardize the diagnosis and treatment of thyroid nodules, a variety of thyroid imaging reporting and data system (TIRADS) have been promulgated worldwide, such as American College of Radiology (ACR) TIRADS, Korean (K) TIRADS and European (EU) TIRADS.[7–9] In 2020, under the support of the Superficial Organ and Vascular Ultrasound Group of the Society of Ultrasound in Medicine of the Chinese Medical Association, as well as the Chinese Artificial Intelligence Alliance for Thyroid and Breast Ultrasound, the Chinese TIRADS (C-TIRADS) was developed in line with China's national conditions and medical status.[10] Research has indicated that C-TIRADS has a high diagnostic efficacy for thyroid nodules, with sensitivity and negative predictive value over 90% and 95%, separately.[11] Meanwhile, compared to other TIRADS, C-TIRADS is easier and more convenient and has been widely used in China.

Previous studies have reported different diagnostic values of ultrasound for thyroid nodules, which are related to the imaging features of nodules of different sizes.[12,13] However, no known research has focused on the changing mode of the positive features with increasing nodule volume. Based on the C-TIRADS, this study aimed to investigate the changing trend of positive features in 1558 different-sized benign and malignant thyroid nodules.

Materials and Methods

General Information

The ethics committee of Affiliated Hospital of Jiangnan University approved this retrospective study, and waived the requirement for informed consent. In our study, we recruited 1337 patients diagnosed with thyroid nodules pathologically from November 2021 to December 2023 at the Affiliated Hospital of Jiangnan University, Huai'an Cancer Hospital, and Zhongda Hospital Southeast University. There were 315 males and 822 females, with an overall mean age of 49.58 ±13.82 years (range from 19 to 84 years). A total of 1558 thyroid nodules were observed, with an average maximum diameter of 19.79±15.43 mm (range, 3–78 mm). The inclusion criteria were as follows: (1) initial diagnosis of thyroid nodules; (2) thyroid nodules confirmed by surgery and pathology; and (3) complete and clear ultrasound imaging data and clinical information. Patients were excluded if they (1) underwent puncture or treatment that might affect the ultrasound characteristics of thyroid nodules and (2) had no confirmed diagnosis by pathology or fine needle puncture.

Apparatus and Methods

Color Doppler ultrasound imaging instruments such as SonoScape S60 (SonoScape Medical Corp.), Logiq E9 (General Electric Co.), and Resona R7 (Mindray Medical Inc.) were used with probe frequencies of 7.8–15 MHz, 7.8–15 MHz and 7.8–15 MHz, respectively. During the examination, the patient was placed in a supine position with the bilateral neck fully exposed. The thyroid was scanned using a combination of cross-and longitudinal sections to investigate the nodules in multiple sections and at multiple angles. Evaluation of nodules was based on the C-TIRADS classification, including location, orientation, margin, acoustic halo, structure, echo, focal hyperechoic, rear echo, and size. All cases were examined and evaluated by qualified sonographers with > 10 years of experience. C-TIRADS positive features were identified, including vertical orientation, solid, marked hypoechogenicity, microcalcifications, and ill-defined/irregular margins/extrathyroidal extension.[10] Thyroid nodules were divided into three groups according to its maximum diameter: group A (≤10 mm), group B (10–20 mm) and group C (≥20 mm), and ultrasonic image feature was then evaluated based on C-TIRADS classification.

Evaluation of C-TIRADS Positive Features

According to the C-TIRADS system,[10] vertical orientation, solid composition, marked hypoechogenicity, microcalcifications, ill-defined/irregular margins, or extrathyroidal extension were regarded as positive features. Vertical orientation indicates that the long axis of the nodule and the skin tend to be perpendicular when evaluating the transverse or longitudinal section, and the anterior-posterior diameter of the nodule is greater than the left-right or upper-inferior diameter. A solid nodule is composed entirely of solid tissue and contains no cystic components. Marked hypoechogenicity nodules have lower echogenicity than the strap neck muscles. Microcalcification refers to the presence of a < 1 mm punctate strong echo in the nodule, and acoustic shadows may or may not appear in the rear. Nodule margin assessment depends on clarity and regularity. Irregular margins are spiculated, angular, or microlobulated; ill-defined

margins denote that the border of the nodule is difficult to distinguish from the surrounding thyroid parenchyma; and extrathyroidal invasion represents nodules invading the thyroid capsule, damaging the capsule.

Statistical Analysis

Continuous variables are expressed as mean ± standard deviation or median and interquartile range (IQR) for normally and non-normally distributed variables, respectively. Categorical variables were presented as counts (%). Numerical differences between the two groups were assessed using the chi-square test or Fisher's exact test for categorical variables, and the independent *t*-test or Mann–Whitney *U*-test for continuous variables. Multi-group comparisons were performed using one-way ANOVA or nonparametric tests, and pairwise comparisons were conducted when an overall significant difference was observed. The threshold for significance was set at P<0.05. All statistical analyses were performed using SPSS, Version 23.0 (SPSS Inc., Chicago, IL, USA).

Results

The Basic Data

A total of 1558 thyroid nodules were observed, including 507 (32.54%) benign nodules, 17 (1.09%) low-risk nodules and 1051 (67.46%) malignant nodules, the incidence of positive features in malignant nodules was higher than that in benign nodules. In group A, a total of 1016 nodules from 863 patients (male, n=324; female, n=539) aged from 19 to 74 years (mean age, 47.33±11.40 years) were included. In group B, a total of 301 nodules from 253 patients (male, n=91; female, n=162) aged from 16 to 77 years (mean age, 51.41±12.63 years) were included. In group C, a total of 241 nodules from 221 patients (male, n=88; female, n=133) aged from 16 to 79 years (mean age, 50.39±12.79 years) were included.

Pathological Results

According to the 5th edition of the World Health Organization (WHO) Classification of Endocrine Tumors,[14,15] the pathological findings in each group are shown in Table 1. In this study, we assigned low-risk thyroid nodules to the malignant classification.

Positive Features of Benign and Malignant Thyroid Nodules in Three Groups

There were significant differences (*P*<0.05) in the positive features between the benign and malignant thyroid nodules of different sizes (Table 2). Typical images of thyroid nodules of different sizes are shown in Figure 1.

Table 1 Pathological Results in Each Group n (%)

Pathological results	Group A	Group B	Group C
1. Benign	185 (11.87)	151 (9.69)	171 (10.98)
2. Nodular goiter	153 (9.82)	120 (7.70)	137 (8.79)
3. Follicular adenoma	11 (0.71)	17 (1.09)	30 (1.93)
4. Oncocytoma	0 (0)	4 (0.26)	2 (0.13)
5. Lymphocytic thyroiditis	13 (0.83)	8 (0.51)	2 (0.13)
6. Granulomatous thyroiditis	8 (0.51)	2 (0.13)	0 (0)
7. Low-risk	0 (0)	6 (0.39)	11 (0.71)
8. Non-invasive follicular thyroid tumor with papillary-like nuclear features	0 (0)	2(0.13)	3 (0.19)
9. Thyroid tumor with undetermined malignant potential	0 (0)	4 (0.26)	8 (0.51)
10. Malignant	831 (53.34)	144 (9.24)	59 (3.79)
11. Papillary carcinoma	827 (53.08)	138 (8.86)	47 (3.02)
12. Follicular thyroid cancer	4 (0.26)	5 (0.32)	4 (0.26)
13. Lymphoma	0 (0)	0 (0)	2(0.13)
14. Anaplastic carcinoma	0 (0)	0 (0)	2(0.13)
15. Medullary carcinoma	0 (0)	1 (0.06)	3 (0.19)
16. Metastatic carcinoma	0 (0)	0 (0)	1 (0.06)

Table 2 Positive Features in Each Groups

Group	Vertical orientation	Solid	Marked Hypoechogenicity	Suspicious Microcalcifications	Ill-defined margins/ irregular margins/ extrathyroidal extension
1. Group A					
2. Benign (185)	29.73 (55)	75.68 (140)	12.43 (23)	22.70 (42)	60.00 (111)
3. Malignant (831)	76.05 (632)	99.76 (829)	29.12 (242)	34.78 (289)	97.23 (808)
4. χ^2	148.290	193.504	21.860	10.044	242.895
5. *P* value	<0.001	<0.001	<0.001	0.002	<0.001
6. Group B					
7. Benign (151)	5.96 (9)	52.98 (80)	3.97 (6)	11.26 (17)	15.89 (24)
8. Malignant (150)	44.67 (67)	95.33 (143)	24.67 (37)	58.00 (87)	88.67 (133)
9. χ^2	59.732	70.308	26.315	72.702	159.701
10. *P* value	<0.001	<0.001	<0.001	<0.001	<0.001
11. Group C					
12. Benign (171)	0 (0)	22.22 (38)	1.75 (3)	2.34 (4)	5.85 (10)
13. Malignant (70)	15.71 (11)	75.71 (53)	12.86 (9)	58.57 (41)	75.71 (53)
14. χ^2		60.472	10.700	99.752	125.570
15. *P* value	<0.001	<0.001	0.001	<0.001	<0.001

Changing Trend of Benign and Malignant Thyroid Nodules in Three Groups

As the benign thyroid nodules grew, the incidence of vertical orientation (χ^2=79.864, *P*<0.001), solid (χ^2=101.970, *P*<0.001), marked hypoechogenicity (χ^2=19.166, *P*<0.001), suspicious microcalcifications (χ^2=38.172, *P*<0.001), and ill-defined/irregular margins/extrathyroidal extension (χ^2=144.611, *P*<0.001) decreased gradually. In addition, all positive features showed a linear decreasing trend (Z = 72.103, 101.081, 17.344, 33.909, and 129.304; $P < 0.001$), further details

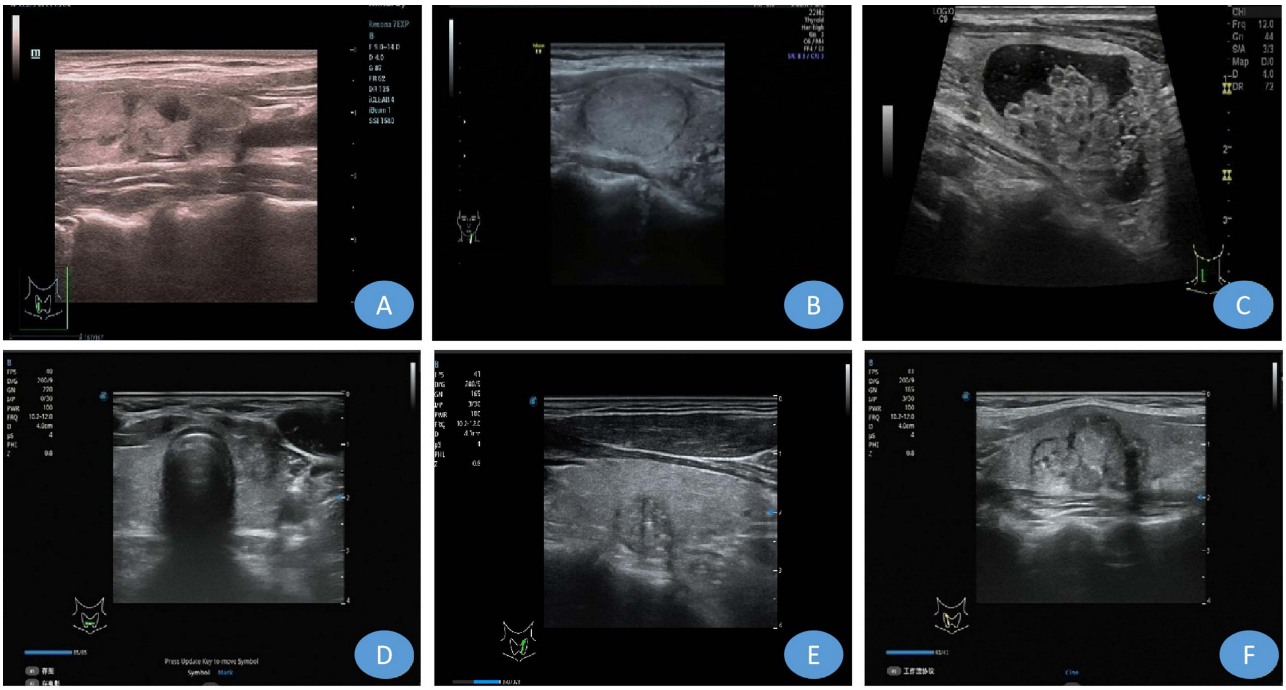

Figure 1 Typical features of different-sized benign and malignant thyroid nodules (**A**) benign thyroid nodule ≤10 mm (**B**) benign thyroid nodule 10–20 mm (**C**) benign thyroid nodule ≥20 mm (**D**) malignant thyroid nodule ≤10 mm (**E**) malignant thyroid nodule 10–20 mm (**F**) malignant thyroid nodule ≥20 mm.

are provided in Figure 2. With an increase in the size of the malignant thyroid nodules, the incidence of vertical orientation (χ^2=149.060, P<0.001), solid (χ^2=81.424, P<0.001), marked hypoechogenicity (χ^2=9.243, P=0.01), and ill-defined/irregular margins/extrathyroidal extension (χ^2=70.195, P<0.001) decreased gradually, with a linearly decreasing trend (Z = 148.854, 135.378, 8.590, and 70.195, P values less than 0.05). The incidence of suspicious microcalcifications (χ^2=38.817, P<0.001) increased gradually with a linearly increasing trend (Z=34.699, P<0.001), further details are provided in Figure 3.

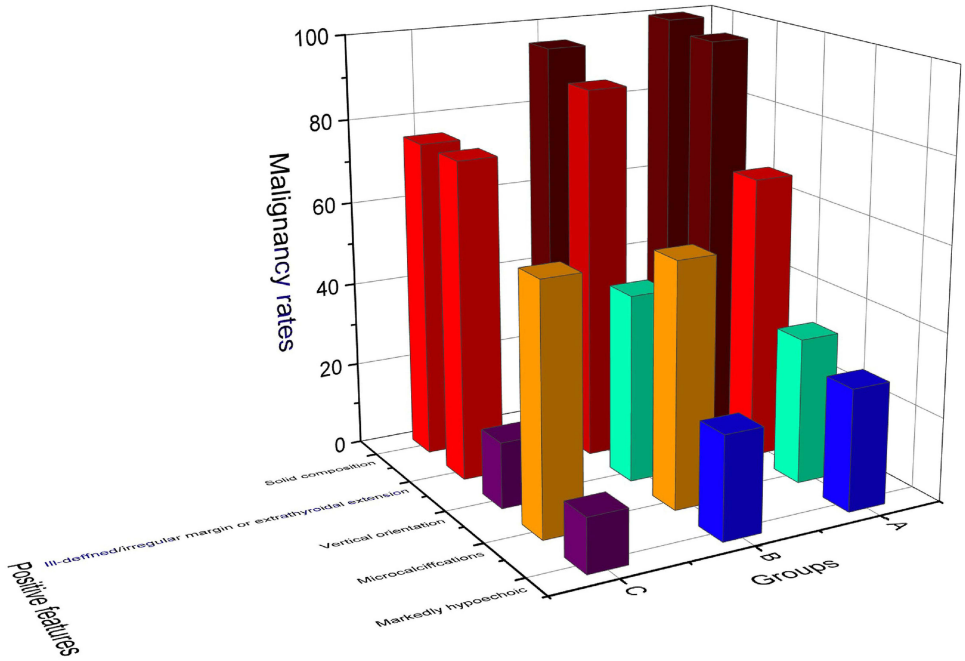

Figure 2 Alteration trend in positive features of different-sized benign thyroid nodules.

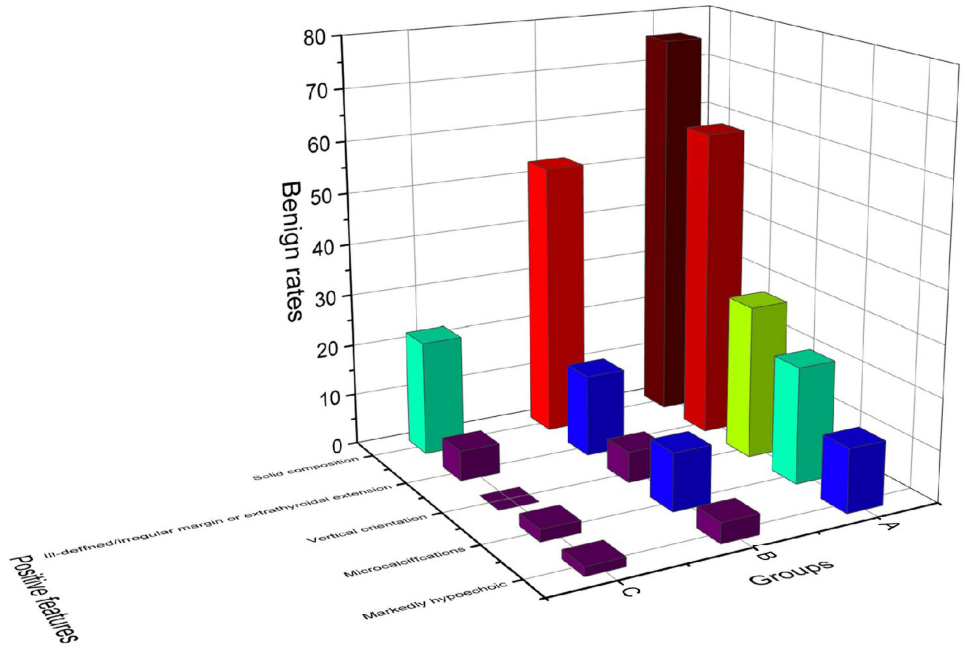

Figure 3 Alteration trend in positive features of different-sized malignant thyroid nodules.

Overlap Analysis in Positive Features of Benign and Malignant Thyroid Nodules in Three Groups

The overlap analysis of the positive features of benign and malignant thyroid nodules in the three groups is shown in Figure 4. In group A, the overlapping rates of benign and malignant nodules, from high to low, were solid, ill-defined /irregular margins/extrathyroidal extension, vertical orientation, suspicious microcalcifications, and marked hypoechogenicity. In Group B, the overlapping rate of benign and malignant nodules, from high to low, was solid, ill-defined/irregular margins/extrathyroidal extension, suspicious microcalcifications, vertical orientation, and emarked hypoechogenicity. In group C, the overlapping rate of benign and malignant nodules from high to low was solid, ill-defined/irregular margins/ extrathyroidal extension, suspicious microcalcifications, marked hypoechogenicity, and vertical orientation. In all three groups, the overlapping rate of solids was significantly higher than that of other positive features ($P<0.05$).

Discussion

The C-TIRADS system developed by Zhou et al was in line with China's national conditions and medical status, which defined vertical orientation, solid, marked hypoechogenicity, microcalcifications, and ill-defined/irregular margins/extrathyroidal extension as positive features. Thyroid nodules with 0, 1, 2, 3–4 and 5 positive features were classified as class 3, 4A, 4 B, 4C, and 5, respectively.[10] C-TIRADS is easy and convenient and has been widely used in China. The current study reported the varied diagnostic value of ultrasound for thyroid nodules, which is related to the imaging features of nodules of different sizes. However, no systematic research has focused on the distribution of positive features along with increasing nodule volume based on C-TIRADS. The Bethesda classification system for reporting thyroid cytopathology is the standard for interpreting fine needle aspirate (FNA). However, Mulita F et al suggested that incidental malignancy was found in 1.53% (8/522) and 19.19% (66/344) in Bethesda II and III thyroid nodules, so they hold the opinion that FNA categorized as Bethesda category II and III may have a higher risk of malignancy than traditionally believed.[16,17] The current study demonstrates that incidental thyroid carcinoma can be diagnosed after thyroidectomy even in patients with an FNA categorized as Bethesda II. Total thyroidectomy can be safely performed in patients with differentiated thyroid carcinoma without increasing the risk of early complications.[18] Both LigaSure vessel (LS) and harmonic scalpel (HS) exhibit identical safety profiles in thyroidectomies specifically regarding major bleeding complications that require reoperation. Additionally, HS was found to be more effective at achieving haemostasis, especially in the subgroup of patients with thyroid carcinoma.[19] So our study take surgical pathology as the gold standard, we retrospectively analyzed 1558 different-sized benign and malignant thyroid nodules and found that, except for suspicious microcalcifications, the incidence of vertical orientation, solid, marked hypoechogenicity, and ill-defined/irregular margins/extrathyroidal extension significantly decreased with increasing nodule size.

As benign thyroid nodules grew, the incidence of all positive features in C-TIRADS showed a linear decreasing trend, which had an impact on nodule scores to a certain extent. Specifically, the score gradually decreased with an increase in benign nodule volume, and the misdiagnosis rate also decreased. In contrast, the smaller the nodule, the greater its score,

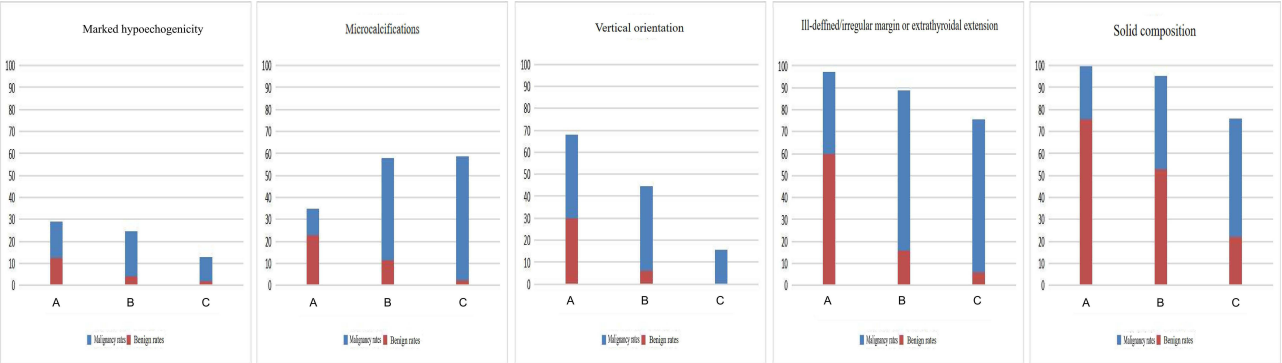

Figure 4 Overlap analysis of different-sized benign and malignant thyroid nodules.

especially for thyroid micronodules (≤ 10 mm) because the incidence of positive features of benign nodules was higher, which also increased the misdiagnosis rate of thyroid micronodules. In this study, the pathological types of thyroid micronodules included nodular goiter, follicular adenoma, granulomatous thyroiditis, and chronic lymphocytic thyroiditis, especially the latter two. When the nodules were small, their ultrasonographic features were similar to those of thyroid micronodular carcinoma,[20,21] which also led to positive features of thyroid micronodular nodules. Follicular adenoma mostly present as solid hypoechoic nodules on ultrasound when the size is small, and are less frequently accompanied by vertical orientation, marked hypoechogenicity, suspicious microcalcifications, and ill-defined/irregular margins/extrathyroidal extension.[22] As the size became larger, the probability of cystic degeneration gradually increased, with decreased incidence of positive features. In terms of nodular goiter, typical ultrasonographic features are thyroid nodules with well-defined margins, mostly accompanied by cystic degeneration. However, in our study, a small nodular goiter always formed highly suspicious nodules if interstitial collagenases, hemorrhage, calcification, multinucleated giant cell aggregation, and cholesterol crystallization were observed.[23–26] The above statements explained that benign nodules in this study could present as solid, hypoechoic, and punctate hyperechoic nodules, which made it difficult to differentiate them from thyroid microcarcinoma. Therefore, the overlap rate of positive features between benign and malignant thyroid micronodules also increased to some extent.

Differences in the incidence of vertical orientation (solid and marked hypoechogenicity) were found among thyroid nodules of different sizes, and the incidence decreased linearly with increasing nodule size. The majority of thyroid microcarcinomas in this study were PTC, which may include one or more positive features. In addition, cystic degeneration may occur in some PTC cases with an increase in nodule volume; however, the incidence of positive ultrasound features is significantly higher than that of benign nodules. In addition, for large malignant thyroid nodules, the ultrasonographic features of ATC and MTC are typical, both of which are solid with a large volume.[27,28] The ultrasonographic features of FTC were similar to those of follicular thyroid tumors, mostly accompanied by a peripheral acoustic halo,[29] some without other positive features, and some with cystic degeneration, which increased the difficulty of ultrasonographic diagnosis. However, thyroid follicular tumors and nodular goiters were predominant in the large benign and malignant thyroid nodules, and their ultrasonographic characteristics remained more typical. Nodular goiter mostly presented as cystic and solid nodules with well-defined margins, and at this time, for large thyroid nodules, the overlapping rate of positive features in C-TIRADS also reduced to some extent.

Among all positive features, the overlapping rate of solid indicators remained the highest in all three groups ($P<0.05$), but this might be overinterpreted because statistical analysis results from the counting method showed that among all evaluation indicators, the odds ratio of solid nodules was the highest, and the solid nodules must be 100% solid. ill-defined/irregular margins/extrathyroidal extension is the second most common positive indicator, which might be associated with a greater overlap in small-sized benign and malignant thyroid nodules. In addition, although statistical differences were found in the overlapping rates of vertical orientation and marked hypoechogenicity and suspicious microcalcifications among different-sized benign and malignant thyroid nodules, the rates were relatively low. Based on the decreasing trend and reduced overlapping rate of positive features, nodule scores also varied significantly. Our results indicated that the C-TIRADS scores for benign and malignant thyroid nodules were negatively correlated with volume; specifically, the scores for thyroid micronodules were the highest, which confirmed the difficulty in diagnosing micronodules in clinical practice. The smaller the nodules, the more suspicious are the benign and malignant nodules and vice versa. Therefore, we propose the following three suggestions: First, for smaller suspicious thyroid nodules, sonographers can appropriately downgrade their classification; for example, class 5 in C-TIRADS for nodules less than 10 mm can be assessed as class 4C, and for nodules with a score of 4, it can be improved to class 5. Second, for larger suspicious thyroid nodules, sonographers can appropriately upgrade their classification; for example, the score of 4C nodules in C-TIRADS is 3 or 4 points, and for those with a score of 4, it can be improved to class 5, which is also based on the varied positive features of different-sized thyroid nodules. Third, for larger thyroid nodules, the incidence of vertical orientation, solid, and marked hypoechogenicity nodules is the lowest, which underestimates the classification of malignant thyroid nodules.

Our study had several limitations. First, our study is a multicenter retrospective study, there may be bias in evaluating C-TIRADS positive features. Besides, there are three centers participating in the study, which is still relatively small. Third, the sample of patients was small,especiall for thyroid nodules>10mm.

Conclusion

Differences in the positive features were found among thyroid nodules of different sizes. Except for suspicious microcalcifications, the incidence of vertical orientation, solid, marked hypoechogenicity, ill-defined/irregular margins/extrathyroidal extensions decreased with increasing nodule size. In addition, a negative correlation was found between the overlap rate and nodule size, and solid indicators had the highest overlap rate among all indicators. These results may provide a basis for sonographers to upgrade or downgrade thyroid nodules based on their own experience.

Ethical Statement

The authors are accountable for all aspects of this work, ensuring that questions related to the accuracy or integrity of any part of the work are appropriately investigated and resolved. All procedures involving human participants were performed in accordance with the Declaration of Helsinki (revised 2013). The ethics committee of Affiliated Hospital of Jiangnan University approved this retrospective study, and waived the requirement for informed consent. Patient information, such as name, age, sex, occupation, address, ID card, related diseases, and treatment plan, was provided by the Affiliated Hospital of Jiangnan University during the treatment period due to illness. Owing to the privacy of patients, the Affiliated Hospital of Jiangnan University kept the above information confidential.

Funding

Wuxi Maternal and Child Health Promotion Project (FYTG202203).

Disclosure

The authors declare that they have no conflicts of interest.

References

1. Mulita F, Anjum F. Thyroid Adenoma. In: *StatPearls [Internet]*. Treasure Island (FL): StatPearls Publishing; 2024:1–2.
2. Hyun MK, Kim JH, Kwon JW. Incidence of thyroid cancer and medical cost among patients with newly diagnosed thyroid nodules in Korea: a retrospective cohort study using nationwide data. *J Cancer Res Ther*. 2019;15:676–680. doi:10.4103/0973-1482.204895
3. Wang J, Yu F, Shang Y, et al. Thyroid cancer: incidence and mortality trends in China, 2005–2015. *Endocrine*. 2020;68:163–173. doi:10.1007/s12020-020-02207-6
4. Pizzato M, Li M, Vignat J, et al. The epidemiological landscape of thyroid cancer worldwide: GLOBOCAN estimates the incidence and mortality rates of thyroid cancer in 2020. *Lancet Diabetes Endoc*. 2022;10:264–272. doi:10.1016/S2213-8587(22)00035-3
5. Miranda Filho A, Lortet-Tieulent J, Bray F, et al. Thyroid cancer incidence trends by histology in 25 countries: a population-based study. *Lancet Diabetes Endoc*. 2021;9:225–234. doi:10.1016/S2213-8587(21)00027-9
6. Lim H, Devesa SS, Sosa JA, Check D, Kitahara CM. Trends in thyroid cancer incidence and mortality in the United States, 1974-2013. *JAMA*. 2017;317:1338–1348. doi:10.1001/jama.2017.2719
7. Tessler FN, Middleton WD, Grant EG, et al. ACR thyroid imaging reporting and data system (TI-RADS): white Paper of the ACR TI-RADS Committee. *J Am Coll Radiol*. 2017;14:587–595. doi:10.1016/j.jacr.2017.01.046
8. Shin JH, Baek JH, Chung J, et al. The *Korean* society of thyroid radiology (KSThR) and the *Korean* society of radiology. ultrasonography diagnosis and imaging-based management of thyroid nodules: revised *Korean* society of thyroid radiology consensus statement and recommendations. *Korean J Radiol*. 2016;17:370–395. doi:10.3348/kjr.2016.17.3.370
9. Russ G, Bonnema SJ, Erdogan MF, et al. European thyroid association guidelines for ultrasound malignancy risk stratification of thyroid nodules in adults: EU-TI-RADS. *Eur Thyroid J*. 2017;6:225–237. doi:10.1159/000478927
10. Zhou J, Yin L, Wei X, et al. Chinese guidelines for ultrasound malignancy risk stratification of thyroid nodules: the C-TIRADS [J]. *Endocrine*. 2020;70:256–279. doi:10.1007/s12020-020-02441-y
11. Jin Z, Pei S, Shen H, et al. Comparative Study of C-TIRADS, ACR-TIRADS, and EU-TIRADS for diagnosis and management of thyroid nodules. *Acad Radiol*. 2023;30:2181–2191. doi:10.1016/j.acra.2023.04.013
12. Zhang S, Huang L, Huang Q, et al. Value of relative size in the ultrasound diagnosis of follicular thyroid neoplasms. *Int J Gen Med*. 2021;14:2321–2328. doi:10.2147/IJGM.S313468
13. Zhou Y, Li WM, Fan XF, Huang YL, Gao Q. Comparison of diagnostic efficacy of C-TIRADS-positive features on different sizes of thyroid nodules. *Int J Gen Med*. 2023;14:3483–3490. doi:10.2147/IJGM.S416403
14. Mete O, Wenig BM. Update from the 5th edition of the world health organization classification of head and neck tumors: Overview of the 2022 WHO Classification of head and neck neuroendocrine neoplasms. *Head Neck Pathol*. 2022;16:123–142. doi:10.1007/s12105-022-01435-8

15. Baloch ZW, Asa SL, Barletta JA, et al. Overview of the 2022 WHO classification of thyroid neoplasms. *Endocr Pathol*. 2022;33:27–63. doi:10.1007/s12022-022-09707-3
16. Mulita F, Iliopoulos F, Tsilivigkos C, et al. Cancer rate of Bethesda category II thyroid nodules. *Med Glas*. 2022;19:53–61. doi:10.17392/1413-21
17. Mulita F, Plachouri MK, Liolis E, et al. Patient outcomes following surgical management of thyroid nodules classified as Bethesda category III (AUS/FLUS). *Endokrynol Pol*. 2021;72:143–144. doi:10.5603/EP.a2021.0018
18. Mulita F, Verras GI, Dafnomili VD, et al. Thyroidectomy for the management of differentiated thyroid carcinoma and their outcome on early postoperative complications: A 6-year single-centre retrospective study. *Chirurgia*. 2022;117:556–562. doi:10.21614/chirurgia.2736
19. Mulita F, Theofanis G, Verras GI, et al. Comparison of postoperative bleeding using harmonic scalpel and LigaSure in thyroid surgery: a 15-year single-centre retrospective study. *Med Glas*. 2023;20:123–132. doi:10.17392/1629-23
20. Erdem Toslak I, Maleeva AS, Martin B, et al. Evaluation of lymphocytic thyroiditis in children using quantitative gray-scale ultrasound echo intensity with a PACS-based tool. *Clin Imaging*. 2020;66:93–97. doi:10.1016/j.clinimag.2020.04.034
21. Zhang Q, Liao L, Peng Q, et al. CEUS value for differentiating clinically atypical subacute thyroiditis from papillary thyroid carcinomas. *Ultrasound Med Biol*. 2021;47:3384–3392. doi:10.1016/j.ultrasmedbio.2021.09.001
22. Yang J, Sun Y, Li X, et al. Diagnostic performance of six ultrasound-based risk stratification systems for thyroid follicular neoplasms: a retrospective multicenter study. *Front Oncol*. 2022;20:1013410. doi:10.3389/fonc.2022.1013410
23. Hristu R, Eftimie LG, Paun B, et al. Pixel-level angular quantification of capsular collagen in second-harmonic generation microscopy images of encapsulated thyroid nodules. *J Biophotonics*. 2020;13:e202000262. doi:10.1002/jbio.202000262
24. Guerlain J, Perie S, Lefevre M, et al. Localization and characterization of thyroid microcalcifications: a histopathological study. *PLoS One*. 2019:14:e0224138. doi:10.1371/journal.pone.0224138
25. Pang T, Huang L, Deng Y, et al. Logistic regression analysis of conventional ultrasonography, strain elastography, and contrast-enhanced ultrasound characteristics for differentiating benign and malignant thyroid nodules. *PLoS One*. 2017;12(12):e018898. doi:10.1371/journal.pone.0188987
26. Peng Q, Niu C, Zhang M, et al. Sonographic characteristics of papillary thyroid carcinoma with coexisting Hashimoto Thyroiditis: Conventional ultrasound, acoustic radiation force impulse imaging and contrast-enhanced ultrasound. *Ultrasound Med Biol*. 2019;45:471–480. doi:10.1016/j.ultrasmedbio.2018.10.020
27. Bible KC, Kebebew E, Brierley J, et al. American Thyroid association guidelines for management of patients with anaplastic Thyroid Cancer. *Thyroid*. 2021;31:337–386. doi:10.1089/thy.2020.0944
28. Trimboli P, Mian C, Piccardo A, et al. Diagnostic tests for medullary thyroid carcinoma: an umbrella review. *Endocrine*. 2023;81:183–193. doi:10.1007/s12020-023-03326-6
29. Boursier L, Clerc UI, Garon J, et al. Ultrasound and cytological characteristics of noninvasive follicular thyroid neoplasms with papillary-like nuclear features compared with papillary carcinomas. *Ann Endocrinol*. 2020;81(28–33). doi:10.1016/j.ando.2019.10.004

International Journal of General Medicine

Dovepress

Publish your work in this journal

The International Journal of General Medicine is an international, peer-reviewed open-access journal that focuses on general and internal medicine, pathogenesis, epidemiology, diagnosis, monitoring and treatment protocols. The journal is characterized by the rapid reporting of reviews, original research and clinical studies across all disease areas. The manuscript management system is completely online and includes a very quick and fair peer-review system, which is all easy to use. Visit http://www.dovepress.com/testimonials.php to read real quotes from published authors.

Submit your manuscript here: https://www.dovepress.com/international-journal-of-general-medicine-journal