

# Undiagnosed Uterine Didelphys in a Multiparous Somali Woman with Two Previous Cesarean Sections

Adil Barut , Umut Erkok , Safia Ahmed Hussein 

Obstetrics and Gynecology Department, Somalia Mogadishu Turkey Recep Tayyip Erdogan Training and Research Hospital, Mogadishu, Somalia

Correspondence: Adil Barut, Obstetrics and Gynecology Department, Somali Mogadishu Turkey Recep Tayyip Erdoğan Research and Training Hospital, Mogadishu, Somalia, Email dradilbarut@gmail.com

**Background:** Uterine didelphys (UD) develops from failure of fusion of the paired Müllerian ducts, resulting in two noncommunicating uteri. We present a 31-year-old pregnant woman whose UD anomaly had not been detected during two previous cesarean sections and her presentation to a health-care clinic for her fifth pregnancy.

**Case Presentation:** She was referred to our obstetrics clinic due to suspicion of abdominal pregnancy and a complaint of severe lower abdominal pain. On ultrasonography, UD was detected with two adjacent uteri, one of which was empty and the other with a fetus of approximately 1100 g at 28 weeks and 1 day of gestational age. Magnetic resonance imaging confirmed the presence of UD. Due to severe lower abdominal pain of the patient and severe oligohydramnios of the fetus, emergency cesarean section was performed, and a 980 g male baby was delivered.

**Conclusion:** This case exemplifies how difficult life is for women living in an underdeveloped and resource-limited country like Somalia.

**Keywords:** uterine didelphys, pregnancy, cesarean section

## Introduction

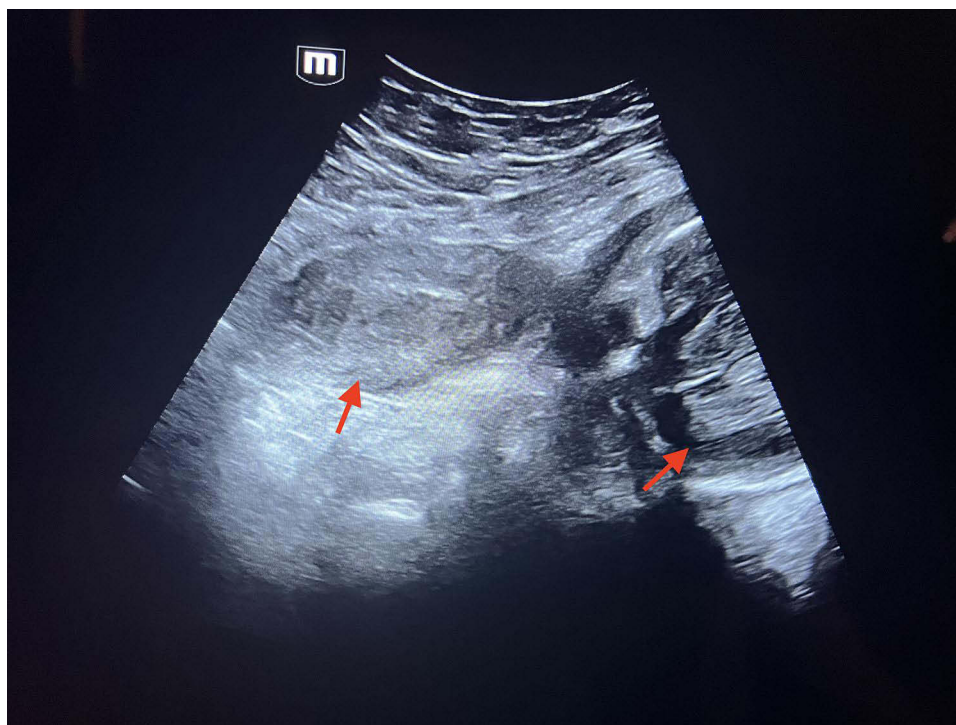
Uterine didelphys (UD) develops from failure of fusion of the paired Müllerian ducts, resulting in two uterine horns and creating two noncommunicating cavities. Each uterine cavity has a fallopian tube, but may or may not have its own cervix. Of all Müllerian anomalies, UD comprises 8%–10%, and has an incidence of one in 3000 women. A single vaginal canal is rarely encountered.<sup>1–4</sup>

UD is known to be accompanied by renal anomalies, which are often unilateral and right-sided, 15%–25% of the time.<sup>1–4</sup> Although this anomaly can be detected by ultrasound examination at any trimester of pregnancy, this may not occur in underdeveloped countries where diagnostic tools are unavailable or extremely limited. Somali is an example of one such countries where many pregnant women may not have the chance to see an obstetrician until delivery or have to give birth at home, even without the help of a midwife.

## Case Presentation

A 31-year-old pregnant woman (gravida 5, para 4) was referred to the obstetrics department of a tertiary health-care center in Mogadishu, Somalia because of a suspected abdominal pregnancy and a 2-day history of severe lower abdominal pain. On the morning of presentation, she had visited a health-care clinic with a complaint of severe lower abdominal pain, where she had her first ultrasound examination during pregnancy. An initial diagnosis of abdominal pregnancy was made. At the current presentation, she did not remember her last menstrual bleeding and did not report any problems with her four prior full-term pregnancies, which ended up with normal vaginal deliveries in the first two and cesarean sections for the latter two. No information could be elicited from the patient concerning her previous cesarean sections.

Physical examination was unremarkable except for abdominal pain on palpation. Uterine contractions were present on a nonstress test. Pelvic examination showed a soft and 2 cm dilated cervix. Transabdominal ultrasonography revealed two adjacent uteri, one of which was empty (Figure 1, arrow) and the other bearing a fetus of approximately 1100 g at 28



**Figure 1** Transabdominal ultrasound showing two adjacent noncommunicating uteri (arrows), one of which is empty and the other is bearing a fetus.

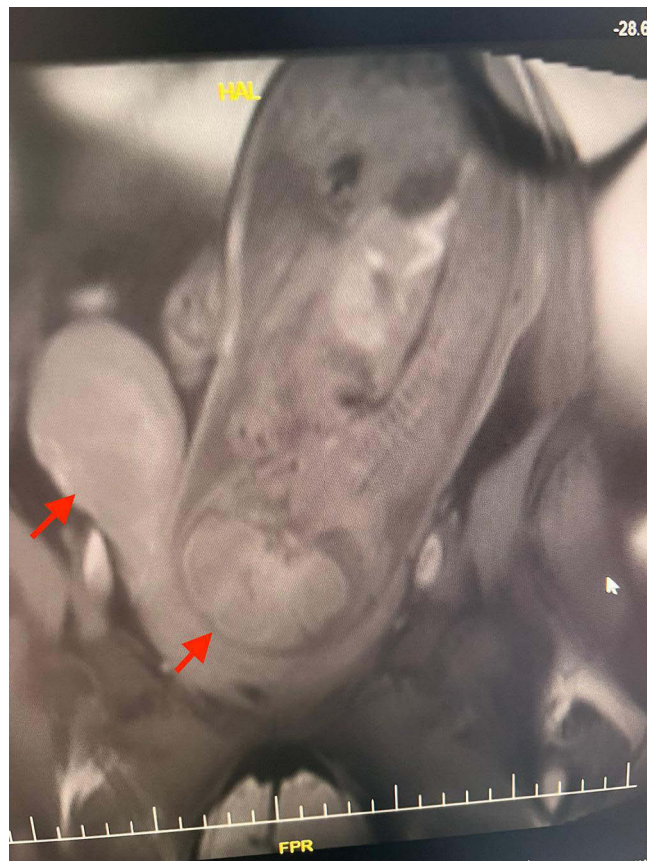weeks and 1 day of gestational age, with cephalic presentation and severe oligohydramnios (Figure 1). Magnetic resonance imaging substantiated ultrasonographic findings of the two uteri, with a single fetus in the left one having cephalic presentation, findings consistent with intrauterine pregnancy (Figure 2, arrow). A diagnosis of UD was made.

On the same day of presentation and after administration of betamethasone, due to the very severe lower abdominal pain of the patient and severe oligohydramnios of the fetus, the patient underwent emergency cesarean section under general anesthesia, and a 980 g male baby was delivered. His 1- and 5-min APGAR scores were 4 and 5, respectively. The newborn was transferred to the newborn intensive care unit for postnatal care. The mother had an uneventful postoperative course and was discharged home on the second postoperative day in very good condition. Given her background of poor health-seeking behavior and the three cesarean sections she had undergone, the patient was counseled about appropriate ways of contraception other than a uterine device.

## Discussion

Although UD can be diagnosed with ultrasonography at any time, particularly during pregnancy, it may easily go unnoticed in underdeveloped countries like Somalia, where women have been particularly unlucky amid a host of adverse conditions, including lack of security throughout the country because of ongoing civil war, resource-limited health-care facilities, and transportation difficulties, as well as poverty. This case also emphasizes the shortcomings of the health-care system, particularly with regard to obstetric policies and services and the training and experience of obstetricians.

The current case had a history of two deliveries with cesarean section, yet her anomaly had been missed. Moreover, at the time of presentation to another clinic with severe lower abdominal pain, the anomaly was not suspected on ultrasonography and the clinical picture was mistaken for abdominal pregnancy. Documentation of UD has mainly been reported in women before pregnancy or during examinations for their first pregnancy.<sup>1,5</sup> Conversely, as with our case, reports of UD have been rare in women whose diagnosis has been missed before or during previous pregnancies and cesarean section deliveries.<sup>6</sup>



**Figure 2** Magnetic resonance image showing two adjacent noncommunicating uteri (arrows), one of which is empty and the other is bearing a fetus.

## Conclusion

This case exemplifies how difficult life is for women living in an underdeveloped and resource-limited country like Somalia. Apart from the UD anomaly being undiagnosed, many women experience their pregnancies without even seeing an obstetrician and deliver their babies at home without medical support. Apart from providing the necessary education and training to all parties concerned, ie, patients and obstetricians, it should be noted that a great majority of problems encountered in underdeveloped countries are of international nature and thus cannot be solved without international cooperation and collaboration.

## Consent

Informed consent was obtained from the patient for the publication of her case.

## Institutional Approval

Institutional review board approval is not required by our hospital if identifiable information is not used in the case report.

## Disclosure

The authors report no conflicts of interest in this work.

---

## References

1. Clare Margaret C, Karim B, Ibrahim Fawzy H, Edward O. Uterine didelphys: diagnosis, management and pregnancy outcome. *BMJ Case Rep.* 2021;14(3):e242233. doi:10.1136/bcr-2021-242233
2. Ćwiertnia A, Borzyszkowska D, Golar A, et al. The impact of uterus didelphys on fertility and pregnancy. *Int J Environ Res Public Health.* 2022;19(17):10571. doi:10.3390/ijerph191710571

3. Sanfilippo JS, Peticca K. Uterus didelphys: diagnosis, treatment, and impact on fertility and reproduction. In: Pfeifer SM, editor. *Congenital Müllerian Anomalies: Diagnosis and Management*. Springer International Publishing; 2016:105–109.
4. Yayna AA, Ayza A, Dana WW, et al. A rare case report of uterine didelphys, in which one uterus carried a pregnancy while the other prolapsed, with a successful pregnancy outcome resulting in an alive-term delivery. *SAGE Open Med Case Rep*. 2023;11:2050313x231159505. doi:10.1177/2050313x231159505
5. Huang W, Fang X, Du X. Uterus didelphys and pregnancy: a case study of successful outcomes amidst obstetric complexity. *Asian J Surg*. 2023;46(12):5464–5465. PMID: 37537073. doi:10.1016/j.asjsur.2023.07.106
6. Ani EO, Ugwa EA, Taiye AB, Agbor IE, Suleiman IS. Simultaneous pregnancy in each uterine cavity of a double uterus in a young Nigerian multipara who presented with a retained second twin following an unsupervised preterm labor at home; Case report. *Int J Surg Case Rep*. 2018;42:224–226. PMID: 29275238; PMCID: PMC5985250. doi:10.1016/j.ijscr.2017.11.068

International Journal of Women's Health

Dovepress

### Publish your work in this journal

The International Journal of Women's Health is an international, peer-reviewed open-access journal publishing original research, reports, editorials, reviews and commentaries on all aspects of women's healthcare including gynecology, obstetrics, and breast cancer. The manuscript management system is completely online and includes a very quick and fair peer-review system, which is all easy to use. Visit <http://www.dovepress.com/testimonials.php> to read real quotes from published authors.

Submit your manuscript here: <https://www.dovepress.com/international-journal-of-womens-health-journal>