

A Case Report of Herpes Zoster After Botulinum Toxin Injections

Shadi Zari 

Department of Dermatology, College of Medicine, University of Jeddah, Jeddah, Saudi Arabia

Correspondence: Shadi Zari, Department of Dermatology, College of Medicine, University of Jeddah, Saudi Arabia, Email Shadizarimd@gmail.com

Abstract: This case report presents a rare occurrence of herpes zoster (HZ) outbreak in a 50-year-old male following botulinum toxin (BTX) type A injections. The patient developed burning swollen lesions on the left forehead four days after receiving BTX injections. Physical examination revealed papules and erosions in a dermatomal distribution. He was diagnosed with HZ and promptly treated with oral acyclovir. The lesions resolved within two weeks without complications. Previous literature reports a few similar HZ outbreaks following aesthetic treatments with BTX injections. The exact mechanism triggering varicella reactivation in these cases remains unclear. Prompt diagnosis and treatment of HZ are crucial in order to minimize outbreak duration and reduce complications. Physicians should maintain awareness of HZ as a potential complication following BTX injections.

Keywords: botulinum toxin, complications, herpes zoster, shingles

Introduction

This report discusses a rare case of herpes zoster (HZ) outbreak in a 50-year-old male, occurring shortly after botulinum toxin (BTX) type A cosmetic injections. The report explores potential triggers, clinical aspects of HZ, and the need for heightened physician awareness.

Case Presentation

A 50-year-old male presented with burning swollen lesions appearing on the left side of the forehead 4 days after receiving 50 units of BTX type A (Botox; Botox Cosmetic, Allergan, Irvine, CA) injections by the author to treat the glabella, forehead, and lateral periorbital areas. On physical examination, the patient had papules and erosions on an erythematous base in a dermatomal distribution on the left side of the forehead [Figure 1](#). He had no eye symptoms and no systemic symptoms. There was no prior history of HZ or immunosuppression, and the patient was not on any medications. He was otherwise healthy, and his past medical history was unremarkable. A diagnosis of HZ was made in the distribution of the ophthalmic division of the left trigeminal nerve. The patient was immediately started on oral acyclovir 800 mg every 4 hours \times 7 days. Since the lesions were close to the right eyebrow, he was also referred to an ophthalmologist who confirmed that there was no eye involvement. The burning lesions resolved within 2 weeks without any sequelae. Interestingly, the patient has previously received BTX injections 3 times per year on average with the author for the past 7 years in the same area with no complications reported.

Discussion

Incidents of HZ outbreaks following aesthetic treatments with BTX injections of the forehead and glabella have been previously documented in four female patients in the scientific literature. The first two women, aged 48 and 55, received injections in the glabella, forehead, and lateral periorbital areas.¹ The third case involved a 32-year-old woman who was administered 50 units of BTX on both sides to lift the mandibular margin.² The fourth case involved a 33-year-old woman who received BTX injections of an unknown dose in the forehead, glabella, and lateral periorbital areas.³ Although all the reported

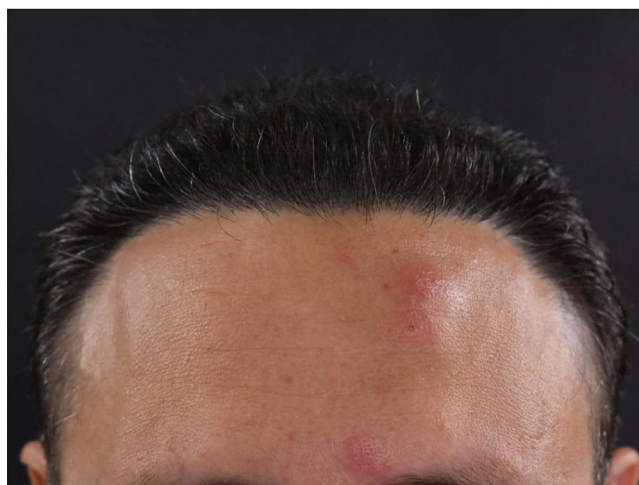


Figure 1 Lesions consistent with herpes zoster in the ophthalmic division of the left trigeminal nerve distribution.

cases were of female patients, this is the first case report of HZ following cosmetic BTX injections involving a male. Similar reactions of HZ have been reported following both invasive and noninvasive procedures.

HZ is caused by the reactivation of varicella zoster virus. Upon reactivation, it manifests as vesicles in a unilateral dermatomal distribution. The onset is typically preceded by a prodromal phase, which may include symptoms such as pain, pruritus, dysesthesia, or general malaise. Facial HZ may be accompanied by symptoms such as headache, earache, and visual disturbances.⁴ HZ is more prevalent in immunocompromised and older individuals, with an increased incidence starting from the age of 55.⁵

In the context of minor procedures, the mechanical trauma caused by needles and local inflammation may contribute to the reactivation of the varicella zoster virus (VZV). The exact immunological mechanism responsible for triggering this reactivation is still unknown but could be related to a decrease in varicella zoster virus-specific cell-mediated immune responses.⁶ The amount of botox complex proteins taken up by dendritic cells from a BTX formulation and subsequently presented to T cells through their specific T-cell receptors plays a significant role in determining antigenicity. On the other hand, when T cells are exposed to antigens for an extended period, the production of CD4+ and CD8+ T cells decreases, leading to a phenomenon known as T cell exhaustion, which is influenced by certain epigenetic factors. As a result of the reduction in CD4+ and CD8+ T cells, the VZV can reactivate.^{3,7}

Postherpetic neuralgia is a frequent complication of HZ, which is defined as pain that continues for at least 120 days after the onset of the disease.⁸ The occurrence and length of postherpetic neuralgia are closely linked to the age of the patients.^{9,10} Other uncommon complications of HZ include encephalitis, myelitis, nerve palsies, and vision impairment.¹¹ Consequently, it is essential to promptly treat HZ in order to minimize the duration and intensity of the outbreak and lower the chances of complications. The Centers for Disease Control and Prevention (CDC) recommends two doses of the recombinant zoster vaccine (Shingrix), administered 2 to 6 months apart, for immunocompetent adults aged 50 and above. This recommendation applies irrespective of whether the individuals have had previous episodes of HZ or varicella. Given that herpes zoster reactivation seems to be quite rare following BTX treatment of the upper face, antiviral therapy is not routinely recommended as a preventive measure in patients undergoing BTX treatments.

Although the incidence of adverse allergic reactions to BTX has been sporadic, there has been an increase in reported cases during the COVID-19 epidemic. Several cases have been documented in the literature, describing various types of hypersensitivity to BTX in women who either had a COVID-19 infection or received a COVID-19 vaccination. In COVID-19 patients, there is an excessive response from neutrophils, and the immune system and complement become hyperactive. Therefore, caution should be exercised when administering BTX injections, particularly in patients with fever or suspected COVID-19 infection.¹²

Conclusion

This case underscores the need for clinicians to maintain a high degree of suspicion for unilateral skin lesions or pain following BTX injections. Although HZ is more commonly associated with immunosuppression and older individuals, it can occur in younger patients devoid of risk factors. Any patient reporting prodromal symptoms or developing a skin eruption after BTX injections should be evaluated for HZ. Once the diagnosis is made, antiviral therapy should be initiated immediately to minimize the risk of complications. Heightened physician awareness is crucial.

Abbreviations

HZ, herpes zoster; BTX, botulinum toxin.

Ethical Approval and Informed Consent

The patient provided written informed consent for the publication of this case report and accompanying image. IRB approval was not required for the publication of this case report.

Funding

There was no funding received for this case report.

Disclosure

The author reports no conflicts of interest in this case report.

References

1. Graber EM, Dover JS, Arndt KA. Two cases of herpes zoster appearing after botulinum toxin type a injections. *J Clin Aesthet Dermatol*. 2011;4(10):49–51.
2. Zhuang J, Liu T, Hu J. Herpes zoster after botulinum toxin combined with hyaluronic acid injection. *J Craniofac Surg*. 2023;34(5):1503–1506. doi:10.1097/SCS.00000000000009359
3. Amini-Salehi E, Eslami N, Tamimi A, et al. Unusual herpetic reactivation in a young female following botox injection: a case report study. *BMC Infect Dis*. 2023;23(1):647. doi:10.1186/s12879-023-08514-3
4. Wareham DW, Breuer J, Wareham DW, Breuer J. Herpes zoster. *BMJ*. 2007;334(7605):1211–1215. doi:10.1136/bmj.39206.571042.AE
5. Choo PW, Donahue JG, Manson JE, Platt R. The epidemiology of varicella and its complications. *J Infect Dis*. 1995;172(3):706–712. doi:10.1093/infdis/172.3.706
6. Watson CP. Postherpetic neuralgia: the importance of preventing this intractable end-stage disorder. *J Infect Dis*. 1998;178(Suppl 1):S91–S94. doi:10.1086/514269
7. Wherry EJ. T cell exhaustion. *Nat Immunol*. 2011;12(6):492–499. doi:10.1038/ni.2035
8. Whitley RJ. A 70-year-old woman with shingles. *JAMA*. 2009;302(1):73–80. doi:10.1001/jama.2009.822
9. Bowsher D. The effects of pre-emptive treatment of postherpetic neuralgia with amitriptyline: a randomized, double-blind, placebo-controlled trial. *J Pain Symptom Manage*. 1997;13(6):327–331. doi:10.1016/S0885-3924(97)00077-8
10. McKendrick MW, McGill JL, Wood MJ. Lack of effect of acyclovir on postherpetic neuralgia. *BMJ*. 1989;298(6671):431. doi:10.1136/bmj.298.6671.431
11. Gilden DH, Kleinschmidt-DeMasters BK, LaGuardia JJ, Mahalingam R, Cohrs RJ. Neurologic complications of the reactivation of varicella-zoster virus. *N Engl J Med*. 2000;342(9):635–645. Erratum in: *N Engl J Med* 2000 Apr 6;342(14):1063. doi:10.1056/NEJM200003023420906
12. Kubaisi T, Sharquie K. The impact of COVID-19 infection on botulinum toxin hypersensitivity: case report and literature review. *J Pak Assoc Dermatol*. 2023;33(4):1762–1766.

International Medical Case Reports Journal

Dovepress

Publish your work in this journal

The International Medical Case Reports Journal is an international, peer-reviewed open-access journal publishing original case reports from all medical specialties. Previously unpublished medical posters are also accepted relating to any area of clinical or preclinical science. Submissions should not normally exceed 2,000 words or 4 published pages including figures, diagrams and references. The manuscript management system is completely online and includes a very quick and fair peer-review system, which is all easy to use. Visit <http://www.dovepress.com/testimonials.php> to read real quotes from published authors.

Submit your manuscript here: <https://www.dovepress.com/international-medical-case-reports-journal-journal>