

# Pneumonia Caused by *Chlamydia psittaci* and SARS-CoV-2 Coinfection Diagnosed Using Metagenomic Next-Generation Sequencing: A Case Report

Anbing Zhang<sup>1,\*</sup>, Jinguang Liang<sup>2,\*</sup>, Xiaoli Lao<sup>1,3</sup>, Xiuqiong Xia<sup>1</sup>, Jianping Liang<sup>1,3</sup>

<sup>1</sup>Department of Respiratory and Critical Care Medicine, Zhongshan People's Hospital, Zhongshan, Guangdong Province, People's Republic of China;

<sup>2</sup>Department of Respiratory and Critical Care Medicine, Zhongshan Huangpu People's Hospital, Zhongshan, Guangdong Province, People's Republic of China; <sup>3</sup>Graduate School, Guangdong Medical University, Zhanjiang, Guangdong Province, People's Republic of China

\*These authors contributed equally to this work

Correspondence: Jianping Liang, Department of Respiratory and Critical Care Medicine, Zhongshan People's Hospital, 2 Sunwen East Road, Zhongshan, 528400, People's Republic of China, Tel +86-159-8910-7884, Fax +86-760-8988-0256, Email ljzhangshan@163.com

**Abstract:** We report a case of pneumonia caused by coinfection with *Chlamydia psittaci* and the severe acute respiratory syndrome coronavirus 2 (SARS-CoV-2) Omicron XBB.1 variant, confirmed using metagenomic next-generation sequencing (mNGS) and quantitative polymerase chain reaction (qPCR). *C. psittaci* and SARS-CoV-2 were detected in bronchoalveolar lavage fluid using mNGS. Additionally, mNGS detected *C. psittaci* in blood and nasopharyngeal specimens and was more sensitive than qPCR. The patient recovered after treatment with moxifloxacin. This report highlights the use of coinfections of *C. psittaci* and SARS-CoV-2, as mNGS has already been recognized to be a diagnostic tool for identifying coinfections.

**Keywords:** coinfection, quantitative reverse-transcription polymerase chain reaction, bronchoalveolar lavage fluid, zoonoses

## Introduction

Psittacosis, also known as *Chlamydia psittaci* (*C. psittaci*) pneumonia, is a zoonotic infection transmitted to humans from birds contaminated with *C. psittaci* through the inhalation route. *C. psittaci* accounts for approximately 1% of cases of community-acquired pneumonia.<sup>1</sup> It is underdiagnosed and, hence, insufficiently understood by clinicians and the public. Previously, psittacosis was diagnosed primarily using serology and polymerase chain reaction (PCR) testing.<sup>2</sup> However, in recent years, metagenomic next-generation sequencing (mNGS) has been used extensively in hospitals at all levels in China to diagnose psittacosis.<sup>3,4</sup>

Familial clustering of psittacosis was reported during the coronavirus disease (COVID-19) pandemic,<sup>5</sup> including clustering in a COVID-19 testing area.<sup>6</sup> Han et al<sup>7</sup> have previously reported a case of psittacosis complicated by severe acute respiratory syndrome coronavirus 2 (SARS-CoV-2) infection; however, the authors did not report the SARS-CoV-2 variant and did not compare the results of pharyngeal swabs, blood, and bronchoalveolar lavage specimens for detecting *C. psittaci* or SARS-CoV-2, nor the respective advantages of mNGS and quantitative PCR (qPCR) testing. Here, we report a case of psittacosis complicated by SARS-CoV-2 infection. This report highlights the use of mNGS as an essential diagnostic tool in identifying coinfections of *C. psittaci* and SARS-CoV-2.

## Case Description

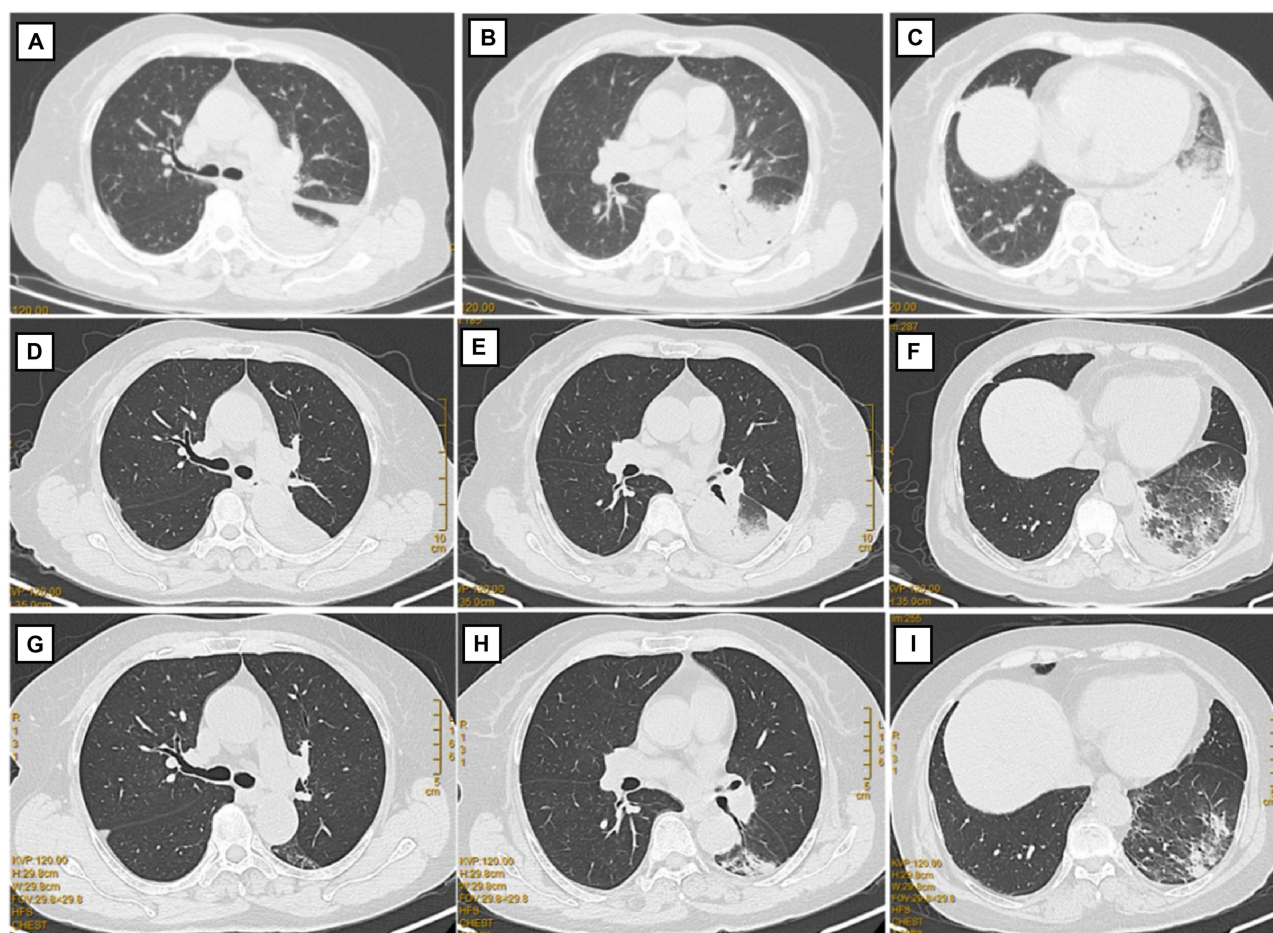
In May 2023, a 75-year-old woman with a history of hypertension and no past SARS-CoV-2 infection was admitted to our hospital for chills, pyrexia (maximum temperature, 38°C), cough, headache, asthenia, myalgia, and lumbago. The patient had

received two doses of Sinopharm/BIBP COVID-19 vaccine. Inquiring about her exposure to birds revealed that she had worked in a slaughterhouse and slaughtered chickens before the disease onset.

The patient was not tested for SARS-CoV-2 on admission to the hospital. Chest computed tomography (CT) on day 1 after admission revealed massive consolidation in the left lower lung and a left-sided pleural effusion (Figure 1), leading to a diagnosis of pneumonia. The laboratory test results revealed elevated white blood cell (WBC) and neutrophil counts, an elevated neutrophil percentage, and elevated levels of C-reactive protein (CRP), aspartate aminotransferase, fibrinogen, and D-dimer (Table 1).

Intravenous piperacillin-tazobactam (4 g/0.5 g) was administered every 8 hours to treat pneumonia. However, 3 days after admission, the patient developed recrudescence pyrexia (maximum temperature, 39.2°C). Fiberoptic bronchoscopy revealed tracheitis and bronchitis with bronchial mucosal hyperemia in the left lower lobe and various subsegments.

The patient underwent bronchoalveolar lavage of the left lower lobe, and bronchoalveolar lavage fluid (BALF), blood, and nasopharyngeal swab (NPS) samples were tested using mNGS to identify the pathogen. Clinical samples were collected according to the standard protocol of our hospital. DNA was extracted from BALF, blood, and other clinical samples using a TIANamp Micro DNA Kit (DP316, Tiangen Biotech Co., Beijing, China), followed by DNA/RNA library construction, high-quality sequencing, and classification analysis, as described previously.<sup>8</sup> The mNGS analysis detected *C. psittaci* in the BALF (sequence number: 874), peripheral blood (sequence number: 2), and NPS (sequence number: 4) samples, as well as SARS-CoV-2 Omicron XBB.1 in the BALF (sequence number: 1,847,027) and NPS (sequence number: 224,671) samples (Figure 2).

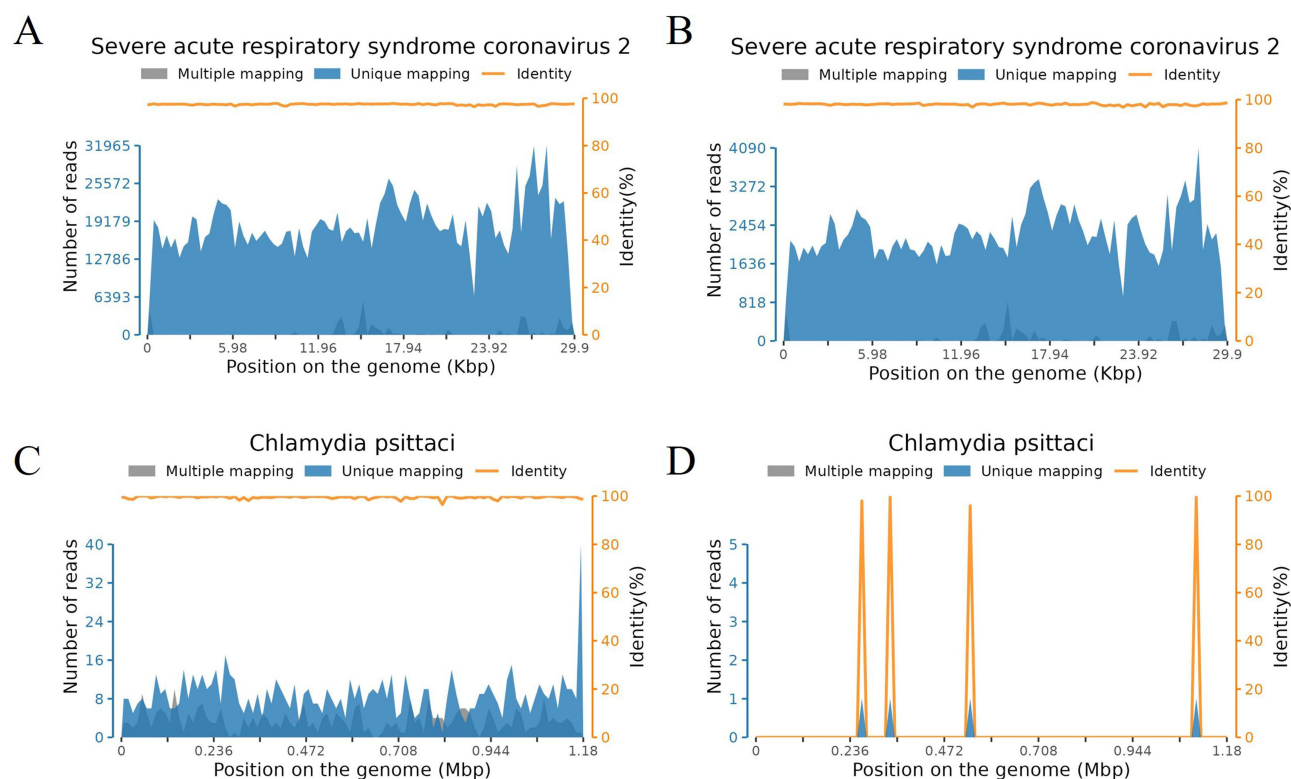


**Figure 1** Chest computed tomography. (A–C) Chest computed tomography (CT) on admission showing massive consolidation in the left lower lung field and left-sided pleural effusion. (D–F) Chest CT after 1 week of treatment with moxifloxacin, showing a reduction in the consolidation, lung lesions, and pleural infusion. (G–I) Chest CT after 2 weeks of treatment with moxifloxacin.

**Table 1** Laboratory Test Results of the Patient with *Chlamydia Psittaci* Pneumonia and SARS-CoV-2 Coinfection

Parameter	Normal Range	On Admission	1 Week After Starting MFX
WBC ( $\times 10^9/L$ )	4–10	12	7.58
Neutrophils ( $\times 10^9/L$ )	2–7	10.68	5.07
Lymphocytes ( $\times 10^9/L$ )	0.8–4	0.73	1.57
Eosinophils ( $\times 10^9/L$ )	0.5–5	0	0.43
Monocytes ( $\times 10^9/L$ )	3–10	0.57	0.43
Basophils ( $\times 10^9/L$ )	0–1	0.02	0.06
Neutrophil (%)	50–70	89	66.7
Lymphocyte (%)	20–40	6.1%	20.8
Eosinophil (%)	0.5–5	0%	5.7
Monocyte (%)	3–10	4.7%	6
Basophil (%)	0–1	0.2%	0.8
Hemoglobin (g/L)	113–151	124	129
Platelets ( $\times 10^9/L$ )	101–320	243	363
CRP (mg/L)	0–8	78	6
PCT (ng/mL)	0–5	0.16	0.05
CK (U/L)	26–174	171	103
CK-MB (U/L)	0–24	9.4	5.7
Myoglobin (ng/mL)	0–110	48.7	40.5
BNP (pg/mL)	0–100	196	191
AST (U/L)	13–40	47.5	19.4
ALT (U/L)	7–40	38.3	10.4
LDH (U/L)	0–247	227	233
Creatinine ( $\mu\text{mol/L}$ )	45–84	106.4	68.5
K (mmol/L)	3.5–5.5	4.07	3.94
Na (mmol/L)	135–145	137	142
Cl (mmol/L)	95–105	99.9	108.4
Ca (mmol/L)	2.08–2.6	2	2.08
P (mmol/L)	0.96–1.62	0.86	1.01
Fibrinogen (g/L)	2–4	7.88	6.19
D-dimer (mg/L)	0–0.5	2.84	2.84

**Abbreviations:** ALT, alanine aminotransferase; AST, aspartate aminotransferase; BNP, brain natriuretic peptide; CK, creatine kinase; CK-MB, creatine kinase MB isoenzyme; CRP, C-reactive protein; LDH, lactate dehydrogenase; MFX, moxifloxacin; PCT, procalcitonin; WBC, white blood.



**Figure 2** Detection depths and coverage of SARS-CoV-2 Omicron XBB.1 and *Chlamydia psittaci* in different sample types. **(A and B)** Detection depths and coverage of SARS-CoV-2 Omicron XBB.1 in **(A)** BALF and **(B)** nasopharyngeal swab specimens. **(C and D)** Detection depths and coverage of *C. psittaci* in **(C)** BALF and **(D)** nasopharyngeal swab specimens.

The mNGS results were confirmed using qPCR tests for *C. psittaci* and SARS-CoV-2. The primer sets targeted the *OmpA* and *ORF/N* genes of *C. psittaci* and SARS-CoV-2, respectively (Table 2). The qPCR detected *C. psittaci* nucleic acid in the BALF only (Ct: 24.59) and SARS-CoV-2 nucleic acid in both the BALF and NPS specimens (Ct: 38.57 and 31.07, respectively; Table 3).

Serum samples were tested for SARS-CoV-2 immunoglobulin (Ig)M/IgG using chemiluminescence immunoassays, performed according to the instructions of Guangzhou Huayin Health Medical Group Co., Ltd. The patient tested negative for SARS-CoV-2 IgM (cutoff index, 0.87) and positive for SARS-CoV-2 IgG (cutoff index, 64.58).

**Table 2** *C. Psittaci* and COVID-19 PCR Primers Used in This Study

Primer Set	Sequence (5'-3')	F/R	Target
<i>C. psittaci</i>	TGAGAAATACCTAGCAAAGTTCCCA	F	<i>OmpA</i>
<i>C. psittaci</i>	TCTCAATGACAATAGGTTGGGTAGG	R	
SARS-CoV-2	GACCCTGTGGGTTTTACACTTAA	F	ORF
SARS-CoV-2	AACGATTGTGCATCAGCTGA	R	
SARS-CoV-2	GGGGAACCTCTCCTGCTAGAAT	F	N
SARS-CoV-2	CAGACATTTTGCTCTCAAGCTG	R	
RPP30	ACCTTGGCTATTCAGTTGTTGC	F	RPP30
RPP30	TGCTCTCAAAACATTGCAGTGA	R	

**Abbreviations:** F, forward; F/R= forward/reverse; R, reverse; SARS-CoV-2, severe acute respiratory syndrome coronavirus 2.

**Table 3** mNGS and Confirmative qPCR Results

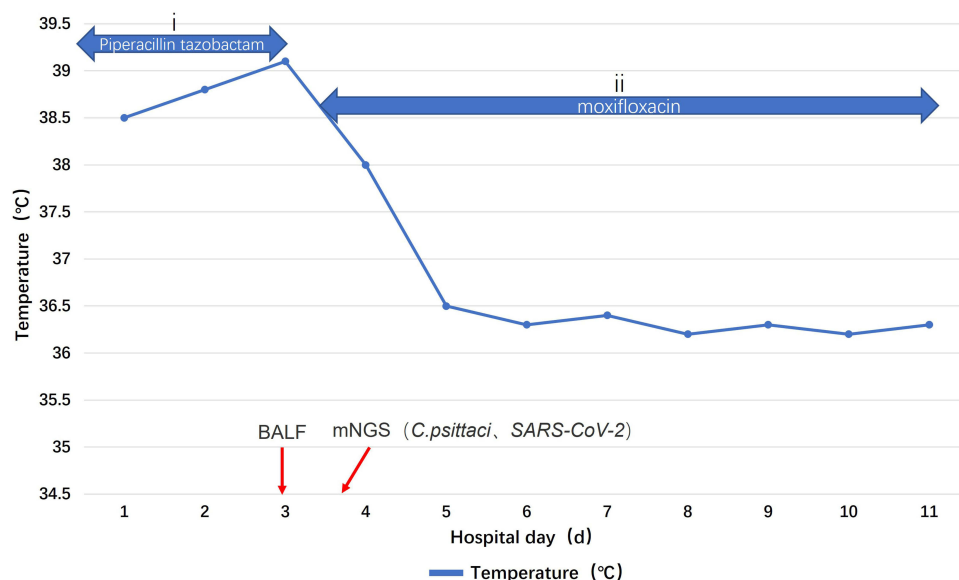
Sample type	Number of DNA reads with <i>C. psittaci</i> Sequences	Number of RNA Reads with SARS-CoV-2 Omicron XBB.1 Sequences	Number of Reads with Other Pathogen Sequences	<i>C. psittaci</i> Ct on qPCR	SARS-CoV-2 Ct on qPCR
BALF	874	1,847,027	Human alphaherpesvirus 1 (reads 46)	24.59	38.57
Blood	2	/	Human alphaherpesvirus 1 (reads 1)	/	/
Nasopharyngeal swab	4	224,671	Human alphaherpesvirus 1 (reads 25)	/	31.07

**Abbreviations:** Ct, cycle threshold; qPCR, quantitative polymerase chain reaction; SARS-CoV-2, severe acute respiratory syndrome coronavirus 2.

Based on these findings, the patient was diagnosed with psittacosis and SARS-CoV-2 coinfection. The antibiotic therapy was switched to intravenous moxifloxacin (MXF) (400 mg daily), and 2 days later, the fever resolved (Figure 3). The patient did not require specific treatment for SARS-CoV-2 infection. Repeat chest CT 1 week after starting MXF showed a reduction in the size of the lung lesions (Figure 1). As she was clinically stable, she was discharged with a prescription for oral MXF (400 mg daily). At a follow-up visit 1 week after discharge, she had almost fully recovered clinically. Follow-up chest CT showed a marked reduction in the size of the lung lesions (Figure 1), and SARS-CoV-2 nucleic acid testing of an NPS was negative.

## Discussion

Psittacosis in humans primarily presents as a respiratory tract infection; however, it may also lead to systemic infections.<sup>9</sup> The lungs are particularly susceptible to *C. psittaci* infection,<sup>10</sup> and *C. psittaci* can be detected in both the upper and lower respiratory tracts of patients infected with *C. psittaci*. In a recent large-scale retrospective study, qPCR detected *C. psittaci* in samples from the upper and lower respiratory tracts and fecal samples. The detection rate of *C. psittaci* in the lower respiratory tract was significantly higher than that in the upper respiratory tract; however, specimens were more readily collected from the upper respiratory tract than from the lower respiratory tract.<sup>11</sup> In the current case, *C. psittaci* was detected in the upper and lower respiratory tracts and the blood specimen using mNGS. The *C. psittaci* sequence number was highest in the BALF specimen and was low in the NPS and blood specimens. Hence, BALF should be the preferred specimen for detecting *C. psittaci* using mNGS.<sup>12</sup>



**Figure 3** The patient's clinical course and treatment. Body temperature alterations and antibacterial therapy, (i) 4.5 g piperacillin-tazobactam administered as an intravenous bolus every 8 hours on days 1–3 and (ii) 0.4 g of moxifloxacin administered as an intravenous bolus once daily on days 4–11.

**Abbreviations:** BALF, Bronchoalveolar Lavage Fluid; mNGS, Metagenomic Next-Generation Sequencing; SARS-CoV, Severe Acute Respiratory Syndrome Coronavirus.



The accurate diagnosis of *C. psittaci* infection poses a challenge. Commonly employed methods include serological testing, in vitro culture, qPCR, and mNGS. Serological tests are prone to inaccuracies and may produce false-positive results,<sup>13</sup> whereas in vitro cultures are challenging due to stringent criteria. Furthermore, although qPCR is specific, it is limited to suspected cases and cannot diagnose coinfections. Contrastingly, mNGS, which is superior to PCR, aids in diagnosing psittacosis and coinfections;<sup>14,15</sup> it can detect *C. psittaci* in blood, NPS, BALF, and cerebrospinal fluid specimens. Because *C. psittaci* does not colonize the human body, *C. psittaci* infection should be diagnosed if *C. psittaci* sequences are detected in upper or lower respiratory tract specimens or other non-respiratory tract specimens. As mNGS can accurately and rapidly identify pathogens, it is useful for diagnosing *C. psittaci* infection, and promptly adjusting the antibiotic regimen following diagnosis can contribute to a favorable prognosis. In this case, the patient experienced recurrent pyrexia 3 days after treatment with piperacillin combined with tazobactam; therefore, mNGS was used to confirm the diagnosis. After mNGS detected *C. psittaci* in the BALF specimen, the antibiotic was changed to MFX, which is a more effective treatment. The patient's temperature normalized, preventing progression to critical illness.<sup>16</sup>

Viral infections can compromise host immunity, facilitating the progression of viral and bacterial coinfections.<sup>17,18</sup> *C. psittaci*, *Legionella pneumophila*, *Streptococcus pneumoniae*, and *Mycoplasma pneumoniae* have been identified as bacterial pathogens with SARS-CoV-2 coinfection.<sup>19</sup> Studies indicate two mechanisms of action in viral and bacterial coinfections: (i) direct interactions, where viruses exploit bacterial components, and (ii) indirect interactions, where bacteria exploit viral infections. These interactions involve complex regulatory mechanisms, such as cell receptor upregulation, epithelial layer damage, symbiotic bacterial turnover, and immune system suppression, leading to further damage to the host.<sup>20</sup> Elevated erythrocyte sedimentation rate and CRP levels are common laboratory parameters for diagnosing psittacosis.<sup>21</sup> In this case, the increased WBC and neutrophil counts and elevated CRP levels indicated that the patient may have been infected with *C. psittaci* on admission. However, it is unknown which infection occurred first in this case.

Both SARS-CoV-2 and *C. psittaci* cause pneumonia. Distinguishing SARS-CoV-2 infection from *C. psittaci* infection is challenging.<sup>22,23</sup> In this case, Omicron XBB.1 and *C. psittaci* were detected in BALF and NPS specimens. Chest CT revealed massive consolidation in the left lower lung field and left-sided pleural effusion. Patients with psittacosis typically show varying degrees of effusion and consolidation, including patchy shadows.

Patients with severe psittacosis may present with lobar shadows, extensive double pneumonia, and sometimes, pleural effusion, and chest lesions usually resolve within 2–4 weeks of initiating pharmacotherapy.<sup>24–26</sup> In this case, SARS-CoV-2 was detected in BALF, blood, and NPS specimens using mNGS. Therefore, the patient was diagnosed with *C. psittaci* and SARS-CoV-2 coinfection. *C. psittaci* and SARS-CoV-2 (Omicron XBB.1) were detected in the BALF specimen from the left lower lung. The NPS specimen showed the same variant as that in the lung.

Common chest imaging findings for SARS-CoV-2 include ground-glass opacity and multifocal consolidation, with pleural effusion (6%) being uncommon.<sup>27</sup> The imaging findings in this patient were atypical. The Omicron XBB.1 variant causes less severe disease than other SARS-CoV-2 variants do.<sup>28,29</sup>

In this case, piperacillin combined with tazobactam was initially administered; however, *C. psittaci* is not sensitive to these antibiotics. After detecting *C. psittaci* in the BALF, the antibiotic therapy was changed to MFX, leading to recovery. Quinolones are first-line antibiotics for community-acquired pneumonia, covering atypical pathogens such as *C. psittaci* and *Mycoplasma pneumoniae*, and MFX should be administered empirically in cases of suspected psittacosis.<sup>4</sup> The recommended first-line treatment for psittacosis is doxycycline rather than quinolones<sup>30</sup> because quinolones have lower intracellular activity against *C. psittaci* than tetracycline does. In this case, the patient was treated with MFX instead of tetracycline because our hospital did not have doxycycline.

This case report compared mNGS with qPCR for testing BALF, blood, and NPS specimens in a patient with *C. psittaci* and SARS-CoV-2 coinfection and highlights the utility of mNGS in patients with pneumonia of unknown cause that is unresponsive to antibiotics and is diagnosing coinfections with more than one pathogen.

This study has one limitation. The clinical characteristics features of this case of *C. psittaci* and SARS-CoV-2 coinfection are derived from this specific patient; therefore, the findings may not be generalizable.

## Data Sharing Statement

All relevant data are provided within the manuscript. All information in the article has been anonymized.

## Ethics Approval and Informed Consent

The Ethics Committees of Zhongshan People's Hospital (K2021-137) approved this study. Informed consents were obtained from the patient. Zhongshan People's Hospital granted approval to publish the case details.

## Consent for Publication

The patient has provided informed consent for the publication of her case details and the associated images.

## Funding

This work was supported by the Science and Technology Plan Project of Zhongshan under grant number 2020B1113.

## Disclosure

The authors report no conflicts of interest in this work.

## References

1. Hogerwerf L, Gier DE, Baan B, et al. *Chlamydia psittaci* (psittacosis) as a cause of community-acquired pneumonia: a systematic review and meta-analysis. *Epidemiol Infect.* 2017;145(15):3096–3105. doi:10.1017/S0950268817002060
2. Nieuwenhuizen AA, Dijkstra F, Notermans DW, et al. Laboratory methods for case finding in human psittacosis outbreaks: a systematic review. *BMC Infect Dis.* 2018;18(1):442. doi:10.1186/s12879-018-3317-0
3. Zhang A, Xia X, Yuan X, et al. Severe *Chlamydia psittaci* pneumonia complicated by rhabdomyolysis: a case series. *Infect Drug Resist.* 2022;15:873–881. doi:10.2147/IDR.S355024
4. Zhang A, Xia X, Yuan X, et al. Clinical characteristics of 14 cases of severe *Chlamydia psittaci* pneumonia diagnosed by metagenomic next-generation sequencing: a case series. *Med Baltim.* 2022;101(24):e29238. doi:10.1097/MD.00000000000029238
5. Li N, Li S, Tan W, et al. Metagenomic next-generation sequencing in the family outbreak of psittacosis: the first reported family outbreak of psittacosis in China under COVID-19. *Emerg Microbes Infect.* 2021;10(1):1418–1428. doi:10.1080/22221751.2021.1948358
6. Lei JH, Xu Y, Jiang YF, et al. Clustering cases of *Chlamydia psittaci* pneumonia in coronavirus disease 2019 screening ward staff. *Clin Infect Dis.* 2021;73(9):e3261–e3265. doi:10.1093/cid/ciaa1681
7. Han L, Sun LX, Chen YL, et al. Clinical characteristics of a case of severe pneumonia caused by coinfection of COVID-19 and *Chlamydia psittaci*. *Zhonghua Jie He He Hu Xi Za Zhi.* 2023;46(11):1118–1120. Chinese. doi:10.3760/cma.j.cn112147-20230906-00143
8. Liang Y, Dong T, Li M, et al. Clinical diagnosis and etiology of patients with *Chlamydia psittaci* pneumonia based on metagenomic next-generation sequencing. *Front Cell Infect Microbiol.* 2022;12:1006117. doi:10.3389/fcimb.2022.1006117
9. Čechová L, Halánová M, Babinská I, et al. Chlamydiosis in farmed chickens in Slovakia and zoonotic risk for humans. *Ann Agric Environ Med.* 2018;25(2):320–325. doi:10.26444/aaem/82948
10. Gu L, Liu W, Ru M, et al. The application of metagenomic next-generation sequencing in diagnosing *Chlamydia psittaci* pneumonia: a report of five cases. *BMC Pulm Med.* 2020;20(1):65. doi:10.1186/s12890-020-1098-x
11. McGovern OL, Kobayashi M, Shaw KA, et al. Use of real-time PCR for *Chlamydia psittaci* detection in human specimens during an outbreak of psittacosis – Georgia and Virginia, 2018. *MMWR Morb Mortal Wkly Rep.* 2021;70(14):505–509. doi:10.15585/mmwr.mm7014a1
12. Wang K, Liu X, Liu H, et al. Metagenomic diagnosis of severe psittacosis using multiple sequencing platforms. *BMC Genomics.* 2021;22(1):406. doi:10.1186/s12864-021-07725-9
13. Stewardson AJ, Grayson ML. Psittacosis. *Infect Dis Clin North Am.* 2010;24(1):7–25. doi:10.1016/j.idc.2009.10.003
14. Duan Z, Gao Y, Liu B, et al. The application value of metagenomic and whole-genome capture next-generation sequencing in the diagnosis and epidemiological analysis of psittacosis. *Front Cell Infect Microbiol.* 2022;12:872899. doi:10.3389/fcimb.2022.872899
15. Shi Y, Chen J, Shi X, et al. A case of *Chlamydia psittaci* caused severe pneumonia and meningitis diagnosed by metagenome next-generation sequencing and clinical analysis: a case report and literature review. *BMC Infect Dis.* 2021;21(1):621. doi:10.1186/s12879-021-06205-5
16. Raeven VM, Spoorenberg SM, Boersma WG, et al. Atypical aetiology in patients hospitalised with community-acquired pneumonia is associated with age, gender and season; a data-analysis on four Dutch cohorts. *BMC Infect Dis.* 2016;16:299. doi:10.1186/s12879-016-1641-9
17. Morris DE, Cleary DW, Clarke SC. Secondary bacterial infections associated with influenza pandemics. *Front Microbiol.* 2017;8:1041. doi:10.3389/fmicb.2017.01041
18. Public Health Agency of Canada. A tool for the potential fall 2009 wave of pandemic H1N1 to guide public health decision-making: an overview of the public health agency of Canada's planning considerations, September 2009. *Can Commun Dis Rep.* 2010;36(S3):1–20. doi:10.14745/ccdr.v36i00as3
19. Li H, Chen K, Liu M, et al. The profile of peripheral blood lymphocyte subsets and serum cytokines in children with 2019 novel coronavirus pneumonia. *J Infect.* 2020;81(1):115–120. doi:10.1016/j.jinf.2020.04.001
20. Bosch AA, Biesbroek G, Trzcinski K, et al. Viral and bacterial interactions in the upper respiratory tract. *PLOS Pathog.* 2013;9(1):e1003057. doi:10.1371/journal.ppat.1003057
21. Khadka S, Timilsina B, Pangeni RP, et al. Importance of clinical history in the diagnosis of psittacosis: a case report. *Ann Med Surg Lond.* 2022;82:104695. doi:10.1016/j.amsu.2022.104695
22. Frutos MC, Origlia J, Gallo Vaulet ML, et al. SARS-CoV-2 and Chlamydia pneumoniae co-infection: a review of the literature. *Rev Argent Microbiol.* 2022;54(3):247–257. doi:10.1016/j.ram.2022.05.009
23. Laine C, Cotton D. Current clinical challenges in the prevention and management of COVID-19. *Ann Intern Med.* 2022;175(10):1475. doi:10.7326/M22-2684

24. Branley JM, Weston KM, England J, et al. Clinical features of endemic community-acquired psittacosis. *New Microbes New Infect.* **2014**;2(1):7–12. doi:10.1002/2052-2975.29
25. Balsamo G, Maxted AM, Midla JW, et al. Compendium of measures to control *Chlamydia psittaci* infection among humans (psittacosis) and pet birds (avian chlamydiosis), 2017. *J Avian Med Surg.* **2017**;31(3):262–282. doi:10.1647/217-265
26. Rybarczyk J, Verstele C, Lernout T, et al. Human psittacosis: a review with emphasis on surveillance in Belgium. *Acta Clin Belg.* **2020**;75(1):42–48. doi:10.1080/17843286.2019.1590889
27. Jeong YJ, Wi YM, Park H, et al. Current and emerging knowledge in COVID-19. *Radiology.* **2023**;306(2):e222462. doi:10.1148/radiol.222462
28. Lewnard JA, Hong VX, Patel MM, et al. Clinical outcomes associated with SARS-CoV-2 Omicron (B.1.1.529) variant and BA.1/BA.1.1 or BA.2 subvariant infection in Southern California. *Nat Med.* **2022**;28(9):1933–1943. doi:10.1038/s41591-022-01887-z
29. Wolter N, Jassat W, von Gottberg A, et al.; DATCOV-Gen author group. Clinical severity of omicron lineage BA.2 infection compared with BA.1 infection in South Africa. *Lancet.* **2022**;400(10346):93–96. doi:10.1016/S0140-6736(22)00981-3
30. Mandell LA, Wunderink RG, Anzueto A, et al. Infectious Diseases Society of America/American Thoracic Society consensus guidelines on the management of community-acquired pneumonia in adults. *Clin Infect Dis.* **2007**;44(suppl 2):S27–S72. doi:10.1086/511159

### International Medical Case Reports Journal

Dovepress

### Publish your work in this journal

The International Medical Case Reports Journal is an international, peer-reviewed open-access journal publishing original case reports from all medical specialties. Previously unpublished medical posters are also accepted relating to any area of clinical or preclinical science. Submissions should not normally exceed 2,000 words or 4 published pages including figures, diagrams and references. The manuscript management system is completely online and includes a very quick and fair peer-review system, which is all easy to use. Visit <http://www.dovepress.com/testimonials.php> to read real quotes from published authors.

Submit your manuscript here: <https://www.dovepress.com/international-medical-case-reports-journal-journal>