


# Diabetic Retinopathy Screening Using Non-Mydriatic Fundus Camera in Primary Health Care Settings – A Multicenter Study from Saudi Arabia

Khalid Mohammad Alabdulwahhab 

Department of Ophthalmology, College of Medicine, Majmaah University, Majmaah, Kingdom of Saudi Arabia

Correspondence: Khalid Mohammad Alabdulwahhab, Department of Ophthalmology, College of Medicine, Majmaah University, Majmaah, Kingdom of Saudi Arabia, Email [k.alabdulwahhab@mu.edu.sa](mailto:k.alabdulwahhab@mu.edu.sa)

**Background:** Screening of diabetic retinopathy (DR) using the current digital imaging facilities in a primary health care setting is still in its early stages in Saudi Arabia. This study aims to reduce the risk of vision impairment and blindness among known diabetic people through early identification by general practitioners (GP) in a primary health care setting in Saudi Arabia. The objective of this study was to evaluate the accuracy of diabetic retinopathy (DR) detection by general practitioners (GPs) by comparing the agreement of DR assessment between GPs and ophthalmologists' assessment as a gold standard.

**Methods:** A hospital-based, six-month cross-sectional study was conducted, and the participants were type 2 diabetic adults from the diabetic registries of seven rural PHCs, in Saudi Arabia. After medical examination, the participants were then evaluated by fundus photography using a non-mydratic fundus camera without medication for mydriasis. Presence or absence of DR was graded by the trained GPs in the PHCs and then compared with the grading of an ophthalmologist which was taken as a reference or a gold standard.

**Results:** A total of 899 diabetic patients were included, and the mean age of the patients was  $64.89 \pm 11.01$  years. The evaluation by the GPs had a sensitivity of 80.69 [95% CI 74.8–85.4]; specificity of 92.23 [88.7–96.3]; positive predictive value, 74.1 [70.4–77.0]; negative predictive value, 73.34 [70.6–77.9]; and an accuracy of 84.57 [81.8–89.88]. For the consensus of agreement the adjusted kappa coefficient was from 0.74 to 0.92 for the DR.

**Conclusion:** This study demonstrates that trained GPs in rural health centers are able to provide reliable detection results of DR from fundus photographs. The study highlights the need for early DR screening programs in the rural areas of Saudi Arabia to facilitate early identification of the condition and to lessen impact of blindness due to diabetes.

**Keywords:** diabetic retinopathy, rural health, primary health care, diabetes mellitus, non mydratic camera, retinal imaging, fundus photography, primary health care, diabetes, family health, ophthalmology, prevention, screening

## Background

Vision impairment among adults from undiagnosed diabetic retinopathy (DR) affects one in every three diabetic persons.<sup>1</sup> Early detection, treatment, and management by diabetic screening has been reported to prevent visual loss in up to 95% of cases.<sup>1–3</sup> According to the current report of the World Health Organization (WHO) for the rate of diabetes, Saudi Arabia holds the second highest rank in the Middle East, and seventh in the world.<sup>4</sup> An estimated 7 million of the population in Saudi Arabia are known to be diabetic, and around 3 million have pre-diabetes.<sup>5</sup> This increasing pattern of the prevalence of the condition makes the affected population vulnerable to diabetes-related complications, including blindness.

Although different types of screening for DR based on retinal photography have been proposed by many studies,<sup>6,7</sup> the most convenient and accessible is the single-field fundus photography using a non-mydratic camera and is the most common method for DR screening.<sup>8–10</sup> Non-physicians, family physicians, trained in digital fundus imaging for DR screening have been reported to have a sensitivity of 61% to 90%, and a high specificity of 85% to 97%, comparable to that of an ophthalmologist's examination.<sup>11–15</sup>

Currently, the accepted practice for the diabetic eye screening in Saudi Arabia is through a visit to an ophthalmologist where single field digital fundus images are acquired and read, leading to decisions of referral and treatments.<sup>16</sup> Very few consultation clinics for glaucoma and diabetic retinopathy treatment have been launched in Saudi Arabia for this purpose.<sup>17</sup> In the rural PHCs the availability of DR screening would be economic for patients with limited access to a specialist clinic for the same purpose.

Many studies assess the knowledge about and preferences regarding DR<sup>18–22</sup> in Saudi Arabia, but, to date, the performance of GPs for DR detection from digital fundus images has never been directly compared with that of ophthalmologists. Such studies can expose the need and suitability of an early DR screening program in the rural as well as urban primary health care facilities in Saudi Arabia. This study is explicit in its purpose to investigate the use DR screening by trained GPs in all PHCs across Saudi Arabia, as an alternative to a visit to a specialist center for the same. The present study has thus a clear objective to identify the accuracy of detecting diabetic retinopathy (DR) by general practitioners (GPs) by comparing the agreement of DR assessment between GPs and ophthalmologists in Saudi primary health care (PHC) settings.

## Methods

A hospital-based, cross-sectional study of DR assessment from retinal images using a single field non-mydratic camera taken from seven rural primary health care centers of Saudi Arabia was performed. The Institutional Research Board (IRB) at Majmaah University, Saudi Arabia (MRIEC07/BHSRC1084) approved this study, and this study adhered to the guidelines of the Declaration of Helsinki.

## Patient Sample

The participants were adult patients with diabetes registered at the seven selected primary health care centers in Saudi Arabia, who were screened under this study in January 2022 to June 2022.

The sample was recruited using a convenience strategy from the pool of patients enrolled in the diabetes registries of the PHCs.

The inclusion criterion for participants were definitive diagnosed cases of type 2 diabetes mellitus patients presenting to the PHC between January 2022 and June 2022. The exclusion criteria were the presence of other visual defects, and unwillingness to participate in the study. Patients with type 1 diabetes were not included because of its low prevalence in the primary care. Informed consents were obtained from participants after informing them about the study procedure and any consequences involved. The participant's age, gender, blood pressure, blood glucose levels, HbA1c, duration of diabetes were registered into a tailor-made spread sheet.

A total of seven GPs participated in this study from seven selected PHCs, and they were trained in person in their PHC, to identify presence or absence of DR using these images according to Saudi Diabetes Clinical Practice Guidelines (SDCPG).<sup>23</sup> Dilation of pupil was deemed not necessary as this study was a non-mydratic approach to take the fundus photographs. A non-mydratic 45 degree digital retinal TRC-NW8 fundus camera (TopCon Medical Systems Tokyo, Japan) was used to acquire bilateral single field retinal digital photographs centered on the macula and encompassing the optic disc.

The GPs graded all the digital retinal images taken, and a pre-designed spread sheet was filled following their assessment outcomes. These digital photographs were then cloud saved and were read in a masked form by an ophthalmologist of the King Khalid hospital at Majmaah, Saudi Arabia. The GPs were not informed about the results of the comparison assessment of their grading to those of the ophthalmologist.

The presence or absence of DR based on the standard definitions and clinical guidelines<sup>24,25</sup> was used for achieving the first objective of this study. “No” equal to “absent DR” was given to the identification of isolated microaneurysms (MAs) or questionable MAs. “Yes” equal to “presence of DR” was marked for MAs, retinal hemorrhages, hard exudates, cotton wool spots, and neovascularization.<sup>26,27</sup> The GPs and the ophthalmologist were allowed to label images as gradable or ungradable, based on their judgement. The patients identified with a definite DR diagnosis were referred for further investigations and treatments. The GPs were not asked to categorize the DR into different types or to categorize

according to severity of the condition. The ophthalmologist's evaluation was used to construct a gold standard only for the identification of the DR from the fundus photographs.

The clinical and laboratory characteristics of the participants were described using descriptive statistics using means and standard deviations for normally distributed variables and medians and quartiles for nonparametric variables. Q-Q plot, Shapiro–Wilk, and Kolmogorov–Smirnov tests were employed to evaluate these variables.

The inter-rater agreement was assessed using the adjusted kappa statistic, and a kappa ( $\kappa$ ) value between 0.81 and 1.00 was accepted as a perfect agreement.<sup>28</sup> Prevalence of DR was established by the ophthalmologist with 772 (42.94%) patients and an average for the GPs as seen in Table 1. Adjusted kappa coefficients for prevalence was used for analyzing the agreement of the accuracy in the diagnostic performance of GPs using WINPEPI environment. Sensitivity, specificity, positive predictive value, negative predictive value, and the accuracy of GPs were calculated by comparison to the ophthalmologist's ratings (gold standard). Positive and negative agreement between GP and ophthalmologist's ratings were calculated. All statistics were performed using Stata version 16.1 (StataCorp, TX, USA).

## Result

A total of 1828 digital retinal images were obtained, from 914 patients. Missing patient data like lack of consent ( $n=8$ ), did not attend imaging ( $n=18$ ), and fundus photos of eyes with advanced media opacity ( $n=1$ ) or insufficient pupil size ( $n=3$ ) led to discarding of 30 images, and thus only 1798 fundus images from 899 patients were retained to be assessed by the GPs and the ophthalmologist. All the 7 GPs assessed DR in roughly the same number of eyes, respectively. Table 2 features demographic,

**Table 1** Diabetic Retinopathy Prevalence in the Study Population

	Gold Standard*	GP1	GP2	GP3	GP4	GP5	GP6	GP7
Diabetic retinopathy present, $n$ (%)	772 (42.94%)	750 (41.32%)	743 (38.77%)	697 (38.77%)	759 (42.21%)	707 (39.32%)	768 (42.71%)	770 (42.83%)
Kappa [95% CI]	0.8 [0.78–0.83]	0.73 [0.66–0.8]	0.88 [0.8–0.96]	0.78 [0.73–0.7]	0.77 [0.75–0.8]	0.71 [0.64–0.78]	0.82 [0.79–0.86]	0.74 [0.71–0.79]

**Note:** \*Ophthalmologist.

**Abbreviation:** GP, general practitioner.

**Table 2** Demographic, Clinical, and Laboratory Characteristics of the Participants Classified by Diabetic Retinopathy Status

Characteristic	Overall Number of Participants	Retinopathy Present	P-value*
$N$ (%)	899	386 (43%)	
Age in years, mean $\pm$ SD	64.89 $\pm$ 11.01	68.33 $\pm$ 11.93	0.079
Male, $n$ (%)	552 (61.40%)	402 (44.7%)	0.081
Female, $n$ (%)	347 (38.60%)	370 (41.5%)	0.157
Diabetes duration in years, mean $\pm$ SD	9.9 $\pm$ 8.1	303 (204–67)	0.07
Hemoglobin A1C % $<6.5\%$ , $n$ (%)	392 (43.6%)	384 (42.71%)	0.001
<b>Blood pressure status, <math>n</math> (%)</b>			
Normotensive	198 (22%)	2 (1.01%)	0.075
Controlled hypertension	569 (63.29%)	130 (14.46%)	0.137
Uncontrolled hypertension	132 (14.68%)	101 (11.23%)	0.07

**Notes:** Data are presented as number (%), or mean  $\pm$  standard deviation. \*P-value for differences between diabetic retinopathy and not diabetic with  $p < 0.05$  is statistically significant.

**Abbreviation:** IQR, interquartile range.

clinical, and laboratory characteristics of the participants classified by diabetic retinopathy status. The mean age  $\pm$  standard deviation of the study population was  $64.89 \pm 11.01$  years, and all the participants were of Saudi origin.

The sample was overwhelmingly hypertensive 701 (77.97%) (including the controlled and the non-controlled), and the glycated hemoglobin levels were  $<6.5\%$  in 392 (43.6%) of participants. The overall prevalence of DR according to the gold standard was 772 (42.94%) and an average by the GPs was 745 (41.48%). Table 1 summarizes this prevalence observation comparison between the ophthalmologist and the GPs.

Table 3 is descriptive of the performance of general practitioners (GPs) and the ophthalmologist for screening of diabetic retinopathy (DR). The average sensitivity of GPs to evaluate DR was 80.69 [74.8–85.4]; specificity, 92.23 [88.7–96.3]; positive predictive value, 74.1 [70.4–77.0]; negative predictive value, 73.34 [70.6–77.9]; and accuracy, 84.57 [81.8–89.88]. As described in Table 4, agreement between the gold standard and the GPs, calculated using the adjusted kappa coefficient, ranged from 0.74 to 0.92 for DR, and the percent agreement ranged from 79.3% to 98.3.9% for DR.

As the kappa statistics range represents 0 as random agreement and 1 as perfect agreement, the cutoffs for classification used in this study were 0.6–0.8 for good agreement, and 0.8–1 for very good agreement. The coefficients were thus adjusted for prevalence in the sample of this study. The percentage of agreement of the GPs compared with the

**Table 3** Performance of General Practitioners (GP) and Ophthalmologists (Gold Standard) for Screening of Diabetic Retinopathy (DR)

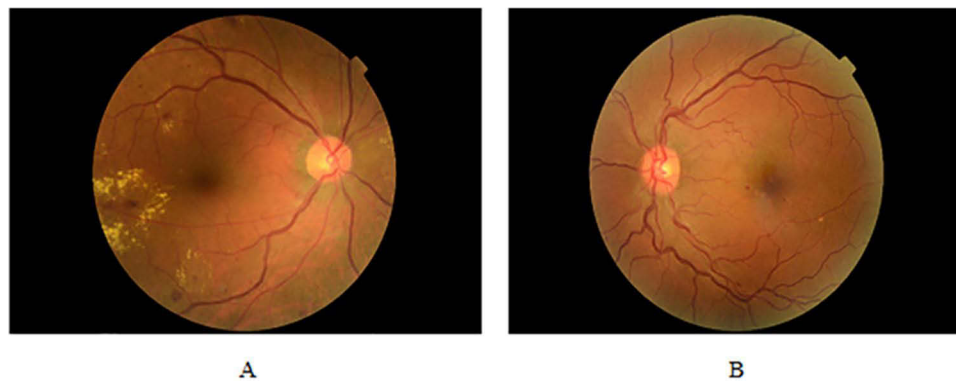
	Sensitivity [95% CI]	Specificity [95% CI]	Positive Predictive Value (PPV) [95% CI]	Negative Predictive Value (NPV) [95% CI]	Accuracy (%)	Positive Agreement (%)	Negative Agreement (%)
GP1	91.6 [90.7–99.3]	89.3 [82.6–91.1]	78.9 [76.1–83.6]	68.1 [66.2–73.1]	84.9	73.1	71.5
GP2	92.6 [88.1–95.8]	91.2 [89.8–96.4]	67 [65.9–73.5]	76.1 [70.8–80.9]	91.2	90.2	72.4
GP3	66.2 [63.2–75.9]	95.7 [92.3–99.7]	75.1 [74.3–83.1]	79.3 [76.9–82.2]	91.1	82.2	68.8
GP4	80 [78.7–86.9]	92.1 [89.7–95.2]	71 [69.8–72.7]	69.4 [66.4–71.3]	89.6	92.1	66.1
GP5	75.4 [71.4–82.8]	93.1 [89.2–98.5]	73.1 [89.9–76.3]	70.8 [69.4–73.1]	69.4	73.1	79.1
GP6	84.2 [81.1–89.1]	91.6 [88.7–95.7]	78.1 [71.3–84.2]	80.7 [77.2–84.5]	77.2	84.5	83.5
GP7	94.8 [91.5–99.2]	92.6 [88.4–94.1]	75.5 [72.1–82.7]	69 [65.9–74.3]	88.6	74.3	89.5
Average	80.69 [74.8–85.4]	92.23 [88.7–96.3]	74.10 [70.4–79.0]	73.34 [70.6–77.9]	84.57 [81.8–89.88]	81.36	75.84

Abbreviation: GP, general practitioner.

**Table 4** Evaluation of Agreement in Diabetic Retinopathy (DR) Between General Practitioners (GP) and Ophthalmologists

	Percent Agreement %	Concordance Measures	
		Kappa	Adjusted Kappa
GP1	85.6	0.67 (0.47 to 0.67)	0.82
GP2	79.8	0.55 (0.38 to 0.57)	0.78
GP3	79.3	0.37 (0.26 to 0.48)	0.74
GP4	90.8	0.067 (–0.12 to 0.25)	0.88
GP5	93.9	0.48 (0.28 to 0.67)	0.92
GP6	93.8	0.12 (–0.12 to 0.37)	0.92
Average	87.2		0.84

Abbreviation: GP, general practitioner.



**Figure 1** Non-mydratic fundus photos used in the study. (A) Positive identification of DR from the multiple hard exudates and aneurysms on the fundus photo of a right eye, by all the GPs. (B) Missed DR identification from the few microaneurysms at the macula and small hard exudates by 4 GPs.

ophthalmologist's ranged from 93.9% to 79.3% for the DR assessment. Along with screening, all the cases of apparent DR both by the GPs and the ophthalmologist were referred by GPs. Figure 1A is a non-mydratic photograph of a right eye; all the seven GPs participating in the study could positively identify the DR from the multiple hard exudates and aneurysms on the fundus photo. Figure 1B is a fundus photo from the current study where 4 GPs missed identifying the DR from the few microaneurysms at the macula and small hard exudates present.

It can be clearly seen from this study that the GPs' assessments of DR from the fundus photographs are notably in agreement with the ophthalmologist's assessment. Thus, this supports and highlights the view that a GP assessment of DR from non-mydratic retinal photographs is reliable and can be promoted as a regular clinical practice in PHCs across Saudi Arabia.

## Discussion

This study demonstrated the agreement of GPs in the assessment of DR from non-mydratic single field fundus photographic images, when compared against a reference from an ophthalmologist. This implies that the assessment by GPs in the DR screening is accurate enough, economic, and a valuable aid in reducing the burden of risk from DR. The prevalence of DR in this study is correlated with the recent study in Majmaah city of Saudi Arabia<sup>29</sup> which was 35.8%.

Studies from other countries have reported the assessment of DR by non-physician graders (NPGs) and para-medical professionals<sup>15,30,31</sup> with the grading of NPGs as quite sensitive. This study, with a higher sample size, has findings that confirm that a trained GP's assessment of DR from the digital images shows considerable consensus with an eye specialist's interpretation. Various studies have been done on DR screening with categorizing its severity along with identifying maculopathy.<sup>32–34</sup> However, limited evidences are available on the reliability of GPs' rating and assessment of DR from the digital retinal photographs. Studies have explored the possibility of severity grading and categorizing of the types of DR from retinal images by family physicians (FPs).<sup>35</sup> It has been reported that FPs have 79% sensitivity for DR assessment, when compared by ophthalmoscopy.<sup>2</sup>

A decreased sensitivity of 85% for DR detection by FPs was observed when compared to retinal specialists' evaluation<sup>36</sup> with single-field non-mydratic digital images. An achievement of reduction in the undiagnosed or misdiagnosed DR has been reported<sup>8</sup> by 24% using ophthalmoscopy and to 8% by digital photography in a tertiary center, when compared with the reference standard of seven-field standard mydratic stereoscopic color photographs. No significant differences were reported in the sensitivity and specificity for DR identification between non-mydratic and mydratic retinal photography.<sup>37</sup> Use of non-mydratic photography relieves patients from the discomfort and limitations of using pharmacological mydriasis.<sup>38</sup> Newer technological innovations like artificial intelligence (AI)-supported features with automated algorithms for DR detection<sup>37–42</sup> have recently been developed and have been shown to achieve promising performance supporting the findings of an ophthalmologist. In near future the PHC-based DR screening can incorporate newer technological innovations, paving the way for a cost-effective early and precise detection of DR.

The GPs in PHC require adequate experience in handling non-mydratic cameras to enhance the image quality and hence the DR assessment outcomes. It can be suggested that the reliability of the DR screening facilities in PHCs can be improved and enhanced through internal auditing in PHCs in order to establish a baseline standard, against which prospective inter-rater assessments and agreements can be established. Training the GPs to grade and acquire digital fundus photographs in PHCs will provide easy data transmission, archiving, and retrieval. The future strategy in health care of Saudi Arabia should focus on the potential of developing and implementing early and economic diagnostic diabetic eye care in PHCs.

## Limitations

This study had some limitations. One was that the GPs in this study did not grade the severity of DR and did not identify maculopathy from the digital retinal images. The requirement of the GPs to be trained demanded further time lapse in the study conduction. The economic benefit of the study needs validation in prospective studies, as it is assumed in this study that a visit to a PHC would be cost-effective for a rural population who have limited access to a full-fledged ophthalmic center.

## Conclusion

The use of a single field non-mydratic camera to acquire images and identify DR at a rural PHC level by GPs is comparable to its use by ophthalmologists. For countries like Saudi Arabia where diabetes mellitus is highly prevalent and is on the rise, this study's findings have broad health policy implications. These pre-assessed and early detected DR can support clinicians who are burdened with increasing clinical workload in planning prompt treatment plans.

## Abbreviations

AI, artificial intelligence; DR, diabetic retinopathy; GP, general practitioners; MA, microaneurysms; NPG, non-physician graders; PHC, primary health care; SDCPG, Saudi Diabetes Clinical Practice Guidelines; WHO, World Health Organization.

## Data Sharing Statement

Any data and materials related to this study are available on a reasonable request.

## Ethical Approval

Received on review and acceptance from the Institutional Research board (IRB) at Majmaah University, Saudi Arabia (MRIEC07/BHSRC1084), and this study adhered to the guidelines of the Declaration of Helsinki.

## Acknowledgments

The author would like to acknowledge the primary health centers in Majmaah and is grateful to King Khalid Hospital for their active participation and helping to conduct this research. The author also extends his appreciation to the Deanship of Scientific Research at Majmaah University for the support provided for this work.

## Funding

No fund or sponsorship in any form was obtained from any organization for carrying out this study.

## Disclosure

The author involved in the current study does not declare any competing conflict of interest.

## References

1. Purola PK, Ojamo MU, Gissler M, Uusitalo HM. Changes in visual impairment due to diabetic retinopathy during 1980–2019 based on nationwide register data. *Diabetes Care*. 2022;45(9):2020–2027. doi:10.2337/dc21-2369
2. Vujosevic S, Aldington SJ, Silva P, et al. Screening for diabetic retinopathy: new perspectives and challenges. *Lancet Diabetes Endocrinol*. 2020;8(4):337–347. doi:10.1016/S2213-8587(19)30411-5
3. Pearce E, Sivaprasad S. A review of advancements and evidence gaps in diabetic retinopathy screening models. *Clin Ophthalmol*. 2020;14:3285. doi:10.2147/OPHT.S267521



4. Morgan SA, Mahmoud Ali M, Amos Channon A, et al. Prevalence and correlates of diabetes and its comorbidities in four gulf cooperation council countries: evidence from the World Health Survey Plus. *J Epidemiol Community Health*. 2019;73(7):630–636. doi:10.1136/jech-2018-211187
5. Robert AA, Al Dawish MA. The worrying trend of diabetes mellitus in Saudi Arabia: an urgent call to action. *Curr Diabetes Rev*. 2020;16(3):204–210. doi:10.2174/18756417OTg2dNzMaTcVY
6. Rajalakshmi R, Prathiba V, Rani PK, Mohan V. Various models for diabetic retinopathy screening that can be applied to India. *Indian J Ophthalmol*. 2021;69(11):2951. doi:10.4103/ijo.IJO\_1145\_21
7. Kárasón KT, Vo D, Grauslund J, Rasmussen ML. Comparison of different methods of retinal imaging for the screening of diabetic retinopathy: a systematic review. *Acta Ophthalmol*. 2022;100(2):127–135. doi:10.1111/aos.14767
8. Hu J, Chen R, Lu Y, et al. Single-field non-mydiatic fundus photography for diabetic retinopathy screening: a systematic review and meta-analysis. *Ophthalmic Res*. 2019;62(2):61–67. doi:10.1159/000499106
9. Fahadullah M, Memon NA, Salim S, et al. Diagnostic accuracy of non-mydiatic fundus camera for screening of diabetic retinopathy: a hospital based observational study in Pakistan. *Innovation*. 2019;69(3):1.
10. Fennner BJ, Wong RL, Lam WC, Tan GS, Cheung G. Advances in retinal imaging and applications in diabetic retinopathy screening: a review. *Ophthalmol Ther*. 2018;7(2):333–346. doi:10.1007/s40123-018-0153-7
11. Cunha LP, Figueiredo EA, Araújo HP, et al. Non-mydiatic fundus retinography in screening for diabetic retinopathy: agreement between family physicians, general ophthalmologists, and a retinal specialist. *Front Endocrinol*. 2018;9:251. doi:10.3389/fendo.2018.00251
12. Piyasena MMPN, Murthy Gudlavalleti VS, Gilbert C, et al. Development and validation of a diabetic retinopathy screening modality using a hand-held nonmydiatic digital retinal camera by physician graders at a tertiary-level medical clinic: protocol for a validation study. *JMIR Res Protoc*. 2018;7(12):e10900. doi:10.2196/10900
13. Srihatrai P, Hlowchitsieng T. The diagnostic accuracy of single-and five-field fundus photography in diabetic retinopathy screening by primary care physicians. *Indian J Ophthalmol*. 2018;66(1):94. doi:10.4103/ijo.IJO\_657\_17
14. Memon MS, Ahsan S, Fahadullah M, Parveen K, Salim S, Fahim MF. Diagnostic accuracy of direct ophthalmoscopy and non-mydiatic retinal photography by trained optometrists for screening of diabetic retinopathy. *Pak J Ophthalmol*. 2020;36(2). doi:10.36351/pjo.v36i2.1015
15. Thapa R, Bajimaya S, Pradhan E, Sharma S, Kshetri B, Paudyal G. Agreement on grading retinal findings of patients with diabetes using fundus photographs by allied medical personnel when compared to an ophthalmologist at a diabetic retinopathy screening program in Nepal. *Clin Ophthalmol*. 2020;14:2731. doi:10.2147/OPTH.S269002
16. Vujosevic S, Limoli C, Luzi L, Nucci P. Digital innovations for retinal care in diabetic retinopathy. *Acta Diabetol*. 2022;59(12):1–10.
17. Abuallut I. Awareness and compliance behavior of diabetic patients for eye care to prevent diabetic retinopathy: the status of Jazan Region, Saudi Arabia. *Middle East J Fam Med*. 2022;20(8):1.
18. Alzahrani SH, Bakarman MA, Alqahtani SM, et al. Awareness of diabetic retinopathy among people with diabetes in Jeddah, Saudi Arabia. *Ther Adv Endocrinol Metab*. 2018;9(4):103–112. doi:10.1177/2042018818758621
19. AlHargan MH, AlBaker KM, AlFadhel AA, AlGhamdi MA, AlMuammar SM, AlDawood HA. Awareness, knowledge, and practices related to diabetic retinopathy among diabetic patients in primary healthcare centers at Riyadh, Saudi Arabia. *J Family Med Prim Care*. 2019;8(2):373. doi:10.4103/jfmpc.jfmpc\_422\_18
20. Fallatah MO. Knowledge, awareness, and eye care-seeking behavior in diabetic retinopathy: a cross-sectional study in Jeddah, Kingdom of Saudi Arabia. *Ophthalmol Ther*. 2018;7(2):377–385. doi:10.1007/s40123-018-0147-5
21. Alswaina NF. Awareness of diabetic retinopathy among patients with type 2 diabetes mellitus in Qassim, Saudi Arabia. *J Family Med Prim Care*. 2021;10(3):1183. doi:10.4103/jfmpc.jfmpc\_2231\_20
22. Alamri A, Al-Jahash NAS, Alsultan MSH, AlQahtani SSA, Saeed YAA, Alhamlan RAO. Awareness, knowledge, and practice regarding to diabetic retinopathy among KCU students besides medical students in Abha, Saudi Arabia. *J Family Med Prim Care*. 2021;10(9):3233. doi:10.4103/jfmpc.jfmpc\_86\_21
23. Alharbi MY, Albunyan A, Al Nahari A, et al. Measuring the impact of flash glucose monitoring in a pediatric population in Saudi Arabia: a retrospective cohort study. *Diabetes Ther*. 2022;13(6):1139–1146.
24. Tang F, Luenam P, Ran AR, et al. Detection of diabetic retinopathy from ultra-widefield scanning laser ophthalmoscope images: a multicenter deep learning analysis. *Ophthalmol Retina*. 2021;5(11):1097–1106. doi:10.1016/j.oret.2021.01.013
25. Teo ZL, Tham YC, Yu M, et al. Global prevalence of diabetic retinopathy and projection of burden through 2045: systematic review and meta-analysis. *Ophthalmology*. 2021;128(11):1580–1591. doi:10.1016/j.ophtha.2021.04.027
26. Antonetti DA, Silva PS, Stitt AW. Current understanding of the molecular and cellular pathology of diabetic retinopathy. *Nat Rev Endocrinol*. 2021;17(4):195–206. doi:10.1038/s41574-020-00451-4
27. Gale MJ, Scruggs BA, Flaxel CJ. Diabetic eye disease: a review of screening and management recommendations. *Clin Experiment Ophthalmol*. 2021;49(2):128–145. doi:10.1111/ceo.13894
28. Jampol LM, Glassman AR, Sun J, Ingelfinger JR. Evaluation and care of patients with diabetic retinopathy. *N Engl J Med*. 2020;382(17):1629–1637. doi:10.1056/NEJMr1909637
29. Alabdulwahhab KM. Prevalence and risk factors of diabetic retinopathy in Saudi Diabetics in Majmaah City. *Aust Med J*. 2016;9(12). doi:10.21767/AMJ.2016.2783
30. Zeune LL, de Wit S, Berghuis AS, IJzerman MJ, Terstappen LW, Brune C. How to agree on a CTC: evaluating the consensus in circulating tumor cell scoring. *Cytometry A*. 2018;93(12):1202–1206. doi:10.1002/cyto.a.23576
31. McKenna M, Chen T, McAneney H, et al. Accuracy of trained rural ophthalmologists versus non-medical image graders in the diagnosis of diabetic retinopathy in rural China. *Br J Ophthalmol*. 2018;102(11):1471–1476. doi:10.1136/bjophthalmol-2018-312440
32. Romero P, Sagarra R, Ferrer J, Fernández-Ballart J, Baget M. The incorporation of family physicians in the assessment of diabetic retinopathy by non-mydiatic fundus camera. *Diabetes Res Clin Pract*. 2010;88(2):184–188. doi:10.1016/j.diabres.2010.02.001
33. Fuller SD, Hu J, Liu JC, et al. Five-year cost-effectiveness modeling of primary care-based, nonmydiatic automated retinal image analysis screening among low-income patients with diabetes. *J Diabetes Sci Technol*. 2022;16(2):415–427. doi:10.1177/1932296820967011
34. Xiao B, Liao Q, Li Y, et al. Validation of handheld fundus camera with mydriasis for retinal imaging of diabetic retinopathy screening in China: a prospective comparison study. *BMJ open*. 2020;10(10):e040196. doi:10.1136/bmjopen-2020-040196

35. Sengupta S, Sindal MD, Baskaran P, Pan U, Venkatesh R. Sensitivity and specificity of smartphone-based retinal imaging for diabetic retinopathy: a comparative study. *Ophthalmol Retina*. 2019;3(2):146–153. doi:10.1016/j.oret.2018.09.016
36. Virk R, Binns AM, Chambers R, Anderson J. How is the risk of being diagnosed with referable diabetic retinopathy affected by failure to attend diabetes eye screening appointments? *Eye*. 2021;35(2):477–483. doi:10.1038/s41433-020-0877-1
37. Zhang Y, Shi J, Peng Y, et al. Artificial intelligence-enabled screening for diabetic retinopathy: a real-world, multicenter and prospective study. *BMJ Open Diabetes Res Care*. 2020;8(1):e001596. doi:10.1136/bmjdr-2020-001596
38. Wu JH, Liu TA, Hsu WT, Ho JHC, Lee CC. Performance and limitation of machine learning algorithms for diabetic retinopathy screening: meta-analysis. *J Med Internet Res*. 2021;23(7):e23863. doi:10.2196/23863
39. Wang YL, Yang JY, Yang JY, Zhao XY, Chen YX, Yu WH. Progress of artificial intelligence in diabetic retinopathy screening. *Diabetes Metab Res Rev*. 2021;37(5):e3414. doi:10.1002/dmrr.3414
40. Zafar S, Mahjoub H, Mehta N, Domalpally A, Channa R. Artificial intelligence algorithms in diabetic retinopathy screening. *Curr Diab Rep*. 2022;1–8. doi:10.1007/s11892-021-01445-w
41. Malerbi FK, Andrade RE, Morales PH, et al. Diabetic retinopathy screening using artificial intelligence and handheld smartphone-based retinal camera. *J Diabetes Sci Technol*. 2022;16(3):716–723. doi:10.1177/1932296820985567
42. Raman R, Dasgupta D, Ramasamy K, George R, Mohan V, Ting D. Using artificial intelligence for diabetic retinopathy screening: policy implications. *Indian J Ophthalmol*. 2021;69(11):2993. doi:10.4103/ijo.IJO\_1420\_21

## International Journal of General Medicine

Dovepress

### Publish your work in this journal

The International Journal of General Medicine is an international, peer-reviewed open-access journal that focuses on general and internal medicine, pathogenesis, epidemiology, diagnosis, monitoring and treatment protocols. The journal is characterized by the rapid reporting of reviews, original research and clinical studies across all disease areas. The manuscript management system is completely online and includes a very quick and fair peer-review system, which is all easy to use. Visit <http://www.dovepress.com/testimonials.php> to read real quotes from published authors.

Submit your manuscript here: <https://www.dovepress.com/international-journal-of-general-medicine-journal>