

# A Case of Critical Japanese Spotted Fever in Zhejiang, China

Yani Zhou<sup>1</sup>, Qi Wang<sup>1</sup>, Yujuan Shen<sup>1</sup>, Bin Shen<sup>1</sup>, Yan Zhang<sup>2</sup>, Weihong Wang<sup>1</sup>, Xiaofeng Li<sup>1,3</sup>

<sup>1</sup>Department of Infectious Diseases, Huzhou Central Hospital, Affiliated Central Hospital Huzhou University, Huzhou, Zhejiang Province, People's Republic of China; <sup>2</sup>Department of Nursing, Huzhou Central Hospital, Affiliated Central Hospital Huzhou University, Huzhou, Zhejiang Province, People's Republic of China; <sup>3</sup>Huzhou Key Laboratory of Precision Medicine Research and Translation for Infectious Diseases, Huzhou, Zhejiang Province, People's Republic of China

Correspondence: Xiaofeng Li, Email [xf\\_li0728@163.com](mailto:xf_li0728@163.com)

**Background:** Japanese spotted fever (JSF) is a rare disease, caused by *Rickettsia japonica*; no case has been reported in Zhejiang Province, China.

**Case Presentation:** An elderly woman presented to the hospital with abdominal pain and fever. Her condition rapidly worsened with severe complications, such as multiple organ failure and central nervous system damage. The presence of *R. japonica* was quickly detected by metagenomic next-generation sequencing. On the basis of combined clinical manifestations and laboratory results, critical JSF was diagnosed and treated with doxycycline. The patient showed good prognosis. Typical symptoms (eschar and rash) were not observed in the early stage, consequently increasing the difficulty of clinical diagnosis.

**Conclusion:** The delay of treatment caused by non-specific symptoms is an important factor affecting the progression of JSF. As an emerging pathogen detection method, mNGS has been successfully applied for disease diagnosis and treatment, and can be an important complement for the diagnosis of this disease.

**Keywords:** Japanese spotted fever, *Rickettsia japonica*, spotted fever group Rickettsia, mNGS, fever, multiple organ failure, central nervous system damage

## Background

Japanese spotted fever (JSF) was first reported in Japan in 1984,<sup>1</sup> and later found in other Asian countries.<sup>2,3</sup> Since the first case in China in 2013, 55 cases have been reported in Henan, Zhejiang, Hubei and Anhui provinces.<sup>4-9</sup> Among which, 16 cases have been recorded in Zhejiang Province. From an epidemiological perspective, JSF is a rare disease in this region.

JSF is a tick-borne disease caused by *Rickettsia japonica*. High fever, erythema, and tick-biting eschar are the main clinical features of JSF. Thrombocytopenia, elevated CRP, and eosinophilia are found in most patients.<sup>10,11</sup> Although this illness is mostly mild, patients with atypical symptoms may experience severe complications, including disseminated intravascular coagulation (DIC), multiple organ failure, acute liver failure, central nervous system disease, hemophagocytic syndrome and acute respiratory distress syndrome, due to delay in diagnosis.<sup>11-15</sup> Therefore, the rapid identification of pathogens is important for JSF.

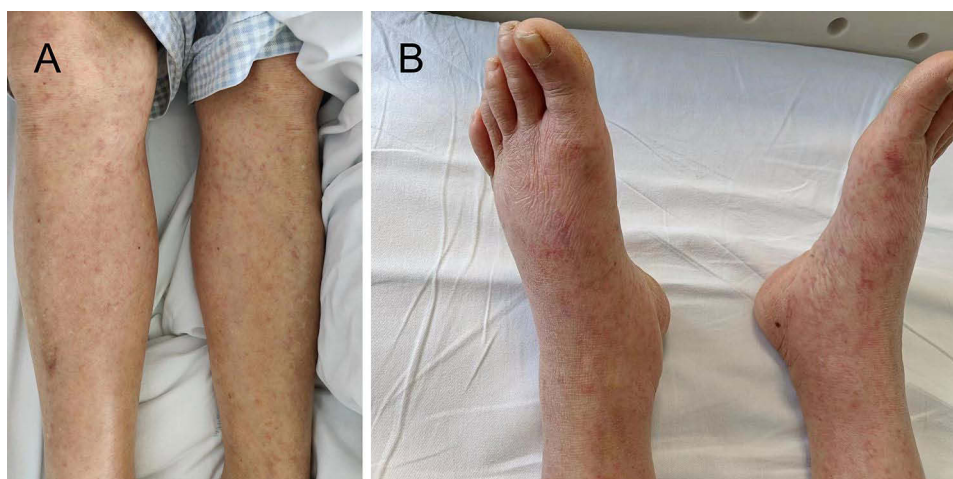Detection methods for *R. japonica* include serological detection techniques, such as Wei-Fei method, immunofluorescence method, indirect immunoperoxidase method, enzyme immunoassay and ELISA,<sup>16</sup> and the widely used quantitative PCR (qPCR) molecular detection.<sup>17,18</sup> Metagenomic next-generation sequencing (mNGS) has proved its potential application in the diagnosis of rickettsial diseases.<sup>19</sup> Owing to its high sensitivity to pathogenic bacteria and less limitation,<sup>20</sup> it has great value in the early diagnosis of rare or even rare diseases. We report the first case of critical JSF with atypical symptoms rapidly diagnosed by mNGS in Zhejiang Province as a reference for clinicians.

## Case Presentation

On May 31, 2022, a 71-year-old woman presented to the surgical department with pain in the right upper abdomen and fever (maximum temperature 39.8°C). She had no other symptoms such as headache and change in bowel habits. The patient lived in the hilly region of Zhejiang Province, China, and had worked in a tea plantation for a long time. Physical examination indicated discomfort with pressure in the right upper abdomen, and Murphy's sign was negative.

Laboratory test results were as follows: high-sensitivity C-reactive protein 61.7mg/L [normal range, <10mg/L], eosinophils  $0.00 \times 10^9/L$  [normal range,  $(0.02-0.52) \times 10^9/L$ ], procalcitonin (PCT) 0.77 ng/mL [normal range, <0.50 ng/mL], lactic acid 1.7 mmol/L [normal range, (0.5–1.6) mmol/L], alanine aminotransferase 48.1 U/L [normal range, (7.0–40.0) U/L], aspartate aminotransferase 65.8 U/L [normal range, (13.0–35.0) U/L], and creatinine 100.5  $\mu\text{mol/L}$  [normal range, (44.0–132.6)  $\mu\text{mol/L}$ ]. Urine occult blood test was positive (2+), and amylase level was normal. Contrast-enhanced abdominal CT showed no abnormalities. Sulperazon (3.0 g twice daily) was administered as anti-infection treatment. After 4 days of treatment, the patient still had recurrent high fever (the highest temperature was 40 °C). A sharp decrease in platelet was detected. The antibiotic was replaced with imipenem to exclude the possibility of drug side effects. Based on the symptoms and auxiliary examinations, the surgeon considered severe infection and transferred the patient to the department of infectious diseases to further clarify the cause.

On day 6, further tests revealed that the platelet count decreased to  $20 \times 10^9/L$  and eosinophil levels continued to decrease to 0. The levels of inflammatory markers (CRP, PCT, IL-6, IL-10, and IFN- $\gamma$ ), liver enzymes, and lactic acid were significantly increased. The coagulation function became abnormal, and even central nervous system symptoms occurred. Physical examination revealed neck rigidity, and the pathological reflex was positive. No wound, rash, or eschar were detected. Cerebrospinal fluid examination and bone puncture results ruled out intracranial infection and hematological diseases, respectively. In addition, epidemic hemorrhagic fever antibody, 3P protamine test, Coombs test, platelet antibody and ADAMTS13 activity test were all negative. Severe fever with thrombocytopenia syndrome virus (SFTSV) was excluded as a cause. Doxycycline (0.2g twice daily) was used for tick-bite-related illness. The patient accepted steroid and gamma globulin for treatment of severe thrombocytopenia. The presence of *R. japonica* was detected by mNGS from the peripheral blood on day 9. A total of 127 sequence readings of *R. japonica* were detected on the MGI-200 platform, accounting for 0.48% of the genome coverage. Finally, the patient was diagnosed with JSF. Rashes developed on the limbs on day 13, but eschar was still not found (Figure 1). The patient completed a 3-week course of doxycycline and exhibited good prognosis (Table 1, Figure 2).



**Figure 1** Erythematous rashes scattered on the legs and feet (A and B).

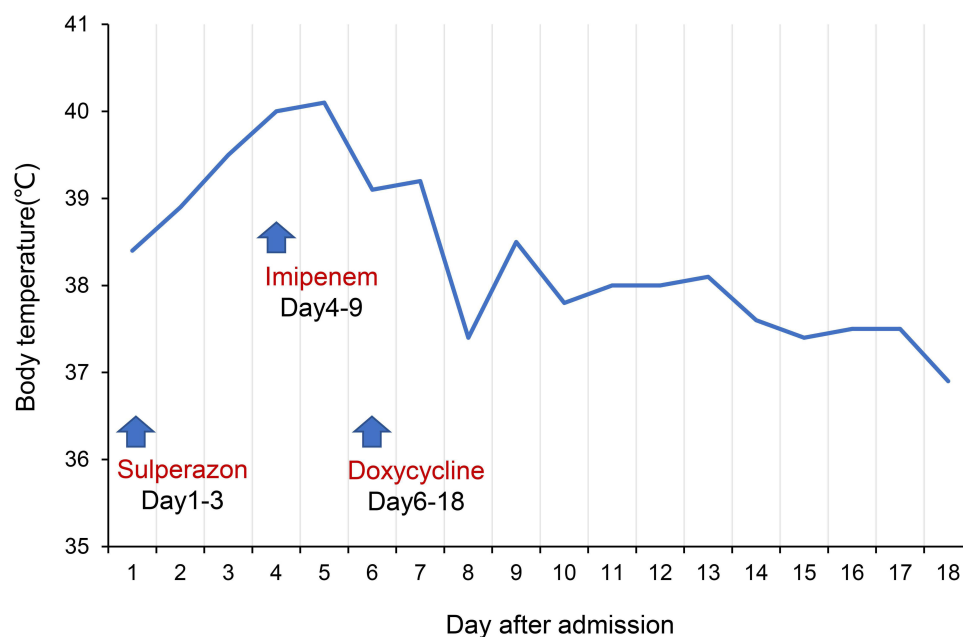
**Table I** Changes in Laboratory Parameters of the Patient

Inspection Items	Day 1	Day 4	Day 6	Day 7	Day 8	Day 12	Day 18	Reference Values
White blood cell count ( $\times 10^9/L$ )	5.3	4.5	9.1	15.0	13.9	9.4	5.0	3.5–9.5
Platelets ( $\times 10^9/L$ )	111.0	46.0	20.0	23.0	35.0	129.0	217.0	125.0–350.0
Haemoglobin (g/L)	109.0	104.0	112.0	118.0	83.0	74.0	91.0	115.0–150.0
C-reactive protein (mg/L)	61.7	110.5	118.9	122.5	64.2	61.2	52.8	<10.0
Eosinophils (%)	0.0	0.0	0.0	0.0	0.0	0.1	0.2	0.4–8.0
Procalcitonin (ng/mL)	0.63	6.73	8.78	5.34	2.96	0.35	0.32	<0.50
Lactic acid (mmol/L)	1.7	2.1	2.2	4.1	3.3	3.2	2.2	0.5–1.6
Albumin (g/L)	37.2	38.4	31.0	23.4	24.8	29.5	37.9	40.0–55.0
Alanine transaminase (U/L)	48.1	54.7	69.9	79.7	61.8	38.3	22.1	7.0–40.0
Aspartate aminotransferase (U/L)	65.8	77.6	110.6	138.7	91.2	65.1	23.8	13.0–35.0
D-dimer (mg/L)	2.08	29.08	36.30	28.55	10.95	1.65	1.30	<0.50

## Discussion

JSF is a potentially fatal disease caused by *R. japonica* infection. We report a case of critical JSF with atypical clinical symptoms, detailing the clinical symptoms, laboratory findings, diagnosis, and treatment. We hope that this case will enhance the sensitivity of practitioners to JSF.

The patient is the first case of critical JSF with atypical symptoms reported in Zhejiang Province, China. Most *R. japonica* infections are mild. When JSF is complicated with DIC, multiple organ failure, acute liver failure, central nervous system disease, hemophagocytic syndrome and acute respiratory distress syndrome, it can be considered as severe. Approximately 18.2% (10/55) critical JSF have occurred in China, including one death case.<sup>7</sup> Hence, this disease



**Figure 2** The curve of body temperature during hospitalization. Doxycycline tablets (0.2g twice daily) were administered from day 6 after admission.

is worthy of attention from clinicians. The singular death was similar to this present case, that is, the patient's early clinical manifestations were high fever and gastrointestinal reactions without rash or eschar. Laboratory tests showed that CRP, PCT, and lactic acid were significantly increased, eosinophils were not detected, and platelet count decreased sharply. No improvement was observed after multiple antibiotic treatments. The disease failed to respond to several antibiotics. Severe sepsis (SOFA score =6) developed after the patient was transferred to the infection ward. The patient had been in critical condition for only 6 days and progressed rapidly. Kodama<sup>11</sup> revealed that delayed treatment (>5 days) is the main reason for the aggravation of JSF. Therefore, early diagnosis and treatment are essential.

In this study, constant 0 level of eosinophils and high levels of lactate, IL-6, IL-10, and IFN- $\gamma$  were detected. Eosinophilia is an independent marker of death in bacteremia<sup>21</sup> and can be used as a sensitive index for the initial diagnosis of JSF.<sup>10</sup> Lactate is an indicator of the severity and outcome of severe infections.<sup>22</sup> In addition, significant increases in IL-6, IL-10, and IFN- $\gamma$  are characteristic of the underlying cytokine release syndrome and can be used as a basis for disease severity in JSF.<sup>23</sup> All the above findings indicated that the disease had a tendency of severe development.

mNGS can be used to simultaneously detect a wide range of pathogens, including viruses, bacteria, fungi, or parasites, by evaluating the unique DNA or RNA sequences of each species. At present, this detection technique is not used as a routine clinical test item, but it is of great value in the early diagnosis of rare and even rare diseases because of its high sensitivity to pathogenic bacteria and small limitation. Previous cases used eschar and blood qPCR to determine *R. japonica* infection and found that fever, eschar, and rash are specific signs of JSF; for most patients, rash and eschar appear 10 days after the onset of the first symptoms, and only about 60% of patients have eschar.<sup>10</sup> Therefore, we have to choose fast and accurate methods for pathogen detection in patients with atypical symptoms to improve the diagnostic rate and reduce the incidence of severe disease. Compared with traditional PCR,<sup>24</sup> mNGS can comprehensively and directly identify pathogens from patient blood samples<sup>25</sup> and save detection time. We have considered the possibility of rickettsial infection on the basis of the epidemiological history, clinical symptoms, signs, and laboratory tests. After SFTSV was excluded, mNGS results further confirmed the clinical diagnosis. In this study, the patient did not have typical symptoms (eschar and rash), and the disease progressed rapidly. Therefore, mNGS can be used as a timely auxiliary diagnostic tool to shorten the window period of disease diagnosis and improve the diagnostic level of *R. japonica* infection. With the wide popularization and decreasing price of mNGS, it exhibits great advantages in the early diagnosis of pathogens.

This report comprises a single case. Owing to the absence of other severe cases in this region, no further analysis of critical JSF was performed. Further development is expected in follow-up studies.

## Conclusions

*R. japonica* infection must be considered in geographic areas with specific tick-borne vectors and in patients showing symptoms such as fever of unknown origin, rash, and thrombocytopenia. mNGS is a promising tool for the diagnosis of *R. japonica* and can improve the rate of disease diagnosis.

## Data Sharing Statement

The original contributions presented in the study are included in the article. Further inquiries can be directed to the corresponding author.

## Ethics Approval and Consent to Participate

Ethics approval or consent to participate was not applicable.

## Consent for Publication

Written informed consent was provided by the patient for the publication of the case details and images. Details of the case can be published without institutional approval.

## Acknowledgments

Many thanks for works by the staffs in the infectious ward from the Huzhou Central Hospital.

## Author Contributions

All authors made a significant contribution to the work reported, whether that is in the conception, study design, execution, acquisition of data, analysis and interpretation, or in all these areas; took part in drafting, revising or critically reviewing the article; gave final approval of the version to be published; have agreed on the journal to which the article has been submitted; and agree to be accountable for all aspects of the work.

## Funding

This work was supported by the Public welfare application research project of Zhejiang Science and Technology Department (No. LGF22H190006).

## Disclosure

The authors declare that no conflicts of interest exist.

## References

1. Mahara F. Japanese spotted fever: report of 31 cases and review of the literature. *Emerg Infect Dis.* 1997;3(2):105–111. doi:10.3201/eid0302.970203
2. Chung MH, Lee SH, Kim MJ, et al. Japanese spotted fever, South Korea. *Emerg Infect Dis.* 2006;12(7):1122–1124. doi:10.3201/eid1207.051372
3. Gaywee J, Sunyakumthorn P, Rodkvamtook W, Ruang-areerate T, Mason CJ, Sirisopana N. Human infection with *Rickettsia* sp. related to *R. japonica*, Thailand. *Emerg Infect Dis.* 2007;13(4):657–659. doi:10.3201/eid1304.060585
4. Lu Q, Yu J, Yu L, et al. *Rickettsia japonica* infections in humans, Zhejiang Province, China, 2015. *Emerg Infect Dis.* 2018;24(11):2077–2079. doi:10.3201/eid2411.170044
5. Gao S, Li L, Zhou X, et al. Fatal *Rickettsia japonica* infection complicating disseminated intravascular coagulation in Yichang, China. *Infect Drug Resist.* 2022;15:6613–6623. doi:10.2147/IDR.S383917
6. Li J, Hu W, Wu T, et al. Japanese spotted fever in Eastern China, 2013. *Emerg Infect Dis.* 2018;24(11):2107–2109. doi:10.3201/eid2411.170264
7. Teng Z, Gong P, Wang W, et al. Clinical forms of Japanese spotted fever from case-series study, Zigui County, Hubei Province, China, 2021. *Emerg Infect Dis.* 2023;29(1):202–206. doi:10.3201/eid2901.220639
8. Li H, Zhang PH, Du J, et al. *Rickettsia japonica* infections in humans, Xinyang, China, 2014–2017. *Emerg Infect Dis.* 2019;25(9):1719–1722. doi:10.3201/eid2509.171421
9. Li W, Liu SN. *Rickettsia japonica* infections in Huanggang, China, in 2021. *IDCases.* 2021;26:e01309. doi:10.1016/j.idcr.2021.e01309
10. Noguchi M, Oshita S, Yamazoe N, Miyazaki M, Takemura YC. Important clinical features of Japanese spotted fever. *Am J Trop Med Hyg.* 2018;99(2):466–469. doi:10.4269/ajtmh.17-0576
11. Kodama K, Senba T, Yamauchi H, Nomura T, Chikahira Y. Clinical study of Japanese spotted fever and its aggravating factors. *J Infect Chemother.* 2003;9(1):83–87. doi:10.1007/s10156-002-0223-5
12. Nakata R, Motomura M, Tokuda M, et al. A case of Japanese spotted fever complicated with central nervous system involvement and multiple organ failure. *Intern Med.* 2012;51(7):783–786. doi:10.2169/internalmedicine.51.6214
13. Kondo M, Kurokawa I, Yamanaka K, Akachi S, Nishii M. Japanese spotted fever with acute hepatic failure: was it associated with Epstein-Barr virus? *Int J Dermatol.* 2010;49(12):1403–1405. doi:10.1111/j.1365-4632.2010.04584.x
14. Kaneko M, Ishimaru N, Nakajima T, Kanzawa Y, Seto H, Kinami S. Japanese Spotted Fever with Hemophagocytic Lymphohistiocytosis. *Intern Med.* 2020;59(3):445–451. doi:10.2169/internalmedicine.3631-19
15. Araki M, Takatsuka K, Kawamura J, Kanno Y. Japanese spotted fever involving the central nervous system: two case reports and a literature review. *J Clin Microbiol.* 2002;40(10):3874–3876. doi:10.1128/JCM.40.10.3874-3876.2002
16. Husin NA, AbuBakar S, Khoo JJ. Current tools for the diagnosis and detection of spotted fever group *Rickettsia*. *Acta Trop.* 2021;218:105887. doi:10.1016/j.actatropica.2021.105887
17. Denison AM, Amin BD, Nicholson WL, Paddock CD. Detection of *Rickettsia rickettsii*, *Rickettsia parkeri*, and *Rickettsia akari* in skin biopsy specimens using a multiplex real-time polymerase chain reaction assay. *Clin Infect Dis.* 2014;59(5):635–642. doi:10.1093/cid/ciu358
18. Madeddu G, Fiore V, Mancini F, et al. Mediterranean spotted fever-like illness in Sardinia, Italy: a clinical and microbiological study. *Infection.* 2016;44(6):733–738. doi:10.1007/s15010-016-0921-z
19. Gu W, Deng X, Lee M, et al. Rapid pathogen detection by metagenomic next-generation sequencing of infected body fluids. *Nat Med.* 2021;27(1):115–124. doi:10.1038/s41591-020-1105-z
20. Huang J, Jiang E, Yang D, et al. Metagenomic next-generation sequencing versus traditional pathogen detection in the diagnosis of peripheral pulmonary infectious lesions. *Infect Drug Resist.* 2020;13:567–576. doi:10.2147/IDR.S235182
21. Terradas R, Grau S, Blanch J, et al. Eosinophil count and neutrophil-lymphocyte count ratio as prognostic markers in patients with bacteremia: a retrospective cohort study. *PLoS One.* 2012;7(8):e42860. doi:10.1371/journal.pone.0042860
22. Liu Z, Meng Z, Li Y, et al. Prognostic accuracy of the serum lactate level, the SOFA score and the qSOFA score for mortality among adults with Sepsis. *Scand J Trauma Resusc Emerg Med.* 2019;27(1):51. doi:10.1186/s13049-019-0609-3

23. Tai K, Iwasaki H, Ikegaya S, et al. Significantly higher cytokine and chemokine levels in patients with Japanese spotted fever than in those with Tsutsugamushi disease. *J Clin Microbiol*. 2014;52(6):1938–1946. doi:10.1128/JCM.03238-13
24. Miao Q, Ma Y, Wang Q, et al. Microbiological diagnostic performance of metagenomic next-generation sequencing when applied to clinical practice. *Clin Infect Dis*. 2018;67(suppl\_2):S231–S240. doi:10.1093/cid/ciy693
25. Graham RMA, Donohue S, McMahon J, Jennison AV. Detection of spotted fever group Rickettsia DNA by deep sequencing. *Emerg Infect Dis*. 2017;1911–1913. doi:10.3201/eid2311.170474

## Infection and Drug Resistance

Dovepress

### Publish your work in this journal

Infection and Drug Resistance is an international, peer-reviewed open-access journal that focuses on the optimal treatment of infection (bacterial, fungal and viral) and the development and institution of preventive strategies to minimize the development and spread of resistance. The journal is specifically concerned with the epidemiology of antibiotic resistance and the mechanisms of resistance development and diffusion in both hospitals and the community. The manuscript management system is completely online and includes a very quick and fair peer-review system, which is all easy to use. Visit <http://www.dovepress.com/testimonials.php> to read real quotes from published authors.

Submit your manuscript here: <https://www.dovepress.com/infection-and-drug-resistance-journal>