

Dexmedetomidine as an Adjuvant in Peripheral Nerve Block

Zheping Chen, Zhenzhen Liu, Chang Feng, Yanwu Jin, Xin Zhao 

Department of Anesthesiology, The Second Hospital, Cheeloo College of Medicine, Shandong University, Jinan, 250012, People's Republic of China

Correspondence: Yanwu Jin; Xin Zhao, Email jinyanwu_aa@163.com; lujnzx@sohu.com

Abstract: Peripheral nerve block technology is important to balanced anesthesia technology. It can effectively reduce opioid usage. It is the key to enhance clinical rehabilitation as an important part of the multimodal analgesia scheme. The emergence of ultrasound technology has accelerated peripheral nerve block technology development. It can directly observe the nerve shape, surrounding tissue, and diffusion path of drugs. It can also reduce the dosage of local anesthetics by improving positioning accuracy while enhancing the block's efficacy. Dexmedetomidine is a highly selective drug α_2 -adrenergic receptor agonist. Dexmedetomidine has the characteristics of sedation, analgesia, anti-anxiety, inhibition of sympathetic activity, mild respiratory inhibition, and stable hemodynamics. Numerous studies have revealed that dexmedetomidine in peripheral nerve blocks can shorten the onset time of anesthesia and prolong the time of sensory and motor nerve blocks. Although dexmedetomidine was approved by the European Drug Administration for sedation and analgesia in 2017, it has not yet been approved by the US Food and Drug Administration (FDA). It is used as a non-label drug as an adjuvant. Therefore, the risk-benefit ratio must be evaluated when using these drugs as adjuvants. This review explains the pharmacology and mechanism of dexmedetomidine, the effect of dexmedetomidine on various peripheral nerve block as an adjuvant, and compare it with other types of adjuvants. We summarized and reviewed the application progress of dexmedetomidine as an adjuvant in nerve block and look forward to its future research direction.

Keywords: dexmedetomidine, alpha-2 agonists, adjuvant, peripheral nerve block, anesthesia, analgesic

Introduction

In 1885, William Stewart Halsted discovered that injecting cocaine into specific parts of the nerve (around the plexus and nerve trunk) can block the sensory conduction of human nerves through self-experiment. Therefore, he invented nerve block anesthesia and pioneered regional nerve block.¹ Numerous traditional regional anesthesia technologies have realized visualization with the help of ultrasound with the continuous development of ultrasound technology. Peripheral nerve blocks (PNB) technology is increasingly significant in perioperative analgesia and clinical anesthesia. PNB or PNB combined with general anesthesia (GA) can reduce persistent incision and visceral pain, reduce opioid usage, shorten hospital stay, and reduce the recurrence rate of some cancers compared to GA, consistent with the concept of enhanced recovery after surgery (ERAS) advocated by modern medicine.^{2,3} PNB is now well-established as an integral part of a balanced anesthetic technique and constitutes a vital component of a multimodal analgesic regimen that enhances ERAS.

PNB has become the cornerstone of perioperative pain management in modern surgical practice. The finite duration of single injection techniques is one of the greatest limitations of PNB in acute pain management. Continuous catheter techniques are widely employed to prolong regional analgesia; however, they have several drawbacks, such as the difficulty of catheter removal and the increased risk of infection.^{4,5} Single-injection PNB is an attractive option because it is technically easier and can be performed quickly. Therefore, there is a growing demand to identify a reliable solution for prolonging analgesia duration from PNB.

Different agents have been combined with local anesthetics (LA) over the years to prolong the duration of action, with varying degrees of success. Analgesic adjuvants include opioids, epinephrine, sodium bicarbonate, magnesium sulfate, dexamethasone, ketorolac, ketamine, neostigmine, midazolam, cortisol, and α_2 -adrenergic receptor (α_2 -AR) agonists.⁶⁻⁸

The existing randomized controlled studies (RCTs) and meta-analysis exhibit that adding LA adjuvant to peripheral nerve block helps to prolong the analgesic time,⁹ can significantly improve the quality of PNB,^{7,8} and has a synergistic analgesic effect with LA. Most adjuvants are safe; neurotoxicity and tissue damage are rare. Although these drugs synergize when used as an adjuvant with LA, several studies have reported systemic adverse reactions, such as itching, nausea, and vomiting caused by opioids, including fentanyl and buprenorphine.^{10,11} Dexamethasone excessively prolonged the analgesic time, resulting in the slow recovery of postoperative walking ability.¹² Neostigmine can increase the analgesic effect by increasing the secretion of acetylcholine in nerve endings, but it can also increase the adverse reactions in the gastrointestinal tract. Ketamine can cause various adverse reactions, including hallucinations, nausea, and drowsiness.¹³ Therefore, adjuvants may have side effects that should be considered.¹⁴

Dexmedetomidine has certain advantages over other adjuvants. Dexmedetomidine is a highly selective drug α_2 -adrenergic receptor agonist with characteristics including sedation, analgesia, anti-anxiety, inhibition of sympathetic activity, mild respiratory inhibition, and stable hemodynamics.¹⁵ Numerous studies have discovered that applying dexmedetomidine in peripheral nerve blocks can shorten the onset time of anesthesia, prolong the time of sensory and motor nerve block, and achieve a satisfactory sedative effect. However, dexmedetomidine can lead to adverse reactions, such as bradycardia, hypotension, and excessive sedation.^{16,17} The dosage and safety of a drug should be considered during clinical application.

This review discusses the pharmacological characteristics of dexmedetomidine, its application progress and reasonable dose as an adjuvant in peripheral nerve block, the performance of dexmedetomidine in analgesic time and intensity, and its future application in peripheral nerve block.

Materials and Methods

The medical subject heading (MeSH) and text words related to dexmedetomidine, medetomidine, and clonidine were sought as interventions to avoid omitting the potentially relevant articles. The results were combined using the Boolean operator “AND” with Mesh and text words, including PNB, local anesthesia, infiltration anesthesia, “anesthetics”, local [MeSH], “nerve block” [MeSH], “adjuvants”, pharmaceutical [MeSH], adjuvant and regional anesthesia. The search included RCTs, meta-analysis, and a literature review. There was no restriction regarding the publication language.

Pharmacological Characteristics of Dexmedetomidine

Pharmacological and Physiological Effects of Dexmedetomidine

Dexmedetomidine is an imidazole compound. It is a right-handed isomer of medetomidine and a highly selective membrane-bound G-protein coupling α_2 -adrenergic receptor agonist discovered by Segal in the 1980s, with sedative and hypnosis effect.¹⁸ In 1999, it was approved by the US Food and Drug Administration (FDA) for short-term sedation of mechanical ventilation patients in an adult intensive care unit (ICU).¹⁹ It was approved for procedural sedation with many off-label indications to employ it in perioperative medicine. Moreover, it was approved by the European Medicines Agency for sedation and analgesia in 2017. The α_2 -adrenergic receptor is a G-protein coupled receptor with seven transmembranes. It is widely distributed in the periphery, central nervous system, and autonomic ganglion. It has the highest density in locus coeruleus, pontine nucleus, pontine tegmental reticular nucleus, parahippocampal gyrus, and cingulate gyrus. The α_2 -adrenergic receptors can be divided into α_{2A} , α_{2B} , and α_{2C} . Previous studies have demonstrated that α_{2A} receptors primarily control the exocytosis of adrenergic neurons. The absence of the α_{2A} receptor can lead to increased blood pressure and faster heart rate; the α_{2A} receptor can activate α_{2A} receptor agonists, plays the role of sedation and analgesia; α_{2B} receptors are mainly distributed in peripheral vascular smooth muscle, and transient blood pressure rise can occur after transient activation;²⁰ and α_{2C} receptors are primarily distributed in the hippocampus, basal ganglia, and cerebral cortex to regulate memory system and behavioral function.²¹

Highly selective activation of the dexmedetomidine α_{2A} receptor is sedative and hypnotic by acting on the locus coeruleus nucleus.²² It also activates the dorsal horn by acting on the nucleus coeruleus α_{2C} and α_{2A} receptor, reducing the secretion of anterior pain transmission molecules, substance P, glutamate, and the hyperpolarization of interneurons, to inhibit pain transmission and produce an analgesic effect directly.^{23,24} When dexmedetomidine was administered,

blood pressure could demonstrate a dose-dependent biphasic response. When administered in small doses, it primarily reduces vascular resistance, heart rate, and blood pressure through selective α_2 function. When administered in large doses or rapidly, it loses its selectivity α_2 , increasing blood pressure and decreasing heart rate, and gradually recovers over time (Figure 1).²⁰

Mechanism of Dexmedetomidine in Peripheral Nerve Block

The mechanism by which dexmedetomidine as an adjuvant to local anesthetics enhances their effect is a multifactorial theory still being debated. Several possible mechanisms have been suggested.

Peripheral Level

Peripheral action is the widely accepted mechanism by which dexmedetomidine enhances the blocking effect as an adjuvant. When dexmedetomidine was used alone in healthy volunteers, its blood concentration reached 1.23 ng/mL, but it did not have a sufficient analgesic effect on thermal or electrical stimulation.²⁵ When the same dose of dexmedetomidine was used in PNB combined with LA, the perineural injection had a stronger analgesic effect than systemic application or subcutaneous injection. This indicated that the peripheral effect was the primary mechanism by which dexmedetomidine could be used as an adjuvant for local anesthetics to enhance their effect.^{26,27} Brummett et al²⁸ compared dexmedetomidine combined with ropivacaine alone; the analgesic time could be effectively prolonged, while the analgesic effect of dexmedetomidine could not be reversed when α_2 receptor antagonist was given, proving that dexmedetomidine extended analgesia through local action. Hypothalamic paraventricular nucleus (PVN) neurons are in direct contact with noradrenergic synapses and are controlled by the hyperpolarization-activated currents called I_h (H current).²⁹ I_h is also called the pacemaker current because it is believed to play a significant role in cell excitability.³⁰ Dexmedetomidine can maintain the hyperpolarized state of cells by inhibiting the activation of the I_h current, inhibit the next action potential by inhibiting the potassium channel, maintain the depolarization of cells, and increase the inhibition of the sodium channel, thereby enhancing the effect of LA.^{28,31–35} This inhibitory effect is more obvious in unmyelinated C fibers (pain fibers) and small myelinated A- δ fibers (temperature sensation and rapid pain sensation) than in large myelinated motor fibers; consequently, the effect of dexmedetomidine on the sensory block is more obvious than on the motor block.^{36–38} Dexmedetomidine may exert its peripheral effect by activating α_2 adrenoceptors in peripheral blood

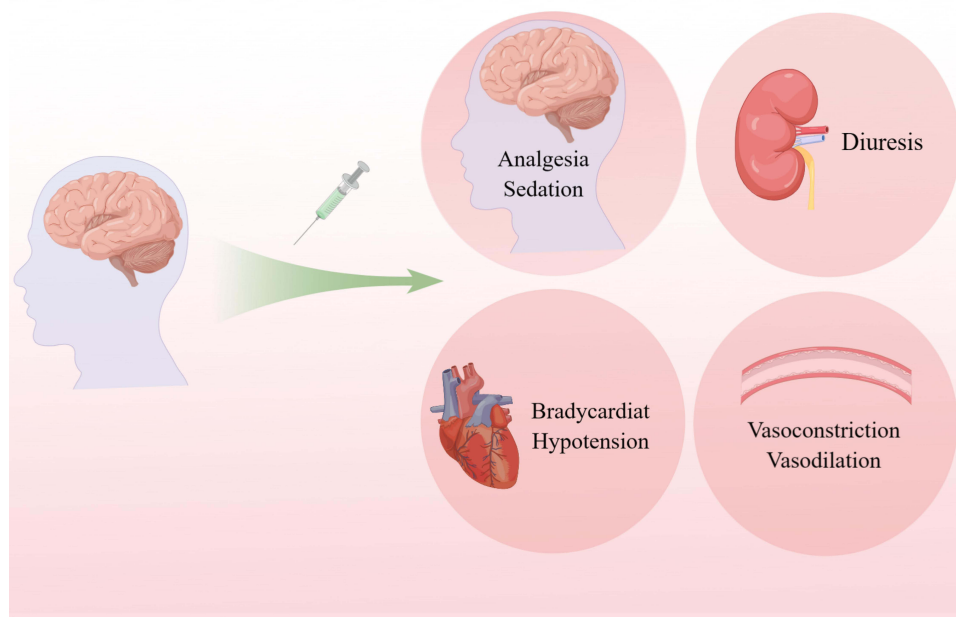


Figure 1 Multiple sites of action of dexmedetomidine (peripherally and centrally).

vessels, constricting blood vessels around the injection site, delaying the absorption of local anesthetics, and prolonging their block time.³⁹

Spinal Cord Level

Dexmedetomidine can reduce the release and reuptake of excitatory neurotransmitters, such as glutamate and substance P, by binding to α_2 receptors in the spinal dorsal horn after systemic absorption or local diffusion.^{23,24,40} Hyperpolarized interneurons inhibit the ascending spinal pathway related to nociceptive sensation, producing analgesia.⁴¹

Supraspinal Level

Although dexmedetomidine is ideally injected peripherally, few studies have discovered that it may have a certain systemic absorption so that it may have peripheral and central effects. It can spread to the cerebrospinal fluid via systemic absorption after perineural injection or intradural application, act on α_{2A} and α_{2C} adrenergic receptors in the brainstem, inhibit the descending noradrenergic pathway in the medulla or reduce sympathetic nerve signals, and achieve analgesic effect from the central level.^{36,41–44} However, the mechanism must be confirmed through further studies. El Sherif et al⁴⁵ discovered that systemic absorption of dexmedetomidine administered in TAP block is common. Dexmedetomidine, in addition to its local effects, may cause direct central effects on locus coeruleus by systemic absorption, thus affecting the analgesic and hemodynamic effects of TAP. This was similar to a previous study in which dexmedetomidine had the same effect as intravenous injection, despite being administered around the nerve.⁴⁶ Dexmedetomidine as an adjuvant for nerve block can also have a certain sedative effect on the center.^{43,44} All of the above evidence indicates that dexmedetomidine exists in different degrees of systemic absorption.

Existing studies have demonstrated that the analgesic mechanism of dexmedetomidine can be summarized as central analgesia and peripheral analgesia (Table 1).

Application of Dexmedetomidine in Peripheral Nerve Block

Dexmedetomidine, as an adjuvant, can affect nerve blocks to different degrees (Table 2).

Brachial Plexus Block (BPB)

Brachial plexus nerves are composed primarily of anterior branches of C_{5–8} and T₁ spinal nerves, frequently with the participation of anterior branches of C₄ and T₂ spinal nerves. These nerves dominate the whole upper limb movement and most of the upper limb sensation. Anesthesia in upper limb surgery can block the nerve trunk, nerve bundle, and branches of brachial plexus nerves separately and have been well-applied.⁴⁷

Biswas et al⁴⁴ divided 60 patients into control and experimental groups equally. The experimental group was given 35 mL of levobupivacaine and 1 mL (100 μ g) of dexmedetomidine, while the control group was given 35 mL of levobupivacaine and 1 mL of normal saline. The results revealed that the control group had a longer duration of sensory block, motor block, and the first time of salvage analgesia, and adding levobupivacaine to supraclavicular brachial nerve block could prolong the duration of block and postoperative analgesia time. However, ultrasound-guided localization was not used. Therefore, Bharti et al⁴⁸ adjusted the above deficiencies in the trial in 2015 and added the onset time of sensory

Table 1 Analgesic Mechanism of Dexmedetomidine

Classification of Analgesia	Mechanism
Spinal level	Act on the presynaptic of the posterior horn of the spinal, the postsynaptic membrane of intermediate neurons, and the locus coeruleus of the brain stem α_2 receptor, changing action potential in spinal and supraspinal ¹⁵⁷ Inhibit the release of excitatory neurotransmitters, such as glutamate and substance P, in the spinal ^{23,24}
Peripheral level	Inhibit δ and C fibers ¹⁵⁸ Act on the α_2 receptors in peripheral vascular smooth muscle cells to constrict the peripheral blood vessels, reduce the absorption of local anesthetics, and prolong the block time Inhibit Ih current for pain control (Na ⁺ and K ⁺ based inward mixed cation current generated by activation of cell membrane hyperpolarization of cyclic-nucleotide gated channel) to reduce pain ²⁶

Table 2 Characteristics of Included Randomised Controlled Trial

	Nerve Block Location	Guiding Technique	Surgery	Dose
Biswas et al ⁴⁴	Supraclavicular brachial plexus block	NS	Orthopaedic surgery of forearm and hand	100µg
Bharti et al ⁴⁸	Supraclavicular brachial plexus block	US	Upper limb and hand surgeries	1µg/kg
Nazir et al ⁴⁹	Supraclavicular brachial plexus block	US	Upper limb surgeries	1µg/kg
Reddy et al ⁵⁰	Supraclavicular brachial plexus block	US	Upper limb surgeries	1µg/kg
Venkatraman et al ⁵³	Supraclavicular brachial plexus block	US	Upper extremity surgeries	50µg
Sane et al ⁵¹	Supraclavicular brachial plexus block	US	Upper extremity orthopedic surgery	0.75µg/kg
Jung et al ⁵²	Interscalene brachial plexus block	US	Arthroscopic shoulder surgery	1, 1.5, 2µg/kg
Samar et al ⁵⁶	Supraclavicular brachial plexus block	NS	Upper limb orthopaedic surgery	1µg/kg
Somsunder et al ⁵⁷	Supraclavicular brachial plexus block	NS	Upper limb surgeries	1µg/kg
Yang et al ¹⁵⁹	Children axillary brachial plexus block	US	Children polydactyly surgery	0.25, 0.5, 0.75µg/kg
Helal et al ⁶²	Femoral-sciatic nerve block	US	Below knee surgery	100µg
Chaudhary et al ⁶³	Femoral-sciatic nerve block	US	Below knee orthopaedic surgeries	0.5µg/kg
Jin et al ⁶⁴	Femoral-sciatic nerve block	US+NS	TKA	0.5µg/kg
Yu et al ⁶⁵	Lumbar plexus-sciatic nerve block	NS	Ankle surgery	1, 1.5, 2µg/kg
Hu et al ⁶⁷	Popliteal sciatic nerve blockade along with femoral and obturator nerve blocks	US	Varicose saphenous vein resection	50µg
Sharma et al ⁶⁸	Femoral nerve block	US (catheter)	Unilateral total knee replacement	1.5µg/kg
Goel et al ⁷³	Femoral nerve block	US	Hip surgeries	50µg
Packiasabapathy et al ⁶⁹	Femoral nerve block	NS	Total knee replacement	1, 2µg/kg
Abdulatif et al ⁷⁰	Femoral nerve block	US	Arthroscopic knee surgery	25,50,75µg
Li et al ⁷¹	Femoral nerve block	NS (catheter)	TKA	1µg/kg
Xiao et al ⁷²	Femoral nerve block and femoral-sciatic nerve block	US+NS	TKA	0.6µg/kg
Ding et al ⁷⁶	Paravertebral block	US	Thoracoscopic lobectomy	1µg/kg
Abdulatif et al ⁷⁰	Paravertebral block	LM	Elective modified radical mastectomy with axillary dissection	1µg/kg
Mohta et al ⁷⁷	Paravertebral block	LM	Breast cancer surgery	1µg/kg
Zha et al ⁷⁹	Thoracic paravertebral block	US	Video-assisted thoracoscopic lobectomy	1µg/kg
Guo et al ⁸⁰	Thoracic paravertebral block	US	Breast cancer surgery	1µg/kg
Bicer et al ⁸¹	Paravertebral block	US	Thoracotomy	100µg
Yang et al ⁸³	Transversus abdominis plane block	US	Renal transplantation	1µg/kg
Qian et al ⁸⁴	Transversus abdominis plane block	US	Caesarian section	0.5µg/kg
Joseph et al ⁸⁵	Transversus abdominis plane block	US	Caesarian section	25µg
Singla et al ¹⁶⁰	Transversus abdominis plane block	US	Caesarean section	1µg/kg
Varshney et al ⁸⁶	Transversus abdominis plane block	US	Cesarean delivery	1µg/kg
Madangopal et al ⁸⁷	Transversus abdominis plane block	US	Unilateral inguinal hernioplasty	0.5,0.25µg/kg
Zeng et al ⁸⁸	Transversus abdominis plane block	US	Laparotomy for gynecologic malignancies	0.5, 1, 2µg/kg
Chapman et al ¹⁶¹	Transversus abdominis plane block	US	Colorectal surgery	25µg
Karasu et al ⁸⁹	Transversus abdominis plane block	US	Laparoscopic cholecystectomy	1µg/kg
Mostafa et al ⁹⁰	Transversus abdominis plane block	US	Laparoscopic surgery in children	0.5µg/kg
El Sherif et al ⁴⁵	Transversus abdominis plane block	US	Lower abdominal cancer surgery	1µg/kg
Santosh et al ⁹⁴	Bilateral superficial cervical plexus block	/	Thyroid surgery	0.5µg/kg
Lin et al ⁹⁵	Cervical plexus block	LM	Thyroid surgery	1µg/kg

(Continued)

Table 2 (Continued).

	Nerve Block Location	Guiding Technique	Surgery	Dose
Elmaddawy et al ⁹⁶ Zhang et al ⁹⁸	Bilateral superficial cervical plexus block Intercostal nerve block (six intercostal)	US Under thoracoscopic direct vision	Thyroid surgery Thoracoscopic pneumonectomy	1 µg/kg 1 µg/kg
Yao et al ⁹⁹	Intercostal nerve block (T2 to T6 intercostal)	LM	Lumpectomy	0.5 µg/kg
Abdallah et al ¹⁰¹	Serratus anterior plane block	US	Video-assisted thoracic surgery	1 µg/kg
Wu et al ¹⁶²	Deep serratus anterior plane block	US	Modified radical mastectomy	1 µg/kg
Li et al ¹⁶³	Continuous serratus anterior plane block	US	Thoracotomy	0.5, 1 µg/kg
Goyal et al ¹⁰³	Adductor canal block	US	Bilateral total knee replacement	0.25, 0.5 µg/kg
Wang et al ¹⁰⁵	Adductor canal block	US	TKA	1 µg/kg
Thapa et al ¹⁰⁶	Adductor canal block	US	Anterior cruciate ligament reconstruction surgery	0.5 µg/kg
Wang et al ¹¹⁰	Erector spinae plane block	US	Thoracotomy	0.5 µg/kg
Wang et al ¹¹¹	Erector spinae plane block	US	Modified radical mastectomy	1 µg/kg
Gao et al ¹¹²	Erector spinae plane block	US	VATS	1 µg/kg
Gao et al ¹⁶⁴	Erector spinae plane block	US	VATS	0.1, 0.5, 1 µg/kg
Manzoor et al ¹¹⁵	Pectoral nerve block I,II	US	Breast surgery	1 µg/kg
Kaur et al ¹¹⁶	Pectoral nerve block I,II	US	Oncological breast surgery	1 µg/kg
Alansary et al ¹²¹	Quadratus lumborum block	US	Open renal surgery	1 µg/kg
Thapa et al ¹²⁴	Stellate ganglion block	US	Upper limb surgery	0.5 µg/kg
Andersen et al ¹⁶⁵	Aphenous nerve blocks	US	/	100 µg/mL
Sivakumar et al ¹⁶⁶	Fascia iliaca compartment block	US	Femur surgeries	1 µg/kg
Varsha et al ¹⁶⁷	Ilioinguinal-iliohypogastric block	US	Pediatric inguinal hernia surgeries	1 µg/kg

Abbreviations: NS, Nerve stimulator; US, Ultrasound; LM, Landmark; TKA, Total knee replacement; VATS, Video-assisted thoracic surgery.

and motor blocks in the result records to observe and record the hemodynamic changes of patients and the number of postoperative analgesics. However, 1 µg/kg dexmedetomidine was administered to the experimental group. The results presented that adding dexmedetomidine to the ropivacaine-lidocaine mixture can significantly prolong the duration of the block, improve postoperative analgesia, and reduce the need for emergency analgesics in patients undergoing upper limb surgery. Consistent with the results of Nazir et al⁴⁹ the experimental group was also established using the standard of 1 µg/kg. Moreover, Nazir also included a sedation score in the evaluation, and the results suggested that dexmedetomidine could increase the postoperative sedation effect. Reddy et al⁵⁰ compared the intravenous infusion of dexmedetomidine with the adjuvant of 0.5% leupivacaine (1 µg/kg) in suclavicular brachial nerve block. The results revealed that sensory and motor blocks acted more quickly in the perineural group, with longer duration and analgesia than intravenous dexmedetomidine. Sane et al⁵¹ employed 39 mL bupivacaine (0.25%) + 0.75 µg/kg dexmedetomidine as the test group. The results also confirmed that dexmedetomidine combined with bupivacaine reduced the onset time of sensory and motor block and increased the duration of numbness and immobility. Jung et al⁵² compared the addition of dexmedetomidine in local anesthetics with the simple control and established dexmedetomidine experimental groups with various concentrations (1, 1.5, and 2 µg/kg). The results demonstrated that 2 µg/kg dexmedetomidine could provide sufficient analgesic duration, indicating that Dexmedetomidine 2 µg/kg may be the best dose for brachial plexus block during arthroscopic shoulder surgery. Venkatraman et al⁵³ compared quantitative morphine (5 mg), dexmedetomidine (50 µg), and dexamethasone (8 mg) for supraclavicular brachial Plexus block (SBPB). The results presented that dexmedetomidine had the shortest onset time of the sensory and motor blocks, but dexamethasone had the best duration of postoperative analgesia.

Therefore, dexmedetomidine, as an adjuvant of LA in BPB, has certain advantages in sedation, analgesia, and onset time, despite the specific concentration of dexmedetomidine or quantitative dexmedetomidine. Similar conclusions have

been reached in a series of recent meta-analyses.^{54,55} However, the selection of different dexmedetomidine concentrations lacks a unified conclusion. The comparison between intravenous infusion and perineural use of dexmedetomidine was also inconsistent. Sehmbi et al⁵⁵ showed that intravenous dexmedetomidine infusion did not prolong the sensation, motor, or pain relief duration. Samar et al⁵⁶ revealed that intravenous dexmedetomidine could produce sensory block earlier, with a longer sensory and motor block and analgesia duration. Regarding the onset and duration of block and duration of analgesia, Somsunder et al⁵⁷ discovered that intravenous dexmedetomidine was equally effective as epineural dexmedetomidine, but the hemodynamic fluctuation was larger. However, additional research indicates that intravenous dexmedetomidine can prolong the analgesic time and reduce opioid consumption to a certain extent, and perineural application has a more pronounced effect.^{46,50}

Sciatic Nerve Block (SNB)

Due to the sciatic nerve is the longest human body is the most massive peripheral nerve (by multilayer membrane package), mainly by the former branch of L₄₋₅ and S₁₋₃ nerve, compared to the smaller nerve, local anesthetics to penetrate or dispersion to target sodium channels need longer effective time.⁵⁸

Currently, Brummett et al⁵⁹ discovered that bupivacaine combined with high-dose dexmedetomidine intranasal administration significantly prolonged the duration of sensory and motor blocks in animal experiments. Other basic studies also demonstrated that dexmedetomidine combined with LA could prolong peripheral nerve block analgesic time in rats.^{60,61}

Clinical studies frequently combine sciatic nerve blocks with other nerve blocks. It usually includes a femoral-sciatic nerve block and a lumbar plexus-sciatic nerve block.

Femoral-Sciatic Nerve Block

Helal et al⁶² used 0.5% bupivacaine to perform nerve block on 60 patients undergoing knee surgery and found that adding 100 µg dexmedetomidine to bupivacaine for femoral sciatic nerve block shortened the pre-operative time of sensory and motor block by 20%. Sensory and motor block durations were 45% and 40% longer, respectively, but blood pressure and heart rate decreased 10 to 90 min after the block. Chaudhary et al⁶³ used dexmedetomidine (0.5 µg/kg) with a combined quantitative dose of 0.125% levobupivacaine to perform femoral-sciatic nerve blocks on patients undergoing knee surgery, and the results demonstrated that dexmedetomidine could prolong the block time. Jin et al⁶⁴ compared the intravenous and systemic administration of dexmedetomidine (0.5 µg/kg) combined with 0.25% ropivacaine (0.25% Rop 40 mL) in total knee arthroplasty (TKA) patients. The results revealed that intranasal dexmedetomidine could significantly prolong the time interval between the onset of pain after TKA, reduce postoperative pain, reduce postoperative opioid dosage, and improve postoperative sleep quality and pain management satisfaction.

Lumbar Plexus-Sciatic Nerve Block (LSB)

Yu et al⁶⁵ added 1 µg/kg, 1.5 µg/kg, and 2 µg/kg of dexmedetomidine to 30 mL 0.5% ropivacaine (ROP) in 80 patients undergoing LSB lower ankle surgery. The results suggested that the peripheral nerve administration of dexmedetomidine (2 µg/kg) was consistent with ropivacaine, which can most significantly prolong the duration of sensory and motor block. Wang et al⁶⁶ demonstrated that an LSB block and 0.33% ropivacaine combined with dexmedetomidine (1 µg/kg) in a 79-year-old man with multiple cerebral infarctions and congestive heart failure who underwent knee amputation due to ischemic necrosis of the left lower limb could also prolong the analgesic time to 26 h and maintain hemodynamic stability. Hu et al⁶⁷ performed a popliteal sciatic nerve block combined with femoral nerve and obturator nerve block in 60 patients with great saphenous vein varicose. The results indicated that 0.5 mL (50 µg) dexmedetomidine could also prolong the block time.

Femoral Nerve Block (FNB)

The femoral nerve (lumbar 2~4) is the largest branch of the lumbar plexus. It descends between the psoas major and the iliac muscles and supplies this muscle with branches. It enters the thigh through the deep surface of the midpoint of the inguinal ligament and is divided into several branches.

Sharma et al⁶⁸ performed femoral nerve block in 50 patients with unilateral total knee replacement (TKR). The results demonstrated that adding 0.2% dexmedetomidine to ropivacaine could improve the quality and prolong the postoperative analgesia time. Subsequently, Packiasabapathy et al⁶⁹ proposed different concentrations of dexmedetomidine, with 1 µg/kg and 2 µg/kg dexmedetomidine + 20 mL (0.25%) bupivacaine used in the experimental group, respectively. The results revealed that dexmedetomidine at 2 µg/kg in FNB was better than 1 µg/kg. Compared to bupivacaine alone, it can prolong the analgesic time and reduce the use of opioids after the operation.

Abdulatif et al⁷⁰ conducted a quantitative study of dexmedetomidine combined with bupivacaine and added 25 µg, 50 µg, and 75 µg multiple doses of dexmedetomidine to 0.5% bupivacaine solution, compared to the blank control group. In comparison to the addition of 25 µg dexmedetomidine, the addition of 50 µg and 75 µg dexmedetomidine could shorten the onset time of the sensory and motor block, prolong the duration of sensory and motor block, reduce the time of postoperative first remedial analgesia and the use of postoperative analgesic morphine. These advantages are more evident with the increase in dexmedetomidine dose, but the risk of adverse reactions also increases.

Additionally, Li et al⁷¹ discovered that ropivacaine combined with dexmedetomidine for femoral nerve block could inhibit the local inflammatory response. For patients requiring TKR, 20 mL of 0.5% ropivacaine with 1 µg/kg dexmedetomidine was used for the femoral nerve block. The results indicated that the VAS score, knee circumference, IL-6 concentration in joint fluid, and prostaglandin E-2 concentration in the experimental group were lower than in the control group 12~8 h after the operation. After the femoral nerve block, adding 1 µg/kg dexmedetomidine to ropivacaine can significantly inhibit the local inflammatory response. Moreover, ropivacaine with dexmedetomidine has a better postoperative analgesic effect on TKA than ropivacaine alone.

Xiao et al⁷² compared the difference between femoral and sciatic nerve blocks. The results indicated that the analgesic effect of dexmedetomidine combined with femoral nerve block in TKA was similar to that of femoral-sciatic nerve block. Goel et al⁷³ compared the effects of peripheral and systemic dexmedetomidine. The results displayed that peripheral (39.5 mL 0.25% bupivacaine + 0.5 mL 50 µg dexmedetomidine) or systemic dexmedetomidine did not prolong the duration of analgesia compared to femoral nerve block using bupivacaine alone.

Paravertebral Blockade (PVB)

Paravertebral blockade (PVB) is a technique used to block the conduction of somatosensory and motor nerves by injecting local anesthetics into the spinal nerve in paravertebral space to pass through the lateral spinal nerve formed by the foraminal foramen to relieve chest and abdominal surgery-related pain.⁷⁴ Previous thoracic epidural analgesia is the gold standard for postoperative analgesia after thoracic surgery, but it is associated with risks, such as hypotension. Studies have demonstrated that the analgesic effect of PVB is comparable to thoracic epidural analgesia (TEA) after chest surgery with fewer adverse reactions, so PVB is widely used in clinical practice.⁷⁵

Ding et al⁷⁶ applied PVB or TEA in 113 patients requiring video-assisted surgery. The results revealed that 0.5% ropivacaine combined with 1 µg/kg dexmedetomidine perineural administration in PVB could prolong the analgesic time and reduce postoperative pain score compared to 0.5% ropivacaine alone. It can effectively reduce postoperative adverse reactions compared to 0.5% ropivacaine TEA. Mohamed et al⁷⁷ performed PVB on patients undergoing radical mastectomy for breast cancer. Compared to 20 mL of 0.25% ropivacaine alone, ropivacaine combined with 1 µg/kg dexmedetomidine could effectively improve postoperative analgesia, prolong analgesia time, and reduce the use of postoperative opioids. This is consistent with the results of Mohta et al⁷⁸ except Mohta used 0.5% bupivacaine combined with 1 µg/kg dexmedetomidine. The results displayed that complications, such as hypotension and arrhythmia, could be effectively avoided. However, the latest results of Zha et al⁷⁹ discovered that 0.5% ropivacaine combined with 1 µg/kg dexmedetomidine perineural application did not reduce the complications of hypotension and arrhythmia, despite producing a longer analgesic effect, reducing postoperative opioid consumption, and reducing the incidence of side effects, such as nausea and vomiting. Guo et al⁸⁰ studied the effect of dexmedetomidine as a PVB adjuvant on the effective concentration (EC₅₀) of propofol successfully placed in the laryngeal mask. The results demonstrated that 0.3 mL/kg of 0.5% ropivacaine combined with 1 µg/kg dexmedetomidine could reduce the TCI concentration of propofol, making it easier for female patients to place the laryngeal mask. Biçer et al⁸¹ conducted a study of dexmedetomidine in PVB in 93 patients requiring thoracotomy. The results revealed a paravertebral block with 20 mL

0.5% bupivacaine + 1 mL dexmedetomidine (100 µg) reduced postoperative pain scores and morphine consumption. However, the perineural administration of dexmedetomidine did not affect hemodynamics.

Transversus Abdominis Plane Block (TAPB)

Transversus abdominis plane block (TAPB) is also known as transversal fascia block. The abdominal muscles can be divided into external oblique, internal oblique, and transverse abdominis, with the fascia layer between them, and the plane between the internal oblique and transverse abdominis is called TAP.⁸² TAPB has an excellent analgesic effect on skin, muscle, and parietal peritoneum of the anterior abdominal wall.

Yang et al⁸³ compared the analgesic effect of TAPB on kidney transplant recipients with or without dexmedetomidine. The results disclosed that 30 mL of 0.33% ropivacaine combined with 1 µg/kg dexmedetomidine reduced morphine consumption in the first 24 h after kidney transplantation. Dexmedetomidine as an adjuvant provided more effective analgesia. Qian et al⁸⁴ performed TAPB on 70 patients requiring cesarean section. The experimental group used bilateral 20 mL 0.3% ropivacaine combined with 0.5 µg/kg dexmedetomidine TAPB. The results indicated that adding 0.5 µg/kg dexmedetomidine to 0.3% ropivacaine can prolong the painless duration and reduce the VAS score. It can also reduce the number of patients who require emergency analgesia, extend the duration of initial analgesia, and improve patient satisfaction without serious side effects. This result was consistent with Joseph et al.⁸⁵ He discovered that 20 mL of 0.5% ropivacaine combined with 25 µg fentanyl or 25 µg dexmedetomidine effectively prolonged analgesia and reduced total analgesic consumption. Varshney et al⁸⁶ and others have also proved this point of view.

In addition to kidney transplantation and Caesarean section, dexmedetomidine has been successfully applied as an adjuvant in hernia repair Madangopal et al⁸⁷ open treatment of gynecological malignant tumor,⁸⁸ minimally invasive colorectal surgery,¹⁶¹ laparoscopic cholecystectomy,⁸⁹ laparoscopic bile duct exploration in children⁹⁰ and other operations. It has obvious advantages in postoperative analgesia.

Cervical Plexus Block (CPB)

The cervical plexus comprises the anterior branches from the first to fourth cervical nerves, and the cervical plexus block can be divided into deep and shallow cervical plexus blocks.⁹¹ It is effective in thyroid surgery, transcatheter aortic valve implantation (TAVI), clavicular surgery, carotid endarterectomy, and chest surgery with spontaneous breathing preservation.^{92,93}

Santosh et al⁹⁴ performed CPB on 60 patients requiring thyroid surgery. The results showed that compared to 0.5% ropivacaine alone, 20 mL of 0.5% ropivacaine combined with 0.5 µg/kg dexmedetomidine significantly prolonged postoperative analgesia and patient satisfaction, and patient satisfaction was higher. However, it did not improve hemodynamic stability and sedation and swallowing pain, consistent with Lin et al⁹⁵ previous results. Lin administrated 0.375% ropivacaine to 40 patients undergoing thyroid surgery to receive CPB, and the experimental group additionally administrated 1 µg/kg dexmedetomidine around the nerve. The results confirmed that the experimental group could shorten the sensory block's onset time and prolong the analgesia's duration. The patient remained sedated and could be awakened at any time during the operation, but the mean arterial pressure and heart rate decreased after the procedure, requiring the anesthesiologist to pay close attention to hemodynamic changes during the operation. Elmaddawy et al⁹⁶ mixed bupivacaine, epinephrine, and dexmedetomidine in thyroid surgery for bilateral CPB. The results demonstrated that applying 1 µg/kg dexmedetomidine around the cervical plexus prolonged the analgesic time during and after surgery, reduced the demand for opioids, and reduced the heart rate. Postoperative complications and mean arterial pressure did not differ.

Intercostal Nerve Block (INB)

The intercostal nerve runs from the inside of the rib angle (6–8 cm from the midline) between the pleura and the intercostal fascia. Intercostal nerve block has been used for various chronic and acute pain conditions, including rib fracture, herpes zoster, postoperative thoracotomy pain syndrome, and intercostal neuralgia.⁹⁷

Zhang et al⁹⁸ performed INB on 80 patients who underwent thoracoscopic pneumonectomy. The experimental group received 10 mg dexamethasone 2 mL or 2 mL 1 µg/kg dexmedetomidine based on 28 mL 0.5% ropivacaine + 2 mL

normal saline, respectively, injected into six intercostal spaces with 5 mL injection in each space. The results presented that perineural application of dexmedetomidine or dexamethasone could effectively prolong the analgesic time and reduce the use of postoperative remedial analgesics, but could not reduce the incidence of postoperative complications. Yao et al⁹⁹ compared the effect of intravenous or perineural dexmedetomidine combined with ropivacaine on mass resection and proved that 0.5 µg/kg dexmedetomidine combined with 0.5% ropivacaine for intercostal nerve block could prolong the duration of postoperative analgesia. The analgesia duration via the nerve route is longer than that via the venous route. However, the sedation scores did not differ.

Serratus Anterior Plane Block (SAPB)

Serratus anterior plane block (SAPB) is a newly proposed thoracic nerve block method that primarily blocks the lateral cutaneous branch of the thoracic intercostal nerve, providing anterolateral and partial posterior thoracic regional analgesia that can be used for postoperative analgesia of breast surgery, rib fracture, and thoracotomy.¹⁰⁰

Abdallah et al¹⁶³ evaluated the postoperative analgesic efficiency of SAPB with dexmedetomidine as an adjuvant of levobupivacaine for thoracic surgery and proposed that levobupivacaine plus dexmedetomidine continuous SAPB can be used as an analgesic program after thoracic surgery, and combined with acetaminophen can provide sufficient sedation and analgesic effect. Li et al¹⁰¹ performed SAPB on 80 patients undergoing video-assisted thoracic surgery (VATS), and the experimental group received 20 mL of 0.5% ropivacaine + 0.5 µg/kg or 1 µg/kg dexmedetomidine. The results revealed that 1 µg/kg dexmedetomidine was the most beneficial adjuvant for prolonging the analgesic time and effect.

Adductor Canal Block (ACB)

Femoral nerve block (FNB) is an effective analgesic method. However, the application of FNB is limited in minimally invasive arthroscopic knee surgery because FNB reduces the muscle strength of the quadriceps femoris, leads to lower limb immobility, and increases the risk of falling. However, adductor Canal block (ACB) can reduce postoperative opioid dosage and has little effect on muscle strength, attracting increased attention.¹⁰²

Goyal et al¹⁰³ proved that adding dexmedetomidine to ropivacaine in Total Knee arthroplasty (TKA) can prolong the analgesic time after adductor canal block. On this basis, Herman et al¹⁰⁴ proposed that an adjuvant combination of dexmedetomidine and dexamethasone (DEX-DEX) can be used in TKA, and their synergistic effect can prolong the analgesic time. Further, Wang et al¹⁰⁵ recently demonstrated that peripheral application of dexmedetomidine 1 µg/kg in TKA reduced the median effective concentration of ropivacaine for adduction block (from 0.38% to 0.29%). In addition to TKA, FNB with dexmedetomidine as an adjuvant was also used in Achilles tendon repair and anterior cruciate ligament reconstruction surgeries.¹⁰⁶

Erector Spinae Plane Block (ESPB)

The erector spinae (ES) is the longest and largest of the deep dorsal muscles. It is located in the sulcus on each side of the spine, rising from the dorsal side of the sacrum and posterior to the iliac crest and terminating in the vertebrae and ribs. Ultrasonics-guided Erector Spinae plane block (ESPB) is a novel interfascial plane block technique first proposed by Forero et al¹⁰⁷ in 2016 and successfully applied in treating severe acute postoperative and neuropathic pain. Several studies have validated that ESPB and PVB may have the same effect in breast cancer surgery and thoracoscopic surgery, and the ESPB is more effective than INB.^{108,109}

Wang et al¹¹⁰ demonstrated that 28 mL 0.5% ropivacaine combined with 2 mL of 0.5 µg/kg dexmedetomidine in treating ESPB after thoracotomy could effectively prolong postoperative analgesia time and reduce opioid consumption without increasing the incidence of additional adverse reactions. Wang et al¹¹¹ also demonstrated this point by using ESPB in modified radical mastectomy, with the difference that 30 mL dexmedetomidine + 0.33% ropivacaine was used in the experimental group. Additionally, Gao et al¹¹² reached the same conclusion in thoracoscopic lobectomy and discovered that 1 µg/kg dexmedetomidine was better than 10 mg dexamethasone as an adjuvant.

Pectoral Nerve Block (PECS)

PECS includes PECS-I and PECS-II, followed by PECS-I combined with PECS-II, widely used in clinics. Since PECS, ESPB, INB, and PVB have similar effects, they have been frequently compared recently, and PECS has certain advantages in breast cancer.^{97,113,114}

Manzoor et al¹¹⁵ reported that PECS with 1 µg/kg dexmedetomidine as an adjuvant of bupivacaine could prolong the duration of postoperative analgesia and improve the quality of postoperative analgesia without serious side effects. Kaur et al¹¹⁶ focused on pain and stress, presenting that dexmedetomidine at 1 µg/kg in PECS provided better analgesia and greater inhibition of stress hormone levels (cortisol and prolactin) without serious side effects. Zusman et al¹¹⁷ examined the synergistic effect of dexmedetomidine and dexamethasone (DEX-DEX) as adjuvants in analgesia, consistent with Herman et al.¹⁰⁴

Quadratus Lumborum Block (QLB)

Quadratus Lumborum block (QLB) has been developed for over a decade since it was first proposed in 2007. QLB suits auxiliary anesthesia and perioperative analgesia in abdominal, hip, and lower limb surgeries.^{118,119} Currently, four common approaches, including lateral QLB, posterior QLB, anterior QLB, and intramuscular QLB, are used for quadratus lumborum block in clinical practice.¹²⁰

Alansary et al¹²¹ performed QLB on 80 patients undergoing open kidney surgery. The experimental group received 30 mL of 0.25% bupivacaine + 1 µg/kg dexmedetomidine. Compared to bupivacaine alone, the amount of postoperative morphine was significantly reduced, the duration of initial analgesia was prolonged, and sufficient sedation was achieved. Moreover, it can effectively reduce the incidence of adverse reactions, but the average blood pressure and heart rate have a certain decrease.

Stellate Ganglion Block (SGB)

Stellate ganglion block is a method in which a local anesthetic is injected into the surface of the stellate ganglion so that it is infiltrated with the drug fluid, thereby blocking sympathetic activity in the area dominated.¹²² General indications for stellate ganglion block include postherpetic neuralgia of the face, chest, back, and upper limbs, trigeminal neuralgia, and migraine.¹²³

Thapa et al¹²⁴ evaluated the effect of dexmedetomidine as an adjuvant in SGB. In upper limb surgery, 3 mL 2% lidocaine + 0.5 µg/kg dexmedetomidine for SGB can reduce the use of tramadol within 24 h after surgery, prolong postoperative analgesia time, and has more advantages than intravenous dexmedetomidine. Shrestha et al¹²⁵ recently proposed ultrasound-guided SGB with dexmedetomidine as an adjuvant for treating Complex Regional Pain Syndrome (CRPS). This case report exposed that dexmedetomidine as an adjuvant of LA in SGB did not cause significant side effects.

Neurotoxicity of Dexmedetomidine in Peripheral Nerve Block

A series of animal experiments were conducted to evaluate the possible neurotoxicity of dexmedetomidine during PNB. The sciatic nerve block was performed with a high dose of dexmedetomidine (20–40 mg/kg) combined with bupivacaine and ropivacaine, respectively. Neurotoxicity, axon, or myelin sheath damage were not observed 24 h and 14 d after injection.^{123,126,127} Meanwhile, dexmedetomidine attenuated bupivacaine-induced neurotoxicity by regulating mast cell degranulation.¹²⁸ It is suggested that the neuroprotective effect of dexmedetomidine makes it suitable for peripheral nerve block as a combined local anesthetic. However, Yu et al¹²⁹ recently discovered that 0.5% ropivacaine caused significant sciatic nerve injury in diabetic rats. A large dose of dexmedetomidine was significantly enhanced, although 20 µg/kg dexmedetomidine was higher than the clinical dose. However, ropivacaine (alone and combined with dexmedetomidine) for peripheral nerve block in diabetic patients must be studied further. Wang et al¹³⁰ studied the dose-dependent neurotoxicity of dexmedetomidine and discovered that the lowest dose of dexmedetomidine (1 and 2 µg/mL) combined with 0.25% ropivacaine was used for continuous femoral nerve block without neurotoxic damage, whereas a higher dose (3 µg/mL) could lead to neurotoxic damage in the experimental rabbit model. Xue et al¹³¹ also proposed that adding dexmedetomidine in ropivacaine to sciatic nerve block in rats prolonged the duration of sciatic nerve sensory and motor block and significantly alleviated the neurotoxicity induced by ropivacaine by reducing caspase-

3-dependent sciatic nerve cell apoptosis. Studies have demonstrated that 20 µg/kg of dexmedetomidine is more effective than 6 µg/kg. Therefore, most current studies are animal and in vitro neural experiments. There is still insufficient strong evidence of whether human peripheral nerve fiber toxicity has a clinical application.

Comparative Studies of Dexmedetomidine with Other Drugs

In several studies, we compared dexmedetomidine and some other drugs as adjuvants (Table 3).

Table 3 Comparative Studies of Dexmedetomidine with Other Drugs as Adjuvants

Comparative Agents	Purpose	Outcome	Reference
Dexmedetomidine vs clonidine	Compare clonidine and dexmedetomidine in supraclavicular BPB	When added to local anesthetic in the supraclavicular BPB, Dexmedetomidine enhanced the duration of sensory and motor block and analgesia. The time for rescue analgesia was prolonged in patients receiving dexmedetomidine. It also enhanced the quality of the block as compared with clonidine	[132]
Dexmedetomidine vs clonidine	Compare dexmedetomidine or clonidine could improve the analgesic profile of levobupivacaine to the same extent during TAPB	Adding dexmedetomidine to levobupivacaine can extend the time of analgesia and reduce the use of postoperative backup analgesics with minimal sedation effects when used in TAPB in pediatrics undergoing laparoscopic orchiopexy. Clonidine can be used as an alternative adjuvant to local anesthetics with good postoperative analgesic profiles	[90]
Dexmedetomidine vs clonidine	Compare dexmedetomidine and clonidine added to bupivacaine in infraclavicular BPB	Dexmedetomidine provides a quicker and prolonged analgesic action without major adverse effects	[133]
Dexmedetomidine vs clonidine	Review the efficacy and safety of dexmedetomidine and clonidine as perineural or systemic adjuvants for BPB	Alpha2-receptor agonists used as adjuvants for BPB lead to a prolonged duration of analgesia, with dexmedetomidine as the most efficient. Alpha2-receptor agonists were associated with an increased risk of cardiovascular adverse events	[54]
Dexmedetomidine vs nalbuphine	Compare dexmedetomidine and nalbuphine in BPB	Compared with dexmedetomidine, nalbuphine had significantly shorter sensory and motor block onset time, longer block duration, less analgesic need, and fewer side effects	[135]
Dexmedetomidine vs nalbuphine	Compare nalbuphine and dexmedetomidine for ESPB in VATS	Nalbuphine and dexmedetomidine are comparable in terms of the associated analgesia, sensory block duration, need for rescue analgesia, and incidence of chronic pain in patients after VATS in ESPB	[136]
Dexmedetomidine vs nalbuphine	Compare dexmedetomidine and nalbuphine in TVPB in breast cancer surgeries	Adding nalbuphine to TPVB improved the block's quality and decreased postoperative analgesic requirements. Adding dexmedetomidine to bupivacaine increased the time to the first analgesic request and more sedation than bupivacaine and bupivacaine with nalbuphine	[134]
Dexmedetomidine vs dexamethasone	Compare dexmedetomidine and dexamethasone in supraclavicular BPB	Both dexmedetomidine and dexamethasone, when used as adjuvants to ropivacaine for supraclavicular BPB, block onset time and prolong block duration.	[17]
Dexmedetomidine vs morphine and dexamethasone	Compare morphine, dexmedetomidine, and dexamethasone in ultrasound-guided supraclavicular BPB	Dexamethasone is an ideal adjuvant to ropivacaine in BPB to prolong postoperative analgesia and is devoid of adverse effects. Dexmedetomidine has a quicker onset of sensory and motor blockade	[53]

(Continued)

Table 3 (Continued).

Comparative Agents	Purpose	Outcome	Reference
Dexmedetomidine vs dexamethasone	Compare dexamethasone and dexmedetomidine for the infraclavicular BPB in patients undergoing forearm fracture surgery	There was no significant difference in postoperative pain intensity between dexamethasone and dexmedetomidine groups, although dexmedetomidine demonstrated a longer sensory block duration in comparison with dexamethasone as a lidocaine adjuvant in infraclavicular BPB	[138]
Dexmedetomidine vs dexamethasone	Compares dexamethasone and dexmedetomidine on postoperative analgesia	Dexamethasone and dexmedetomidine have equivalent analgesic effects in peripheral nerve blocks	[137]
Dexmedetomidine vs magnesium sulfate	Compare dexmedetomidine and MgSO ₄ in supraclavicular BPB	Dexmedetomidine provides earlier onset of the sensory and motor block and a prolonged duration of sensory and motor blocks, the duration of analgesia is longer, and postoperative rescue analgesia is less compared to patients receiving MgSO ₄ . The incidence of hypotension and bradycardia and sedation score was higher with dexmedetomidine	[139]
Dexmedetomidine vs magnesium sulfate	Compare magnesium sulfate and dexmedetomidine in infraclavicular BPB	Dexmedetomidine provided quicker onset, longer duration of analgesia with lesser consumption of postoperative rescue analgesia. It showed a higher incidence of intraoperative hypotension and bradycardia than magnesium sulfate	[140]
Dexmedetomidine vs sufentanil	Compare dexmedetomidine and sufentanil as adjuvants for bupivacaine in BPB	Sufentanil is a fairly better choice than dexmedetomidine as an adjuvant for bupivacaine and can provide preferable sensory and motor blocks	[141]
Dexmedetomidine vs fentanyl	Compare dexmedetomidine and fentanyl under ultrasound guidance in supraclavicular BPB	Dexmedetomidine prolongs the duration of sensory and motor block and postoperative analgesia as compared to fentanyl when used as an adjuvant to ropivacaine in supraclavicular BPB and is not associated with any major adverse events	[122]
Dexmedetomidine vs epinephrine	Compare dexmedetomidine and epinephrine in infraclavicular BPB.	Perineural 1 µg/kg of dexmedetomidine similarly prolonged nerve block duration compared to 200 µg of epinephrine but slowed heart rate	[13]
Dexmedetomidine vs ketorolac	Examine dexmedetomidine and ketorolac as local anesthetic adjuvants in infraclavicular BPB	Dexmedetomidine had better effects on sensory and motor block duration and onset than ketorolac, as lidocaine adjuvants in infraclavicular BPB were present in both protocols. The first time to an analgesic request by ketorolac was longer than dexmedetomidine	[143]

Abbreviations: BPB, Brachial plexus block; TAPB, Transversus abdominis plane block; ESPB, Erector spinae plane block; VATS, Video-assisted thoracic surgery; TPVB, thoracic paravertebral block.

Dexmedetomidine vs Clonidine

Clonidine, similar to dexmedetomidine, has received great attention. When 1 µg/kg Dexmedetomidine was added to local anesthetic in the supraclavicular brachial plexus block, it enhanced the sensory and motor block and analgesia duration compared to 1 µg/kg Clonidine. The time for rescue analgesia was prolonged in patients receiving dexmedetomidine. It also enhanced the quality of the block compared to clonidine.¹³² This suggests that dexmedetomidine may have a better analgesic effect and longer analgesic time as an adjuvant. Another study on the brachial plexus block also proves this view, although it is not the supraclavicular brachial plexus block but the axial plexus block. The results indicate that adding dexmedetomidine to the axial plexus block increases the sensor and motor block duration and time to first acute

use while decreasing total acute use without side effects. The results were consistent when dexmedetomidine was used as an adjuvant in the subclavian brachial plexus block. Compared to 1 µg/kg clonidine, 1 µg/kg dexmedetomidine provides a quicker and prolonged analgesic action without major adverse effects.¹³³ More systematic meta-analysis also identified that α_2 -adrenergic receptor agonists used as adjustments for BPBs lead to a prolonged analysis period, with dexmedetomidine as the most effective. However, α_2 -adrenergic receptor agonists were associated with an increased risk of cardiovascular adverse events.⁵⁴ When used in TAPB in pediatrics undergoing laparoscopic orchiopexy, adding dexmedetomidine to levobupivacaine can extend the time of analgesia and reduce the use of postoperative backup analgesics with minimal sedation effects. Clonidine can be an alternative adjuvant to local anesthetics with good postoperative analgesic profiles. However, considering the price of these two drugs, clonidine can be the best choice in developing countries and regions.⁹⁰

Dexmedetomidine vs Nalbuphine

Nalbuphine is a recently developed and powerful analgesic. Nalbuphine and μ , κ , and δ receptor binding, but not with σ receptor binding, nalbuphine is κ receptor agonist/ μ receptor partially antagonistic analgesic. A new study exhibits that adding nalbuphine 10 mg as an adjuvant to bupivacaine local anesthetic in PVB improved the quality of the block and decreased postoperative analgesic requirements than the bupivacaine only group and dexmedetomidine and bupivacaine group. Although nalbuphine has more advantages in analgesic quality, dexmedetomidine can prolong the analgesic time and provide stronger sedation.¹³⁴ This is not completely consistent with Jiang's results, indicating that 10 mg nalbuphine has significantly shorter sensory and motor block onset time, longer block duration, less analgesic need, and fewer side effects than 0.75 µg/kg dexmedetomidine.¹³⁵ Rao et al¹³⁶ results are also different from the above. As an adjuvant to ropivacaine in ESPB, 20 mg nalbuphine and 1 µg/kg dexmedetomidine are comparable in terms of the associated analgesia, sensory block duration, need for rescue analgesia, and incidence of chronic pain.

Therefore, the results of nalbuphine and dexmedetomidine as adjuvants are inconsistent, likely due to the type of nerve block and the concentration of the two drugs, as we discovered that most comparisons were produced at different doses.

Dexmedetomidine vs Dexamethasone

Singh et al¹⁷ discovered that 1 µg/kg dexmedetomidine and 8 mg dexamethasone when used as adjuvants to ropivacaine for SCBP block, delay onset time and prolong block duration. In the comparative meta-analysis of the two drugs, Song et al¹³⁷ concluded that the analgesic effects of dexamethasone and dexmedetomidine in peripheral nerve blocks are equivalent. Venkatraman's research results present different views. In brachial plexus block, 8 mg dexamethasone is an ideal adjuvant to ropivacaine to prolong postoperative analgesia without adverse effects. However, 50 µg dexmedetomidine has a quicker sensory and motor blockade onset.⁵³ Yaghoobi et al¹³⁸ discovered no significant difference in postoperative pain intensity between the 8 mg Dexamethasone and 1 µg/kg dexmedetomidine. However, dexmedetomidine demonstrated a longer sensory block duration than dexamethasone as a lidocaine adjuvant in the infraclavicular block. We consider that the dose may be the most important factor affecting the results.

Dexmedetomidine vs MgSO₄

The comparison results of Shukla et al^{139,140} and Elyazed et al¹⁴⁰ on dexmedetomidine and magnesium sulfate are similar. The results proved that dexmedetomidine provides earlier onset of the sensory and motor block and prolonged duration of sensory and motor blocks and duration of analgesia is longer, and postoperative rescue analgesia is less compared to patients receiving MgSO₄. However, the incidence of hypotension and bradycardia was higher with dexmedetomidine.

Dexmedetomidine vs Others

Ghasemifa et al¹⁴¹ identified that 5 µg/mL sufentanil is superior to 100 µg/mL dexmedetomidine in analgesia, contrary to Dharmarao et al.¹²² The most likely explanation is the difference between concentration and dose. Additionally, the efficacy of sufentanil and fentanyl differs.

Song et al¹⁴² identified that perineural 1 µg/kg dexmedetomidine prolonged nerve block duration similarly to 200 µg epinephrine but slowed heart rate. Mirkheshti et al¹⁴³ found that dexmedetomidine had better effects on sensory and motor block duration and onset than ketorolac, as lidocaine adjuvants in infraclavicular brachial plexus block were present in both protocols.

Recommendations for Peripheral Nerve Blocks

The optimal dose of dexmedetomidine as an adjuvant in peripheral nerve block depends on the dose, the block location, the concentration and dose of the local anesthetic drug, surgical method, population, and other factors. Additionally, the choice of dose varies according to the investigator's purpose.

Based on numerous meta-analyses and clinical studies results, we revealed that a dexmedetomidine dose greater than 50 µg has great potential for clinicians who want to accelerate the onset of action and prolong the duration of peripheral nerve anesthesia.^{144,145} The peripheral effect of dexmedetomidine is dose-dependent, and 100 µg dexmedetomidine has more advantages in prolonging the block time.¹⁴⁵

Many studies have established that the maximum safe dose of dexmedetomidine is 2 µg/kg, and the duration of continuous analgesia is the longest, but the incidence of hypotension is higher in 1.5–2 µg/kg dexmedetomidine.¹⁴⁵ Thus, a dose of dexmedetomidine of 1 µg/kg provides an optimal balance between adequate postoperative analgesia and the adverse effects of peripheral nerve block.^{50,146}

Summarize

As early as 1902, American neurosurgeon Cushing proposed the definition of “local anesthesia” and the technology of combined application of local anesthesia and general anesthesia to control perioperative stress response, reduce drug dosage of general anesthesia, and control postoperative pain. Recently, the popularization of ERAS and Multimodal Analgesia (MMA) has raised higher requirements for perioperative management. Therefore, PNB technology has been widely used in clinical practice. Anesthesiologists have focused on applying PNB as an adjuvant of LA around nerves to increase the analgesic effect and duration of PNB.

Currently, the advantages and limitations of adjuvants have been widely discussed.¹⁴⁷ Adjuvants are widely used in clinical practice to prolong the duration of anesthesia/analgesia, stabilize hemodynamics, reduce postoperative pain, and reduce postoperative complications. However, their clinical use in most cases has not been ethically reviewed and demonstrated, with the unclear definition of possible neurotoxicity and systemic adverse effects. Therefore, any anesthesiologist should obtain the patient's informed consent before adding adjuvants and assess the risks and benefits adequately.

A recent meta-analysis of dexmedetomidine as an adjuvant demonstrated that it had achieved good clinical efficacy in PNB. It can reduce the use of LA and analgesic drugs. Simultaneously, it can improve the effect of analgesia, extend the time of analgesia, and improve the quality of anesthesia and patient satisfaction.^{148,149} However, it is undeniable that many studies support the possible hypotension, bradycardia, and excessive sedation caused by dexmedetomidine as an adjuvant, so the risks and benefits of adding dexmedetomidine should be carefully weighed.^{150,151}

As previously stated, sufficient evidence presents that dexmedetomidine as an adjuvant has apparent advantages in brachial plexus block, paravertebral block, and transverse abdominis plane block, manifesting as prolonged analgesia time. These studies were mainly based on adult patients. We discovered a few clinical studies on nerve block in children with dexmedetomidine as an adjuvant, including transversus abdominis plane block,^{152,153} greater palatine nerve block,¹⁵⁴ retrobulbar nerve block,¹⁵⁵ and caudal blockade.¹⁵⁶ Based on the results, dexmedetomidine as a local anesthetic adjuvant for other nerve blocks in children is also worth trying and promoting.

However, the optimal dose of dexmedetomidine for clinical applications needs further study. Although possible neurotoxicity is rarely reported in clinical practice, neurotoxicity in animal studies requires further research and consideration. Finally, intravenous versus perineural administration of dexmedetomidine is controversial; therefore, additional clinical studies and evidence-based medical evidence are needed.

Ethical Approval

No ethical approval was required for the review.

Acknowledgments

We thank Figdraw (www.figdraw.com) for expert assistance in Figure 1.

Funding

The present study was supported by grants from 2021 Shandong Medical Association Clinical Research Fund-Qilu Special Project YXH2022ZX02079.

Disclosure

The authors report no conflicts of interest in this work.

References

1. Spirling LI, Daniels IR. William Stewart Halsted—surgeon extraordinaire: a story of ‘drugs, gloves and romance’. *J R Soc Promot Health*. 2002;122(2):122–124. doi:10.1177/146642400212200215
2. Zhang JW, Feng XY, Yang J, Wang ZH, Wang Z, Bai LP. Ultrasound-guided single thoracic paravertebral nerve block and erector spinae plane block for perioperative analgesia in thoracoscopic pulmonary lobectomy: a randomized controlled trial. *Insights Imaging*. 2022;13(1):16. doi:10.1186/s13244-021-01151-x
3. Sessler DI, Pei L, Huang Y, et al. Recurrence of breast cancer after regional or general anaesthesia: a randomised controlled trial. *Lancet*. 2019;394(10211):1807–1815. doi:10.1016/s0140-6736(19)32313-x
4. Aveline C, Le Hetet H, Le Roux A, et al. Perineural ultrasound-guided catheter bacterial colonization: a prospective evaluation in 747 cases. *Reg Anesth Pain Med*. 2011;36(6):579–584. doi:10.1097/AAP.0b013e31822e665a
5. Bowens C Jr, Briggs ER, Malchow RJ. Brachial plexus entrapment of interscalene nerve catheter after uncomplicated ultrasound-guided placement. *Pain Med*. 2011;12(7):1117–1120. doi:10.1111/j.1526-4637.2011.01177.x
6. Opperer M, Gerner P, Memtsoudis SG. Additives to local anesthetics for peripheral nerve blocks or local anesthesia: a review of the literature. *Pain Manag*. 2015;5(2):117–128. doi:10.2217/pmt.15.2
7. Lundblad M, Trifa M, Kaabachi O, et al. Alpha-2 adrenoceptor agonists as adjuncts to peripheral nerve blocks in children: a meta-analysis. *Paediatr Anaesth*. 2016;26(3):232–238. doi:10.1111/pan.12825
8. Xuan C, Yan W, Wang D, et al. The facilitatory effects of adjuvant pharmaceuticals to prolong the duration of local anesthetic for peripheral nerve block: a systematic review and network meta-analysis. *Anesth Analg*. 2021;133(3):620–629. doi:10.1213/ane.0000000000005640
9. Edinoff AN, Houk GM, Patil S, et al. Adjuvant drugs for peripheral nerve blocks: the role of alpha-2 agonists, dexamethasone, midazolam, and non-steroidal anti-inflammatory drugs. *Anesth Pain Med*. 2021;11(3):e117197. doi:10.5812/aapm.117197
10. Kirksey MA, Haskins SC, Cheng J, Liu SS, Schwentner C. Local anesthetic peripheral nerve block adjuvants for prolongation of analgesia: a systematic qualitative review. *PLoS One*. 2015;10(9):e0137312. doi:10.1371/journal.pone.0137312
11. Werdehausen R, Braun S, Hermanns H, et al. The influence of adjuvants used in regional anesthesia on lidocaine-induced neurotoxicity in vitro. *Reg Anesth Pain Med*. 2011;36(5):436–443. doi:10.1097/AAP.0b013e318226ba62
12. Dawson RL, McLeod DH, Koerber JP, Plummer JL, Dracopoulos GC. A randomised controlled trial of perineural vs intravenous dexamethasone for foot surgery. *Anaesthesia*. 2016;71(3):285–290. doi:10.1111/anae.13346
13. Lee IO, Kim WK, Kong MH, et al. No enhancement of sensory and motor blockade by ketamine added to ropivacaine interscalene brachial plexus blockade. *Acta Anaesthesiol Scand*. 2002;46(7):821–826. doi:10.1034/j.1399-6576.2002.460711.x
14. Neal JM, Rathmell JP, Rowlingson JC. Publishing studies that involve “off-label” use of drugs: formalizing regional anesthesia and pain medicine’s policy. *Reg Anesth Pain Med*. 2009;34(5):391–392. doi:10.1097/AAP.0b013e3181b87066
15. Bilotta F, Pugliese F. The evolving clinical use of dexmedetomidine. *Lancet*. 2020;396(10245):145–147. doi:10.1016/s0140-6736(20)30902-8
16. Rancourt MP, Albert NT, Côté M, Létourneau DR, Bernard PM. Posterior tibial nerve sensory blockade duration prolonged by adding dexmedetomidine to ropivacaine. *Anesth Analg*. 2012;115(4):958–962. doi:10.1213/ANE.0b013e318265bab7
17. Singh N, Gupta S, Kathuria S. Dexmedetomidine vs dexamethasone as an adjuvant to 0.5% ropivacaine in ultrasound-guided supraclavicular brachial plexus block. *J Anaesthesiol Clin Pharmacol*. 2020;36(2):238–243. doi:10.4103/joacp.JOACP_176_19
18. Segal IS, Vickery RG, Walton JK, Doze VA, Maze M. Dexmedetomidine diminishes halothane anesthetic requirements in rats through a postsynaptic alpha 2 adrenergic receptor. *Anesthesiology*. 1988;69(6):818–823. doi:10.1097/0000542-198812000-00004
19. Gertler R, Brown HC, Mitchell DH, Silvius EN. Dexmedetomidine: a novel sedative-analgesic agent. *Proc*. 2001;14(1):13–21. doi:10.1080/08998280.2001.11927725
20. Ebert TJ, Hall JE, Barney JA, Uhrich TD, Colino MD. The effects of increasing plasma concentrations of dexmedetomidine in humans. *Anesthesiology*. 2000;93(2):382–394. doi:10.1097/0000542-200008000-00016
21. Knaus AE, Muthig V, Schickinger S, et al. Alpha2-adrenoceptor subtypes--unexpected functions for receptors and ligands derived from gene-targeted mouse models. *Neurochem Int*. 2007;51(5):277–281. doi:10.1016/j.neuint.2007.06.036
22. Guo TZ, Jiang JY, Buttermann AE, Maze M. Dexmedetomidine injection into the locus ceruleus produces antinociception. *Anesthesiology*. 1996;84(4):873–881. doi:10.1097/0000542-199604000-00015
23. Jaakola ML, Salonen M, Lehtinen R, Scheinin H. The analgesic action of dexmedetomidine--a novel alpha 2-adrenoceptor agonist--in healthy volunteers. *Pain*. 1991;46(3):281–285. doi:10.1016/0304-3959(91)90111-a
24. Ishii H, Kohno T, Yamakura T, Ikoma M, Baba H. Action of dexmedetomidine on the substantia gelatinosa neurons of the rat spinal cord. *Eur J Neurosci*. 2008;27(12):3182–3190. doi:10.1111/j.1460-9568.2008.06260.x
25. Angst MS, Ramaswamy B, Davies MF, Maze M. Comparative analgesic and mental effects of increasing plasma concentrations of dexmedetomidine and alfentanil in humans. *Anesthesiology*. 2004;101(3):744–752. doi:10.1097/0000542-200409000-00024

26. Brummett CM, Amodeo FS, Janda AM, Padda AK, Lydic R. Perineural dexmedetomidine provides an increased duration of analgesia to a thermal stimulus when compared with a systemic control in a rat sciatic nerve block. *Reg Anesth Pain Med*. 2010;35(5):427–431. doi:10.1097/AAP.0b013e3181ef4cf0
27. Marhofer D, Kettner SC, Marhofer P, Pils S, Weber M, Zeitlinger M. Dexmedetomidine as an adjuvant to ropivacaine prolongs peripheral nerve block: a volunteer study. *Br J Anaesth*. 2013;110(3):438–442. doi:10.1093/bja/aes400
28. Brummett CM, Hong EK, Janda AM, Amodeo FS, Lydic R. Perineural dexmedetomidine added to ropivacaine for sciatic nerve block in rats prolongs the duration of analgesia by blocking the hyperpolarization-activated cation current. *Anesthesiology*. 2011;115(4):836–843. doi:10.1097/ALN.0b013e318221fcc9
29. Shirasaka T, Kannan H, Takasaki M. Activation of a G protein-coupled inwardly rectifying K⁺ current and suppression of I_h contribute to dexmedetomidine-induced inhibition of rat hypothalamic paraventricular nucleus neurons. *Anesthesiology*. 2007;107(4):605–615. doi:10.1097/01.anes.0000281916.65365.4e
30. Pape HC. Queer current and pacemaker: the hyperpolarization-activated cation current in neurons. *Annu Rev Physiol*. 1996;58:299–327. doi:10.1146/annurev.ph.58.030196.001503
31. Marhofer P, Brummett CM. Safety and efficiency of dexmedetomidine as adjuvant to local anesthetics. *Curr Opin Anaesthesiol*. 2016;29(5):632–637. doi:10.1097/aco.0000000000000364
32. Chen BS, Peng H, Wu SN. Dexmedetomidine, an alpha2-adrenergic agonist, inhibits neuronal delayed-rectifier potassium current and sodium current. *Br J Anaesth*. 2009;103(2):244–254. doi:10.1093/bja/aep107
33. Memiş D, Turan A, Karamanlioğlu B, Pamukçu Z, Kurt I. Adding dexmedetomidine to lidocaine for intravenous regional anesthesia. *Anesth Analg*. 2004;98(3):835–840, table of contents. doi:10.1213/01.ane.0000100680.77978.66
34. Kosugi T, Mizuta K, Fujita T, Nakashima M, Kumamoto E. High concentrations of dexmedetomidine inhibit compound action potentials in frog sciatic nerves without alpha(2) adrenoceptor activation. *Br J Pharmacol*. 2010;160(7):1662–1676. doi:10.1111/j.1476-5381.2010.00833.x
35. Dalle C, Schneider M, Clergue F, Bretton C, Jirounek P. Inhibition of the I(h) current in isolated peripheral nerve: a novel mode of peripheral antinociception? *Muscle Nerve*. 2001;24(2):254–261. doi:10.1002/1097-4598(200102)24:2<254::aid-mus110>3.0.co;2-#
36. Weerink MAS, Struys M, Hannivoort LN, Barends CRM, Absalom AR, Colin P. Clinical pharmacokinetics and pharmacodynamics of dexmedetomidine. *Clin Pharmacokinet*. 2017;56(8):893–913. doi:10.1007/s40262-017-0507-7
37. Gaumann DM, Brunet PC, Jirounek P. Hyperpolarizing afterpotentials in C fibers and local anesthetic effects of clonidine and lidocaine. *Pharmacology*. 1994;48(1):21–29. doi:10.1159/000139158
38. Erne-Brand F, Jirounek P, Drewe J, Hampl K, Schneider MC. Mechanism of antinociceptive action of clonidine in non myelinated nerve fibres. *Eur J Pharmacol*. 1999;383(1):1–8. doi:10.1016/s0014-2999(99)00620-2
39. Han M, Kang F, Yang C, et al. Comparison of adrenaline and dexmedetomidine in improving the cutaneous analgesia of mexiletine in response to skin pinpricks in rats. *Pharmacology*. 2020;105(11–12):662–668. doi:10.1159/000506487
40. Shaikh SI, Revur LR, Mallappa M. Comparison of epidural clonidine and dexmedetomidine for perioperative analgesia in combined spinal epidural anesthesia with intrathecal levobupivacaine: a randomized controlled double-blind study. *Anesth Essays Res*. 2017;11(2):503–507. doi:10.4103/aer.AER_255_16
41. Nguyen V, Tiemann D, Park E, Salehi A. Alpha-2 agonists. *Anesthesiol Clin*. 2017;35(2):233–245. doi:10.1016/j.anclin.2017.01.009
42. She YJ, Zhang ZY, Song XR. Caudal dexmedetomidine decreases the required concentration of levobupivacaine for caudal block in pediatric patients: a randomized trial. *Paediatr Anaesth*. 2013;23(12):1205–1212. doi:10.1111/pan.12278
43. Pöpping DM, Elia N, Marret E, Wenk M, Tramèr MR. Clonidine as an adjuvant to local anesthetics for peripheral nerve and plexus blocks: a meta-analysis of randomized trials. *Anesthesiology*. 2009;111(2):406–415. doi:10.1097/ALN.0b013e3181aae897
44. Biswas S, Das RK, Mukherjee G, Ghose T. Dexmedetomidine an adjuvant to levobupivacaine in supraclavicular brachial plexus block: a randomized double blind prospective study. *Ethiop J Health Sci*. 2014;24(3):203–208. doi:10.4314/ejhs.v24i3.3
45. El Sherif FA, Abdel-Ghaffar H, Othman A, et al. Pharmacokinetics and pharmacodynamics of dexmedetomidine administered as an adjunct to bupivacaine for transversus abdominis plane block in patients undergoing lower abdominal cancer surgery. *J Pain Res*. 2022;15:1–12. doi:10.2147/jpr.S335806
46. Abdallah FW, Dwyer T, Chan VW, et al. IV and perineural dexmedetomidine similarly prolong the duration of analgesia after interscalene brachial plexus block: a randomized, three-arm, triple-masked, placebo-controlled trial. *Anesthesiology*. 2016;124(3):683–695. doi:10.1097/aln.0000000000000983
47. Haber HP, Sinis N, Haerle M, Schaller HE. Sonography of brachial plexus traction injuries. *AJR Am J Roentgenol*. 2006;186(6):1787–1791. doi:10.2214/ajr.04.1861
48. Bharti N, Sardana DK, Bala I. The analgesic efficacy of dexmedetomidine as an adjunct to local anesthetics in supraclavicular brachial plexus block: a randomized controlled trial. *Anesth Analg*. 2015;121(6):1655–1660. doi:10.1213/ane.0000000000001006
49. Nazir N, Jain S, Randomized Controlled A. Trial study on the effect of adding dexmedetomidine to bupivacaine in supraclavicular block using ultrasound guidance. *Ethiop J Health Sci*. 2016;26(6):561–566. doi:10.4314/ejhs.v26i6.9
50. Reddy BS, Gaude YK, Vaidya S, Kini GK, Budania LS, Eeshwar MV. Effect of dexmedetomidine on characteristics of ultrasound-guided supraclavicular brachial plexus block with levobupivacaine-A prospective double-blind randomized controlled trial. *J Anaesthesiol Clin Pharmacol*. 2021;37(3):371–377. doi:10.4103/joacp.JOACP_289_18
51. Sane S, Shokouhi S, Golabi P, Rezaeian M, Kazemi Haki B, Ushida T. The effect of dexmedetomidine in combination with bupivacaine on sensory and motor block time and pain score in supraclavicular block. *Pain Res Manag*. 2021;2021:8858312. doi:10.1155/2021/8858312
52. Jung HS, Seo KH, Kang JH, Jeong JY, Kim YS, Han NR. Optimal dose of perineural dexmedetomidine for interscalene brachial plexus block to control postoperative pain in patients undergoing arthroscopic shoulder surgery: a prospective, double-blind, randomized controlled study. *Medicine*. 2018;97(16):e0440. doi:10.1097/md.00000000000010440
53. Venkatraman R, Pushparani A, Karthik K, Nandhini P. Comparison of morphine, dexmedetomidine and dexamethasone as an adjuvant to ropivacaine in ultrasound-guided supraclavicular brachial plexus block for postoperative analgesia-a randomized controlled trial. *J Anaesthesiol Clin Pharmacol*. 2021;37(1):102–107. doi:10.4103/joacp.JOACP_70_19
54. Andersen JH, Karlsen A, Geisler A, et al. Alpha(2) -receptor agonists as adjuvants for brachial plexus nerve blocks-a systematic review with meta-analyses. *Acta Anaesthesiol Scand*. 2022;66(2):186–206. doi:10.1111/aas.14002

55. Sehmbi H, Brull R, Ceballos KR, et al. Perineural and intravenous dexamethasone and dexmedetomidine: network meta-analysis of adjunctive effects on supraclavicular brachial plexus block. *Anaesthesia*. 2021;76(7):974–990. doi:10.1111/anae.15288
56. Samar P, Dhawale TA, Pandya S. Comparative study of intravenous dexmedetomidine sedation with perineural dexmedetomidine on supraclavicular approach brachial plexus block in upper limb orthopaedic surgery. *Cureus*. 2020;12(10):e10768. doi:10.7759/cureus.10768
57. Somsunder RG, Archana NB, Shivkumar G, Krishna K. Comparing efficacy of perineural dexmedetomidine with intravenous dexmedetomidine as adjuvant to levobupivacaine in supraclavicular brachial plexus block. *Anesth Essays Res*. 2019;13(3):441–445. doi:10.4103/aer.AER_105_19
58. Gustafson KJ, Grinberg Y, Joseph S, Triolo RJ. Human distal sciatic nerve fascicular anatomy: implications for ankle control using nerve-cuff electrodes. *J Rehabil Res Dev*. 2012;49(2):309–321. doi:10.1682/jrrd.2010.10.0201
59. Brummett CM, Norat MA, Palmisano JM, Lydic R. Perineural administration of dexmedetomidine in combination with bupivacaine enhances sensory and motor blockade in sciatic nerve block without inducing neurotoxicity in rat. *Anesthesiology*. 2008;109(3):502–511. doi:10.1097/ALN.0b013e318182c26b
60. Marolf V, Ida KK, Siluk D, Struck-Lewicka W, Markuszewski MJ, Sandersen C. Effects of perineural administration of ropivacaine combined with perineural or intravenous administration of dexmedetomidine for sciatic and saphenous nerve blocks in dogs. *Am J Vet Res*. 2021;82(6):449–458. doi:10.2460/ajvr.82.6.449
61. Taylan SB, Bariskaner H. Effects of dexmedetomidine and dexketoprofen on the conduction block of rat sciatic nerve. *Neural Regen Res*. 2020;15(5):929–935. doi:10.4103/1673-5374.268926
62. Helal SM, Eskandr AM, Gaballah KM, Gaarour IS. Effects of perineural administration of dexmedetomidine in combination with bupivacaine in a femoral-sciatic nerve block. *Saudi J Anaesth*. 2016;10(1):18–24. doi:10.4103/1658-354x.169469
63. Chaudhary SK, Verma RK, Rana S, Singh J, Gupta B, Singh Y. Ultrasound-guided femoro-sciatic nerve block for post-operative analgesia after below knee orthopaedic surgeries under subarachnoid block: comparison between clonidine and dexmedetomidine as adjuvants to levobupivacaine. *Indian J Anaesth*. 2016;60(7):484–490. doi:10.4103/0019-5049.186027
64. Jin XB, Xiao R, Zhou W, et al. Effect of different modes of administration of dexmedetomidine combined with nerve block on postoperative analgesia in total knee arthroplasty. *Pain Ther*. 2021;10(2):1649–1662. doi:10.1007/s40122-021-00320-6
65. Yu J, Shan S, Nie Y. Impact of local administration of various doses of dexmedetomidine on ropivacaine-induced lumbar plexus-sciatic nerve block. *Exp Ther Med*. 2018;16(2):711–717. doi:10.3892/etm.2018.6218
66. Wang CG, Ding YL, Han AP, et al. Adding dexmedetomidine to ropivacaine for lumbar plexus and sciatic nerve block for amputation of lower limb in high-risk patient-a case report. *Int J Clin Exp Med*. 2015;8(8):14184–14187.
67. Hu X, Li J, Zhou R, et al. Dexmedetomidine added to local anesthetic mixture of lidocaine and ropivacaine enhances onset and prolongs duration of a popliteal approach to sciatic nerve blockade. *Clin Ther*. 2017;39(1):89–97.e81. doi:10.1016/j.clinthera.2016.11.011
68. Sharma B, Rupal S, Swami AC, Lata S. Effect of addition of dexmedetomidine to ropivacaine 0.2% for femoral nerve block in patients undergoing unilateral total knee replacement: a randomised double-blind study. *Indian J Anaesth*. 2016;60(6):403–408. doi:10.4103/0019-5049.183392
69. Packiasabapathy SK, Kashyap L, Arora MK, et al. Effect of dexmedetomidine as an adjuvant to bupivacaine in femoral nerve block for perioperative analgesia in patients undergoing total knee replacement arthroplasty: a dose-response study. *Saudi J Anaesth*. 2017;11(3):293–298. doi:10.4103/sja.SJA_624_16
70. Abdulatif M, Fawzy M, Nassar H, Hasanin A, Ollaek M, Mohamed H. The effects of perineural dexmedetomidine on the pharmacodynamic profile of femoral nerve block: a dose-finding randomised, controlled, double-blind study. *Anaesthesia*. 2016;71(10):1177–1185. doi:10.1111/anae.13603
71. Li J, Wang H, Dong B, Ma J, Wu X. Adding dexmedetomidine to ropivacaine for femoral nerve block inhibits local inflammatory response. *Minerva Anesthesiol*. 2017;83(6):590–597. doi:10.23736/s0375-9393.17.11430-6
72. Xiao R, Liu LF, Luo YR, et al. Dexmedetomidine combined with femoral nerve block provides effective analgesia similar to femoral nerve combined with sciatic nerve block in patients undergoing total knee arthroplasty: a randomized controlled study. *Drug Des Devel Ther*. 2022;16:155–164. doi:10.2147/dddt.S334415
73. Goel CP, Desai S. Efficacy of dexmedetomidine as an adjuvant in femoral nerve block for post-op pain relief in hip surgery: a prospective randomized double-blind controlled study. *J Anaesthesiol Clin Pharmacol*. 2021;37(3):383–388. doi:10.4103/joacp.JOACP_182_19
74. Karmakar MK, Kwok WH, Kew J. Thoracic paravertebral block: radiological evidence of contralateral spread anterior to the vertebral bodies. *Br J Anaesth*. 2000;84(2):263–265. doi:10.1093/oxfordjournals.bja.a013417
75. Singh S, Jacob M, Hasnain S, Krishnakumar M. Comparison between continuous thoracic epidural block and continuous thoracic paravertebral block in the management of thoracic trauma. *Med J Armed Forces India*. 2017;73(2):146–151. doi:10.1016/j.mjafi.2016.11.005
76. Ding W, Chen Y, Li D, et al. Investigation of single-dose thoracic paravertebral analgesia for postoperative pain control after thoracoscopic lobectomy - a randomized controlled trial. *Int J Surg*. 2018;57:8–14. doi:10.1016/j.ijsu.2018.07.006
77. Mohamed SA, Fares KM, Mohamed AA, Alieldin NH. Dexmedetomidine as an adjunctive analgesic with bupivacaine in paravertebral analgesia for breast cancer surgery. *Pain Physician*. 2014;17(5):E589–E598.
78. Mohta M, Kalra B, Sethi AK, Kaur N. Efficacy of dexmedetomidine as an adjuvant in paravertebral block in breast cancer surgery. *J Anesth*. 2016;30(2):252–260. doi:10.1007/s00540-015-2123-8
79. Zha J, Ji S, Wang C, Yang Z, Qiao S, An J. Thoracic paravertebral nerve block with ropivacaine and adjuvant dexmedetomidine produced longer analgesia in patients undergoing video-assisted thoracoscopic lobectomy: a randomized trial. *J Healthc Eng*. 2021;2021:1846886. doi:10.1155/2021/1846886
80. Guo F, Chen H, Cai X, Ge J, Du B, Song J. Effects of dexmedetomidine as an adjuvant in thoracic paravertebral block on EC50 of propofol for successful laryngeal mask insertion: a randomized controlled trial. *Ann Transl Med*. 2020;8(22):1480. doi:10.21037/atm-20-5174
81. Biçer C, Ünal EN, Aksu R, Önal Ö, Güneş I. Adicão de dexmedetomidina à bupivacaína em bloqueio paravertebral guiado por ultrassom potencializa o alívio da dor pós-operatória em pacientes submetidos à toracotomia [Addition of dexmedetomidine to bupivacaine in ultrasonography-guided paravertebral blockade potentiates postoperative pain relief among patients undergoing thoracotomy]. *Braz J Anesthesiol*. 2019;69(2):144–151. Turkish. doi:10.1016/j.bjan.2018.11.002
82. McDonnell JG, O'Donnell BD, Farrell T, et al. Transversus abdominis plane block: a cadaveric and radiological evaluation. *Reg Anesth Pain Med*. 2007;32(5):399–404. doi:10.1016/j.rapm.2007.03.011

83. Yang P, Luo Y, Lin L, Zhang H, Liu Y, Li Y. The efficacy of transversus abdominis plane block with or without dexmedetomidine for postoperative analgesia in renal transplantation. A randomized controlled trial. *Int J Surg.* **2020**;79:196–201. doi:10.1016/j.ijssu.2020.05.073
84. Qian H, Zhang Q, Zhu P, et al. Ultrasound-guided transversus abdominis plane block using ropivacaine and dexmedetomidine in patients undergoing caesarian sections to relieve post-operative analgesia: a randomized controlled clinical trial. *Exp Ther Med.* **2020**;20(2):1163–1168. doi:10.3892/etm.2020.8781
85. Joseph B, Zachariah SK, Abraham SP. The comparison of effects of fentanyl and dexmedetomidine as adjuvants to ropivacaine for ultrasound-guided transversus abdominis plane block for postoperative pain in cesarean section under spinal anesthesia -A randomized controlled trial. *J Anaesthesiol Clin Pharmacol.* **2020**;36(3):377–380. doi:10.4103/joacp.JOACP_313_18
86. Varshney A, Prabhu M, Periyadka B, Nanjundegowda DC, Rao A. Transversus abdominis plane (TAP) block with levobupivacaine versus levobupivacaine with dexmedetomidine for postoperative analgesia following cesarean delivery. *J Anaesthesiol Clin Pharmacol.* **2019**;35(2):161–164. doi:10.4103/joacp.JOACP_372_17
87. Madangopal RM, Dang A, Aggarwal M, Kumar J. A comparative evaluation of different doses of dexmedetomidine as an adjuvant to bupivacaine in transversus abdominis plane block for postoperative analgesia in unilateral inguinal hernioplasty. *J Anaesthesiol Clin Pharmacol.* **2020**;36(3):398–406. doi:10.4103/joacp.JOACP_26_19
88. Zeng Y, Wen Y, Yang J, Sun H. Comparing post-operative analgesic effects of varying doses of dexmedetomidine as an adjuvant to ropivacaine for ultrasound-guided dual transversus abdominis plane block following laparotomy for gynecologic malignancies. *Exp Ther Med.* **2020**;20(2):860–867. doi:10.3892/etm.2020.8787
89. Karasu D, Yilmaz C, Ozgunay SE, Yalcin D, Ozkaya G. Ultrasound-guided transversus abdominis plane block for postoperative analgesia in laparoscopic cholecystectomy: a retrospective study. *North Clin Istanbul.* **2021**;8(1):88–94. doi:10.14744/nci.2020.84665
90. Mostafa MF, Hamed E, Amin AH, Herdan R. Dexmedetomidine versus clonidine adjuvants to levobupivacaine for ultrasound-guided transversus abdominis plane block in paediatric laparoscopic orchiopexy: randomized, double-blind study. *Eur J Pain.* **2021**;25(2):497–507. doi:10.1002/ejp.1689
91. Kim JS, Ko JS, Bang S, Kim H, Lee SY. Cervical plexus block. *Korean J Anesthesiol.* **2018**;71(4):274–288. doi:10.4097/kja.d.18.00143
92. Colegrave N, Mascitti P, Zannis K, et al. Ultrasound-guided intermediate cervical plexus block for transcatheter aortic valve replacement. *J Cardiothorac Vasc Anesth.* **2021**;35(6):1747–1750. doi:10.1053/j.jvca.2020.08.053
93. Mađro P, Dąbrowska A, Jarecki J, Garba P. Anaesthesia for carotid endarterectomy. Ultrasound-guided superficial/intermediate cervical plexus block combined with carotid sheath infiltration. *Anaesthesiol Intensive Ther.* **2016**;48(4):234–238. doi:10.5603/ait.2016.0043
94. Santosh BS, Mehandale SG. Does dexmedetomidine improve analgesia of superficial cervical plexus block for thyroid surgery? *Indian J Anaesth.* **2016**;60(1):34–38. doi:10.4103/0019-5049.174797
95. Lin YN, Li Q, Yang RM, Mao ZX, Liu JC. Addition of dexmedetomidine to ropivacaine improves cervical plexus block. *Acta Anaesthesiol Taiwan.* **2013**;51(2):63–66. doi:10.1016/j.aat.2013.06.001
96. Elmaddawy AEA, Mazy AE. Ultrasound-guided bilateral superficial cervical plexus block for thyroid surgery: the effect of dexmedetomidine addition to bupivacaine-epinephrine. *Saudi J Anaesth.* **2018**;12(3):412–418. doi:10.4103/sja.SJA_653_17
97. Rokhtabnak F, Sayad S, Izadi M, Djalali Motlagh S, Rahimzadeh P. Pain control after mastectomy in transgender patients: ultrasound-guided pectoral nerve block II versus conventional intercostal nerve block: a randomized clinical trial. *Anesth Pain Med.* **2021**;11(5):e119440. doi:10.5812/aapm.119440
98. Zhang P, Liu S, Zhu J, Rao Z, Liu C. Dexamethasone and dexmedetomidine as adjuvants to local anesthetic mixture in intercostal nerve block for thoracoscopic pneumonectomy: a prospective randomized study. *Reg Anesth Pain Med.* **2019**. doi:10.1136/rapm-2018-100221
99. Yao F, Xu S, Zhang W, Xiong H, Han J, Zhu A. Impacts of different administration modes of dexmedetomidine with 0.5% ropivacaine on intercostal nerve block. *Ann Palliat Med.* **2020**;9(2):447–450. doi:10.21037/apm.2020.03.25
100. Mayes J, Davison E, Panahi P, et al. An anatomical evaluation of the serratus anterior plane block. *Anaesthesia.* **2016**;71(9):1064–1069. doi:10.1111/anae.13549
101. Abdallah NM, Bakeer AH, Youssef RB, Zaki HV, Abbas DN. Ultrasound-guided continuous serratus anterior plane block: dexmedetomidine as an adjunctive analgesic with levobupivacaine for post-thoracotomy pain. A prospective randomized controlled study. *J Pain Res.* **2019**;12:1425–1431. doi:10.2147/jpr.S195431
102. Kuang MJ, Xu LY, Ma JX, et al. Adductor canal block versus continuous femoral nerve block in primary total knee arthroplasty: a meta-analysis. *Int J Surg.* **2016**;31:17–24. doi:10.1016/j.ijssu.2016.05.036
103. Goyal R, Mittal G, Yadav AK, Sethi R, Chattopadhyay A. Adductor canal block for post-operative analgesia after simultaneous bilateral total knee replacement: a randomised controlled trial to study the effect of addition of dexmedetomidine to ropivacaine. *Indian J Anaesth.* **2017**;61(11):903–909. doi:10.4103/ija.IJA_277_17
104. Herman J, Urits I, Eskander J, Kaye A, Viswanath O. Adductor canal block duration of analgesia successfully prolonged with perineural dexmedetomidine and dexamethasone in addition to IPACK block for total knee arthroplasty. *Cureus.* **2020**;12(9):e10566. doi:10.7759/cureus.10566
105. Wang C, Zhang Z, Ma W, Liu R, Li Q, Li Y. Perineural dexmedetomidine reduces the median effective concentration of ropivacaine for adductor canal block. *Med Sci Monit.* **2021**;27:e929857. doi:10.12659/msm.929857
106. Thapa D, Ahuja V, Pandey K, Gombor S, Gupta R. Evaluation of analgesic efficacy of dexmedetomidine as adjuvant with ropivacaine in ultrasound-guided adductor canal block in patients following anterior cruciate ligament reconstruction surgeries. *Br J Pain.* **2019**;13(2):91–98. doi:10.1177/2049463718796865
107. Forero M, Adhikary SD, Lopez H, Tsui C, Chin KJ. The erector spinae plane block: a novel analgesic technique in thoracic neuropathic pain. *Reg Anesth Pain Med.* **2016**;41(5):621–627. doi:10.1097/aap.0000000000000451
108. Hung KC, Liao SW, Sun CK. Comparable analgesic efficacy between erector spinae plane and thoracic paravertebral blocks for breast and thoracic surgeries? *J Clin Anesth.* **2021**;71:110200. doi:10.1016/j.jclinane.2021.110200
109. Saadawi M, Layera S, Aliste J, Bravo D, Leurcharusmee P, Tran Q. Erector spinae plane block: a narrative review with systematic analysis of the evidence pertaining to clinical indications and alternative truncal blocks. *J Clin Anesth.* **2021**;68:110063. doi:10.1016/j.jclinane.2020.110063

110. Wang Q, Li H, Wei S, et al. Dexmedetomidine added to ropivacaine for ultrasound-guided erector spinae plane block prolongs analgesia duration and reduces perioperative opioid consumption after thoracotomy: a randomized, controlled clinical study. *Clin J Pain*. 2021;38(1):8–14. doi:10.1097/ajp.0000000000000992
111. Wang X, Ran G, Chen X, et al. The effect of ultrasound-guided erector spinae plane block combined with dexmedetomidine on postoperative analgesia in patients undergoing modified radical mastectomy: a randomized controlled trial. *Pain Ther*. 2021;10(1):475–484. doi:10.1007/s40122-020-00234-9
112. Gao Z, Xiao Y, Wang Q, Li Y. Comparison of dexmedetomidine and dexamethasone as adjuvant for ropivacaine in ultrasound-guided erector spinae plane block for video-assisted thoracoscopic lobectomy surgery: a randomized, double-blind, placebo-controlled trial. *Ann Transl Med*. 2019;7(22):668. doi:10.21037/atm.2019.10.74
113. Fujii T, Shibata Y, Akane A, et al. A randomised controlled trial of pectoral nerve-2 (PECS 2) block vs. serratus plane block for chronic pain after mastectomy. *Anaesthesia*. 2019;74(12):1558–1562. doi:10.1111/anae.14856
114. Elshanbary AA, Zaazouee MS, Darwish YB, et al. Efficacy and safety of Pectoral Nerve Block (Pecs) compared with control, paravertebral block, erector spinae plane block, and local anesthesia in patients undergoing breast cancer surgeries: a systematic review and meta-analysis. *Clin J Pain*. 2021;37(12):925–939. doi:10.1097/ajp.0000000000000985
115. Manzoor S, Taneja R, Sood N, Puri A, Kadayaprath G. Comparative study to assess the quality of analgesia of bupivacaine and bupivacaine with dexmedetomidine in ultrasound-guided pectoral nerve block type I and II in breast surgeries. *J Anaesthesiol Clin Pharmacol*. 2018;34(2):227–231. doi:10.4103/joacp.JOACP_366_16
116. Kaur H, Arora P, Singh G, Singh A, Aggarwal S, Kumar M. Dexmedetomidine as an adjunctive analgesic to ropivacaine in pectoral nerve block in oncological breast surgery: a randomized double-blind prospective study. *J Anaesthesiol Clin Pharmacol*. 2017;33(4):457–461. doi:10.4103/joacp.JOACP_298_16
117. Zusman RP, Urits I, Kaye AD, Viswanath O, Eskander J. Synergistic effect of perineural Dexamethasone and Dexmedetomidine (Dex-Dex) in Extending the analgesic duration of pectoral type I and II blocks. *Cureus*. 2020;12(9):e10703. doi:10.7759/cureus.10703
118. Hussain N, Brull R, Weaver T, Zhou M, Essandoh M, Abdallah FW. Postoperative analgesic effectiveness of quadratus lumborum block for cesarean delivery under spinal anesthesia. *Anesthesiology*. 2021;134(1):72–87. doi:10.1097/aln.0000000000003611
119. Saleh AH, Abdallah MW, Mahrous AM, Ali NA. Quadratus lumborum block (transmuscular approach) versus transversus abdominis plane block (unilateral subcostal approach) for perioperative analgesia in patients undergoing open nephrectomy: a randomized, double-blinded, controlled trial. *Braz J Anesthesiol*. 2021;71(4):367–375. doi:10.1016/j.bjane.2021.01.009
120. Elsharkawy H, El-Boghdady K, Barrington M. Quadratus lumborum block: anatomical concepts, mechanisms, and techniques. *Anesthesiology*. 2019;130(2):322–335. doi:10.1097/aln.0000000000002524
121. Alansary AM, Badawy A, Elbeialy MAK. Dexmedetomidine added to bupivacaine versus bupivacaine in transincisional ultrasound-guided quadratus lumborum block in open renal surgeries: a randomized trial. *Pain Physician*. 2020;23(3):271–282.
122. Dharmarao PS, Holyachi R. Comparative study of the efficacy of dexmedetomidine and fentanyl as adjuvants to ropivacaine in ultrasound-guided supraclavicular brachial plexus block. *Turk J Anaesthesiol Reanim*. 2018;46(3):208–213. doi:10.5152/tjar.2018.98058
123. Yasuda M, Kuroda H, Suzuki K, Takahashi SS, Morimoto Y, Sanuki T. Impact of stellate ganglion block on tissue blood flow/oxygenation and postoperative mandibular nerve hypoesthesia: a cohort study. *J Oral Maxillofac Surg*. 2022;80(2):266.e261–266.e268. doi:10.1016/j.joms.2021.08.161
124. Thapa D, Dhiman D, Ahuja V, Gombor S, Gupta RK. Tramadol sparing effect of dexmedetomidine as an adjuvant with lignocaine in preoperative stellate ganglion block for postoperative pain relief following upper limb surgeries. *Br J Pain*. 2018;12(1):26–34. doi:10.1177/2049463717720788
125. Shrestha BR, Lama S, Shrestha U. Ultrasound guided stellate ganglion block with dexmedetomidine as an adjuvant in Complex Regional Pain Syndrome (CRPS). *Kathmandu Univ Med J*. 2021;19(73):148–151. doi:10.3126/kumj.v19i1.49606
126. Kapral S, Krafft P, Gosch M, Fleischmann D, Weinstabl C. Ultrasound imaging for stellate ganglion block: direct visualization of puncture site and local anesthetic spread. A pilot study. *Reg Anesth*. 1995;20(4):323–328.
127. Kawabata K, Sago T, Oowatari T, Shiiba S. Prolonged blockade of the cervical sympathetic nerve by stellate ganglion block accelerates therapeutic efficacy in trigeminal neuropathy. *J Oral Sci*. 2022;64(1):6–10. doi:10.2334/josn.21-0245
128. Tüfek A, Kaya S, Tokgöz O, et al. The protective effect of dexmedetomidine on bupivacaine-induced sciatic nerve inflammation is mediated by mast cells. *Clin Invest Med*. 2013;36(2):E95–E102. doi:10.25011/cim.v36i2.19572
129. Yu ZY, Geng J, Li ZQ, et al. Dexmedetomidine enhances ropivacaine-induced sciatic nerve injury in diabetic rats. *Br J Anaesth*. 2019;122(1):141–149. doi:10.1016/j.bja.2018.08.022
130. Wang HL, Zhang GY, Dai WX, et al. Dose-dependent neurotoxicity caused by the addition of perineural dexmedetomidine to ropivacaine for continuous femoral nerve block in rabbits. *J Int Med Res*. 2019;47(6):2562–2570. doi:10.1177/0300060519847368
131. Xue X, Fan J, Ma X, et al. Effects of local dexmedetomidine administration on the neurotoxicity of ropivacaine for sciatic nerve block in rats. *Mol Med Rep*. 2020;22(5):4360–4366. doi:10.3892/mmr.2020.11514
132. Swami SS, Keniya VM, Ladi SD, Rao R. Comparison of dexmedetomidine and clonidine (α_2 agonist drugs) as an adjuvant to local anaesthesia in supraclavicular brachial plexus block: a randomised double-blind prospective study. *Indian J Anaesth*. 2012;56(3):243–249. doi:10.4103/0019-5049.98767
133. Sreeja R, Mathew A, Velayuden M. Effect of added alpha 2 agonists with local anaesthetic in infraclavicular brachial plexus block: a comparative study between dexmedetomidine and clonidine. *Anesth Essays Res*. 2020;14(4):638–643. doi:10.4103/aer.aer_54_21
134. Omar Mostafa M, Makram Botros J, Sayed Khaleel AM. Effect of dexmedetomidine versus nalbuphine as an adjuvant on paravertebral block to manage postoperative pain after mastectomies. *Anesth Pain Med*. 2018;8(2):e13308. doi:10.5812/aapm.13308
135. Jiang C, Xie W, Xie H, Xie W, Kang Z, Liu N. Nalbuphine exhibited a better adjuvant than dexmedetomidine in supraclavicular brachial plexus block in youths. *Clin Neuropharmacol*. 2020;43(5):134–138. doi:10.1097/wnf.0000000000000410
136. Rao J, Gao Z, Qiu G, et al. Nalbuphine and dexmedetomidine as adjuvants to ropivacaine in ultrasound-guided erector spinae plane block for video-assisted thoracoscopic lobectomy surgery: a randomized, double-blind, placebo-controlled trial. *Medicine*. 2021;100(32):e26962. doi:10.1097/md.0000000000002692

137. Song ZG, Pang SY, Wang GY, Zhang Z. Comparison of postoperative analgesic effects in response to either dexamethasone or dexmedetomidine as local anesthetic adjuvants: a systematic review and meta-analysis of randomized controlled trials. *J Anesth*. 2021;35(2):270–287. doi:10.1007/s00540-021-02895-y
138. Yaghoobi S, Shahamat H, Alizadeh A, Khezri MB. Comparing postoperative analgesic effect of dexmedetomidine or dexamethasone added to lidocaine through infraclavicular block in forearm surgery. *Clin J Pain*. 2019;35(9):766–771. doi:10.1097/ajp.0000000000000736
139. Shukla U, Singh D, Yadav JBS, Azad MS. Dexmedetomidine and magnesium sulfate as adjuvant to 0.5% ropivacaine in supraclavicular brachial plexus block: a comparative evaluation. *Anesth Essays Res*. 2020;14(4):572–577. doi:10.4103/aer.AER_28_21
140. Elyazed MMA, Mogahed MM. Comparison of magnesium sulfate and dexmedetomidine as an adjuvant to 0.5% ropivacaine in infraclavicular brachial plexus block. *Anesth Essays Res*. 2018;12(1):109–115. doi:10.4103/aer.AER_70_17
141. Ghasemi A, Chamanara M, Paknejad B, Yousefizoshk M, Hazrati E. Dexmedetomidine versus sufentanil as adjuvants to bupivacaine for brachial plexus block during upper extremity surgery: a randomized clinical trial. *Braz J Anesthesiol*. 2021. doi:10.1016/j.bjane.2021.03.026
142. Song JH, Shim HY, Lee TJ, et al. Comparison of dexmedetomidine and epinephrine as an adjuvant to 1% mepivacaine in brachial plexus block. *Korean J Anesthesiol*. 2014;66(4):283–289. doi:10.4097/kjae.2014.66.4.283
143. Mirkheshti A, Saadatniai A, Salimi A, Manafi Rasi A, Memary E, Yahyaee H. Effects of dexmedetomidine versus ketorolac as local anesthetic adjuvants on the onset and duration of infraclavicular brachial plexus block. *Anesth Pain Med*. 2014;4(3):e17620. doi:10.5812/aapm.17620
144. Hussain N, Grzywacz VP, Ferreri CA, et al. Investigating the efficacy of dexmedetomidine as an adjuvant to local anesthesia in brachial plexus block: a systematic review and meta-analysis of 18 randomized controlled trials. *Reg Anesth Pain Med*. 2017;42(2):184–196. doi:10.1097/aap.0000000000000564
145. Vorobeichik L, Brull R, Abdallah FW. Evidence basis for using perineural dexmedetomidine to enhance the quality of brachial plexus nerve blocks: a systematic review and meta-analysis of randomized controlled trials. *Br J Anaesth*. 2017;118(2):167–181. doi:10.1093/bja/aew411
146. Abdallah FW, Brull R. Facilitatory effects of perineural dexmedetomidine on neuraxial and peripheral nerve block: a systematic review and meta-analysis. *Br J Anaesth*. 2013;110(6):915–925. doi:10.1093/bja/aet066
147. Singh S, Bansal P, Dureja J. Off-label use of drugs in regional anesthesia: a need for setting up policies. *J Anaesthesiol Clin Pharmacol*. 2017;33(4):448–449. doi:10.4103/joacp.JOACP_341_15
148. Jiang J, Shen H, Zhang J, et al. Comparative study of the adverse events associated with adjuvant use of dexmedetomidine and clonidine in local anesthesia. *Front Med*. 2021;8:602966. doi:10.3389/fmed.2021.602966
149. Deng S, Yu Y. Effects of dexmedetomidine as an analgesic adjuvant for surgery of femur fracture: a systematic review and meta-analysis. *Pharmacology*. 2021;106(9–10):453–461. doi:10.1159/000515788
150. Williams BA, Hough KA, Tsui BY, Ibinson JW, Gold MS, Gebhart GF. Neurotoxicity of adjuvants used in perineural anesthesia and analgesia in comparison with ropivacaine. *Reg Anesth Pain Med*. 2011;36(3):225–230. doi:10.1097/AAP.0b013e3182176f70
151. Rwei AY, Sherburne RT, Zurakowski D, Wang B, Kohane DS. Prolonged duration local anesthesia using liposomal bupivacaine combined with liposomal dexamethasone and dexmedetomidine. *Anesth Analg*. 2018;126(4):1170–1175. doi:10.1213/ane.0000000000002719
152. Bryskin RB, Londergan B, Wheatley R, et al. Transversus abdominis plane block versus caudal epidural for lower abdominal surgery in children: a double-blinded randomized controlled trial. *Anesth Analg*. 2015;121(2):471–478. doi:10.1213/ane.0000000000000779
153. Raof RA, El Metainy SA, Alia DA, Wahab MA. Dexmedetomidine decreases the required amount of bupivacaine for ultrasound-guided transversus abdominis plane block in pediatric patients: a randomized study. *J Clin Anesth*. 2017;37:55–60. doi:10.1016/j.jclinane.2016.10.041
154. Obayah GM, Refaie A, Aboushanab O, Ibraheem N, Abdelazeem M. Addition of dexmedetomidine to bupivacaine for greater palatine nerve block prolongs postoperative analgesia after cleft palate repair. *Eur J Anaesthesiol*. 2010;27(3):280–284. doi:10.1097/EJA.0b013e3183347c15
155. Ye W, Hu Z, Jin X. Retrobulbar dexmedetomidine decreases the MLAC of ropivacaine in vitreoretinal surgery in children. *Eur J Ophthalmol*. 2015;25(4):352–356. doi:10.5301/ejo.5000549
156. She YJ, Xie GT, Tan YH, et al. A prospective study comparing the onset and analgesic efficacy of different concentrations of levobupivacaine with/without dexmedetomidine in young children undergoing caudal blockade. *J Clin Anesth*. 2015;27(1):17–22. doi:10.1016/j.jclinane.2014.09.005
157. Chan AK, Cheung CW, Chong YK. Alpha-2 agonists in acute pain management. *Expert Opin Pharmacother*. 2010;11(17):2849–2868. doi:10.1517/14656566.2010.511613
158. Tang C, Xia Z. Dexmedetomidine in perioperative acute pain management: a non-opioid adjuvant analgesic. *J Pain Res*. 2017;10:1899–1904. doi:10.2147/jpr.S139387
159. Yang SH, Sun WG, Li YL, Chen XN, Qi DM, Sun YJ. 不同剂量右美托咪定复合罗哌卡因臂丛阻滞用于小儿多指手术的效果比较 [Effects of different doses of dexmedetomidine combined with ropivacaine for brachial plexus nerve block in children undergoing polydactyly surgery]. *Nan Fang Yi Ke Da Xue Xue Bao*. 2017;37(6):833–836. Chinese. doi:10.3969/j.issn.1673-4254.2017.06.21
160. Singla N, Garg K, Jain R, Malhotra A, Singh MR, Grewal A. Analgesic efficacy of dexamethasone versus dexmedetomidine as an adjuvant to ropivacaine in ultrasound-guided transversus abdominis plane block for post-operative pain relief in caesarean section: a prospective randomized controlled study. *Indian J Anaesth*. 2021;65(Suppl 3):S121–S126. doi:10.4103/ija.IJA_228_21
161. Chapman BC, Shepherd B, Moore R, Stanley DJ, Nelson EC. Dual adjunct therapy with dexamethasone and dexmedetomidine in transversus abdominis plane blocks reduces postoperative opioid use in colorectal surgery. *Am J Surg*. 2021;222(1):198–202. doi:10.1016/j.amjsurg.2020.09.027
162. Wu Y, Kang Y, Li Y, Fu B. Impact of ultrasound-guided deep serratus anterior plane block combined with dexmedetomidine as an adjuvant to ropivacaine inpatient quality of recovery scores undergoing modified radical mastectomy: a randomized controlled trial. *Front Oncol*. 2022;12:858030. doi:10.3389/fonc.2022.858030
163. Li X, Liu Y, Zhao J, Xiang Z, Ren C, Qiao K. The safety and efficacy of ultrasound-guided Serratus Anterior Plane Block (SAPB) combined with dexmedetomidine for patients undergoing Video-Assisted Thoracic Surgery (VATS): a randomized controlled trial. *J Pain Res*. 2020;13:1785–1795. doi:10.2147/jpr.S258443
164. Gao X, Zhao T, Xu G, Ren C, Liu G, Du K. The efficacy and safety of ultrasound-guided, bi-level, erector spinae plane block with different doses of dexmedetomidine for patients undergoing video-assisted thoracic surgery: a randomized controlled trial. *Front Med*. 2021;8:577885. doi:10.3389/fmed.2021.577885

165. Andersen JH, Grevstad U, Siegel H, Dahl JB, Mathiesen O, Jæger P. Does dexmedetomidine have a perineural mechanism of action when used as an adjuvant to ropivacaine?: a paired, blinded, randomized trial in healthy volunteers. *Anesthesiology*. 2017;126(1):66–73. doi:10.1097/aln.0000000000001429
166. Sivakumar RK, Panneerselvam S, Cherian A, Rudingwa P, Menon J. Perineural vs. intravenous dexmedetomidine as an adjunct to bupivacaine in ultrasound guided fascia iliaca compartment block for femur surgeries: A randomised control trial. *Indian J Anaesth*. 2018;62(11):851–857. doi:10.4103/ija.IJA_397_18
167. Varsha R, Desai SN, Mudakanagoudar MS, Annigeri VM. Comparison between caudal epidural and ultrasound-guided ilioinguinal-iliohypogastric block with bupivacaine and dexmedetomidine for postoperative analgesia following pediatric inguinal hernia surgeries: a prospective randomized, double-blind study. *J Anaesthesiol Clin Pharmacol*. 2021;37(3):389–394. doi:10.4103/joacp.JOACP_175_19

Drug Design, Development and Therapy

Dovepress

Publish your work in this journal

Drug Design, Development and Therapy is an international, peer-reviewed open-access journal that spans the spectrum of drug design and development through to clinical applications. Clinical outcomes, patient safety, and programs for the development and effective, safe, and sustained use of medicines are a feature of the journal, which has also been accepted for indexing on PubMed Central. The manuscript management system is completely online and includes a very quick and fair peer-review system, which is all easy to use. Visit <http://www.dovepress.com/testimonials.php> to read real quotes from published authors.

Submit your manuscript here: <https://www.dovepress.com/drug-design-development-and-therapy-journal>