

Case Report: A Novel Homozygous Mutation of Cyclin O Gene Mutation in Primary Ciliary Dyskinesia with Short Stature

Dai Gong, Qiong Tang, Li-Juan Yan, Xiao-Min Ye, Yi-Can Yang, Li Zou, Qing Ji, Xiang-Lan Wen

Department of Children Health Care Center, Zhuzhou Hospital Affiliated to Xiangya Medical College, Central South University, Zhuzhou, Hunan, 412007, People's Republic of China

Correspondence: Xiang-Lan Wen, Department of Children Health Care Center, Zhuzhou Hospital Affiliated to Xiangya Medical College, Central South University, No. 116 Changjiang Road, Tianyuan District, Zhuzhou, Hunan, 412007, People's Republic of China, Tel/Fax +86 13873317331, Email wenxianglianw@126.com

Background: Primary ciliary dyskinesia (PCD) is a group of autosomal recessive genetic diseases caused by abnormal ciliary ultrastructure and/or function, resulting in reduced ciliary clearance function or other dysfunctions. PCD is one of the causes of recurrent respiratory tract infections in children. At present, there is no gold standard for diagnosis. In patients clinically suspected with PCD, a variety of examination methods are available to assist in diagnosis, such as high-speed video microscopic imaging to analyze ciliary movement patterns, transmission electron microscopy to observe ciliary ultrastructure, genetic testing, and detection of nitric oxide content in nasal expiratory air.

Case Description: We present a case summary of the clinical data and treatment process of a child with PCD and short stature induced by Novel exon 1 of CCNO mutation (NM-021147.5) at c.323del, and the proband father and mother were heterozygous mutators, who was diagnosed and treated in the Pediatric Healthcare Department of our hospital. We treated the child with recombinant human growth hormone to increase the height, and the patient was also advised to improve nutrition, prevent and control infections, and encouraged sputum expectoration. We also recommended regular follow-up visits to the outpatient department, and to seek other symptomatic and supportive treatments as necessary.

Conclusion: The height and nutritional status of the child improved after treatment. We also reviewed relevant literature to help clinicians improve their understanding of this disease.

Keywords: gene test, primary ciliary dyskinesia, reduced ciliary clearance function, short stature

Primary ciliary dyskinesia (PCD) is a rare genetic disease caused by structural or functional defects of cilia caused by gene mutation. PCD affects males and females equally. Reports across the world estimate its incidence rate as being between 1:15,000–1:20,000, PCD can cause functional defects in the high affinity sodium dependent carnitine transporter (OCTN2) protein, increase urinary carnitine excretion, and lack of carnitine in the blood, tissues, and cells, resulting in fatty acids β Oxidative defect disease.^{1–3} Here, short stature refers to individuals who are much shorter than normal people of the same race, gender, and age. Generally, they are two standard deviations shorter than normal people, or they are below the third percentile of the normal growth curve. There are varying causes for short stature in children. It affects children's growth and development adversely, and impacts their physical and psychological health. Cases of PCD with short stature are rare in clinical practice, and there are few reports available in current literature. In this paper, we present our analysis and summary of the process of diagnosis and treatment of a patient with PCD and short stature, who was treated in the Pediatric Healthcare Department of our hospital. We have also included a review of relevant literature, and a discussion of the main clinical manifestations, diagnosis, and treatment methods of this syndrome.

General Information

The patient was a girl aged 9 years and 10 months, born in Hunan Province.

She presented at the Pediatric Healthcare Department of our hospital with chief complaints of “repeated cough, runny nose, phlegm in the throat, which have persisted nearly nine years, with slow growth in height since childhood.” After birth, her height and weight were lagging those of children of the same age, and her height grew at the rate of about 3 cm/year.

Three months earlier, the patient came to our department for treatment. Physical examination showed that she was significantly shorter than others of her age. Her father’s height was 175 cm, her mother’s height was 165 cm, and her genetic height was estimated as 163.5 cm.

She had a younger brother, who was five years old, healthy, with no obvious abnormality in growth and development when compared with children of the same age. The patient’s diet and sleep were adequate, and her urine and stool were normal. Findings from the physical examination at the time of admission: height was 125.0 cm, weight was 18.3 kg (lower than the third percentile of children of the same age and gender), body mass index was 11.7. She was oriented, cheerful, had a dystrophic appearance, no unusual facial features, no yellowing of skin, no edema or hirsutism of the whole body, small superficial lymph nodes, slight congestion of the pharynx, I–II enlargement of the tonsils, no enlargement or nodule of the thyroid gland, pectus excavatum, rib ectropion, no abnormality in cardio-pulmonary examination, soft abdomen, liver and spleen not palpated under ribs, no deformity in appearance of the spine, normal proportion of the upper and lower parts, and no obvious abnormality of the external genitalia and nervous system.

Auxiliary investigations: Routine blood examination showed white blood cells of $7.48 \times 10^9/L$, neutrophil of $4.79 \times 10^9/L$, hemoglobin of 143 g/L, and platelets of $267 \times 10^9/L$. Growth hormone provocation test (arginine and levodopa stimulation) showed that the peak value of growth hormone was 6.523 ng/mL, IGF-1: 77.2 ng/mL (-2.5 SD), IGFBP-3: 3.25 ug/mL. Serum fat soluble vitamins suggested that vitamin A was 0.35 mg/L and 25 hydroxyvitamin D was 20 ng/mL. Bone age study suggested that the carpal bone was more than four years old, and the phalange was 6 years old. The following investigations were normal: Hepatitis B test, liver and kidney functions, thyroid function, electrolytes, fasting blood glucose and fasting insulin release, six trace elements, alpha fetoprotein, carcinoembryonic antigen, human chorionic gonadotropin, full-length anteroposterior and lateral radiographs of the spine, heart, color ultrasound of liver, gallbladder, spleen and pancreas, vision screening, and bone mineral density. Magnetic resonance imaging (MRI) of the head showed otitis media. The result of the hearing test was normal. Genetic testing results, as shown in Figure 1: High throughput sequencing and gene analysis of the whole exome of the child’s peripheral blood showed mutation of CCNO:NM_021147.5:exon1:c.323del:p.F108Sfs*21, which came from the parents who were both heterozygotes.

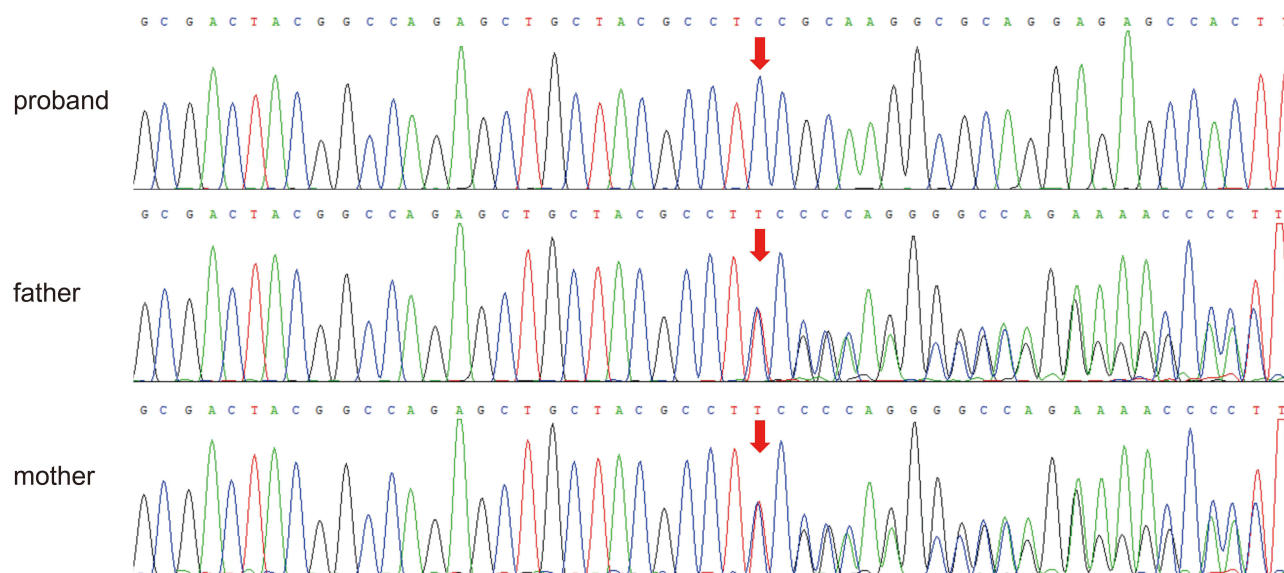


Figure 1 Sanger sequencing of the girl and the parents. Up panel: the girl with CCNO gene (NM-021147.5) at c.323del. Middle and down panel: the father and the mother with heterozygous mutation in CCNO gene.

Diagnosis and treatment: The patient had neonatal history of atelectasis, repeated cough and expectoration, chronic sinusitis, otitis media, and other clinical manifestations since infancy. Diagnosis of PCD was confirmed based on the examination of bronchial mucosa for immotile-cilia syndrome and genetic testing, which showed pathogenic mutation of Cyclin O (CCNO) gene. The patient had short stature, delayed bone age, and growth hormone provocation test peak of 6.523 ng/mL, IGF-1: 77.2 ng/mL (−2.5 SD). Hence, the diagnosis of short stature (growth hormone deficiency) was confirmed. The secretion of growth hormone was partially deficient. The patient was treated with recombinant human growth hormone to increase her height, and was advised vitamin D and calcium supplements, to pay attention to diet, sleep and exercise, prevent and control infections, encourage sputum expectoration, maintain regular follow-up visits to the outpatient department, and seek symptomatic and supportive treatments as necessary.

Follow-up visit: After three months of treatment, the height of the child increased by 2.90 cm and the weight increased by 1.10 kg. Investigations: IGF-1: 80.1 ng/mL, routine blood test, liver and kidney functions, blood glucose, and thyroid functions were normal. The child is currently continuing treatment and maintains regular follow-up visits.

Discussion

Primary ciliary dyskinesia (PCD) is characterized by abnormal ciliary structure and/or dysfunction of the mucociliary clearance system. Patients with PCD are prone to nasal symptoms and respiratory diseases soon after birth, and likely to develop bronchiectasis in adulthood. The clinical manifestations in patients with PCD are complex and diverse, with significant individual differences. The main clinical manifestations are chronic sinusitis, situs inversus, secretory otitis media, bronchiectasis, pulmonary infection, and infertility. Patients can also present with multiple symptoms and the condition may involve multiple organs. Patients may develop persistent chronic cough and expectoration a few months after birth, and this causes repeated respiratory tract infections, eventually leading to bronchiectasis. Some patients may have repeated attacks of acute otitis media, exudative otitis media, and chronic otitis media, resulting in temporary or permanent hearing damage.⁴ In addition, sinusitis is also a common clinical manifestation, while nasal polyps are relatively rare, and the incidence rate in children is less than 15%.⁵

This patient had typical manifestations such as respiratory distress in the neonatal period, repeated cough and expectoration since infancy, chronic sinusitis, and otitis media.

At present, there is no single specific diagnostic method for PCD. Two evidence-based guidelines published by the European Respiratory Society and the American Thoracic Society recommend comprehensive detection: nitric oxide determination in nasal expiratory air, high-speed video microscopy analysis (HSVA), immunofluorescence microscopy analysis (IF), transmission electron microscopy (TEM), and gene test.^{6,7} Current international and domestic guidelines agree unanimously that on the basis of typical clinical symptoms of PCD, if TEM reveals typical ciliary structural abnormalities, or genetic testing shows PCD-related biallelic pathogenic mutations, a diagnosis of PCD can be confirmed.^{6–8} At present, there are more than 50 mutant genes related to PCD that are reported in literature, and this data is constantly being updated. Most genes follow autosomal recessive inheritance, while a few genes follow X-linked recessive inheritance; for instance, the recently reported FOXJ1 gene follows autosomal dominant inheritance.⁹ Mutant genes commonly associated with PCD that have been mentioned in current literature include DNAH5, DNAI1, DNAAF1, CCDC39, CCDC40, DNAH11, and LRRC6,¹⁰ all of which have been reported in China.¹¹ The results of genetic testing of this patient are shown in Figure 1—the c.323del mutation of the gene CCNO is a pathogenic mutation site, this gene encodes a member of the cyclin protein family, and the encoded protein is involved in regulation of the cell cycle. Disruption of this gene is associated with primary ciliary dyskinesia, and Ciliary dyskinesia, obstructive pulmonary disease, and other metabolic diseases are related, which may cause growth retardation in patients.

CCNO:NM_021147.5:exon1:c.323del:p.F108Sfs*21 mutation. Evidence for high pathogenicity, PVS1: This mutation causes changes in gene open reading frame, leading to changes in protein function; evidence for moderate pathogenicity, PM2: This mutation was not found in the Shenzhou Genome Database, the Human Exon Database (ExAC), the reference population 1000 Genomes Project (1000G) and the Genome Aggregation Database (gnomAD); evidence for supporting pathogenicity PM3: Supporting: homozygous mutation was detected in the patient; according to the public database, mutations in the gene CCNO (OMIM: 607752) can lead to autosomal recessive genetic diseases, 29 (type 29 primary ciliary dyskinesia) (OMIM: 615872). The patient had a c.323del homozygous mutation on gene CCNO, while her father

and mother had heterozygous mutations, and the mutation originated from the parents. Mutation sites have not been reported before for this gene heterozygous mutation. We confirmed a diagnosis of PCD based on these results and the clinical manifestations that the child presented with. There are some gene mutations in patients with PCD that can reduce the generation of motile cilia, leading to a significant reduction in the number of cilia or even its absence. At present, such gene mutations that have been reported include MCIDAS, CCNO, and FOXJ1. Among them, MCIDAS and CCNO mutations can lead to a serious reduction in the number of cell basal bodies, resulting in a reduction in the number of cilia on the surface of each cell.¹²

Growth hormone deficiency (GHD) is an endocrinal condition caused by disordered secretion of the growth hormone, and mainly occurs in children. The main clinical manifestation of this disease is retardation in growth and development, which has a great impact on the physical and psychological health of children. A disorder commonly seen in clinical practice, the typical symptoms of children with GHD are metabolic disorder and short stature. Its pathogenesis has not been fully defined yet, and it is generally considered to be related to genetic, nutritional, environmental, and other clinical factors.¹³ Many factors affect children's growth and development; some of these factors may lead to low secretion of growth hormones, which affects their height and causes short stature, impacting their quality of life. The poor physique and short stature of this child may be related to the frequent treatment of upper respiratory tract infections and malnutrition, but environmental, endocrinal and metabolic disorders, and other factors cannot be ruled out. The incidence rate of GHD is high in children. If timely and effective treatment is not given, it may stunt their growth, proving non-conducive to their physical and psychological development.

There is no specific treatment for PCD. The aim of current treatment is to restore or maintain normal lung function as far as possible, limit further progression of the disease, and avoid irreversible lung diseases such as bronchiectasis. Treatment mainly includes a combination of physical therapy and physical exercise to actively remove airway secretions, which is effective for non-cystic fibrosis bronchiectasis and hypertonic saline atomization. The progression rate of PCD varies. Some patients can maintain good lung function and quality of life into adulthood, while others have poor prognosis, and these may be related to the patient's genotype. Further, a study found that the quality of life of patients improved after PCD was diagnosed, and patients diagnosed early had better psychosocial outcomes than those diagnosed late,¹⁴ suggesting that early diagnosis and early medical intervention can improve the prognosis of patients.

Currently, the patient's respiratory symptoms are well controlled with standard treatment, but her stature remains short due to malnutrition, and her growth and development are lagging. Growth hormone (GH) is a protein hormone produced by the anterior pituitary growth hormone cells. In addition to the role of increasing height, it has a great impact on the metabolism of sugar, fat and protein in human body. Promote protein synthesis, speed up fat and mineral metabolism, etc., which makes bones, guts and muscles grow. Growth hormone stimulates collagen synthesis in skeletal muscles and tendons to increase muscle strength and improve physical fitness. The Food and Drug Administration approved growth hormone in 1985 to treat children with growth hormone deficiency, to improve height and metabolic abnormalities. Children with chronic and repeated respiratory tract infections have an impact on nutrition and psychology of children. After treatment with growth hormone, the height and nutritional metabolism of children are improved, and the growth of height and weight is improved compared with before. It is expected that follow-up regular follow-up and treatment can improve the vital mass of children, delay the progression of disease and improve the prognosis in the long term. This case report and treatment can provide a new clinical treatment for children with PCD and short stature, and has certain clinical guidance value for prenatal diagnosis. For example, if such a mutation is found in prenatal diagnosis, or if the parents contain such a mutation, it can prompt the pregnant and lying-in women or their families as soon as possible, which may lead to the occurrence of abnormalities and reduce the risk of developing diseases in children.^{15–17}

The child had a homozygous c.323del mutation in the gene CCNO, and heterozygous mutations in both father and mother were derived from the parents. Gene heterozygous variation, so it has the value of genetic research. This mutation site has not been reported in the past.

At present, molecular genetic detection is an effective diagnostic method for ciliary immobile diseases. In this study, a new heterozygous mutation of CCNO gene was reported, which enriched the gene mutation types of PCD, contributed to a better understanding of the molecular pathology of this disease, and provided genetic basis for genetic counseling and prenatal diagnosis of this family, so as to effectively avoid the second birth defect in this family.

Repeated respiratory tract infections affected the nutrition and psychology of the child. After growth hormone treatment, her height and weight improved. Regular follow-ups and treatment are expected to improve the quality of life of the child, delay the progression of disease, and improve long-term prognosis.

Abbreviations

PCD, primary ciliary dyskinesia; HSVA, high-speed video microscopy analysis; IF, immunofluorescence microscopy analysis; GHD, growth hormone deficiency; TEM, Transmission Electron Microscope; ExAC, Exome Aggregation Consortium; 1000G, The 1000Genomes Project; gnomAD, Genome Aggregation Database; GH, Growth Hormone; FDA, Food and Drug Administration.

Ethics Approval and Consent to Participate

The study was conducted in accordance with the Declaration of Helsinki (as was revised in 2013). The study was approved by Ethics Committee of the Zhuzhou Central Hospital (ZZCHEC2021121-01) and institution has approved to publish the case details.

Consent for Publish

The written informed consent has been provided by the legal guardian to have the case details and any accompanying images published.

Acknowledgments

We are particularly grateful to all the people who have given us help on our article.

Funding

Natural Science Foundation of Hunan Province (2019JJ60091).

Disclosure

The authors declare that they have no competing interests.

References

1. Kuehni CE, Frischer T, Strippoli MP, et al. Force on primary ciliary dyskinesia in children. Factors influencing age at diagnosis of primary ciliary dyskinesia in European children. *Eur Respir J*. 2010;36(6):1248–1258. PMID: 20530032. doi:10.1183/09031936.00001010
2. Kobbernagel HE, Buchvald FF, Haarman EG, et al. Efficacy and safety of azithromycin maintenance therapy in primary ciliary dyskinesia (BESTCILIA): a multicentre, double-blind, randomised, placebo-controlled Phase 3 trial. *Lancet Respir Med*. 2020;8(5):493–505. PMID: 32380069. doi:10.1016/S2213-2600(20)30058-8
3. Leigh MW, O'Callaghan C, Knowles MR. The challenges of diagnosing primary ciliary dyskinesia. *Proc Am Thorac Soc*. 2011;8(5):434–437. PMID: 21926395; PMCID: PMC3209576. doi:10.1513/pats.201103-028SD
4. Zhang J, Bai Y, You S, et al. Gene diagnosis in patients with Kartagener syndrome induced chronic secretory otitis media. *Chin J Otol*. 2014;12(1):41–44.
5. Rollin M, Seymour K, Hariri M, Harcourt J. Rhinosinusitis, symptomatology & absence of polyposis in children with primary ciliary dyskinesia. *Rhinology*. 2009;47(1):75–78. PMID: 19382500.
6. Lucas JS, Barbato A, Collins SA, et al. European Respiratory Society guidelines for the diagnosis of primary ciliary dyskinesia. *Eur Respir J*. 2017;49(1):1601090. doi:10.1183/13993003.01090-2016
7. Shapiro AJ, Davis SD, Polineni D, et al. Diagnosis of primary ciliary dyskinesia. An Official American Thoracic Society Clinical Practice Guideline. *Am J Respir Crit Care Med*. 2018;197(12):e24–e39. doi:10.1164/rccm.201805-0819ST
8. Chinese Alliance for Rare Lung Diseases. Expert consensus on the diagnosis and treatment of primary ciliary dyskinesia in China. *Shanghai Med J*. 2020;43(4):193–202. Chinese. Available from: <https://oversea.cnki.net/KCMS/detail/detail.aspx?dbcode=CJFD&dbname=CJFDLAST2020&filename=SHYX202004003&uniplatform=OVERSEA&v=D9wgKTSNeyB38n9KXSYWBCO8AC4b7g7gSYf8MdD5Xm1quBxBDmP55eIsldIdgJK>.
9. Wang H, Xu B. Research progress on genetic pathogenesis and gene diagnosis of primary ciliary dyskinesia in children. *Chin J Appl Pediatr*. 2021;36(10):786–789.
10. Wang K, Chen X, Guo CY, Liu FQ, Wang JR, Sun LF. 一例CCNO新基因突变致原发性纤毛运动障碍伴身材矮小治疗病例报告 [Cilia ultrastructural and gene variation of primary ciliary dyskinesia: report of three cases and literatures review]. *Zhonghua Er Ke Za Zhi*. 2018; 56(2):134–137. Chinese. doi:10.3760/cma.j.issn.0578-1310.2018.02.012
11. Guo T, Tan ZP, Chen HM, et al. An effective combination of whole-exome sequencing and runs of homozygosity for the diagnosis of primary ciliary dyskinesia in consanguineous families. *Sci Rep*. 2017;7(1):7905. PMID: 28801648; PMCID: PMC5554225. doi:10.1038/s41598-017-08510-z

12. Henriques AR, Constant C, Descalço A, et al. Primary ciliary dyskinesia due to CCNO mutations-A genotype-phenotype correlation contribution. *Pediatr Pulmonol*. 2021;56(8):2776–2779. PMID: 34102041. doi:10.1002/ppul.25440
13. Richmond E, Rogol AD. Testing for growth hormone deficiency in children. *Growth Horm IGF Res*. 2020;50:57–60. PMID: 31865218. doi:10.1016/j.ghir.2019.12.002
14. Frija-Masson J, Bassinet L, Honoré I, et al. Clinical characteristics, functional respiratory decline and follow-up in adult patients with primary ciliary dyskinesia. *Thorax*. 2017;72(2):154–160. PMID: 27382041. doi:10.1136/thoraxjnl-2015-207891
15. Knowles MR, Zariwala M, Leigh M. Primary ciliary dyskinesia. *Thorax Clin Chest Med*. 2016;37(3):449–461. doi:10.1016/j.ccm.2016.04.008
16. Lie H, Ferkol T. Primary ciliary dyskinesia: recent advances in pathogenesis, diagnosis and treatment. *Drugs*. 2007;67(13):1883–1892. doi:10.2165/00003495-200767130-00006
17. Zhang SJ, Lin D, Lin LL, et al. The use of goal attainment scaling in the acupuncture of children with intellectual disability. *World J Tradit Chin Med*. 2022;8:522–529.

Pharmacogenomics and Personalized Medicine

Dovepress

Publish your work in this journal

Pharmacogenomics and Personalized Medicine is an international, peer-reviewed, open access journal characterizing the influence of genotype on pharmacology leading to the development of personalized treatment programs and individualized drug selection for improved safety, efficacy and sustainability. This journal is indexed on the American Chemical Society's Chemical Abstracts Service (CAS). The manuscript management system is completely online and includes a very quick and fair peer-review system, which is all easy to use. Visit <http://www.dovepress.com/testimonials.php> to read real quotes from published authors.

Submit your manuscript here: <https://www.dovepress.com/pharmacogenomics-and-personalized-medicine-journal>