

# A Prospective Comparative Study of Laryngeal Glottic View Using the Vie Scope<sup>®</sup> versus Standard Macintosh Laryngoscope in Morbidly Obese Patients

Tomasz Gaszynski<sup>1</sup>, Pavel Michalek<sup>2</sup>, Pawel Ratajczyk<sup>1</sup>

<sup>1</sup>Department of Anaesthesiology and Intensive Therapy, Medical University of Lodz, Lodz, Poland; <sup>2</sup>Department of Anaesthesia and Intensive Medicine, Charles University and General University Hospital, Prague, Czech Republic

Correspondence: Tomasz Gaszynski, Department of Anaesthesiology and Intensive Therapy, Medical University of Lodz, Lodz, Poland, Email [tomasz.gaszynski@umed.lodz.pl](mailto:tomasz.gaszynski@umed.lodz.pl)

**Background:** The visualization of the glottis may be inadequate in morbidly obese patients when a standard Macintosh blade laryngoscope (MCL) is used. The Vie Scope<sup>®</sup> (VS) is a novel type laryngoscope consisting of a straight, enclosed, illuminated tube that offers intubation via a bougie using the paraglossal technique. In this prospective, nonrandomized comparative study, we tested the research hypothesis that the VS may improve visualization of the glottic larynx in comparison to the MCL.

**Materials and Methods:** After obtaining institutional ethics committee approval, 60 morbidly obese patients (BMI >40 kg/m<sup>2</sup>) undergoing elective non-head and neck surgery were included in the study. After induction of general anesthesia (GA), the glottic visualization was performed using the two laryngoscopes in succession, first MCL size 3 or 4 followed by the VS and was assessed using the modified Cormack–Lehane scale. Tracheal intubation was performed using the VS. The first pass intubation success and the total success rate was recorded only for the VS. Intubation time was not measured because of the paired study design.

**Results and Discussion:** Mean demographic data included: age 41.9±8.2 years, height 171.2±10.2 cm, weight 129.9±21.6 kg, BMI 44.95±3.85 kg/m<sup>2</sup>. Using MCL, Cormack–Lehane grade 1 was observed in 36 (60%) cases; grade 2 in 7/60 (11.6%); grade 3 in 13/60 (21.7%); and grade 4 in 4/60 (6.7%). Poor laryngeal views represented by grades 3 and 4 were observed in 28.4% of patients with the MCL. Grades obtained with the VS were all grade 1 (100%). The first attempt intubation success was in 58/60 (96.7%) with the VS. No complications were observed.

**Conclusion:** The Vie Scope<sup>®</sup> laryngoscope, using the paraglossal technique of tracheal intubation, significantly improves visualization of the vocal cords in morbidly obese patients compared to the standard Macintosh laryngoscope.

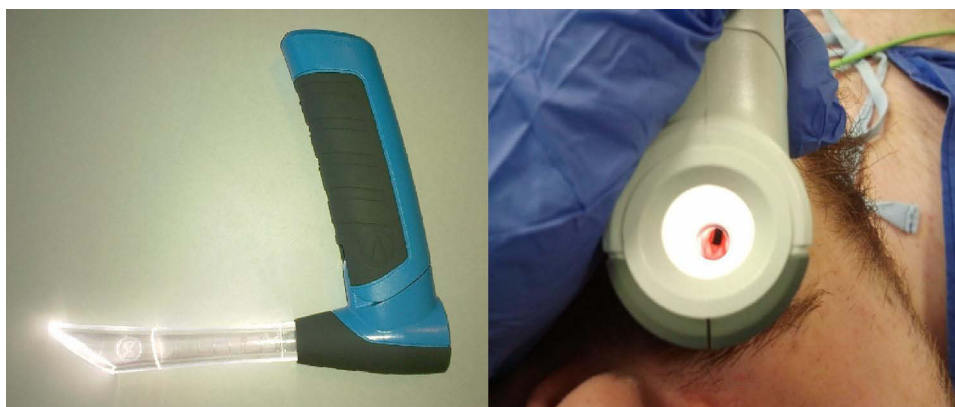**Keywords:** morbid obesity, intubation, Vie Scope<sup>®</sup> laryngoscope, direct laryngoscopy, Macintosh, difficult airway

## Introduction

Morbidly obese patients are considered potentially difficult to intubate, especially in emergency cases.<sup>1</sup> Significantly high BMI is associated with an increased probability of difficult intubation.<sup>2</sup> This probability is 1.24 times higher with BMI 25–35 kg/m<sup>2</sup> and 1.42 times higher with BMI ≥35 kg/m<sup>2</sup> when compared to the nonobese population.<sup>2</sup> Other published evidence suggests that the probability of difficult intubation is three times<sup>3</sup> or even six times<sup>4</sup> higher in obese patients compared to nonobese patients.

Standard laryngoscopy may be technically difficult in obese patients because of elevated chest diameter providing limited space for laryngoscope positioning, limited neck mobility, and increased amount of adipose tissue in the upper airway, including a larger tongue.<sup>5</sup>

The Vie Scope<sup>®</sup> (Adroit Surgical LLC, OK, USA) (VS) is a new type of laryngoscope consisting of a straight, shielded or enclosed, illuminated tube designed to perform tracheal intubation with a gum-elastic bougie utilizing the paraglossal technique (Figure 1). The VS is a one size, single use device that can be used on either side of the mouth or in either hand. The technique of intubation using the VS needs several steps: first the VS is introduced into the mouth of the



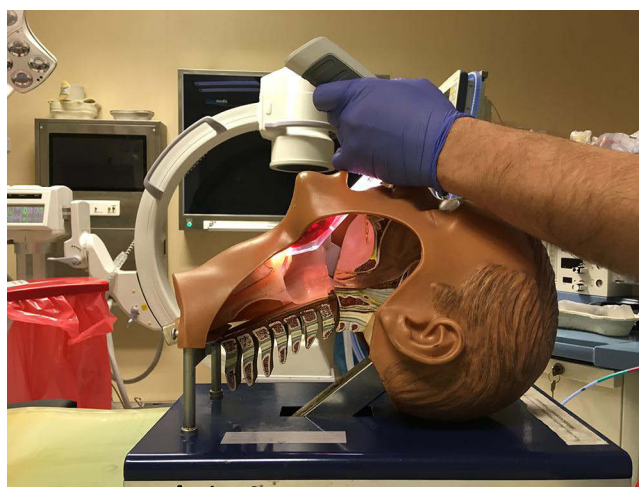**Figure 1** Vie Scope® laryngoscope.

patient and direct laryngoscopy is performed (Figure 2), then the bougie is inserted through the VS channel into trachea of the patient (Figure 3), and next the VS is removed and the endotracheal tube is introduced into trachea with road-trail method over the bougie (Figure 4). We decided to conduct a prospective, nonrandomized, paired study to test the hypothesis that the VS may improve visualization of the laryngeal inlet when compared to a standard Macintosh laryngoscope (MCL).

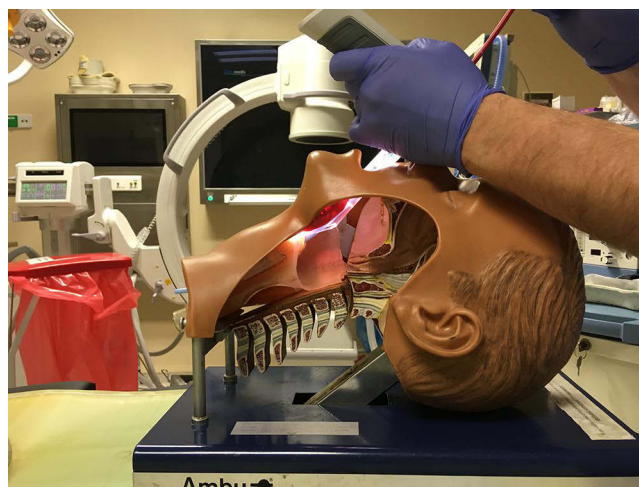
## Methods and Patients

The study protocol was approved by the Medical University of Lodz Ethics Committee (Protocol number: RNN/49/21/KB, Chairperson: Professor Jozef Drzewoski, February 9, 2021). The study was registered in ClinicalTrials.gov: NCT05502120. The study complies with the Declaration of Helsinki. The participants were fully informed before providing their consent for participation in this research. Study period was from March 2021 to October 2021. In total, 60 morbidly obese (BMI  $>40 \text{ kg/m}^2$ ) patients scheduled for bariatric surgery were included in the study after receiving written consent. Patients with predicted difficult laryngoscopy were excluded from the study: limited mouth opening  $<3 \text{ cm}$ , Mallampati grade  $>3$ , neck circumference  $>50 \text{ cm}$ , and thyromental distance  $<6 \text{ cm}$ .<sup>6</sup>

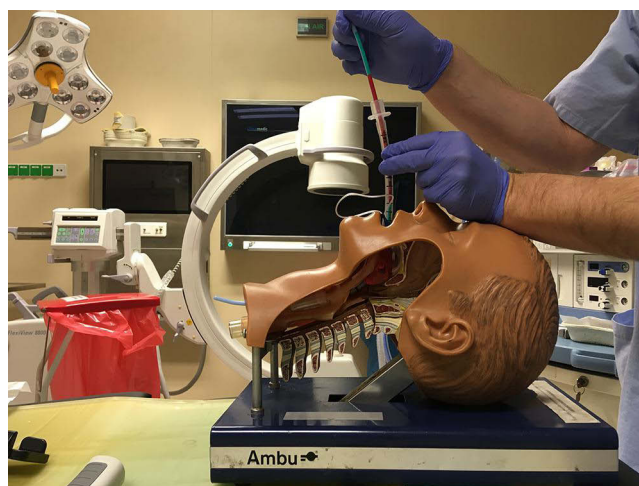
Prior to tracheal intubation, all patients were placed in the head-elevated laryngoscopy position (HELP).<sup>7</sup> All study subjects were anesthetized in concordance with the European Society for Peri-Operative Care of Obese Patients ([www.espcop.eu](http://www.espcop.eu)) protocols: proper positioning, pre-oxygenation with CPAP, induction of anesthesia with propofol  $2.0 \text{ mg/kg}^{-1}$  of corrected body weight; for muscle relaxation rocuronium  $0.6 \text{ mg/kg}^{-1}$  of ideal body weight (IBW); ketamine  $50 \text{ mg}$ ; lidocaine  $100 \text{ mg}$ , and



**Figure 2** Insertion of Vie Scope® and laryngoscopy.



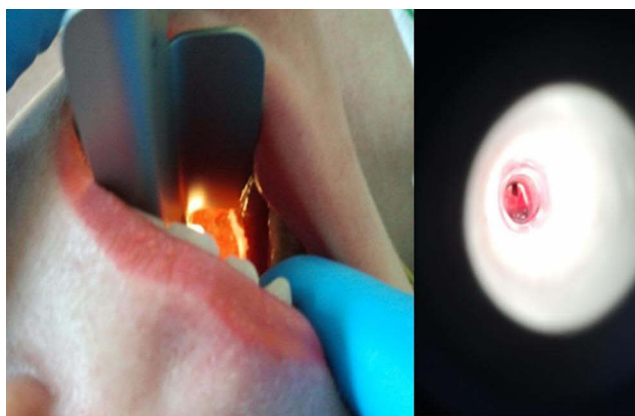
**Figure 3** Insertion of Voir Bougie® through the Vie Scope®.



**Figure 4** Introduction of endotracheal tube over Voir Bougie® after removal of the Vie Scope®.

fentanyl 0.1 mg. After achieving 100% neuromuscular block confirmed by TOF-Watch monitoring, laryngoscopy was performed by anesthesiologists familiar with both the Vie Scope® and Macintosh blade laryngoscope, and also experienced in bariatric anesthesia. All anesthesiologists participating in the study underwent VS training using manikins.

Primary outcome was the assessment of glottic visualization with direct laryngoscopy using the Cormack–Lehane scale (CL). This was performed in all patients in sequence using both laryngoscopes: first, the Macintosh blade laryngoscope (MCL) using blade 3 or 4 depending on patient's height and then the Vie Scope® laryngoscope (VS) (Figure 5). Tracheal intubation was performed with the VS. The study subjects all received oxygen using nasal CPAP (level 20 cmH<sub>2</sub>O) in order to maintain sufficient oxygenation.<sup>8</sup> An additional dose 50 mg of propofol was administered after 1 min. Because of the within-subjects study design, intubation time was not measured. Other secondary outcomes were recorded: hemodynamic stability, spO<sub>2</sub>, fall in spO<sub>2</sub> – desaturation below 90%, below 85%, the use of additional maneuvers such as BURP, and additional head positioning. The success of tracheal intubation on the first attempt was recorded only for VS general anesthesia (GA) was maintained with oxygen and air mixture, desflurane, and boluses of fentanyl and rocuronium. The patients were monitored according to ASA standards for monitoring. At the end of the procedure, residual muscle relaxation was reversed with sugammadex to achieve TOF value of more than 90%. The oral cavity was inspected for any sign of trauma in the PACU.



**Figure 5** Comparison of glottis view in the same patient using Macintosh blade laryngoscope (left) and the Vie Scope® (right).

We proposed that visualization of the larynx using the CL grade would be in total 0.4 better (20%) with the VS when compared with the MCL. Using power of 0.8 (type II error) and significance of 0.05 (type II error) we calculated the minimal sample size in the study as 52 patients ([www.harvard.edu](http://www.harvard.edu)). Sixty patients were enrolled in order to compensate for potential dropouts.

Statistical analysis was performed using Microsoft Office Excel Package (Microsoft, Warsaw, Poland).

## Results

Mean demographic cohort data included: age  $41.9 \pm 8.2$  years, height  $171.2 \pm 10.2$  cm, weight  $129.9 \pm 21.6$  kg, BMI  $44.95 \pm 3.85$  kg/m<sup>2</sup>. In visualizing the larynx with MCL: CL 1 was observed in 36/60 (60%) cases; CL 2 in 7/60 (11.6%); CL 3 in 13/60 (21.7%); CL 4 in 4/60 (6.7%). Difficult laryngeal views represented by CL 3 and 4 were observed in 28.4% of cases when using MCL. Cormack–Lehane observed with the Vie Scope® was grade 1 in all cases (100%). The first pass intubation success was achieved in 58/60 (96.7%) of patients using the VS. Two cases of first attempt failure of VS intubation were: female, 40 years old, 168 cm, 121 kg, BMI of 40.06 kg/m<sup>2</sup>, and female, 45 years old, 153 cm, 103 kg, BMI of 44.01 kg/m<sup>2</sup>. Both patients had CL grade 1 when MCL was used. The first attempt of intubation using the VS was abandoned because of difficulties introducing the endotracheal tube over the bougie due to resistance. Both of these patients were successfully intubated using a videolaryngoscope. No correlation between CL grade in MCL and BMI was observed. No complications associated with airway management were observed in our cohort. No additional maneuvers such as BURP, change of head position were necessary. There was no drop in SpO<sub>2</sub> because of the use of nasal CPAP. There was no hemodynamic instability observed.

## Discussion

The Vie Scope® laryngoscope has not to our knowledge, been evaluated in the morbidly obese population. The evaluation of this laryngoscope has been performed in a manikin model during CPR,<sup>9</sup> simulated pediatric difficult airway,<sup>10</sup> and in out-of-hospital intubations performed during CPR by paramedics.<sup>11</sup> Maslanka et al reported that the VS performed significantly better than the Macintosh blade laryngoscope with a first attempt success rate using MCL of 50.0% vs 92.9% for the VS in their study.<sup>11</sup> Another study concluded that the first pass success rate was similar for both VS and MCL – 89% vs 91%, but visualization of the glottis was significantly better in the VS group; with a mean CL scale rating of 1.2 vs 1.6 in VS and MCL respectively.<sup>12</sup> In a human clinical study by Szarpak et al during out-of-hospital CPR, the VS, when inserted by paramedics, significantly improved the first attempt success rate, 93.3% vs 51.1% using MCL respectively ( $p < 0.001$ ).<sup>13</sup>

One randomized trial compared Vie Scope® with Macintosh laryngoscope for tracheal intubation in elective surgical patients.<sup>14</sup> The authors concluded that the VS significantly improved the view of the vocal cords, however, total intubation time was longer and tracheal tube placement over the bougie was more difficult than direct tracheal intubation using the Macintosh laryngoscope.

In our study, the overall intubation success rate was 96.7% when using the VS. Intubation success rate could not be evaluated with the MCL because of the study design. The mean CL score was  $1.58 \pm 0.88$  for MCL and 1.00 for VS. We observed two cases of failed first attempt intubation using the VS. The reason for this was resistance while introducing the endotracheal tube. The method of intubation using VS – introducing first the bougie, then removing the VS and railroading the endotracheal tube over the bougie without use of the VS, makes it impossible to observe the insertion of endotracheal tube following the bougie unless the VS is reinserted to view the endotracheal tube (ETT) pass the glottis. When the operator feels resistance, but does not know the reason because he or she cannot observe the tube the VS can be reinserted into the mouth of the patient alongside the bougie and the ETT can be observed entering the glottis. This maneuver could have helped in these two situations but was not performed. Other potential causes for tube resistance whilst railroading an ETT over a bougie include an oversized ETT for the patient, inflated cuff, and “hang up” on the arytenoids. Although uncommon, “hang up” is addressed by rotating the ETT 180°.

The Vie Scope® laryngoscope essentially employs a straight blade for tracheal intubation. The use of a straight blade has already been shown in several studies to improve glottic view compared to a curved Macintosh blade laryngoscope, mostly in children,<sup>15</sup> however, no research has been undertaken on the morbidly obese using a straight blade laryngoscope.

The use of a straight blade laryngoscope with the the paraglossal technique in difficult intubation was described by Henderson and supported by a series of cases.<sup>16</sup> Among 10 described cases only one patient was obese, in whom the CL grade obtained with MCL was 3–4 but with the use of a straight blade, improved CL grade to 1. The comparison of a Miller straight blade laryngoscope with MLC for standard intubation was described by Jindal P et al.<sup>17</sup> Cormack–Lehane grade I was obtained in 97.1% of subjects among 140 included patients in the straight blade intubation group compared to 67.1% in the group where a standard Macintosh blade was employed. Unfortunately, there is no information available on the number of obese patients in this trial, but the percentage of CL 1 in our study was similar to the results of Jindal et al. In another study, Achen et al evaluated the laryngeal view obtained using the Miller blade with paraglossal approach to the Macintosh blade in 161 patients.<sup>18</sup> This study was also performed on the general population without dividing into subgroups depending on body weight. However, their results were also similar to those obtained in our study: CL 1 was observed in 96.5% and 85% of Miller and Macintosh blade laryngoscopes, respectively.

The incidence of difficult intubation has been shown to be approximately 5% in adult patients with the use of a straight blade laryngoscope,<sup>19</sup> whereas almost 9% have been reported for the Macintosh blade.<sup>18</sup> It is likely that the incidence of difficult intubation is underreported depending on the patient, location, and user. The study of Arino et al evaluating different laryngoscope blades concluded that curved blades increase the ease of intubation while straight blades improve the visualization of the larynx.<sup>20</sup> Kulkarni and Tirmanwar compared the Miller blade with McCoy, Macintosh, and TruView in 120 cancer patients.<sup>21</sup> They found the use of Miller blade was associated with the best laryngeal view compared to Macintosh blade: CL 1 was obtained in 83% vs 63%, respectively.

Another similar study evaluated the conventional Macintosh technique versus a paraglossal and retromolar Miller blade approach in 100 patients.<sup>22</sup> Direct laryngoscopy was performed in each patient with both the Miller blade and Macintosh blade in random sequence. The mean body mass index was  $26.5 \text{ kg/m}^2$ . The authors found significantly improved laryngeal view using the Miller blade compared to Macintosh blade laryngoscopy: CL 1 in 70% vs 40%, respectively.<sup>22</sup>

A study by Amornyotin et al however, reported that the use of the Miller blade was associated with a lower intubation success rate compared to the Macintosh blade laryngoscope: 100% vs 78.4% first pass success, respectively.<sup>23</sup> The study was performed on 119 patients with mean body mass index of  $22 \text{ kg/m}^2$  and providers of intubation were inexperienced in laryngoscopy. Since this study included novice users, the lack of familiarity for these devices, particularly for the Miller blade may explain the results.

The results of this prospective study are consistent with the majority of research regarding the improved glottic view using straight blade laryngoscopy. Although there is a paucity of information on the effectiveness of straight blade laryngoscope in the morbidly obese it can be assumed that the use of this method would also increase laryngeal view during direct laryngoscopy for intubation in this group of patients as it does in the general population. According to published evidence, various videolaryngoscopes also improve visualization of the glottis in the obese population<sup>24</sup> and a comparison with the Vie Scope® may be interesting for a future trial.

Patients with predicted difficult laryngoscopy were excluded from the study, however the Vie Scope<sup>®</sup> has been shown to be effective in other difficult airway patient scenarios with poor predictors. The device has been advocated as a tool to address difficult airway patients both in-hospital and within the pre-hospital environment. Future studies may include patients with poor airway predictors in elective bariatric morbidly obese patients.

A limitation of this study is that it represents a single group prospective observational analysis and that there was no measurement of time of intubation because of the paired device study design. The primary endpoint was assessment of glottis view in the same patient. If we wanted to measure time of intubation first of all it would not be possible in the same patient and second the time of intubation using the VS would be longer because of method of intubation.

Moreover, we are aware and support that in case of availability of video laryngoscopes the use of them should be recommended in patients with obesity over use of the VS. It is necessary to mention that use of the bougie intubation technique may expose the patient to additional risk of possible complications related to method of intubation. However, our intension was to evaluate possibility of using the VS if videolaryngoscope is not available, for example, in out-of-hospital settings in ambulances, in case of actual intubation difficulties. So in our opinion the VS can be an alternative to the videolaryngoscope if is not available immediately.

Further study comparing the VS and videolaryngoscope in patients with actual difficult airways would be necessary.

## Conclusion

The use of the Vie Scope<sup>®</sup> laryngoscope for endotracheal intubation with the employment of paraglossal technique significantly improves the glottic view in patients with obesity compared to using the standard Macintosh laryngoscope.

## Acknowledgments

The preliminary results were presented during conference Euroanesthesia 2022 Milan as a poster.

## Funding

Adroit Surgical company provided complimentary Vie Scope<sup>®</sup> devices free of charge.

## Disclosure

Professor Tomasz Gaszynski reports personal fees from Adroit Surgical LLC, outside the submitted work. The authors report no other conflicts of interest in this work.

## References

1. Cook T, Woodall N, Frerk C, et al. Major complications of airway management in the UK: results of the Fourth National Audit Project of the Royal College of Anaesthetists and the Difficult Airway Society. Part 1: anaesthesia. *Br J Anaesth*. 2011;106(5):617–631. doi:10.1093/bja/aer058
2. Lundström LH, Möller AM, Rosenstock C, Astrup G, Wetterslev J. High body mass index is a weak predictor for difficult and failed tracheal intubation: a cohort study of 91,332 consecutive patients scheduled for direct laryngoscopy registered in the Danish anesthesia database. *Anesthesiology*. 2009;110(2):266–274. doi:10.1097/ALN.0b013e318194cac8
3. Shiga T, Wajima Z, Inoue T, Sakamoto A. Predicting difficult intubation in apparently normal patients: a meta-analysis of bedside screening test performance. *Anesthesiology*. 2005;103(2):429–437. doi:10.1097/00000542-200508000-00027
4. Brodsky JB, Lemmens HJM, Brock-Utne JG, Vierra M, Saidman LJ. Morbid obesity and tracheal intubation. *Anesth Analg*. 2002;94(3):732–736. doi:10.1097/00000539-200203000-00047
5. Juvin P, Lavaut E, Dupont H, et al. Difficult tracheal intubation is more common in obese than in lean patients. *Anesth Analg*. 2003;97(2):595–600. doi:10.1213/01.ANE.0000072547.75928.B0
6. Pelosi P, Gregoret C. Perioperative management of obese patients. *Best Practice & Research*. 2010;24(2):211–225.
7. Gonzalez H, Minville V, Delanoue K, Mazerolles M, Concina D, Fourcade O. The importance of increased neck circumference to intubation difficulties in obese patients. *Anesth Analg*. 2008;106(4):1132–1136. doi:10.1213/ane.0b013e3181679659
8. Gaszynski T. Nasal Continuous Positive Airway Pressure During Intubation in Superobese Patients Prolongs Safe Apnea Period. *Anesth Analg*. 2019;129(1):e34. doi:10.1213/ANE.00000000000004176
9. Maslanka M, Smereka J, Czyzewski L, Ladny JR, Dabrowski M, Szarpak L. Vie scope laryngoscope versus Macintosh laryngoscope with personal protective equipment during intubation of COVID-19 resuscitation patient. *Am J Emerg Med*. 2020;46:S0735–6757. doi:10.1016/j.ajem.2020.08.085
10. Maslanka M, Szarpak L, Ahuja S, Ruetzler K, Smereka J. Novel airway device Vie Scope in several pediatric airway scenario- a randomized simulation pilot trial. *Medicine*. 2020;99(28):e21084. doi:10.1097/MD.00000000000021084
11. Maslanka M, Smereka J, Czyzewski L, et al. VieScope<sup>®</sup> laryngoscope versus Macintosh laryngoscope during difficult intubation performed by paramedics: a randomized cross-over manikin trial. *Disaster Emerg Med J*. 2020;5(3):134–141.

12. Ecker H, Kolvenbach S, Stranz S, et al. Comparison of the novel VieScope with conventional and video laryngoscope in a difficult airway scenario – a randomized, controlled simulation trial. *BMC Emerg Med.* 2021;21:90. doi:10.1186/s12873-021-00484-6
13. Szarpak L, Peacock FW, Rafique Z, et al. Comparison of Vie Scope® and Macintosh laryngoscopes for intubation during resuscitation by paramedics wearing personal protective equipment. *Am J Emerg Med.* 2022;53:122–126. doi:10.1016/j.ajem.2021.12.069
14. Petzoldt M, Engels Y, Popal Z, et al. Elective Tracheal Intubation With the VieScope-A Prospective Randomized Non-inferiority Pilot Study (VieScOP-Trial). *Front Med.* 2022;9:820847. doi:10.3389/fmed.2022.820847
15. Saracoglu A, Lerman J, Kafali H, Canaz H, Saracoglu T. Glottic views using a Miller size 0 blade are superior to those from a Macintosh size 0 blade in neonates: a randomized trial. *Anaesthesiol Intensive Ther.* 2021;53(3):246–251. doi:10.5114/ait.2021.108561
16. Henderson JJ. The use of paraglossal straight blade laryngoscopy in difficult tracheal intubation. *Anaesthesia.* 1997;52:pages 552–560. doi:10.1111/j.1365-2222.1997.129-az0125.x
17. Jindal P, Khurana G, Gupta D, Chander U. Can Paraglossal Approach be an Effective Alternative to the Conventional Laryngoscopy in Routine Anesthesia Practice- A Comparative Study. *J Anesth Clin Res.* 2014;2014(5):406. doi:10.4172/2155-6148.1000406
18. Achen B, Terblanche OC, Finucane BT. View of the larynx obtained using the Miller blade and paraglossal approach, compared to that with the Macintosh blade. *Anaesth Intensive Care.* 2008;36:717–721. doi:10.1177/0310057X0803600515
19. Landry WB, Nossaman BD. Airway risk factors for the Miller laryngoscope blade. *J Clin Anesth.* 2016;33:62–67. doi:10.1016/j.jclinane.2016.01.032
20. Arino JJ, Velasco JM, Gasco C, Lopez-Timoneda F. Straight blades improve visualization of the larynx while curved blades increase ease of intubation: a comparison of the Macintosh, Miller, McCoy, Belscope and Lee-Fiberview blades. *Can J Anaesth.* 2003;50(5):501–506. doi:10.1007/BF03021064
21. Kulkarni AP, Tirmanwar AS. Comparison of glottic visualisation and ease of intubation with different laryngoscope blades. *Indian J Anaesth.* 2013;57:170–174. doi:10.4103/0019-5049.111846
22. Reiterer C, Walzl B, Kabon B, Schramm W. Retromolar laryngoscopy: a randomized crossover vocal cords visualization study. *Minerva Anesthesiol.* 2017;83(8):798–803. doi:10.23736/S0375-9393.17.11537-3
23. Amornytin S, Prakanrattana U, Vichitvejpaisal P, et al. Comparison of the Clinical Use of Macintosh and Miller Laryngoscopes for Orotracheal Intubation by Second-Month Nurse Students in Anesthesiology. *Anesthesiol Res Pract.* 2010;2010:1–5. doi:10.1155/2010/432846
24. Brozek T, Bruthans J, Porizka M, Blaha J, Ulrichova J, Michalek P. A Randomized Comparison of Non-Channeled Glidescope™ Titanium Versus Channeled KingVision™ Videolaryngoscope for Orotracheal Intubation in Obese Patients with BMI > 35 kg·m<sup>-2</sup>. *Diagnostics.* 2020;10:1024. doi:10.3390/diagnostics10121024

## Therapeutics and Clinical Risk Management

Dovepress

### Publish your work in this journal

Therapeutics and Clinical Risk Management is an international, peer-reviewed journal of clinical therapeutics and risk management, focusing on concise rapid reporting of clinical studies in all therapeutic areas, outcomes, safety, and programs for the effective, safe, and sustained use of medicines. This journal is indexed on PubMed Central, CAS, EMBase, Scopus and the Elsevier Bibliographic databases. The manuscript management system is completely online and includes a very quick and fair peer-review system, which is all easy to use. Visit <http://www.dovepress.com/testimonials.php> to read real quotes from published authors.

Submit your manuscript here: <https://www.dovepress.com/therapeutics-and-clinical-risk-management-journal>