



# Facial Demodicosis-Induced Skin Hyperpigmentation in an Immunocompromised Man Treated Successfully with Ivermectin 1% Cream: A Case Report

Sadan Mohammed Al Harbi , Nasser Mohammed Al Saif , Ahmad Mawkili, Sarah Al Breiki

Department of Dermatology, College of Medicine, Imam Abdulrahman Bin Faisal University, Dammam, Eastern Province, Saudi Arabia

Correspondence: Sadan Mohammed Al Harbi, Department of Dermatology, College of Medicine, Imam Abdulrahman Bin Faisal University, Post Box No. 1982, Dammam, 31441, Saudi Arabia, Email [Smharbi@iau.edu.sa](mailto:Smharbi@iau.edu.sa)

**Abstract:** Demodex folliculorum is a common ectoparasite of humans that inhabits follicular infundibulum and sebaceous ducts. Its role in various dermatological diseases is well studied. However, data on demodex-induced skin pigmentation are very limited. A diagnosis of this entity can be easily missed for other causes of facial hyperpigmentation such as melasma, lichen planus pigmentosus, erythema dyschromicum perstans, post-inflammatory hyperpigmentation, and drug-induced hyperpigmentation. Here, we report a case of facial demodicosis-induced skin hyperpigmentation in a 35-year-old Saudi male who is on multiple immunosuppressive agents. He was successfully treated with ivermectin 1% cream and had a dramatic improvement at his 3-month follow-up. Our aim is to shed light on this underdiagnosed cause of facial hyperpigmentation which can be easily diagnosed and followed up by bedside dermoscopic examination and managed effectively by anti-demodectic therapies.

**Keywords:** demodex, hypermelanosis, ivermectin, pilosebaceous unit

## Introduction

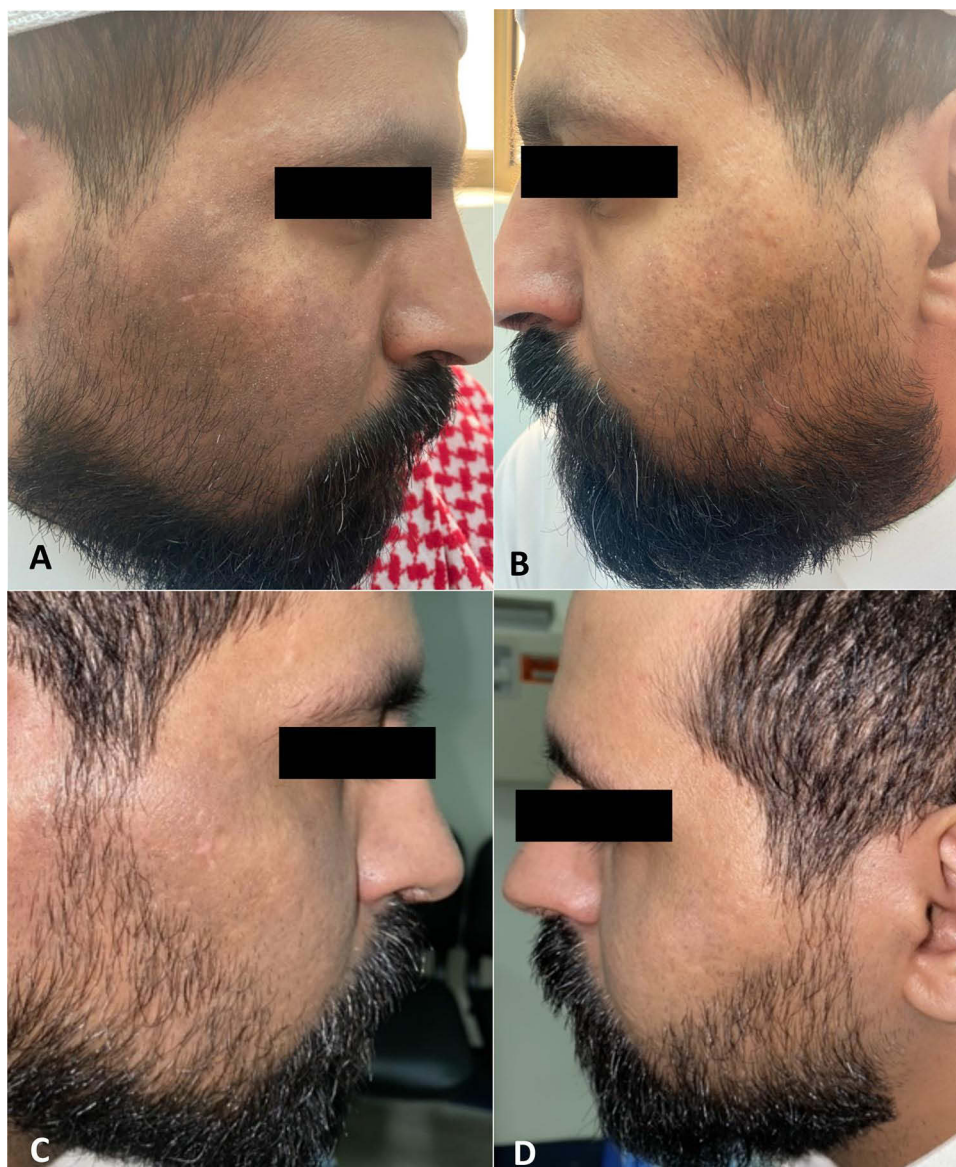Demodex mites, namely, Demodex folliculorum and D. brevis, are common ectoparasites that obligatorily inhabit the pilosebaceous units.<sup>1,2</sup> The term demodicosis or demodicidosis is used to describe cutaneous manifestations caused by demodex mites.<sup>3</sup> Various skin conditions were attributed to the pathogenic role of demodex mites including papulopustular rosacea, erythematotelangiectatic rosacea, pityriasis folliculorum, granulomatous rosacea, and perioral dermatitis.<sup>3-5</sup> Demodicosis-induced facial hyperpigmentation is an underdiagnosed entity. Published data on demodex-associated pigmentation are very limited. Upon review of English literature, only two recent studies reported this entity; a cohort study described morphological, dermoscopic and histopathological features of “pigmented demodicidosis” and a single case report by Betul Serefican et al.<sup>6,7</sup> We describe a case of facial demodicosis-induced hyperpigmentation which showed a significant clinical and dermoscopic improvement with topical ivermectin cream. Our purpose of this study is to encourage clinicians to be alerted to this under-recognized cause of facial hyperpigmentation which can be efficiently treated with topical anti-demodectic.

## Case Report

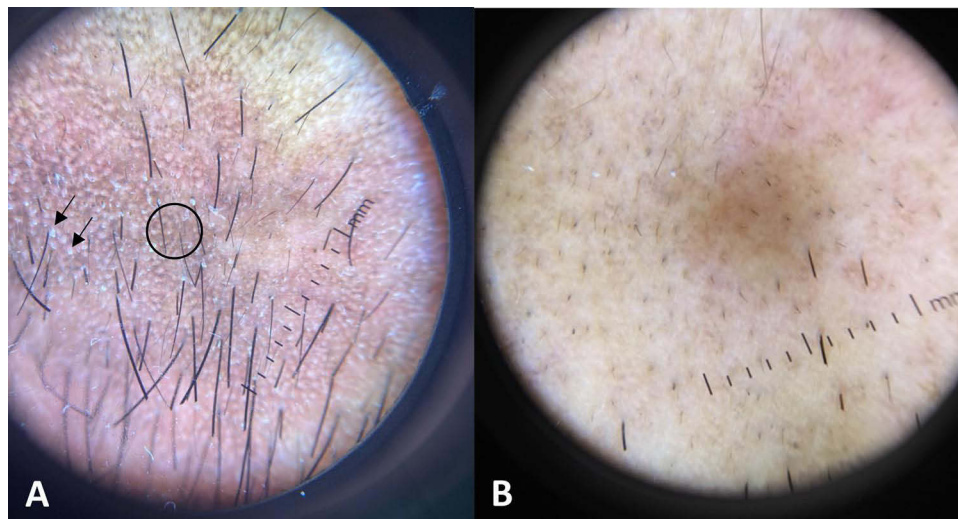
A 35-year-old Saudi man presented to our dermatology clinic at King Fahad Hospital of Imam Abdulrahman Bin Faisal University with a complaint of asymptomatic facial skin discoloration. Initially, lesions started as brown-grey macules on both cheeks, which gradually expanded and conflated into larger patches over the past 2 years. He tried a combined formula consisted of hydroquinone 4%, tretinoin 0.1%, and hydrocortisone 1% cream for 3 months without improvement. His medical history was remarkable for Behcet’s disease with active ocular and neurological diseases. His immunosuppressive regimen at the time of dermatologic evaluation consisted of infliximab, 600 mg every 6 weeks, prednisolone, 5 mg daily, mycophenolate sodium, 720 mg thrice daily, and colchicine, 0.5 mg twice daily.

Dermatological examination revealed confluent poorly demarcated grayish-brown hyperpigmented macules and patches with fine scales distributed symmetrically on his cheeks. The lesions on the right cheek were more pigmented compared to the left cheek (Figure 1A and B). A wide differential diagnosis was considered which included melasma, lichen planus pigmentosus, erythema dyschromicum perstans, post-inflammatory hyperpigmentation, drug-induced hyperpigmentation, Riehl's melanosis and ochronosis. Further evaluation by dermoscopy showed white gelatinous filaments protruding out of follicular openings known as "Demodex tails" associated with reticular perifollicular pigmented network (Figure 2A).

The histopathological examination of skin punch biopsy showed epidermis with multiple demodex mites within the stratum corneum and folliculosebaceous units, parakeratosis, spongiosis, and lymphocytic exocytosis. A diagnosis of facial demodicosis-induced hyperpigmentation was given. Accordingly, the patient was treated with ivermectin 1% cream applied once daily over areas of hyperpigmentation for 3 months. The patient showed significant improvement in which the hyperpigmented patches became lighter in color with less associated scales (Figure 1C and D), and fewer demodex tails with partial resolution of the reticular perifollicular pigmented network on dermoscopic examination (Figure 2B) at a 3-month follow-up time frame.



**Figure 1 (A and B)** Poorly demarcated greyish-brown confluent macules and patches associated with fine rough scales on the right cheek and the left cheek respectively. Lesions on the right side are darker and more diffuse compared to the left side. **(C and D)** Sites of the lesions after using ivermectin 1% cream daily at 3-month follow-up, significant improvement in discoloration and texture on the right cheek and the left cheek respectively.



**Figure 2** (A) dermoscopic picture showing white gelatinous filaments protruding through follicular openings “demodex tails” (arrows), and reticular perifollicular pigmented network (circle). (B) dermoscopic picture showing improvement after 3 months of treatment with ivermectin 1% cream.

## Discussion

Demodex mites are common infestations that obligatorily inhabit the pilosebaceous units in mammals. There are about 65 species of *Demodex*. However, only two species are recognized in human: *Demodex folliculorum* and *D. brevis*.<sup>1,2</sup> Demodex mites have a predilection to areas of high sebum production, specifically forehead, nose, nasolabial folds, and cheeks, yet they can be found in scalp, external ear, eyelashes, meibomian gland and upper chest.<sup>8</sup>

Demodex-induced facial hyperpigmentation was first described by De Amicis (1898), Mjocchi (1918) and Dubreuilh (1901) as quoted by Hana Feuerman et al.<sup>6</sup> Francis Burton reported 2 cases with pigmentation around the roots of the eyelashes where *arcus demodex folliculorum* was demonstrated alive on the shafts of these eyelashes.<sup>9</sup> The term “pigmented demodicosis” was given by a cohort study which was done on 19 patients who presented with facial pigmentation that was associated with demodicosis. Parallel to our case findings, dermoscopy showed a white gelatinous protrusion (demodex tails) or opaque infiltration with amorphous material coming through the hair follicle openings, a specific finding was a reticular uneven perifollicular pigmentation seen in all patients. Anti-demodectic treatment was offered, and complete and partial resolution were seen in 73.6% and 23.4%, respectively.<sup>6</sup> Betul Sereflican et al reported a case of facial hyperpigmentation with high demodex density on histopathological study in an immunocompromised patient and questioned if this pigmentation was an inflammatory response to the infestations or it was only a coexistence.<sup>7</sup> Serpil Sener et al retrospectively studied the affinity of demodex toward the melanin pigment by examining the presence of this parasite in nevi of 110 patients, 39.1% of these specimens found to be positive for demodex spp. with significant association with dermal nevus type (P-value <0.05), this may raise the question whether demodex induces pigmentation or it notably favors the melanin pigment environment.<sup>10</sup>

Various studies compared demodex density between immunocompromised patients and controls; majorities of these studies showed significant higher density of mites in immunocompromised patients; the hypotheses behind this were either that immunosuppression led to the increase in the number of the follicle mites causing an inflammatory reaction or it was an abnormal immunological response to the parasite.<sup>11–14</sup> Our patient was similarly on multiple immunosuppressive regimen, and his dermoscopic and histopathologic examinations confirmed the presence of numerous demodex mites. Contrastingly, Iris Amitay et al who studied facial demodicosis in 28 immunosuppressed patients observed no significant correlation between mites count and disease severity between both groups, and this was explained by the attenuation of immune response to the parasite owing to the immunosuppression.<sup>15</sup>

Numerous treatment options have been used for Demodex-associated skin conditions; this includes topical and oral metronidazole, topical benzoyl peroxide, topical permethrin, topical crotamiton, topical ivermectin, sulphur cleansers, and topical azelaic acid.<sup>6,15,16</sup>

Our review of the literature revealed a very limited data on the management of Demodicosis-induced facial hyperpigmentation.<sup>6,7</sup> Hana Feuerman et al described the use of different topical anti-demodectic in treating this entity in 19 patients specifically ivermectin 1% cream, benzoyl peroxide 2.5% gel, crotamiton cream, metronidazole 0.75% gel, and permethrin 5% cream. This resulted in complete resolution in all patients except for two patients who had a partial response to topical treatment in which oral isotretinoin or oral metronidazole were added to their management and showed further improvement.<sup>6</sup> Ivermectin 1% cream (SOOLANTRA) is approved by the FDA for the indication for the treatment of inflammatory lesions of rosacea and was considered the most effective topical treatment for rosacea in a large network meta-analysis study.<sup>17</sup> Our patient was treated with Ivermectin 1% cream once daily for three-month duration with a dramatic improvement.

## Conclusion

Facial hyperpigmentation is a major cosmetic concern and might have a great negative psychosocial impact on person's life.<sup>18,19</sup> One of the most important causes yet an under-recognized entity is demodex-induced facial hyperpigmentation. Our aim is to encourage dermatologists to add this entity to the differential diagnosis of facial pigmentation in healthy individuals and more importantly immunocompromised patients. We recommend considering dermoscopic examination which can easily confirm the diagnosis. Treatment with anti-demodectic, namely, ivermectin 1% cream showed acceptable cosmetic result.

## Abbreviation

D. brevis, Demodex brevis.

## Data Sharing Statement

All data for this scientific paper are provided within this case study.

## Ethics Approval and Consent for Publication

This case report has been performed in accordance with the principles stated in the Declaration of Helsinki. A written informed consent provided by our institution for publication of this case report and including photography and medical information was signed by the patient. Institutional ethical approval was not required for the case details.

## Acknowledgments

The authors would like to thank all department colleagues who contributed to this case report.

## Author Contributions

All authors made a significant contribution to the work reported, whether that is in the conception, study design, execution, and acquisition of data, or in all these areas; took part in drafting, revising, or critically reviewing the article; gave final approval of the version to be published; have agreed on the journal to which the article has been submitted; and agree to be accountable for all aspects of the work.

## Funding

The authors declare that this article has not received any financial support.

## Disclosure

The authors report no conflicts of interests in this paper.

## References

1. Baima B, Sticherling M. Demodicidosis revisited. *Acta Derm Venereol*. 2002;82(1):3–6. doi:10.1080/000155502753600795
2. Rather PA, Hassan I. Human demodex mite: the versatile mite of dermatological importance. *Indian J Dermatol*. 2014;59(1):60–66. doi:10.4103/0019-5154.123498



3. Hsu CK, Hsu MM, Lee JY. Demodicosis: a clinicopathological study. *J Am Acad Dermatol.* 2009;60(3):453–462. doi:10.1016/j.jaad.2008.10.058
4. Ayres S. Demodectic eruptions (demodicidosis) in the human. 30 years' experience with 2 commonly unrecognized entities: pityriasis folliculorum (Demodex) and acne rosacea (Demodex type). *Arch Dermatol.* 1961;83:816–827. doi:10.1001/archderm.1961.01580110104016
5. Purcell SM, Hayes TJ, Dixon SL. Pustular folliculitis associated with Demodex folliculorum. *J Am Acad Dermatol.* 1986;15(5 Pt 2):1159–1162. doi:10.1016/s0190-9622(86)70287-9
6. Feuerman H, Atzmony L, Glick M, et al. Pigmented demodicidosis – an under-recognized cause of facial hyperpigmentation. *Int J Dermatol.* 2022;61(5):564–569. doi:10.1111/ijd.15992
7. Serefican B, Tuman B, Boran C, Goksugu N, Parlak AH, Polat M. Facial pigmentation with demodex Mite; a mere coincidence or an association? *Dermatol Online J.* 2016;22(9):13030/qt4628m9xr.
8. Burns DA. Follicle mites and their role in disease. *Clin Exp Dermatol.* 1992;17(3):152–155. doi:10.1111/j.1365-2230.1992.tb00192.x
9. Blackmar FB. Pigmentation of roots of cilia caused by Acarus Demodex folliculorum. *Am J Ophthalmol.* 1929;12(5):373–375. doi:10.1016/s0002-9394(29)92280-7
10. Serpil S, Ulku K, Cemil C, Nasuhi Engin A, Sezai S, Meryem I. Positivity of Demodex spp. in biopsy specimens of nevi. *Trop Biomed.* 2009;26(1):51–56.
11. Seyhan ME, Karıncaoğlu Y, Bayram N, Aycan O, Kuku I. Density of Demodex folliculorum in haematological malignancies. *J Int Med Res.* 2004;32(4):411–415. doi:10.1177/147323000403200410
12. Morrás PG, Santos SP, Imedio IL, Echeverría ML, Hermosa JM. Rosacea-like demodicidosis in an immunocompromised child. *Pediatr Dermatol.* 2003;20(1):28–30. doi:10.1046/j.1525-1470.2003.03006.x
13. Keles H, Pancar Yuksel E, Aydin F, Senturk N. Pre-treatment and post-treatment demodex densities in patients under immunosuppressive treatments. *Medicina.* 2020;56(3):107. doi:10.3390/medicina56030107
14. Karıncaoğlu Y, Esrefoglu Seyhan M, Bayram N, Aycan O, Taskapan H. Incidence of Demodex folliculorum in patients with end stage chronic renal failure. *Ren Fail.* 2005;27(5):495–499. doi:10.1080/08860220500198037
15. Amitay-Laish I, Solomon-Cohen E, Feuerman H, et al. Facial demodicosis in the immunosuppressed state: a retrospective case series from a tertiary referral center. *Int J Dermatol.* 2022;61(10):1245–1252. doi:10.1111/ijd.16162
16. Pormann AN, Vieira L, Majolo F, Johann L, Silva GL. *Demodex folliculorum* and *demodex brevis* (Acari: demodicidae) and their association with facial and non-facial pathologies. *Int J Acarol.* 2021;47(5):396–403. doi:10.1080/01647954.2021.1919757
17. Siddiqui K, Stein Gold L, Gill J. The efficacy, safety, and tolerability of ivermectin compared with current topical treatments for the inflammatory lesions of rosacea: a network meta-analysis. *Springerplus.* 2016;5(1):1151. doi:10.1186/s40064-016-2819-8
18. Gupta M, Mahajan VK. Clinical profile of 300 men with facial hypermelanosis. *J Dermatol Case Rep.* 2017;11(2):20–24. doi:10.3315/jder.2017.1244
19. Taylor A, Pawaskar M, Taylor SL, Balkrishnan R, Feldman SR. Prevalence of pigmentary disorders and their impact on quality of life: a prospective cohort study. *J Cosmet Dermatol.* 2008;7(3):164–168. doi:10.1111/j.1473-2165.2008.00384.x

## Clinical, Cosmetic and Investigational Dermatology

Dovepress

### Publish your work in this journal

Clinical, Cosmetic and Investigational Dermatology is an international, peer-reviewed, open access, online journal that focuses on the latest clinical and experimental research in all aspects of skin disease and cosmetic interventions. This journal is indexed on CAS. The manuscript management system is completely online and includes a very quick and fair peer-review system, which is all easy to use. Visit <http://www.dovepress.com/testimonials.php> to read real quotes from published authors.

Submit your manuscript here: <https://www.dovepress.com/clinical-cosmetic-and-investigational-dermatology-journal>