

# Effects of Methylenetetrahydrofolate Reductase (*MTHFR*) Polymorphisms on Retinal Tissue Perfusion in Mild Diabetic Retinopathy Patients Receiving the Medical Food, Ocufofin<sup>®</sup>

Hong Jiang<sup>1,2</sup>, Zhiping Liu<sup>1,3</sup>, Justin H Townsend<sup>1</sup>, Jianhua Wang<sup>1</sup>

<sup>1</sup>Department of Ophthalmology, Bascom Palmer Eye Institute, University of Miami Miller School of Medicine, Miami, FL, USA; <sup>2</sup>Department of Neurology, University of Miami Miller School of Medicine, Miami, FL, USA; <sup>3</sup>Ophthalmic Center, the Second Affiliated Hospital of Guangzhou Medical University, Guangzhou, Guangdong, People's Republic of China

Correspondence: Jianhua Wang, Bascom Palmer Eye Institute, University of Miami, Miller School of Medicine, 1638 NW 10th Avenue, McKnight Building - Room 202A, Miami, FL, 33136, USA, Tel +1 305 482-5010, Fax +1 305 482-5012, Email jwang3@med.miami.edu

**Purpose:** We evaluate the effects of methylenetetrahydrofolate reductase (*MTHFR*) polymorphisms on retinal tissue perfusion in patients with mild diabetic retinopathy (DR + PM) taking the medical food, Ocufofin<sup>®</sup>, for 6 months.

**Methods:** Prospective, case-controlled study. Eight early diabetic retinopathy patients with common reduced function *MTHFR* polymorphisms (DR+PM) and 15 normal controls (NC) were recruited. *MTHFR* polymorphisms were subtyped as normal, C677T, or A1298C. Best corrected visual acuity (BCVA) was evaluated. Retinal blood flow velocity (BFV) was measured using Retinal Function Imager. Retinal tissue perfusion (RTP, blood flow rate per inner retinal volume) was calculated within a 2.5 mm diameter circle centered on the fovea. The medical food is intended to address ocular ischemia with high doses of vitamin B-complexes and antioxidants, including L-methylfolate, methylcobalamin, zinc, copper, lutein, vitamins C, D, E, and n-acetylcysteine. The subjects were provided with a medical food for a period of 6 months.

**Results:** BCVA and vascular indices of DR + PM patients at baseline were initially below those of NC and improved after medical food. Compared to baseline, DR + PM patients after the medical food had significantly improved BCVA during the follow-up period ( $P < 0.05$ ). In comparison, overall RTP and arteriolar BFV were significantly increased at 6 months ( $P < 0.05$ ). The changes varied with *MTHFR* subtypes. In patients with the C677T and the C677T/A1298C compound mutations, RTP was increased at 6 months as compared to that at baseline and 4 months ( $P < 0.05$ ). In patients with only the A1298C mutation, all microcirculation metrics were increased from baseline at 4 and 6 months, but with less improvement at 6 months than at 4 months ( $P < 0.05$ ).

**Conclusion:** Medical food was effective in improving both visual acuity and retinal tissue perfusion in DR + PM patients. The degree of improvement of retinal microcirculation varied among *MTHFR* subtypes.

**Keywords:** diabetic retinopathy, homocysteine, L-methylfolate, n-acetylcysteine, medical food, *MTHFR*, Ocufofin<sup>®</sup>, retinal microcirculation, retinal perfusion

## Introduction

Type II Diabetes Mellitus (DM), also known as adult-onset diabetes, is a condition in which the body is unable to control blood glucose levels due to insulin resistance or, at late stages, reduced insulin production.<sup>1</sup> Current estimates suggest that there are 466 million diabetics worldwide, almost half of whom are undiagnosed. Another 374 million have impaired glucose tolerance.<sup>2</sup> The exact cause is unknown, but genetic tendencies and environmental factors, such as high glycemic loading, lack of exercise, low fiber diet, and obesity, have been found to correlate to disease incidence.<sup>3,4</sup> A common microvascular complication of DM, diabetic retinopathy (DR) is one of the leading causes of visual loss and the leading cause of newly diagnosed blindness among working-age adults worldwide.<sup>5,6</sup> DR affects more than 126 million people,

more often in developed countries.<sup>7,8</sup> Among diabetics, the worldwide prevalence of DR and vision-threatening DR has been estimated to be 35% and 10%, respectively.<sup>8,9</sup>

DR is a multifactorial disease that leads to irreversible retinal damage without timely and effective treatment.<sup>5</sup> As an early event, endothelial dysfunction plays a significant role in the development of vascular diseases, including DR.<sup>10,11</sup> Attacking the risk factors and drivers for DR to slow its progression during the earliest stages may lessen the burden and preserve vision in diabetic patients.<sup>12</sup> Risk factors for DR include longer duration of diabetes, higher HbA1c level, chronic hyperglycemia, elevated systolic blood pressure, hyperhomocysteinemia (Hcy), hyperlipidemia, and impaired enzymatic activity, which in turn result in increased vascular permeability, impaired autonomic vasoregulation, and capillary loss.<sup>10,11,13,14</sup>

Reduced function methylenetetrahydrofolate reductase (*MTHFR*) polymorphisms play a role in vascular disease progression in DR.<sup>15</sup> The *MTHFR* gene codes for the synthesis of methylenetetrahydrofolate reductase, an enzyme for adding a methyl group to tetrahydrofolate. *MTHFR* mutations impair folate methylation and cause increased homocysteine, a high-risk factor for DR incidence and progression.<sup>16,17</sup> Two common *MTHFR* polymorphisms have been reported: a mutation at nucleotide 677 (*C677T*) and another at nucleotide 1298 (*A1298C*).<sup>18–21</sup> Close to 70% of several significant populations have at least one of these reduced function variants. This is common in patients of Amerindian, European, Latino, and Chinese heritage. The most severe homozygous variant state of *MTHFR* *C677T* is present in 25% and 57%, respectively, of Latino and Amerindian populations studied, possibly accounting for their higher risks of hypertensive and diabetic disease.<sup>22</sup> In Chinese population studies, *C677T* is present in 62% of the population, and the *A1298C* mutation is present in 25%.<sup>23</sup> European populations carry the *MTHFR* *C677T* heterozygously in 24–64% of groups surveyed, and *MTHFR* *A1298C* in 10–20% of studied populations.<sup>23,24</sup> This is particularly important for patients with diabetic retinopathy because studies show that nutritional intervention reduces hypertension and other variant driven vasculopathies.<sup>25,26</sup> Although both genes are reported to be associated with increased vascular and neurological diseases, the significance of the *MTHFR* *A1298C* variant is still controversial. Most population studies have focused on the *MTHFR* *C677T*, however there are some data associating *A1298C* mutations with thrombotic disease, diabetic vasculopathy, and stroke.<sup>27,28</sup> The relatively common compound heterozygous state, *MTHFR* *C677T/A1298C*, is noted to be associated with increased serum homocysteine and neural tube defects.<sup>21</sup> This impairment of the folate cycle is also associated with increased homocysteine, reduced nitric oxide synthesis, and vascular endothelial injury. The resultant endothelial injury is associated with small vessel disease and reduced perfusion of the eye and brain tissue beds.<sup>29</sup> Perfusion impairments and ischemia are especially problematic for the retina and the visual cortex of the brain, which have the highest requirement for antioxidants, glucose, and oxygen in the body.<sup>30–32</sup>

In addition, our previous reports showed that the responses to medical food in conjunctival and retinal microvascular architecture varied in DR patients with different *MTHFR* polymorphism subtypes.<sup>19,33</sup> Ocufolin<sup>®</sup> is a medical food with a formulation of antioxidants, nutrients, and B-complex vitamins intended to reduce homocysteine, increase nitric oxide, and beneficially impact small vessel disease of the visual system.<sup>29</sup> All ingredients serve that purpose to some degree. N-acetylcysteine is a very potent neuroprotective anti-oxidant. Vitamins B6, B9, and B12 offset folate cycle impairment, decreasing homocysteine and raising nitric oxide. They are supplied in natural food-based forms: pyridoxyl-5-phosphate, L-methylfolate, and methylcobalamin to avoid the toxicities of pyridoxine, folic acid, and cyanocobalamin, which are commonly used in dietary supplements. Of particular note is that L-methylfolate readily crosses the Blood Brain Barrier and Blood Retinal Barrier, unlike folic acid, and is 7 times more bioavailable for CNS homocysteine reduction, increasing nitric acid synthesis, and neuroprotection. Ingredients of Ocufolin<sup>®</sup> are well known to improve hypertension control.<sup>34</sup> As a medical food, Ocufolin<sup>®</sup> is manufactured to a higher standard of purity and label accuracy than equivalent dietary supplements, and thus is more reliable and suitable for medical intervention.<sup>29</sup> The goal of the present study was to examine the effects of *MTHFR* polymorphisms on retinal tissue perfusion in patients with mild diabetic retinopathy (DR + PM) taking the medical food, Ocufolin<sup>®</sup> for 6 months. The results are analyzed in the context of the recent literature concerning diabetic retinopathy, hypertension, riboflavin, L-methylfolate, and n-acetylcysteine.

## Methods

This was a prospective, case-controlled study, and the study protocol has been reported.<sup>19,33,35</sup> In brief, The Research Subjects Review Board Office at the University of Miami approved this study, and all study subjects signed an informed consent form after the study details were discussed. The tenets of the Declaration of Helsinki were followed. The eligibility was determined at the screening visit according to study criteria, including mild DR without other retinal vascular diseases, clear ocular media, visual acuity  $\geq 20/80$ , and *MTHFR* polymorphisms (*A1289C* and/or *C677T*). The exclusion criteria included glaucoma, severe cataract, other retinal diseases, cardiovascular disease, dementia, infectious diseases, cancer, multiple sclerosis, and cerebrovascular diseases. The diagnosis of mild DR was made by treating retinal specialist (JT) based on American Diabetes Association (ADA) criteria and the American Academy of Ophthalmology Retina/Vitreous Panel.<sup>36,37</sup> HbA1c was tested by Quest Diagnostics (Secaucus, NJ) and the threshold was 10 or less for this study. Gene tests were conducted by MyGenetx Laboratory, LLC (Franklin, TN). A total of eight DR patients with *MTHFR* polymorphisms (DR + PM) patients were enrolled in the study, and they received medical food for 6 months.

Retinal blood flow velocity (BFV) was measured using Retinal Function Imager (RFI, Optical Imaging Ltd., Rehovot, Israel). Retinal tissue perfusion (RTP, blood flow rate per inner retinal volume) was calculated within a 2.5 mm diameter circle centered on the fovea. Details of measuring RTP have been previously reported.<sup>35,38</sup> In short, RFI is a fundus camera-based imaging device, which has a synchronized green flashlight equipped with a high-speed fundus camera. During imaging, a series of fundus photos were acquired, which enable the tracking of the movement of red blood cell clusters. The measurement of the motion of these erythrocytes yielded BFV. With the information of the vessel diameters, retinal blood flow (RBF) in the vessels crossing a 2.5 mm diameter circle center on the fovea was calculated. To obtain the tissue volume in the same area of the macula, an optical coherence tomography angiography (OCTA, Optovue, Fremont, CA) was also used. RTP was calculated as the RBF divided by the inner retinal volume.<sup>35,38</sup>

The medical food tested in the present study (a vitamin nutraceutical formulation, Global Healthcare Focus, Montgomery, AL, USA) has been reported previously.<sup>19</sup> The ingredients are listed at the end of this paper. The medical food is intended to address ocular ischemia with high doses of vitamin B-complexes and antioxidants, including L-methylfolate, methylcobalamin, zinc, copper, lutein, vitamins C, D, E, and n-acetylcysteine. The medical food additionally reduces blood homocysteine levels by 30%.<sup>39</sup> The subjects were provided with one capsule orally each morning for the first week, then two capsules for the second week, and three capsules for the rest of the study period (6M).<sup>19,33,35</sup> Ocular imaging was performed at baseline, 4M, and 6M.

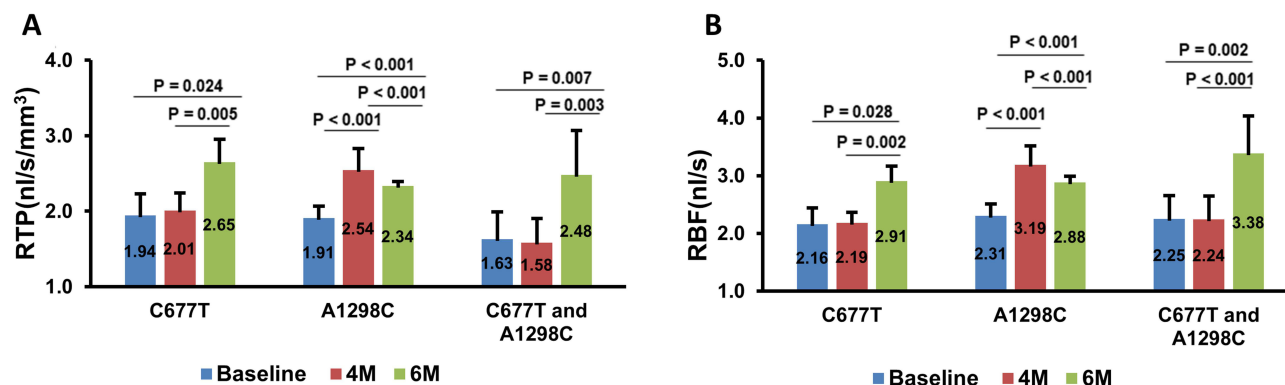
Statistical analysis was performed using the IBM SPSS Statistics software package (version 27, IBM Corp., Armonk, NY, USA). The main outcome was RTP in patients with polymorphisms of *MTHFR* over time, analyzed using a generalized estimating equation (GEE) model. P values less than 0.05 were considered statistically significant.

## Results

A total of 8 subjects participated in the study, with 75% of male subjects and a mean age of 58.3 years old (standard deviation, SD, 6.8 years). The mean diabetes duration was 14.5 years (SD 7.3 years, range 5–25 years). The HbA1c was 7.6% (SD: 0.9%, range 6.9–8.1). Five subjects had controlled hypertension. Four patients carried only the *C677T* mutation. Two patients carried only the *A1298C* mutation. And two patients carried both *C677T/A1298C* (compound heterozygous mutations).

When compared with baseline, BCVA at 4M and 6M was significantly improved compared to baseline (all  $P < 0.05$ ). Overall, significant alterations in the measurements (ie, RTP and RBF) were found after intake of the medical food, with significantly increased RTP and RBF at 6M compared to baseline (all  $P < 0.05$ ).

The impact of *MTHFR* mutations on the changes of RTP and RBF within the trial period was examined (Figure 1). In patients with only the *A1298C* mutation, all microcirculation metrics (RTP and RBF) improved at 4M, declining slightly but remaining above baseline at 6M (all  $P < 0.05$ ). In patients with the *C677T* and *C677T/A1298C* compound mutations, RTP was increased at 6M as compared to that at baseline and 4M.



**Figure 1** Effects of methylenetetrahydrofolate reductase (*MTHFR*) polymorphisms on retinal tissue perfusion (**A**) RTP and blood flow (**B**) RBF in mild diabetic retinopathy patients with methylenetetrahydrofolate reductase polymorphisms (DR + PM) patients receiving the medical food during follow-up periods. In patients with *A1298C* mutation, all vascular metrics (including RTP and RBF) were improved over the Baseline at 4 months and 6 months, but the peak benefit was at four months (all  $P < 0.05$ ). In patients with *C677T* and *C677T/A1298C* compound mutations, RTP at 6 months significantly increased as compared to those at baseline and 4 months. Bars = standard error.

## Discussion

The current study revealed a positive effect on retinal perfusion in DR patients with *MTHFR* mutations after a 6M intake of the medical food. In this study group, a similar *MTHFR* polymorphism-associated variance was also reported in conjunctival microcirculation and retinal microvascular architecture.<sup>19,33</sup> At the fourth month of medical food intake, conjunctival blood flow velocity was increased in all genotypes. For patients with the genotype of *A1298C* alone or with *C677T/A1298C*, the conjunctival blood flow rate peaked at 4M but remained well above baseline at 6M. Similarly, conjunctival vessel density was improved at 6M in all DR patients, with peak improvement at 4M for patients with *C677T/A1298C*. *C677T* patients improved at 4 months, with further improvement at 6M.

The effects of *MTHFR* polymorphisms on the improvement of retinal microvascular architecture were also studied previously.<sup>19</sup> Vessel density (VD) in superficial vascular plexus (SVP) and retinal vascular network (RVN, including SVP and deep vascular plexus) were studied in patients with DR after intake of medical food.<sup>19</sup> Overall, VD in SVP was increased at 4M after intake of the medical food. However, VD in RVN did not change. DR Patients with *C677T* combined with *A1298C* showed an increased VD in superficial and deep vascular plexuses after 6M of the medical food intake. Interestingly, DR patients with *A1298C* also showed decreased VD measurements from 4M to 6M, which is similar to the changes in RTP and RBF in the present study.

This may be viewed in the context of a study of Tunisian patients with type 2 diabetes and *MTHFR* variants demonstrating that either variant increased the risk of DR. Double heterozygotes (*A1298CC*, *C677TT*, or *A1298C/C677T*) had the greatest risk for DR and complications.<sup>40</sup> *MTHFR* gene mutations are common in the US, with the *MTHFR* *C677T* polymorphism prevalence alone being greater than 40%.<sup>15,16</sup> These *MTHFR* polymorphisms cause reduced enzyme activity and reduced synthesis of L-methylfolate, leading to a deficiency in the methylation process and resulting in elevated plasma homocysteine.<sup>16,18</sup> It appears that different *MTHFR* mutations may have different effects on disease onset, progression, and intervention efficacy.<sup>18,19</sup> Riboflavin insufficiency further impairs methylation, driving up plasma homocysteine. Biochemically the *C677T* polymorphism requires a higher level of riboflavin to recycle tetrahydrofolate into L-methylfolate,<sup>17</sup> an effect magnified by riboflavin insufficiency.<sup>16,17</sup> Horgan et al<sup>41</sup> demonstrated that in patients with the common *MTHFR* polymorphism *C677T*, there is an increase in difficult-to-treat hypertension, which responds to the administration of riboflavin. This is clinically very significant for patients with DR because DR is very sensitive to the degree of hypertension.<sup>5</sup> Elias and Brown recommend the medical food as a supplemental way to address resistant hypertension because of the blood pressure-lowering benefits of riboflavin, L-methylfolate, and n-acetylcysteine.<sup>34</sup>

Our previous studies showed retinal microvascular architectural improvements of the conjunctiva and retina in DR patients after a 6-month intake of the medical food. Improvement varied with different combinations of *MTHFR* polymorphisms.<sup>19</sup> Furthermore, our previous study also showed that retinal perfusion improved after 6 months of intake of the medical food.<sup>35</sup> The present study examines the variation of improvement in retinal perfusion in response to the

medical food according to polymorphism type. It may be relevant that the *MTHFR* C677T polymorphism has reduced sensitivity to the riboflavin co-factor FAD.<sup>42</sup> Riboflavin deficiency is associated with hyperhomocysteinemia and hypertension. Riboflavin supplementation lowers blood pressure.<sup>43</sup> Genetic defects in riboflavin transport proteins produce blindness and neurodegenerative conditions similar to dietary riboflavin deficiency.<sup>44–46</sup>

The medical food tested in the presented study is designed to reduce ischemia and retinopathy in patients with common *MTHFR* polymorphisms. It works by reducing oxidative stress in the mitochondria, optimizing critical metabolic pathways with vitamins and co-factors for methylation, reducing homocysteine, and increasing retinal blood flow. This is accomplished by using nutrient doses well above what can be obtained from dietary modification. In this context, high doses of riboflavin and l-methylfolate improve methylation leading to homocysteine reduction.<sup>29</sup> The ordinary recommended dose is three capsules each morning with food. Each capsule contains L-methylfolate 900 mcg, vitamin C (ascorbic acid) 33.3 mg, vitamin D (as Cholecalciferol) 1500 IU, vitamin E natural complex (as Alpha, Beta, Gamma, and Delta tocopherols) 7.5 IU, vitamin B1 (as thiamine hydrochloride) 1.5 mg, vitamin B2 (riboflavin) 10 mg, vitamin B6 (as pyridoxal 5'-phosphate) 3 mg, vitamin B12 (as methylcobalamin) 500 mcg, pantothenic acid (as calcium-D-pantothenate) 5 mg, zinc (as zinc oxide) 26.6 mg, selenium (as L-selenomethionine) 20 mcg, copper (as cupric oxide) 0.667 mcg, n-acetyl cysteine 180 mg, lutein 3.35 mg, and zeaxanthin 700 mcg.

Schmidl et al found a 30% decrease in homocysteine in a study of diabetic patients treated with the medical food.<sup>39</sup> Wang et al published a case series of eight cases of diabetic retinopathy demonstrating photographically documented structural improvement after long-term intake of the medical food or a nearly identical product, Eyefolate®.<sup>47</sup> A case of preservation of retinal structure after retinal artery occlusion with improvement in vision following the use of the medical food has been reported.<sup>48</sup> Although a large clinical study is needed to confirm the benefits of the medical food on DR and other conditions, the current literature supports the notion that the medical food is beneficial for DR patients with deteriorating microvascular architecture and loss of perfusion.

It is worth mentioning the limitations of the present study. As this is a pilot study, the sample size is small. Further studies with large-size samples are needed. We did not measure post-treatment homocysteine in the present study and were not able to analyze the impact of *MTHFR* mutations on serum homocysteine. The intake of this medical food was only for 6 months, and a longer follow-up may show further improvement. Future studies need to address these three points to more fully understand the effects of the medical food on homocysteine, retinal vascular density, and retinal perfusion.

In summary, the medical food tested in the present study was effective in improving both visual acuity and retinal tissue perfusion in patients with mild diabetic retinopathy and common *MTHFR* polymorphisms. The degree of improvement of retinal perfusion varied among *MTHFR* mutation subtypes.

## Funding

This study was supported by research grants from Global Healthcare Focus LLC, NIH Center Grant P30 EY014801, NINDS 1R01NS111115-01 (Wang), and a grant from the Research to Prevent Blindness (RPB).

## Disclosure

The authors report no conflicts of interest in this work.

## References

1. Stumvoll M, Goldstein BJ, van Haeften TW. Type 2 diabetes: principles of pathogenesis and therapy. *Lancet*. 2005;365:1333–1346. doi:10.1016/S0140-6736(05)61032-X
2. Angellotti E, D'Alessio D, Dawson-Hughes B, et al. Vitamin D supplementation in patients with type 2 diabetes: the vitamin D for established type 2 diabetes (DDM2) study. *J Endocr Soc*. 2018;2:310–321. doi:10.1210/js.2018-00015
3. Willett W, Manson J, Liu S. Glycemic index, glycemic load, and risk of type 2 diabetes. *Am J Clin Nutr*. 2002;76:274S–280S. doi:10.1093/ajcn/76.1.274S
4. Ekelund U, Franks PW, Sharp S, Brage S, Wareham NJ. Increase in physical activity energy expenditure is associated with reduced metabolic risk independent of change in fatness and fitness. *Diabetes Care*. 2007;30:2101–2106. doi:10.2337/dc07-0719
5. Klein BE. Overview of epidemiologic studies of diabetic retinopathy. *Ophthalmic Epidemiol*. 2007;14:179–183. doi:10.1080/09286580701396720



6. Grauslund J, Green A, Sjølie AK. Blindness in a 25-year follow-up of a population-based cohort of Danish type 1 diabetic patients. *Ophthalmology*. 2009;116:2170–2174. doi:10.1016/j.ophtha.2009.04.043
7. Yau JW, Rogers SL, Kawasaki R, et al. Global prevalence and major risk factors of diabetic retinopathy. *Diabetes Care*. 2012;35:556–564. doi:10.2337/dc11-1909
8. Zheng Y, He M, Congdon N. The worldwide epidemic of diabetic retinopathy. *Indian J Ophthalmol*. 2012;60:428–431. doi:10.4103/0301-4738.100542
9. Keel S, Xie J, Foreman J, Van WP, Taylor HR, Dirani M. The prevalence of diabetic retinopathy in Australian adults with self-reported diabetes: the national eye health survey. *Ophthalmology*. 2017;124:977–984. doi:10.1016/j.ophtha.2017.02.004
10. Yun JS, Ko SH, Kim JH, et al. Diabetic retinopathy and endothelial dysfunction in patients with type 2 diabetes mellitus. *Diabetes Metab J*. 2013;37:262–269. doi:10.4093/dmj.2013.37.4.262
11. Jousen AM, Poulaki V, Le ML, et al. A central role for inflammation in the pathogenesis of diabetic retinopathy. *FASEB J*. 2004;18:1450–1452. doi:10.1096/fj.03-1476fje
12. Willis JR, Doan QV, Gleeson M, et al. Vision-related functional burden of diabetic retinopathy across severity levels in the United States. *JAMA Ophthalmol*. 2017;135:926–932. doi:10.1001/jamaophthalmol.2017.2553
13. Nappo F, De RN, Marfella R, et al. Impairment of endothelial functions by acute hyperhomocysteinemia and reversal by antioxidant vitamins. *JAMA*. 1999;281:2113–2118. doi:10.1001/jama.281.22.2113
14. Rajendran P, Rengarajan T, Thangavel J, et al. The vascular endothelium and human diseases. *Int J Biol Sci*. 2013;9:1057–1069. doi:10.7150/ijbs.7502
15. Qi Z, Hoffman G, Kurtycz D, Yu J. Prevalence of the C677T substitution of the methylenetetrahydrofolate reductase (MTHFR) gene in Wisconsin. *Genet Med*. 2003;5:458–459. doi:10.1097/01.GIM.0000095001.12570.A8
16. Brustolin S, Giugliani R, Felix TM. Genetics of homocysteine metabolism and associated disorders. *Braz J Med Biol Res*. 2010;43:1–7. doi:10.1590/S0100-879X2009007500021
17. Hustad S, Ueland PM, Vollset SE, Zhang Y, Bjorke-Monsen AL, Schneede J. Riboflavin as a determinant of plasma total homocysteine: effect modification by the methylenetetrahydrofolate reductase C677T polymorphism. *Clin Chem*. 2000;46:1065–1071. doi:10.1093/clinchem/46.8.1065
18. Maeda M, Yamamoto I, Fukuda M, et al. MTHFR gene polymorphism as a risk factor for diabetic retinopathy in type 2 diabetic patients without serum creatinine elevation. *Diabetes Care*. 2003;26:547–548. doi:10.2337/diacare.26.2.547-a
19. Liu Z, Jiang H, Townsend JH, Wang J. Effects of Ocufolin on retinal microvasculature in patients with mild non-proliferative diabetic retinopathy carrying polymorphisms of the MTHFR gene. *BMJ Open Diabetes Res Care*. 2021;9:e002327. doi:10.1136/bmjdr-2021-002327
20. Maeda M, Fujio Y, Azuma J. MTHFR gene polymorphism and diabetic retinopathy. *Curr Diabetes Rev*. 2006;2:467–476. doi:10.2174/1573399810602040467
21. van der Put NM, Gabreels F, Stevens EM, et al. A second common mutation in the methylenetetrahydrofolate reductase gene: an additional risk factor for neural-tube defects? *Am J Hum Genet*. 1998;62:1044–1051. doi:10.1086/301825
22. Binia A, Contreras AV, Canizales-Quinteros S, Alonzo VA, Tejero ME, Silva-Zolezzi I. Geographical and ethnic distribution of single nucleotide polymorphisms within genes of the folate/homocysteine pathway metabolism. *Genes Nutr*. 2014;9:421. doi:10.1007/s12263-014-0421-7
23. Wang X, Fu J, Li Q, Zeng D, Wei Q-Y. Geographical and ethnic distributions of the MTHFR C677T, A1298C and MTRR A66G gene polymorphisms in Chinese populations: a meta-analysis. *PLoS One*. 2016;11(4):e0152414. doi:10.1371/journal.pone.0152414
24. Botto LD, Yang Q. 5,10-Methylenetetrahydrofolate reductase gene variants and congenital anomalies: a HuGE review. *Am J Epidemiol*. 2000;151:862–866. doi:10.1093/oxfordjournals.aje.a010290
25. Elias MF, Brown CJ. New evidence for homocysteine lowering for management of treatment-resistant hypertension. *Am J Hypertens*. 2022;35:303–305. doi:10.1093/ajh/hpab194
26. McNulty H, Strain JJ, Hughes CF, Ward M. Riboflavin, MTHFR genotype and blood pressure: a personalized approach to prevention and treatment of hypertension. *Mol Aspects Med*. 2017;53:2–9. doi:10.1016/j.mam.2016.10.002
27. Santana BH, de Severo AC, Dos Santos Nunes MK, et al. The MTHFR promoter hypermethylation pattern associated with the A1298C polymorphism influences lipid parameters and glycemic control in diabetic patients. *Diabetol Metab Syndr*. 2019;11:4. doi:10.1186/s13098-019-0399-9
28. Dong X, Wang J, Wang G, Wang L, Du Y. MTHFR A1298C gene polymorphism on stroke risk: an updated meta-analysis. *Genes Environ*. 2021;43:40. doi:10.1186/s41021-021-00208-z
29. Shi C, Wang P, Airen S, et al. Nutritional and medical food therapies for diabetic retinopathy. *Eye Vis*. 2020;7:33. doi:10.1186/s40662-020-00199-y
30. Raichle ME, Gusnard DA. Appraising the brain's energy budget. *Proc Natl Acad Sci U S A*. 2002;99:10237–10239. doi:10.1073/pnas.172399499
31. Yu DY, Cringle SJ. Oxygen distribution and consumption within the retina in vascularised and avascular retinas and in animal models of retinal disease. *Prog Retin Eye Res*. 2001;20:176–205. doi:10.1016/S1350-9462(00)00027-6
32. Kurihara T, Westenskow PD, Gantner ML, et al. Hypoxia-induced metabolic stress in retinal pigment epithelial cells is sufficient to induce photoreceptor degeneration. *Elife*. 2016;5. doi:10.7554/eLife.14319
33. Liu Z, Jiang H, Townsend JH, Wang J. Improved conjunctival microcirculation in diabetic retinopathy patients with MTHFR polymorphisms after Ocufolin Administration. *Microvasc Res*. 2020;132:104066. doi:10.1016/j.mvr.2020.104066
34. Elias MF, Brown CJ. Medical foods for lowering homocysteine in hypertensive patients. *J Clin Hypertens*. 2023;25:111–114. doi:10.1111/jch.14608
35. Liu Z, Jiang H, Townsend JH, Wang J. Improved retinal microcirculation in mild diabetic retinopathy patients carrying MTHFR polymorphisms who received the medical food, Ocufolin(R). *Clin Ophthalmol*. 2022;16:1497–1504. doi:10.2147/OPHTH.S358753
36. Chamberlain JJ, Rhinehart AS, Shaefer CF, Neuman A. Diagnosis and management of diabetes: synopsis of the 2016 American Diabetes Association Standards of medical care in diabetes. *Ann Intern Med*. 2016;164:542–552. doi:10.7326/M15-3016
37. Flaxel CJ, Adelman RA, Bailey ST, et al. Diabetic retinopathy preferred practice Pattern(R). *Ophthalmology*. 2020;127:66–145.
38. Liu Z, Jiang H, Townsend JH, Wang J. Retinal tissue perfusion reduction best discriminates early stage diabetic retinopathy in patients with type 2 diabetes mellitus. *Retina*. 2021;41:546–554. doi:10.1097/IAE.0000000000002880
39. Schmidl D, Werkmeister R, Szegedi S, et al. The effect of folate supplementation on systemic homocysteine plasma concentration and ocular blood flow in patients with diabetes. Schweizerische Ophthalmologische Gesellschaft (SOG) Annual conference; 2018; Friborg, Switzerland.
40. Fekih-Mrissa N, Mrad M, Ibrahim H, et al. Methylenetetrahydrofolate Reductase (MTHFR) (C677T and A1298C) Polymorphisms and vascular complications in patients with type 2 diabetes. *Can J Diabetes*. 2017;41:366–371. doi:10.1016/j.jcjd.2016.11.007

41. Horigan G, McNulty H, Ward M, Strain JJ, Purvis J, Scott JM. Riboflavin lowers blood pressure in cardiovascular disease patients homozygous for the 677C→T polymorphism in MTHFR. *J Hypertens*. 2010;28:478–486. doi:10.1097/HJH.0b013e328334c126
42. Hustad S, Schneede J, Ueland PM. *Riboflavin and Methylenetetrahydrofolate Reductase*. Austin, TX: Landes Bioscience; 2019.
43. McAuley E, McNulty H, Hughes C, Strain JJ, Ward M. Riboflavin status, MTHFR genotype and blood pressure: current evidence and implications for personalised nutrition. *Proc Nutr Soc*. 2016;75:405–414. doi:10.1017/S0029665116000197
44. Srouf M, Putorti ML, Schwartzentruber J, et al. Mutations in riboflavin transporter present with severe sensory loss and deafness in childhood. *Muscle Nerve*. 2014;50:775–779. doi:10.1002/mus.24224
45. O'Callaghan B, Bosch AM, Houlden H. An update on the genetics, clinical presentation, and pathomechanisms of human riboflavin transporter deficiency. *J Inherit Metab Dis*. 2019;42(4):598–607. doi:10.1002/jimd.12053
46. Venkataswamy G. Ocular manifestations of vitamin B-complex deficiency. *Br J Ophthalmol*. 1967;51:749–754. doi:10.1136/bjo.51.11.749
47. Wang J, Brown C, Shi C, et al. Improving diabetic and hypertensive retinopathy with a medical food containing L-Methylfolate: a preliminary report. *Eye Vis*. 2019. doi:10.1186/s40662-019-0147-0
48. Brown CJ. Preservation of retinal structure and function after cilioretinal artery occlusion: a case report. *Int Med Case Rep J*. 2016;9:29–34. doi:10.2147/IMCRJ.S96858

## Clinical Ophthalmology

Dovepress

### Publish your work in this journal

Clinical Ophthalmology is an international, peer-reviewed journal covering all subspecialties within ophthalmology. Key topics include: Optometry; Visual science; Pharmacology and drug therapy in eye diseases; Basic Sciences; Primary and Secondary eye care; Patient Safety and Quality of Care Improvements. This journal is indexed on PubMed Central and CAS, and is the official journal of The Society of Clinical Ophthalmology (SCO). The manuscript management system is completely online and includes a very quick and fair peer-review system, which is all easy to use. Visit <http://www.dovepress.com/testimonials.php> to read real quotes from published authors.

Submit your manuscript here: <https://www.dovepress.com/clinical-ophthalmology-journal>