

Inferior displacement of the lower eyelid during intraoperative quantification in blepharoptosis surgery

Hirohiko Kakizaki
Yasuhiro Takahashi
Masahiro Zako
Masayoshi Iwaki

Department of Ophthalmology,
Aichi Medical University,
Nagakute, Aichi, Japan

Purpose: To examine inferior displacement of the lower eyelid during eye closing in intraoperative quantification of blepharoptosis surgery.

Methods: A series of lower eyelid movements during eye closing in intraoperative quantification of blepharoptosis surgery were examined in 30 eyelids of 15 patients (6 males and 9 females; mean age 70.0 years; range 43–81 years) with bilateral aponeurotic blepharoptosis.

Results: Inferior displacement of the lower eyelid was observed in all eyelids examined, although the extent varied in each patient (range 2.0–4.5 mm; mean 3.2 mm). Inferior displacement occurred with upward eye movement caused by Bell's phenomenon. Many wrinkles were simultaneously observed as a result of contraction of the orbicularis oculi muscle. After maintaining the inferiorly displaced state for several seconds, 20 lower eyelids in 10 patients naturally moved superiorly to a resting position. On the other hand, 10 lower eyelids in 5 patients remained in the same inferior position for more than 5 seconds, after which we had to manually elevate them to a resting position. The eyes then moved inferiorly to their resting position with a decrease in the number of lower eyelid wrinkles. Once the patients opened their eyes, inferior displacement of the lower eyelid completely disappeared.

Conclusions: Inferior displacement of the lower eyelid during eye closing increases the amount of lagophthalmos. This phenomenon needs to be considered for quantifying the intraoperative lagophthalmos level during blepharoptosis surgery.

Keywords: blepharoptosis surgery, eye closing, inferior displacement, intraoperative quantification, lower eyelid

Introduction

Intraoperative quantification is generally performed during eye opening in blepharoptosis surgery.^{1–5} However, occasionally the upper eyelid height may be influenced by epinephrine affecting the Müller muscle or direct anesthesia to the levator palpebrae superioris muscle. Under these conditions, supplemental quantification during eye closing is helpful to estimate the appropriate amount of levator advancement.⁶ Less than 2 mm of lagophthalmos after downward push of the upper eyelid is a safe indicator to prevent postoperative lagophthalmos.⁶

However, paradoxical downward movement of the lower eyelid during eye closing sometimes occurs in intraoperative quantification of blepharoptosis surgery, which has not been known until now. Because inferior displacement of the lower eyelid during eye closing increases the amount of lagophthalmos and influences intraoperative quantification, evaluation of this phenomenon is required to determine the correct lagophthalmos level.

Correspondence: Hirohiko Kakizaki
Department of Ophthalmology,
Aichi Medical University, Nagakute,
Aichi 480-1195, Japan
Tel +81 561 62 3311
Fax +81 561 63 7255
Email cosme@d1.dion.ne.jp

In this study, we examined a series of lower eyelid movements during eye closing in intraoperative quantification of blepharoptosis surgery.

Materials and methods

Thirty eyelids of 15 patients (6 males and 9 females; mean age 70.0 years; range 43–81 years) with bilateral aponeurotic blepharoptosis were examined. All patients were preoperatively informed of the study and consented to the study.

Intraoperative quantification of blepharoptosis surgery during eye closing was as follows:⁶ if a patient presented with more than 3 mm of lagophthalmos during eye closing but could still open the upper eyelid, we forcibly closed the upper eyelid manually following the voluntary eyelid closing. If more than 3 mm of lagophthalmos was still observed after this procedure, we corrected the eyelid tension so that it was more relaxed until the lagophthalmos became less than 2 mm.

In the above situation, we have sometimes experienced a paradoxical downward movement of the lower eyelid, which has made it difficult to make an appropriate judgment of the quantification. Therefore, we examined a series of lower eyelid movements during eye closing in intraoperative quantification of blepharoptosis surgery. The degree of inferior displacement of the lower eyelid was measured on photographs with a millimeter ruler to the nearest 0.5 mm. The reference was set on the horizontal line through the medial canthal angle. The positive value of inferior displacement of the lower eyelid was determined as more than 2 mm of lower movement, because lower eyelid motion during normal blinking is occasionally accompanied by downward movement of 1 or 2 mm.⁷ Serial photographs were taken with a digital camera (HandyCam DCR-PC300K; Sony, Tokyo, Japan). During observations, we pulled the upper eyelid slightly superiorly using a hook to facilitate observation of lower eyelid movements.

Results

Inferior displacement of the lower eyelid was observed in all the eyelids examined, although the extent of displacement varied in each patient. The range was 2.0 to 4.5 mm (mean 3.2 mm). Inferior displacement occurred with upward eye movement caused by Bell's phenomenon⁸ (Figure 1A, B). Many wrinkles were simultaneously observed as a result of contraction of the orbicularis oculi muscle. After maintaining the inferiorly displaced state for several seconds, 20 lower eyelids in 10 patients naturally moved

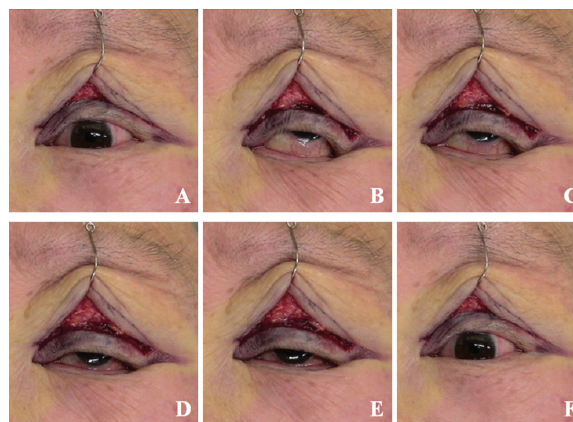


Figure 1 Serial photographs of lower eyelid inferior displacement during eye closing. **A)** The eye is open and the lower eyelid is in a relaxed position. **B)** The patient is instructed to close the eyes (**B–E** show various states during eye closing). The lower eyelid is lowered. Many wrinkles are caused by orbicularis contraction. The eye shows supraduction caused by Bell's phenomenon. **C–E)** Over time, the lower eyelid moves superiorly to a relaxed position, accompanied by a decrease in the wrinkles. The eye also moves to a relaxed position. **F)** The patient opens the eye again. Inferior displacement of the lower eyelid is resolved.

superiorly to a resting position. On the other hand, 10 lower eyelids in 5 patients remained in the same inferior position for more than 5 seconds, after which we had to elevate them manually to a resting position (Figure 1C–E). The eyes then moved inferiorly to their resting position with a decrease in the number of lower eyelid wrinkles (Figure 1C–E). Once the patients opened their eyes, inferior displacement of the lower eyelids completely disappeared (Figure 1F).

Discussion

We determined the characteristics of inferior displacement of the lower eyelid during eye closing in intraoperative quantification of blepharoptosis surgery.

A possible mechanism responsible for inferior displacement of the lower eyelid is related to the anatomical course of the orbicularis oculi muscle in the eyelid margin. It originates from the posterior lacrimal crest, goes anteriorly to take an arched shape on the way and is directed posteriorly toward the orbit to insert onto the lateral orbital tubercle.⁹ The eyelid margin orbicularis oculi muscle has an arched shape explained as above and its contraction causes it to be flattened moving posteriorly. In addition, the lower eyelid margin is situated on the downward slope of the eyeball. According to these features, the lower eyelid margin moves posteriorly during eye closing⁸ and slides inferiorly on the globe.

The degree of insufficient voluntary eye closing needs to be precisely evaluated to prevent postoperative lagophthalmos.⁶ Incomplete voluntary eye closing is caused by over-corrected levator advancement or insufficient motility of the orbicularis oculi muscle induced by an anesthetic effect. Manual assistance

for eye closing helps to distinguish these two states⁶ and less than 2 mm of lagophthalmos after downward push of the upper eyelid is within the tolerable level for patients to close the eyes completely in the postoperative period.⁶ When the blepharoptosis is over-corrected, there is still lagophthalmos of more than 3 mm after the downward push. When orbicularis movement is insufficient, lagophthalmos less than 2 mm is present after manual assistance. Under these conditions, paradoxical downward movement of the lower eyelid sometimes makes it difficult to make an appropriate judgment. The results of our study could contribute to correct measurement of intraoperative quantification.

All the patients demonstrated Bell's phenomenon during eye closing in intraoperative quantification.^{7,8} This phenomenon is accompanied by upward rotation of the globe with downward shift of the lower eyelid,⁷ which makes it difficult for surgeons to judge the precise amount of lagophthalmos. A previous report⁶ showed that lagophthalmos was observed for less than 5 seconds after supplemental downward push of the upper eyelid. In our study, inferior displacement of the lower eyelid occasionally continued for more than 5 seconds. Complete resolution of inferior displacement of the lower eyelid is required as well as evaluation of the precise amount of lagophthalmos.

In conclusion, inferior displacement of the lower eyelid during eye closing increases the amount of lagophthalmos.

This phenomenon needs to be considered in quantifying intraoperative lagophthalmos levels during blepharoptosis surgery.

Disclosure

The authors declared no conflicts of interest in relation to this paper.

References

1. Older JJ. Levator aponeurosis surgery for the correction of acquired ptosis: analysis of 113 procedures. *Ophthalmology*. 1983;90:1056–1059.
2. Linberg JV, Vasquez RJ, Chao G-M. Aponeurotic ptosis repair under local anesthesia: prediction of results from operative lid height. *Ophthalmology*. 1988;95:1046–1052.
3. Small RG, Sabates NR, Burrows D. The measurement and definition of ptosis. *Ophthalm Plast Reconstr Surg*. 1989;5:171–175.
4. Collin JRO, O'Donnell BA. Adjustable sutures in eyelid surgery for ptosis and lid retraction. *Br J Ophthalmol*. 1994;78:167–174.
5. Landa M, Bedrossian EH Jr. Blepharoptosis. In: Della Rocca RC, Bedrossian EH Jr, Arthus BP, editors. *Ophthalmic Plastic Surgery: Decision making and techniques*. New York, NY: McGraw-Hill; 2002: 77–89.
6. Kakizaki H, Zako M, Mito H, Iwaki M. Intra-operative quantification using finger force for involutional blepharoptosis without post-operative lagophthalmos. *Jpn J Ophthalmol*. 2006;50:135–140.
7. Doane MG. Interaction of eyelids and tears in corneal wetting and the dynamics of the normal human eyeblink. *Am J Ophthalmol*. 1980;89:507–516.
8. Kanski JJ. *Clinical Ophthalmology*. 5th ed. Oxford, UK: Butterworth-Heinemann; 2003:1–42.
9. Kakizaki H, Zako M, Nakano T, Asamoto K, Miyaishi O, Iwaki M. Microscopic findings of lateral tarsal fixation in Asians. *Ophthalm Plast Reconstr Surg*. 2008;24:131–135.

Clinical Ophthalmology

Publish your work in this journal

Clinical Ophthalmology is an international, peer-reviewed journal covering all subspecialties within ophthalmology. Key topics include: Optometry; Visual science; Pharmacology and drug therapy in eye diseases; Basic Sciences; Primary and Secondary eye care; Patient Safety and Quality of Care Improvements. This journal is indexed on PubMed

Submit your manuscript here: <http://www.dovepress.com/clinical-ophthalmology-journal>

Dovepress

Central and CAS, and is the official journal of The Society of Clinical Ophthalmology (SCO). The manuscript management system is completely online and includes a very quick and fair peer-review system, which is all easy to use. Visit <http://www.dovepress.com/testimonials.php> to read real quotes from published authors.