

# Ultrasound-Guided Urokinase in the Remedy of Spontaneous Vaginal Hematoma After Vaginal Delivery: A Case Report

Jin Shang<sup>1</sup>, Juan Li<sup>2</sup>, Qing Bai<sup>2</sup>, Yongmei Wang<sup>2</sup>, Hongjian Chen<sup>1</sup>, Shunxu Li<sup>2</sup>

<sup>1</sup>Department of Ultrasound, The Third People's Hospital of Yunnan, Kunming, People's Republic of China; <sup>2</sup>Department of Obstetrics, The Third People's Hospital of Yunnan, Kunming, People's Republic of China

Correspondence: Shunxu Li, Department of Obstetrics, The Third People's Hospital of Yunnan, No. 292 Beijing Road, Guandu District, Kunming, 650011, People's Republic of China, Tel +86 15925210080, Fax +86 871 63196549, Email 63505214@qq.com

**Introduction:** Vaginal hematoma is commonly treated by traditional incision and sutures. In this report, we describe the treatment of a spontaneous vaginal hematoma after vaginal delivery by ultrasound-guided urokinase injection.

**Case Presentation:** A 32-year-old multipara developed a spontaneous vaginal hematoma after vaginal delivery. The hematoma diagnosed via ultrasound examination of the postpartum pelvic basin was located in the posterior vaginal wall, and measured to be  $8.92 \times 5.71$  cm from transvaginal ultrasonography. After considering the size and position of the hematoma, treatment by urokinase injection under ultrasound guidance was selected and performed three times. Forty-two days after the last treatment, the hematoma had disappeared.

**Discussion and Conclusion:** For patients in stable condition, when incision and sutures of vaginal hematoma after natural delivery is difficult to perform, urokinase injection under ultrasound guidance can be an effective treatment method that helps in the absorption of the hematoma.

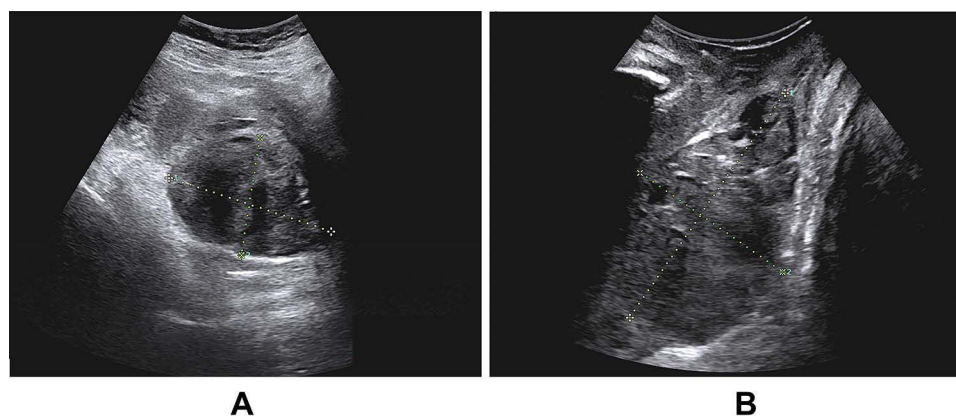
**Keywords:** ultrasound, urokinase, vaginal hematoma, treatment

## Introduction

Vaginal hematoma is a common complication in natural childbirth that causes postpartum hemorrhage, which can be life-threatening.<sup>1</sup> Hematomas are most commonly treated using incision and sutures, while uterine arterial embolization is used to treat complicated hematomas.<sup>2</sup> When the hematoma is deep, it needs to be surgically removed under anesthesia. Furthermore, the inaccessible location makes exposing and suturing the hematoma difficult and increases the risk of secondary injury and operation failure.<sup>3</sup> The success of the neurosurgical application of urokinase in the treatment of craniocerebral hematoma has led obstetricians to consider it for treating pelvic hematomas. While a literature review has examined hematomas associated with childbirth,<sup>4</sup> the present report is the first to describe the use of urokinase injection for treating vaginal hematoma under ultrasound guidance.

## Case Presentation

A 32-year-old multipara at 41 weeks of pregnancy was admitted to our hospital. Childbirth commenced naturally, and the patient delivered a baby weighing 3150 g. She sustained a first-degree perineal laceration but no vaginal laceration. A rectal examination 2 hours after delivery revealed no hematomas, and the patient reported no anal swelling. On the first postpartum day, routine pelvic floor ultrasound examination revealed a slightly hypoechoic mass near the posterior wall of the vagina, which was about  $8.32 \times 5.41$  cm in size by abdominal ultrasonography (Figure 1A) and  $8.92 \times 5.71$  cm in size by vaginal ultrasonography (Figure 1B). It was diagnosed as a vaginal hematoma.



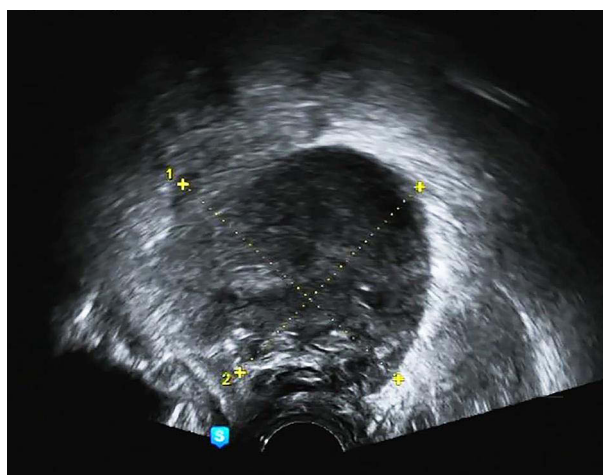
**Figure 1** Grayscale ultrasound image showing a cystic solid mass with clear boundaries in the posterior vaginal wall by abdominal ultrasonography (2020.05.23, (A)) and vaginal ultrasonography (2020.05.23, (B)).

Because the hematoma was large and located deep in the vaginal wall, exposing and surgically removing it was difficult. At 2 days postpartum, the vital signs were stable, and we speculated that the patient had no active bleeding. However, her hemoglobin level dropped to 79 g/L, so she received a transfusion of 1.5 u red blood cells and 200 mL fresh frozen plasma. After discussion and comprehensive evaluation, we performed conservative treatment. If the hematoma increased in size, it may compress the rectum and bladder, resulting in urination difficulties and anal distension. Thus, promoting hematoma absorption is critical.

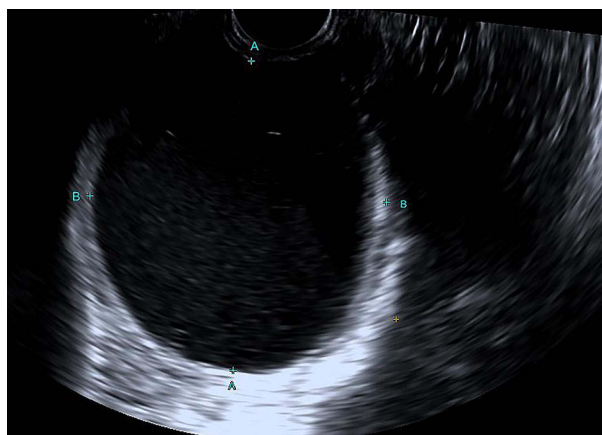After considering the previous success of using urokinase to promote the absorption of hematoma in neurosurgery,<sup>5</sup> as well as the patient's risk for infection and the long absorption time of the hematoma, urokinase was injected into the hematoma under ultrasound on the fourth day postpartum.

The hematoma was examined again before the operation, and its size was about  $7.62 \times 6.79$  cm (Figure 2). Under the guidance of real-time ultrasound, a puncture needle was inserted into the lesion, and a small amount of pooled blood was obtained, which further confirmed our diagnosis of vaginal hematoma. Then, 100,000 units of urokinase with 50 mL normal saline were repeatedly infused into the hematoma, with 20 mL of urokinase retained.

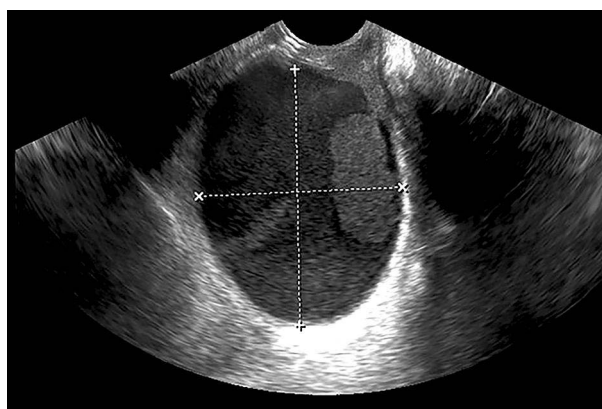After 8 days, the patient received the second treatment. The hematoma was measured again, and its size was about  $7.06 \times 6.77$  cm (Figure 3). This time, we withdrew 135 mL of pooled blood. Then, urokinase was infused into the hematoma, with 20 mL retained.



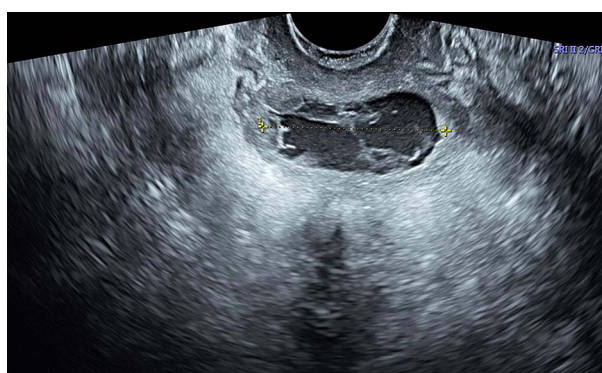**Figure 2** Grayscale ultrasound image showing a well-defined mass in the posterior vaginal wall (2020.05.25).



**Figure 3** Vaginal ultrasound image showing a dark liquid area (2020.06.03).



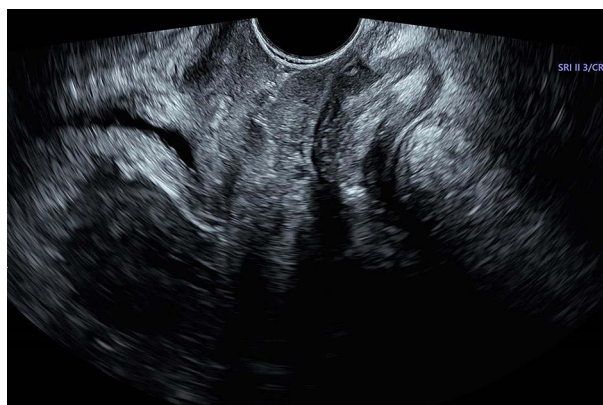
**Figure 4** Vaginal ultrasound showing a dark, liquid area (2020.06.10).



**Figure 5** Grayscale ultrasound image showing the length of a mass (2020.06.15).

After 7 days, the patient received a third urokinase treatment. The size of hematoma had shrunk to  $6.61 \times 5.27$  cm (Figure 4). As performed previously, 180 mL of pooled blood was aspirated, and 20 mL urokinase was retained in the hematoma.

Five days after the third treatment, we performed another ultrasound examination. The length of the hematoma had shrunk significantly to 4.09 cm (Figure 5). Thus, we stopped the treatment and allowed the hematoma to be absorbed. On examination at 42 days postpartum, the hematoma had dramatically disappeared (Figure 6).



**Figure 6** Normal vaginal ultrasound image indicating the disappearance of the mass (2020.07.03).

## Discussion and Conclusion

The vulva and vagina are rich in blood vessels with soft subcutaneous tissues, making these areas prone to hematoma formation owing to the rupture of subcutaneous blood vessels.<sup>6</sup> With increasing age, the elasticity of the birth canal tissue decreases and the brittleness of blood vessels increases.<sup>7</sup> This increases the likelihood of birth canal scarring and poor ductility of the vaginal wall, which further increasing the risk of bleeding and subsequent hematoma formation. However, not all women develop anal swelling. Consequently, an ultrasound examination of the postpartum pelvic floor after vaginal delivery is necessary. Doctors should monitor hemoglobin levels or perform a digital rectal test the following day. The present case demonstrates the necessity of these interventions.

Studies have shown that arterial embolization using interventional embolization technology for preventive or therapeutic embolization, such as by interventional angiography, is effective in treating vaginal hematoma.<sup>8</sup> However, complications can develop, such as excessive embolism, false embolism, and vascular injury.

Urokinase is a type of plasminogen activator with a thrombolytic effect. Thus, it can promote the degradation and transformation of fibrin and massive hematomas.<sup>9</sup> It has been used in neurosurgery for treating intracranial hematomas with a remarkable curative effect. Based on these successes, we used urokinase in the present case to dissolve the vaginal hematoma and successfully promote hematoma absorption. Performed under ultrasound guidance, urokinase treatment features few side effects, low risk, fast recovery, and accurate treatment. However, this treatment is not a standard procedure for vaginal hematomas. Rather, it is an option when the hematoma is discovered late and is difficult to cut and suture in a patient with normal blood pressure and heart rate. While complications, such as fever, infection, and bleeding, are commonly reported with urokinase treatment of intracranial hematomas,<sup>10</sup> we did not observe such complications in the present case. However, more cases are needed to draw further conclusions.

Urokinase injection presents a new minimally invasive method for treating vaginal hematomas contraindicated for incision and suture. The treatment facilitates the hematoma absorption, reduces the risk of the hematoma affecting rectal and bladder function, and reduces the risk of infection. This study is the first successful report on the treatment of a vaginal hematoma by urokinase injection.

## Data Sharing Statement

The original data presented in the study are included in the article. Further inquiries can be directed to the corresponding author.

## Ethics Approval and Informed Consent

Written informed consent was obtained from the patient. We further obtained ethical clearance from the Institutional Ethics Review Board of The Third People's Hospital of Yunnan (2020003). The writing and publishing of this case report was approved by The Third People's Hospital of Yunnan.

## Consent for Publication

Written informed consent was obtained from the patient for the publication of this report.

## Author Contributions

All authors made substantial contributions to conception and design, as well as the acquisition, analysis, and interpretation of data; took part in drafting the article or revising it critically for important intellectual content; have agreed to submission to the current journal; gave final approval of the version to be published; and have agreed to be accountable for all aspects of the work.

## Funding

There is no funding to report.

## Disclosure

The authors have no conflicts of interest to disclose for this work.

## References

1. Wais M, Chan C. Massive vaginal hematoma—a complication of in vitro fertilization. *J Obstetr Gynaecol Canada*. 2018;40(1):72–74. doi:10.1016/j.jogc.2017.05.016
2. Aoki M, Tokue H, Miyazaki M, et al. Primary postpartum hemorrhage: outcome of uterine artery embolization. *Br J Radiol*. 2018;91(1087):20180132. doi:10.1259/bjr.20180132
3. Varvoutis M, Nguyen NTT, Grotegut C. Spontaneous broad ligament hematoma after vaginal delivery requiring hysterectomy. *AJP Rep*. 2021;11(1):e34. doi:10.1055/s-0040-1722727
4. Zheng HX, Nyam TTE, Liu CA, et al. Spontaneous spinal epidural hematoma after normal spontaneous delivery with epidural analgesia: case report and literature review. *World Neurosurg*. 2020;137:214–217. doi:10.1016/j.wneu.2020.01.240
5. Zhuo J, Xu Y, Zhang J, et al. Prediction models for recurrence of chronic subdural hematoma in patients underwent twist-drill craniostomy combined with urokinase instillation. *J Craniofacial Surg*. 2020;31(8):2267–2272. doi:10.1097/SCS.0000000000006779
6. Rachaneni S, Dua A. Interventions to reduce morbidity from vault hematoma following vaginal hysterectomy: a systematic review and meta-analysis. *Int Urogynecol J*. 2019;30(7):1061–1070. doi:10.1007/s00192-018-3829-6
7. Bhansakarya R, Subedi S. Broad ligament hematoma following vaginal delivery—a rare entity. *J Nobel Med Coll*. 2019;8(1):63–65. doi:10.3126/jonmc.v8i1.24481
8. Lee HJ, Kim M, Lim BB, et al. Transcatheter arterial embolization in the management of postpartum hemorrhage due to genital tract injury after vaginal delivery. *J Vasc Intervent Radiol*. 2021;32(1):99–105. doi:10.1016/j.jvir.2020.08.025
9. Cho SW, Choi SW, Lim J, et al. Burr hole drainage with urokinase irrigation for the treatment of acute subdural hematoma: a case report. *Korean J Neurotrauma*. 2018;14(2):142. doi:10.13004/kjnt.2018.14.2.142
10. Zhang R, Wei H, Ren Y, et al. Outcomes and treatment complications of intravenous urokinase thrombolysis in acute ischemic stroke in China. *Front Neurol*. 2021;7(12):685454. doi:10.3389/fneur.2021.685454

International Journal of Women's Health

Dovepress

### Publish your work in this journal

The International Journal of Women's Health is an international, peer-reviewed open-access journal publishing original research, reports, editorials, reviews and commentaries on all aspects of women's healthcare including gynecology, obstetrics, and breast cancer. The manuscript management system is completely online and includes a very quick and fair peer-review system, which is all easy to use. Visit <http://www.dovepress.com/testimonials.php> to read real quotes from published authors.

Submit your manuscript here: <https://www.dovepress.com/international-journal-of-womens-health-journal>