

# Successful Retreatment with Crizotinib After Crizotinib-Induced Liver Failure in ALK-Positive Advanced Lung Adenocarcinoma: A Case Report

Xiangming Zhang<sup>1</sup>, Kai Ni<sup>1</sup>, Huijun Chen<sup>2</sup>

<sup>1</sup>Department of Respiratory Medicine, Jinxi District of Jinhua Municipal Central Hospital, Jinhua, People's Republic of China; <sup>2</sup>Department of Respiratory and Critical Care Medicine, Affiliated Jinhua Hospital, Zhejiang University School of Medicine, Jinhua, People's Republic of China

Correspondence: Huijun Chen, Department of Respiratory and Critical Care Medicine, Affiliated Jinhua Hospital, Zhejiang University School of Medicine, 365 East Renmin Road, Jinhua, 321000, Zhejiang Province, People's Republic of China, Tel +86 0579 82552278, Fax +86 0579 82318024, Email chj0577@163.com

**Abstract:** Patients with non-small cell lung cancer (NSCLC) harboring anaplastic lymphoma kinase (ALK) gene rearrangements are treated with crizotinib. However, treatment with crizotinib is often discontinued owing to hepatotoxicity. Herein, we report a case of crizotinib-induced liver failure that was successfully treated. A 70-year-old woman complained of a cough with blood in her sputum and presented to our hospital in September 2020. Imaging examination revealed a mass in the middle and lower lobes of the right lung invading the right pulmonary artery and metastases to the right hilar lymph nodes and pleura. A stage IVa (cT4N1M1a) lung adenocarcinoma with ALK fusion was diagnosed. The patient received crizotinib, an ALK tyrosine kinase inhibitor and achieved partial remission. However, she suffered from acute liver failure, which led to the cessation of treatment. The patient was started on a liver protection treatment, and the liver function subsequently recovered. One year later, crizotinib was readministered at a half-dose because of disease progression, and the patient achieved stable disease without hepatotoxicity for 9 months. Therefore, the patient benefited from crizotinib without hepatotoxicity one year after acute liver failure caused by crizotinib.

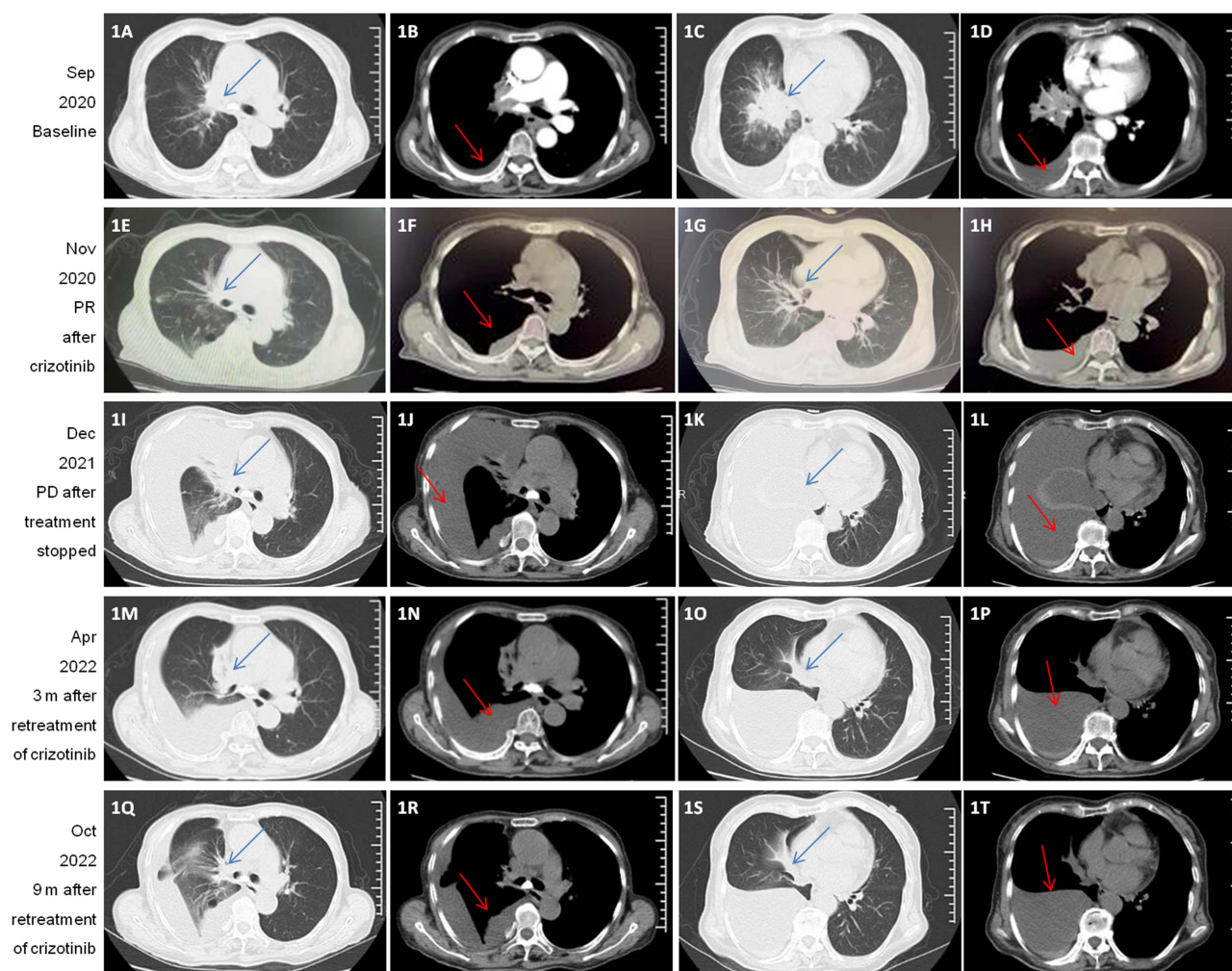
**Keywords:** crizotinib, liver failure, lung adenocarcinoma, ALK, retreatment

## Introduction

Tumorigenic rearrangements in anaplastic lymphoma kinase (ALK) account for 3–7% of non-small cell lung cancer (NSCLC) cases.<sup>1</sup> Crizotinib, a first-generation ALK inhibitor, is used as a first-line of treatment for ALK-positive tumors. Crizotinib has been shown to prolong survival, and its efficacy and safety have also been demonstrated.<sup>2</sup> However, treatment with crizotinib is associated with several adverse events, of which elevated levels of transaminases are the most common, which may lead to acute liver failure.<sup>3,4</sup> Successful retreatment after acute liver failure is rare. Herein, we report a case of a 70-year-old woman with crizotinib-induced acute liver who was successfully retreated with crizotinib without hepatotoxicity one year after treatment cessation.

## Case Presentation

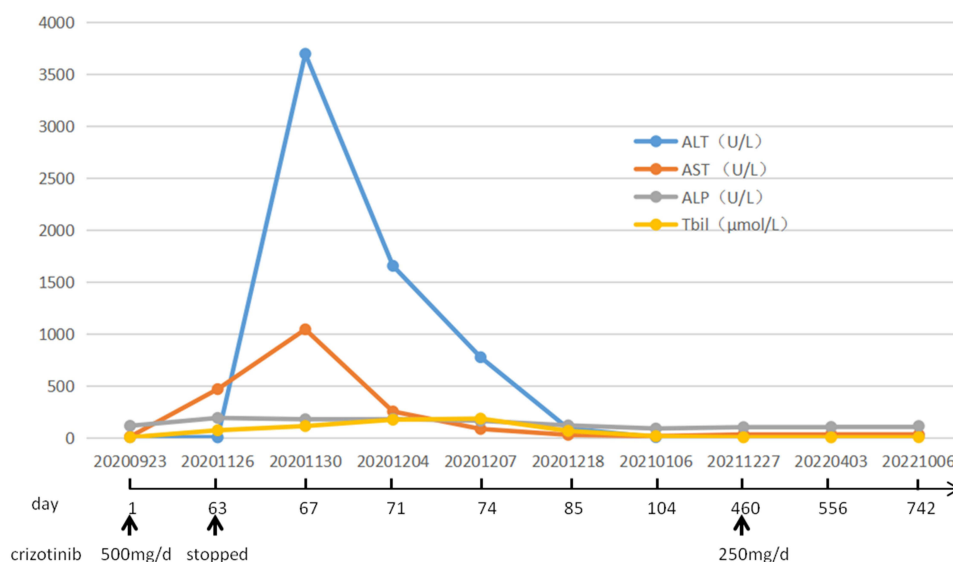
A 70-year-old woman presented to our hospital in September 2020 for a cough with bloody sputum. Enhanced chest computed tomography showed lung cancer in the middle (Figure 1A and B) and lower lobes of the right lung (Figure 1C and D), invading the right pulmonary artery, with metastasis in the right hilar lymph nodes and the right pleura, accompanied by right pleural effusion (Figure 1B and D). Double ALK fusions, EML4/ALK and ADCY3/ALK, were identified in biopsy tissues by next-generation sequencing 10-gene panel profiling. A stage IVa (cT4N1M1a) lung adenocarcinoma with ALK fusion was diagnosed. The patient was started on the ALK- tyrosine kinase inhibitor (TKI), crizotinib, twice daily (250 mg). After 9 weeks of treatment, the lesions and pleural effusion decreased, and partial response was achieved (Figure 1E–H). However, treatment with crizotinib had to be interrupted as the patient complained of fatigue, anorexia, nausea, and vomiting and



**Figure 1** Computed tomography scans showing clinical response to treatments. (A–D) Computed tomography scan of lesions and pleural effusion at baseline. (E–H) The patient achieved partial remission after crizotinib treatment. (I–L) PD with mass enlargement and increased pleural effusion. (M–P) Three months after half-dose crizotinib treatment, the patient achieved SD, (Q–T) which was maintained for more than 9 months. Blue arrows indicate lesions, and red arrows indicate pleural effusion.

**Abbreviations:** PR, partial remission; PD, progressive disease; SD, stable disease; m, months.

showed acute liver failure, grade 4 according to the CSH (Chinese Society of Hepatology) guidelines for the diagnosis and treatment of drug-induced liver injury,<sup>5</sup> accompanied by abnormal levels of aminotransferases (alanine aminotransferase, 3700 U/L; aspartate aminotransferase, 1049 U/L), alkaline phosphatase (187 U/L), and total bilirubin (179.9  $\mu\text{mol/L}$ ); prothrombin time activity (25.2%); and international standardized ratio (2.3) and a moderate amount of ascites (Figure 2). The results of the ultrasonography of the liver and gallbladder, hepatitis virology, and autoimmune markers were normal. The patient had no history of alcohol or other drug intake. Therefore, drug-induced liver injury (DILI) caused by crizotinib was identified by Hy's Law. The patient was started on a liver protection treatment with magnesium isoglycyrrhizinate, silybin, ademetonine 1,4-butanedisulfonate, and methylprednisolone, and the liver function recovered completely within 40 days. Among other ALK-TKIs, alectinib and ceritinib were covered by medical insurance, but their use in local hospitals had not yet begun. Moreover, the patient could not afford them. She refused further antitumor treatment until she failed to tolerate dyspnea due to tumor progression one year later. However, she had taken the remaining crizotinib at half-dose for 2 weeks before hospital without any liver function damage. As the patient had benefited from the first-line treatment of crizotinib, crizotinib 250 mg once daily was continued, deferring to the patient's wishes. The symptoms improved within a month, and for the next 9 months the patient showed stable disease without hypohepatia (Figure 1Q–T).



**Figure 2** Timeline and trends of liver function. The selected liver function tests (LFTs) were normal at baseline and increased after nine weeks of treatment with crizotinib. Liver function recovered after treatment interruption and initiation of a liver protection treatment for 40 days. Crizotinib was administered again at a half-dose without liver injury. Normal values for LFTs at our institution are as follows: ALT, 5–40 U/L; AST, 5–40 U/L; ALP, 50–136 U/L; and Tbil, 5.1–22 μmol/L.

**Abbreviations:** LFTs, the selected liver function tests; ALT, alanine aminotransferase; AST, aspartate aminotransferase; ALP, alkaline phosphatase; Tbil, total bilirubin.

## Discussion

In this study, we report a case of crizotinib-induced acute liver failure (DILI grade 4), which was reversed after treatment cessation and initiation of a liver protection treatment for 40 days. The patient was administered crizotinib (250 mg, once daily) one year later and achieved stable disease without liver damage.

Drug-induced liver damage is one of the most common and serious adverse reactions that can lead to acute liver failure and even death. Although the efficacy and safety of crizotinib for the treatment of patients with metastatic NSCLC with ALK rearrangements have been demonstrated,<sup>2,6</sup> liver toxicity induced by crizotinib should not be underestimated. Increased transaminase levels accounted for 69.2% (72/104) of any-grade adverse events and 11.5% (12/104) of grade 3 or 4 adverse events in East Asian patients with NSCLC and ALK.<sup>7</sup> Most patients with crizotinib-induced DILI recovered after treatment interruption; however, there were three cases of fatality, and the median duration to the onset of liver enzyme abnormalities was 17 days. Ota et al reported that most crizotinib-induced DILIs are hepatocellular, with no association with the initial prescribed dose, and the onset of liver enzyme abnormalities in cases of fatality is sooner.<sup>8</sup> However, in the presence of hepatocellular jaundice, the mortality rate of DILI is as high as 10%,<sup>9</sup> and treatment with systemic corticosteroids is controversial. In our case, the DILI was hepatocellular, grade 4, and accompanied by jaundice. Treatment with crizotinib was immediately interrupted when abnormal levels of aminotransferases were first observed, and hepatitis recovered completely after treatment with liver-protecting drugs and systemic corticosteroids. Treatment with systemic corticosteroids may reduce the inflammatory responses in hepatocytes. However, the mechanisms underlying crizotinib-induced hepatotoxicity remain unclear. Type 4 and type 1 hypersensitivity reactions may play a role in crizotinib-induced liver injury.<sup>3</sup> Previous studies have shown that crizotinib activates the oxidative stress response and stimulates hepatocyte mitochondrial apoptosis through reactive oxygen species (ROS) and the nuclear factor erythroid 2-related factor 2 (Nrf2) pathway in human hepatocytes<sup>10</sup> and that accumulation of ROS promotes pyroptosis and excessive autophagy.<sup>11</sup> Further studies are needed to clarify the mechanism of crizotinib-induced hepatotoxicity.

There is still a lack of consensus on developing a follow-up clinical strategy for crizotinib treatment after interruption. Our patient refused antitumor treatment, including systemic chemotherapy and other ALK-TKIs. A case of successful oral desensitization with crizotinib after drug-induced hepatitis was reported.<sup>3</sup> In our case, the patient accepted treatment with crizotinib at half the initial dose one year after treatment cessation due to disease symptoms, such as dyspnea. The treatment did not cause liver injury. Moreover, the median progression-free survival (PFS) of crizotinib is 11.1 months as first-line<sup>7</sup> and 8.1 months as second-line treatment in Asian patients.<sup>12</sup> The patient survived for more than two years even after discontinuing treatment for a year. Additionally, the hepatotoxicity of crizotinib in our case was not dose-dependent, and it was unclear whether

the therapeutic effect increased after the dosage increased. As the first-line treatment of the patient reached partial remission, retreatment with crizotinib may prolong the PFS, increasing the opportunity for the use of more ALK-TKIs in the future, which may effectively increase overall survival.

## Conclusion

Herein, we report a case of stage IVa lung adenocarcinoma with ALK fusions. The patient achieved partial response but suffered from crizotinib-induced acute liver failure, which was reversed after initiation of a liver protection treatment and cessation of crizotinib. Owing to disease progression a year later, the patient was restarted on crizotinib at half-dose and achieved stable disease without liver injury for 9 months. This report of PFS of 9 months after retreatment of crizotinib is rare.

## Ethics Statement and Consent to Participate

This study was approved by the Ethical Committee of Medical Research, Jinxi District, Jinhua Municipal Central Hospital. Written informed consent was obtained from the patient for publication of this report.

## Acknowledgments

This work was supported by the Public Welfare Project of the Social Development of the Jinhua Science and Technology Bureau (2018-4-090).

## Disclosure

The authors report no conflicts of interest in this work.

## References

1. Addeo A, Tabbò F, Robinson T, Buffoni L, Novello S. Precision medicine in ALK rearranged NSCLC: a rapidly evolving scenario. *Crit Rev Oncol Hematol*. 2018;122:150–156. doi:10.1016/j.critrevonc.2017.12.015
2. Krawczyk P, Grenda A, Terlecka P, et al. Crizotinib efficacy in advanced non-squamous NSCLC patients with ALK or ROS1 rearrangement. *Sci Rep*. 2021;11(1):20939. doi:10.1038/s41598-021-00309-3
3. Yasuda Y, Nishikawa Y, Sakamori Y, et al. Successful oral desensitization with crizotinib after crizotinib-induced hepatitis in an anaplastic lymphoma kinase-rearranged non-small-cell lung cancer patient: a case report. *Mol Clin Oncol*. 2017;7(2):295–297. doi:10.3892/mco.2017.1310
4. Charville GW, Padda SK, Sibley RK, Puthillath A, Kwo PY. Resolution of crizotinib-associated fulminant hepatitis following cessation of treatment. *Case Rep Hepatol*. 2018;2018:3413592.
5. Yu YC, Mao YM, Chen CW, et al. CSH guidelines for the diagnosis and treatment of drug-induced liver injury. *Hepatol Int*. 2017;11(3):221–241. doi:10.1007/s12072-017-9793-2
6. Liu C, Yu H, Long Q, et al. Real world experience of crizotinib in 104 patients with ALK rearrangement non-small-cell lung cancer in a single Chinese Cancer Center. *Front Oncol*. 2019;9:1116. doi:10.3389/fonc.2019.01116
7. Wu YL, Lu S, Lu Y, et al. Results of PROFILE 1029, a Phase III comparison of first-line crizotinib versus chemotherapy in East Asian patients with ALK-positive advanced non-small cell lung cancer. *J Thorac Oncol*. 2018;13(10):1539–1548. doi:10.1016/j.jtho.2018.06.012
8. Ota T, Masuda N, Matsui K, et al. Successful desensitization with crizotinib after crizotinib-induced liver injury in ROS1-rearranged lung adenocarcinoma. *Intern Med*. 2019;58(18):2651–2655. doi:10.2169/internalmedicine.2554-18
9. Chalasani NP, Maddur H, Russo MW, Wong RJ, Reddy KR; Practice Parameters Committee of the American College of Gastroenterology. ACG clinical guideline: diagnosis and management of idiosyncratic drug-induced liver injury. *Am J Gastroenterol*. 2021;116(5):878–898.
10. Guo L, Gong H, Tang TL, Zhang BK, Zhang LY, Yan M. Crizotinib and sunitinib induce hepatotoxicity and mitochondrial apoptosis in L02 cells via ROS and Nrf2 signaling pathway. *Front Pharmacol*. 2021;12:620934. doi:10.3389/fphar.2021.620934
11. Li M, Wang C, Yu Z, et al. MglG exerts therapeutic effects on crizotinib-induced hepatotoxicity by limiting ROS-mediated autophagy and pyroptosis. *J Cell Mol Med*. 2022;26(16):4492–4505. doi:10.1111/jcmm.17474
12. Nishio M, Kim DW, Wu YL, et al. Crizotinib versus chemotherapy in Asian patients with ALK-positive advanced non-small cell lung cancer. *Cancer Res Treat*. 2018;50(3):691–700. doi:10.4143/crt.2017.280

OncoTargets and Therapy

Dovepress

### Publish your work in this journal

OncoTargets and Therapy is an international, peer-reviewed, open access journal focusing on the pathological basis of all cancers, potential targets for therapy and treatment protocols employed to improve the management of cancer patients. The journal also focuses on the impact of management programs and new therapeutic agents and protocols on patient perspectives such as quality of life, adherence and satisfaction. The manuscript management system is completely online and includes a very quick and fair peer-review system, which is all easy to use. Visit <http://www.dovepress.com/testimonials.php> to read real quotes from published authors.

Submit your manuscript here: <https://www.dovepress.com/oncotargets-and-therapy-journal>