

# Adjuvant Therapy for High-Risk Localized Renal Cell Carcinoma: Current Landscape and Future Direction

Dylan M Buller<sup>1,\*</sup>, Maria Antony<sup>2,\*</sup>, Benjamin T Ristau<sup>1</sup>

<sup>1</sup>Division of Urology, UConn Health, Farmington, CT, USA; <sup>2</sup>University of Connecticut School of Medicine, Farmington, CT, USA

\*These authors contributed equally to this work

Correspondence: Benjamin T Ristau, Division of Urology, UConn Health, 263 Farmington Avenue, Farmington, CT, 06030, Tel +1 860 679 3438, Fax +1 860 679 6109, Email [benristaum@gmail.com](mailto:benristaum@gmail.com)

**Abstract:** Locally and regionally advanced renal cell carcinoma (RCC) can recur at high rates even after visually complete resection of primary disease. Both targeted therapies and immunotherapies represent potential agents that might help reduce recurrence of RCC in these patients. This paper reviews the current body of evidence defining their potential impact and examines the large Phase III randomized clinical trials that have been performed to assess the safety and efficacy of these systemic therapies in the adjuvant setting. Given that the findings from these trials have been predominantly negative, this paper also explores the role of other potential adjuvant agents, including single and combination agent targeted therapies and immunotherapies, whose use is currently limited to metastatic RCC. Finally, the use of radiation therapy and the use of advanced imaging modalities in RCC are also considered.

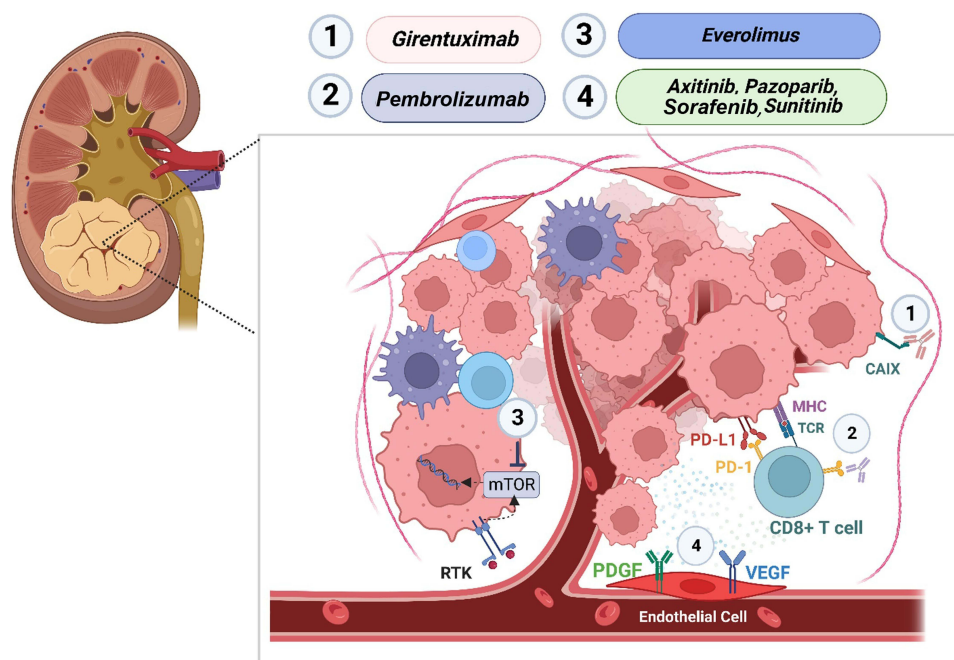
**Keywords:** renal cell carcinoma, adjuvant therapy, targeted therapy, immunotherapy, radiation

## Introduction

Renal cell carcinoma (RCC) is a heterogeneous disease carrying a wide range of prognoses. An estimated 79,000 new cases of RCC will be diagnosed in the United States in 2022, and approximately 13,920 will die from RCC.<sup>1</sup> Nephrectomy remains the mainstay of therapy in localized RCC patients and is curative in most, yet one in three patients undergoing partial or radical nephrectomy for localized disease will experience disease recurrence.<sup>2–5</sup> Patients with locally or regionally advanced disease represent an even higher risk for disease recurrence after resection. While there is a clear need for therapy in the adjuvant setting to reduce the risk of recurrence for patients with localized RCC who have undergone surgical resection, no therapy to date has demonstrated an overall survival benefit.

Patient selection is likely the key for choosing a successful adjuvant treatment strategy. A number of studies have attempted to predict outcomes, including the likelihood of recurrence, in patients with RCC.<sup>2,6–13</sup> While there is not a specific consensus defining a “high risk” of recurrence of RCC after surgical resection, it is generally accepted that patients with higher stage disease have a greater likelihood of recurrence. The UCLA Integrated Staging System (UISS) is a risk predictor that utilizes TNM stage, performance status, and Fuhrman nuclear grade to categorize patients into low, moderate, and high risk.<sup>14</sup> Patients with low-risk disease according to the UISS have a 91% chance of five-year disease-specific survival, compared to 80% in the moderate-risk group and 55% in the high-risk group.<sup>14</sup> Nonetheless, risk assessment inclusion criteria vary among currently published adjuvant trials, despite the assertion that all are evaluating “high-risk RCC.” Therefore, while patient selection for adjuvant therapies is important, there is little current consensus around what makes a patient high risk for recurrence and thereby a good adjuvant candidate.

We will explore completed and ongoing trials to define the role of adjuvant therapy in patients with RCC at high risk of recurrence, including systemic therapies (targeted and immune-oncology agents) and radiation therapy. Systemic therapies exploit tumorigenesis pathways in RCC and are depicted in Figure 1. Targeted therapies such as tyrosine kinase inhibitors of vascular endothelial growth factor receptor (VEGFR; eg sunitinib, sorafenib, axitinib, pazopanib) exploit



**Figure 1** Schematic of RCC tumor microenvironment. Schematic depicts cell types and protein targets corresponding to therapeutics with demonstrated efficacy for advanced RCC.

disordered angiogenesis that is upregulated in the pathogenesis of RCC. Inhibition of the mammalian target of rapamycin (mTOR; eg everolimus) and a monoclonal antibody to carbonic anhydrase IX (girentuximab) has also been used. Immunotherapies targeting the PD-1/PD-L1 pathway (pembrolizumab, atezolizumab, nivolumab, durvalumab) and CTLA-4 pathway (ipilimumab, tremelimumab) have reported early data but continue to remain under investigation. Finally, the resurgence and possible role of radiation therapy for RCC will also be considered.

## Randomized Controlled Trials for Adjuvant Systemic Therapy in High-Risk RCC

Since 2016, a number of large, phase III randomized controlled trials have been published exploring the role of adjuvant agents in patients with high-risk RCC (Table 1).

In 2016, Haas et al reported data on the ASSURE trial.<sup>15</sup> This study randomized 1943 patients with high-risk RCC to receive either sunitinib, sorafenib, or placebo within twelve weeks of nephrectomy. No differences were seen with regard to the primary endpoint of DFS; median DFS was 5.8 years (HR 1.02, 97.5% CI 0.85–1.23,  $p = 0.8038$ ) for sunitinib, 6.1 years (HR 0.97, 97.5% CI 0.80–1.17,  $p = 0.7184$ ) for sorafenib, and 6.6 years for placebo (hazard ratios for sunitinib and sorafenib are compared to placebo). A subsequent subgroup analysis of higher risk patients (pT3/4 or node-positive disease) additionally found no differences in DFS or overall survival (OS) when comparing sunitinib to sorafenib or either agent to placebo.<sup>16</sup>

Later, in 2016, Ravaud et al published findings from the S-TRAC trial, in which 615 patients with high-risk RCC were randomized to receive either adjuvant sunitinib or placebo.<sup>17</sup> The primary outcome was blinded, independently reviewed DFS, with secondary outcomes of OS, safety, and investigator-reviewed DFS. When compared to placebo (5.6 years, 95% CI 3.8–6.6), patients in the sunitinib arm experienced longer DFS (6.8 years, 95% CI 5.8–not reached) based on central blinded review (HR 0.76, 95% CI 0.59–0.98;  $p = 0.03$ ). Subgroup analyses were published separately, with data demonstrating a DFS benefit of sunitinib in higher risk patients, neutrophil-to-lymphocyte ratio  $\leq 3$ , and Fuhrman grade 3/4.<sup>18</sup>

A year after S-TRAC's promising results were reported, data from the PROTECT trial were published.<sup>19</sup> This trial randomized 1538 patients with high-risk RCC to receive either pazopanib or placebo. Because of significant toxicity from and discontinuation of pazopanib with the intended 800mg dosing, a dose adjustment was made to 600mg after 403

**Table I** Summary of Major Randomized Controlled Trials Evaluating Adjuvant Therapy for High-Risk Renal Cell Carcinoma

Trial	First Author	Year	N	Intervention (vs Placebo*)	Primary Outcome(s)	Results of Primary Outcome
ASSURE <sup>15</sup>	Haas	2016	1943	Sunitinib Sorafenib	DFS	No statistically significant difference
S-TRAC <sup>17</sup>	Ravaud	2016	615	Sunitinib	DFS	DFS favors sunitinib (sunitinib: 6.8 years, 95% CI 5.8-not reached; placebo: 5.6 years, 95% CI 3.8–6.6; HR 0.76, 95% CI 0.59–0.98; p = 0.03)
PROTECT <sup>19</sup>	Motzer	2017	1538	Pazopanib	DFS (in pazopanib reduced dose)	No statistically significant difference
ARISER <sup>20</sup>	Chamie	2017	864	Girentuximab	DFS OS	No statistically significant differences
ATLAS <sup>21</sup>	Gross-Goupil	2018	724	Axitinib	DFS	No statistically significant difference
SORCE <sup>22</sup>	Eisen	2020	1711	Sorafenib (1 year) Sorafenib (3 years)	DFS (3y sorafenib vs placebo)	No statistically significant difference
KEYNOTE-564 <sup>24</sup>	Choueiri	2021	994	Pembrolizumab	DFS	DFS favors pembrolizumab (at 24 months, pembrolizumab: 77.3%; placebo: 68.1%, HR 0.54; 95% CI 0.30–0.96)
EVEREST <sup>23</sup>	Ryan	2022	1545	Everolimus	DFS	DFS favors everolimus (HR 0.85; 95% CI, 0.72–1.00; p = 0.0246)
IMmotion010 <sup>26</sup>	Pal	2022	778	Atezolizumab	DFS	No statistically significant difference
CheckMate 914 <sup>27</sup>	Motzer	2022	816	Nivolumab plus ipilimumab	DFS	No statistically significant difference
PROSPER/ECOG-ACRIN EA8143 <sup>28</sup>	Allaf	2022	819	Perioperative nivolumab*	DFS	No statistically significant difference

**Note:** \*Patients in the control group of the PROSPER/ECOG-ACRIN EA8143 trial underwent observation only and did not receive a placebo.

**Abbreviations:** DFS, disease-free survival; OS, overall survival; CI, confidence interval; HR, hazard ratio.

patients had undergone randomization. The primary endpoint in this study was DFS in the dose-adjusted (600mg) group versus placebo; secondary outcomes included DFS with the initial 800mg dosing and safety. No statistically significant difference was seen with regard to the primary endpoint of DFS in patients randomized to receive the 600mg dose of pazopanib. Secondary analyses of patients randomized to pazopanib 800mg (HR 0.69; 95% CI 0.51–0.94; p = 0.02) and of all patients randomized to receive pazopanib (HR 0.80, 95% CI 0.68–0.95, p = 0.01) did demonstrate DFS benefit.

The ARISER trial diverged from the VEGFR-TKI class of adjuvant chemotherapy in its investigation of girentuximab, a monoclonal antibody to carbonic anhydrase IX (CA-IX).<sup>20</sup> CA-IX is a cell surface glycoprotein that demonstrates low expression in normal tissues but is highly expressed in clear cell RCC, therefore making it a potential target for therapy. A total of 864 patients with high-risk RCC were randomized to receive either girentuximab or placebo. No

statistically significant differences in the primary endpoints of DFS or OS were seen. Median DFS in patients receiving girentuximab was 71.4 months and was not reached in the placebo group (HR 0.97, 95% CI 0.79–1.18). Median OS was not reached in either the intervention or placebo arm (HR 0.99, 95% CI 0.74–1.32). Exploratory analysis of carbonic anhydrase IX (CAIX) expression and correlation with treatment response demonstrated mild DFS improvements in some subgroups, namely younger patients, those with lower grade disease, and those with good performance status.

Axitinib was investigated in the ATLAS trial as adjuvant therapy for patients with high-risk RCC.<sup>21</sup> A total of 724 patients were randomized to either axitinib or placebo, with a primary endpoint of DFS based on an independent review committee. An interim analysis was planned after 203 DFS events, at which time no statistically significant difference in DFS was seen (HR 0.870, 95% CI 0.660–1.147;  $p = 0.3211$ ); the study was terminated at that time due to futility. In a subgroup analysis of the highest risk patients, a statistically significant DFS benefit was seen on investigator analysis (HR 0.641, 95% CI 0.468–0.879,  $p = 0.0051$ ) but not independent review committee analysis (HR 0.735, 95% CI 0.525–1.028,  $p = 0.0704$ ).

Data from the SORCE trial was published in 2020.<sup>22</sup> This study examined the use of adjuvant sorafenib in patients with RCC at intermediate and high risk of recurrence; approximately half of the patients were categorized as high risk. The primary outcome was DFS. A total of 1711 patients were included in the study and were randomized to receive either sorafenib or placebo. Patients assigned to the treatment arm were initially given sorafenib 400mg twice daily, but this dosage was later adjusted to 400mg once daily given unexpectedly high rates of patient intolerance. Patients who tolerated three weeks of the reduced dose could be re-escalated to the 400mg twice daily dosing at the discretion of the treating provider. No differences were found in DFS between the intervention and placebo groups, both overall and within the high risk-only subgroup (high-risk patients receiving 1 year of sorafenib: HR 1.02, 95% CI 0.80–1.30,  $p = 0.875$ ; high-risk patients receiving 3 years of sorafenib: HR 0.92, 95% CI 0.72–1.17,  $p = 0.49$ ).

The EVEREST trial randomized 1545 patients who underwent nephrectomy for RCC at intermediate-high or very-high risk of recurrence to everolimus or placebo.<sup>23</sup> The primary endpoint in this trial focused on DFS, with secondary outcomes evaluating OS and adverse events. When compared to placebo, DFS in patients receiving everolimus carried an HR of 0.85 (95% CI 0.72–1.00;  $p = 0.0246$ ); the pre-specified level of significance was given as 0.022. A statistically significant improvement in DFS was seen in patients receiving everolimus who had a very high risk of recurrence (HR 0.79, 95% CI 0.65–0.97;  $p = 0.011$ ). This improvement was not seen in patients at intermediate-high risk of recurrence.

The KEYNOTE-564 trial randomized 994 patients to receive either pembrolizumab or placebo after nephrectomy.<sup>24</sup> To meet inclusion criteria, patients must have had intermediate-high or high risk of recurrence; patients with complete resection of soft tissue metastases (M1 with no evidence of disease after resection) were also included. The primary outcome assessed was DFS; OS was analyzed as a secondary outcome. After 24 months, patients randomized to receive pembrolizumab did experience a significant increase in DFS; 77.3% of patients receiving pembrolizumab remained disease-free, compared to 68.1% of patients receiving the placebo (HR 0.68, 95% CI 0.53–0.87;  $p = 0.0010$ ). Subsequent 30-month follow-up data continued to demonstrate a DFS benefit (HR 0.63, 95% CI 0.50–0.80;  $p < 0.0001$ ). OS data is still maturing.<sup>25</sup>

The IMmotion010 trial evaluated adjuvant atezolizumab compared to placebo following nephrectomy with or without metastasectomy for patients with RCC and an increased risk of recurrence.<sup>26</sup> The primary endpoint was DFS in the intention to treat (ITT) population, based on investigator determination. Secondary endpoints included OS, DFS based on independent reviewer determination, DFS in patients with higher PD-L1 expression ( $\geq 1\%$ ), event-free survival, disease-specific survival, distant metastasis-free survival, and DFS assessed at years one, two, and three. A total of 778 patients were randomized, with 390 assigned to receive atezolizumab and 388 assigned to receive placebo. After a median follow-up of 44.7 months, median DFS was similar between patients receiving atezolizumab (57.2 months; 95% CI 44.6 – not evaluable) and those receiving placebo (49.5 months; 95% CI 47.4 – not evaluable; HR 0.93, 95% CI 0.75–1.15,  $p = 0.50$ ). Secondary outcomes also did not differ between the two groups.

A recent abstract reported results of the as-yet unpublished CheckMate 914 trial, which randomized patients with high-risk localized RCC across two arms.<sup>27</sup> One group of patients was randomized to receive either nivolumab plus ipilimumab or placebo, while the other was randomized to receive nivolumab alone, nivolumab plus ipilimumab, or placebo. The primary endpoint was independent reviewer-assessed DFS, with OS and safety analyses comprising the

secondary endpoints. Only results from the combination therapy arm of the trial have been reported. A total of 816 patients were randomized to receive either nivolumab plus ipilimumab ( $n = 405$ ) or placebo ( $n = 411$ ). The primary outcome was not reached; median DFS with nivolumab plus ipilimumab was not reached, and with placebo was 50.7 months (HR 0.92, 95% CI 0.71–1.19,  $p = 0.5347$ ).

The PROSPER/ECOG-ACRIN EA8143 trial took a slightly different approach.<sup>28</sup> In this trial, 819 patients with high-risk RCC were randomized. Those randomized to the intervention group ( $n = 404$ ) received one dose of pre-operative (neoadjuvant) nivolumab, as well as nine doses of adjuvant nivolumab following nephrectomy; patients randomized to the control group ( $n = 415$ ) underwent observation only and did not receive a placebo. The primary outcome was DFS, with outcomes for DFS for clear-cell RCC, OS, and quality of life metrics comprising secondary endpoints. Median DFS was not reached and was not statistically significantly different between the intervention and control groups (HR 0.97; 95% CI 0.74–1.28,  $p = 0.43$ ). OS outcomes also did not differ between groups. Future subgroup analyses are planned.

Several trials remain ongoing and without reported data. The RAMPART trial (Renal Adjuvant MultiPle Arm Randomized Trial; clinicaltrials.gov ID NCT03288532) is a phase III randomized controlled trial in which patients with RCC at intermediate and high risk of recurrence are randomized to receive adjuvant durvalumab alone, adjuvant durvalumab plus tremelimumab, or active monitoring.<sup>29</sup> Primary outcomes are DFS and OS; secondary outcomes include metastasis-free survival and disease-specific survival. Target enrollment is 1750 patients, with primary study completion expected in 2024.

The MK-6482-022/LITESPARK-022 trial (clinicaltrials.gov ID NCT05239728) is another phase III randomized controlled trial that is also ongoing. In this trial, patients with intermediate-high risk or high-risk localized RCC, or patients with M1 pathology with no evidence of disease following resection, are randomized to receive either adjuvant belzutifan plus pembrolizumab or placebo plus pembrolizumab.<sup>30</sup> There is no group of patients assigned to only receive placebo or active monitoring. The primary outcome is DFS. Their protocol specifies nine secondary outcomes, including OS, safety/adverse event data, quality of life and symptom metrics and further data on recurrence patterns. Target enrollment is 1600 patients, and primary study completion is expected in 2027.

## Adverse Events in Adjuvant Systemic Therapy Trials

Adverse events (AEs) with an incidence of least 10% in safety populations are summarized in Table 2. In general, most interventions were poorly tolerated. In the ASSURE,<sup>15</sup> PROTECT,<sup>19</sup> and SORCE<sup>22</sup> trials, discontinuation related to excess drug toxicity was present to a large enough degree that the trial protocols were amended to decrease dosing. Hand-foot syndrome and hypertension were common adverse events in anti-VEGFR TKIs (sunitinib, sorafenib, pazopanib, axitinib). Data indicate that patients tolerated girentuximab<sup>20</sup> better than the anti-VEGFR TKIs, however it was not effective in improving disease-free or overall survival. The sole immunotherapeutic agent with positive data, pembrolizumab, appears to have been better tolerated than the anti-VEGFR TKIs as well, as patients experienced adverse events  $\geq$  grade 3 less frequently. Nonetheless, 21% of patients in the safety analysis discontinued pembrolizumab due to an adverse event, indicating a continued need for therapies that are tolerable in addition to being effective.<sup>24</sup>

## Adjuvant Therapy in Other Domains

Trials for adjuvant therapy in RCC have been predominantly negative to date. There are several theories as to why this might be the case. RCC might recur following what was considered to be complete surgical resection as a result of microscopic residual or micrometastatic disease. TKIs and immunotherapies do not specifically target cancer cells. Instead, their effectiveness is predicated on disruption of tumor neovasculature and immune system activation, respectively, making microscopic disease an ineffective target for such therapies.

Nonetheless, despite the lack of efficacy in the majority of trials investigating adjuvant therapy for RCC, adjuvant therapy has proven effective in improving outcomes in other neoplastic processes. For example, adjuvant therapy is often given to patients following surgery for breast cancer to reduce recurrence and improve survival.<sup>31</sup> Hormone therapies (eg tamoxifen),<sup>32,33</sup> chemotherapies (eg anthracycline, docetaxel/paclitaxel, cyclophosphamide),<sup>34–36</sup> and targeted therapies (eg trastuzumab, pertuzumab)<sup>37–39</sup> have all demonstrated both DFS and OS benefits when given in the adjuvant setting. Though breast cancer certainly represents a fundamentally unique disease process compared to RCC, DFS and OS



**Table 2** Summary of Adverse Events in Major Randomized Controlled Trials Evaluating Adjuvant Therapy for High-Risk Renal Cell Carcinoma

Trial	Study Drug	Adverse Events $\geq$ Grade 3 in at Least 10% of Patients	# Dropouts Due to Adverse Event	Trial Design Amended Due to Early Toxicity?
ASSURE <sup>15</sup>	Sunitinib	Fatigue (18%) Hypertension (17%) Hand-foot syndrome (15%)	124/625 (20%)	Yes
	Sorafenib	Hand-foot syndrome (33%) Hypertension (16%) Rash/desquamation (15%)	128/628 (20%)	Yes
S-TRAC <sup>17</sup>	Sunitinib	Hand-foot syndrome (16%)	86/306 (28%)	No
PROTECT <sup>19</sup>	Pazopanib	Hypertension (25%) Elevated ALT (16%)	800mg dose: 77/198 (39%) 600mg dose: 201/568 (35%)	Yes
ARISER <sup>20</sup>	Girentuximab	51/431 (12%) had any $\geq$ Grade 3 AE; individual $\geq$ Grade 3 AEs not reported	7/431 (2%)	No
ATLAS <sup>21</sup>	Axitinib	61% had $\geq$ Grade 3 AE; individual $\geq$ Grade 3 AEs not reported	19% <sup>a</sup>	No
SORCE <sup>22</sup>	Sorafenib 1 year	Hand-foot syndrome (24%) Hypertension (26%)	30% <sup>a</sup>	Yes
	Sorafenib 3 years	Hand-foot syndrome (24%) Hypertension (24%)	34% <sup>a</sup>	
KEYNOTE-564 <sup>24</sup>	Pembrolizumab	None	101/488 (21%)	No
EVEREST <sup>23</sup>	Everolimus	Mucositis (14%) Hypertriglyceridemia (11%)	37%*	No
IMmotion010 <sup>26</sup>	Atezolizumab	None	12%	No
CheckMate 914 <sup>27</sup>	Nivolumab plus ipilimumab	28.5% had $\geq$ Grade 3 AE; individual $\geq$ Grade 3 AEs not reported	29%	No
PROSPER/ECOG-ACRIN EA8143 <sup>28</sup>	Perioperative nivolumab	None	Not reported	No

**Note:** <sup>a</sup>Number of patients included in safety analysis not listed.

**Abbreviation:** AE, adverse event.

benefits seen with adjuvant therapies in breast cancer remain an encouraging reminder that success may be possible for RCC as well.

## Radiation as Adjuvant Therapy for Patients with High-Risk RCC

### Rationale for Adjuvant Radiation in RCC: Emerging Data for Primary Treatment of Clinically Localized RCC

Radiation alone for the management of nonmetastatic RCC has been historically limited due to its insensitivity to traditional doses of radiotherapy (4 Gy).<sup>40</sup> However, contemporary trials evaluating the role of stereotactic body radiation therapy (SBRT) [also referred to as stereotactic ablative radiotherapy (SABR)] for precise, ablative management of primary RCC have challenged this notion in select populations. SBRT delivers a high dose (20 to 40 Gy) of radiation at a single focus while limiting the dose to surrounding organs with a less invasive approach than traditional ablation.<sup>41,42</sup>

RCC can pose a risk of both local and systemic recurrence following local surgical resection. The rate of local recurrence compared to systemic recurrence is comparatively low (ranging from 2% to 6%); however, this may vary with tumor pathology, local vessel involvement, and genetic predisposition.<sup>43,44</sup> Among those with locoregional recurrence, overall survival is poor.<sup>45</sup> Therefore, early identification and appropriate selection of patients, particularly those with complex tumor pathology or local extension, is essential for assessing the utility of local radiation for RCC.

Over the last decade, studies have demonstrated that surgical extirpation and ablative therapy (cryotherapy, radio-frequency ablation [RFA], microwave thermotherapy) for low-risk, small (<3cm) lesions have comparable outcomes.<sup>46,47</sup> In contrast to widely available ablative therapy modalities, SBRT has the potential to treat large (>4cm), complex endophytic tumors or local oligometastatic disease without high risk of fistula or stricture involving the collecting system and surrounding vasculature.<sup>48–50</sup> Some retrospective studies suggest that SBRT compares well to thermal ablation for safety and efficacy, but there are limited trials to prospectively compare outcomes of RFA and SBRT.<sup>42,51</sup> Across several trials, SBRT has promising benefit for patients with inoperable disease with high risk of functional sequelae (eg solitary kidney) or oligometastatic disease (Table 3).<sup>41,48,49,52,53</sup>

Similar to ablative therapy, a major limitation of SBRT for the management of primary RCC is the missed opportunity to assess index lesions by histopathology, although renal mass biopsy and imaging modalities exist to predict and assess treatment response to SBRT.<sup>54,55</sup> Additionally, though technology can be standardized across several institutions, expertise and equipment are costly and only available in select centers.

**Table 3** SABR/SBRT for High-Risk/Morbidity RCC

First Author	N	Inclusion Criteria/Primary Outcome	Experimental Design	Primary Outcome	Result
Correa <sup>52</sup>	81	Biopsy confirmed primary RCC of a single lesion within a solitary kidney	Retrospective	PFS, OS, and renal function	Progression-free, cancer specific and overall survival in the solitary cohort were 98.0%, 77.5%, 98.2% and 81.5%, respectively. No significant difference in renal function or oncologic outcomes between groups
Swaminath <sup>142</sup>	28	Patient-reported QoL after SBRT for primary kidney cancer.	Prospective	Repeated measures QOL 1 week, 1,3,6 month post-treatment	No significant reduction in any QoL metric
Margulis <sup>143</sup>	6	Patients with RCC with IVC tumor thrombus	Prospective single-arm Phase I and 2 trial	Absence of grade 4 to 5 AEs within 90 days of RN-IVCT.	No grade 4 to 5 AEs. After a median follow-up of 24 months, all patients are alive.
Tetar <sup>144</sup>	36	Patients treated with MRgRT on the MRIdian-system for primary RCC between 2016 and 2020	Retrospective	OS and LC	LC and OS rates at 1 year were 95.2% and 91.2%. No grade ≥3 toxicity was reported.
Siva <sup>145</sup>	95	Patients with larger (T1b, >4 cm) RCC not suitable for surgery. Patients with T1a tumors, M1 disease, and/or upper tract urothelial carcinoma were excluded.	Retrospective	Cancer specific survival (CSS), OS, and PFS	CSS, OS, and PFS were 96.1%, 83.7%, and 81.0% at 2 years and 91.4%, 69.2%, 64.9% at 4 years.

(Continued)

**Table 3** (Continued).

First Author	N	Inclusion Criteria/Primary Outcome	Experimental Design	Primary Outcome	Result
Senger <sup>146</sup>	10	Histology-confirmed clear cell RCC grade 1 or 2 with evidence of renal dysfunction	Retrospective	LC, and renal function	Persistent LC by robotic SABR in 9/10 patients (92.3% of lesions). Renal function stable with a mean eGFR of $51.3 \pm 19.7$ mL/min at baseline and $51.6 \pm 25.8$ mL/min at follow-up.
Grelier <sup>147</sup>	23	Patients underwent SBRT for primary RCC	Retrospective	RFS, CSS, and OS	Local RFS, event-free survival, CSS, and OS were 96 (22/23), 74 (18/23), 96 (22/23) and 83% (19/23), respectively.
Grubb <sup>148</sup>	11	Patients were required to have localized RCC and be poor surgical candidates due to medical comorbidities.	Prospective analysis, single arm	AE, LC	Three-year local control was 90%. Late grade 2+ and grade 3+ possibly treatment-related events occurred in 18.1% and 9.1%, respectively.
Siva <sup>51</sup>	223	Pooled multiinstitutional dataset receiving SABR in single or multifraction	Retrospective	LC, CSS, PFS at 2 and 4 years	The rates of LC, CSS, and PFS were 97.8%, 95.7%, and 77.4%, respectively, at 2 years; and they were 97.8%, 91.9%, and 65.4%, respectively, at 4 years.
Siva <sup>53</sup>	37	Patients unsuitable for surgery/nephrectomy	Prospective, single arm	AEs, LC, OS	No grade 4–5 toxicities were recorded and six patients (18%) reported no toxicity. Local PFS, distant PFS, and OS at 2 years were 100%, 89% and 92%, respectively.
Siva <sup>59</sup>	30	Patients with up to 2 lines of prior systemic therapy with 1–5 oligometastases from ccRCC	Prospective, single arm, phase I/2	AEs, PFS, OS	There were no grade 4 or 5 AEs. Estimated 1- and 2-yr OS was 90% and 74%. PFS was 60% (1y) and 45% (2y).

**Abbreviations:** RCC, renal cell carcinoma; QoL, quality of life; SBRT, stereotactic body radiation therapy; SABR, stereotactic ablative radiotherapy; PFS, progression free survival; OS, overall survival; LC, local control; RFS, recurrence free survival; CSS, cancer specific survival; eGFR, estimated glomerular filtration rate.

From a functional standpoint, SBRT also allows for renal parenchyma preservation even in the setting of a solitary kidney and surgically unresectable tumors.<sup>51,52,56</sup> SBRT is a less invasive modality and may be more suitable for medically complex patients.<sup>48,51</sup> Lastly, several emerging trials have evaluated the “abscopal effect” of RCC, referring to the phenomenon of distant response of metastatic sites after localized treatment. This can be partly explained by systemic introduction of non-oncogenic neoantigens after RCC cell death after precision, localized radiation. Based on this phenomenon and emerging biologic rationale, ongoing trials exist to evaluate the clinical efficacy and safety of SBRT on immune priming and induction with adjuvant chemotherapy for metastatic and oligometastatic RCC.<sup>57–62</sup> Preliminary results investigating the role of SBRT in the treatment of primary RCC are hypothesis generating, and larger trials are eagerly awaited to tease out the role of this promising technology.

SBRT has not been studied in the isolated high-risk RCC or local recurrence setting. However, given that adjuvant therapy options are limited for patients with RCC at a high risk of recurrence, it may be reasonable to consider applying therapy that has shown initial promise in clinically localized disease to patients with locally advanced or locoregionally metastatic disease.



## Considerations for Adjuvant Radiation for RCC

One objective of adjuvant radiation therapy is to eradicate viable oncogenic tissue following surgery for macroscopic disease, especially in those who are at high risk for recurrence or locoregional failure. Use of adjuvant radiation is a mainstay in breast cancer treatment; however, current trials studying the efficacy of adjuvant radiation for primary, nonmetastatic RCC have been limited and historically with negative results (Table 4).<sup>63,64</sup> Furthermore, these historical trials do suggest that adjuvant radiation has demonstrated variable tumor response with relative toxicity including bowel stenosis, possible liver injury, and bleeding.<sup>64,65</sup> More contemporary trials have shown improved safety and efficacy profiles for adjuvant radiotherapy.<sup>66</sup>

**Table 4** Adjuvant Radiation Therapy for High-Risk RCC

Study	Year	N	5-Year OS (%)		Regional Recurrence		Adjuvant Radiation Toxicity
			Nephrectomy Alone	Adjuvant Radiation	Nephrectomy Alone	Adjuvant Radiation	
Finney <sup>65</sup>	1973	100	51	45	—	RT did not influence the incidence of local recurrence or distant metastases.	Evidence of liver damage in right-sided lesions irradiated as shown from biochemical liver function tests and isotope scans.
Kjaer <sup>149</sup>	1978	65	62	38	—	Recurrence in 43% during the follow-up without difference between the two groups.	Significant complications from stomach, duodenum or liver, median 5 mo., range 1–44 mo. after RT.
Stein <sup>150</sup>	1992	119	40	50	Recurrence in T <sub>2</sub> N <sub>0</sub> M <sub>0</sub> disease was 2/28; T <sub>3</sub> N <sub>0</sub> M <sub>0</sub> was 11/30 <sup>a</sup> ; and T <sub>4</sub> N <sub>0</sub> M <sub>0</sub> was 1/2.	Recurrence in T <sub>2</sub> N <sub>0</sub> M <sub>0</sub> disease was 0/17; in T <sub>3</sub> N <sub>0</sub> M <sub>0</sub> was 4/37 <sup>a</sup> ; and T <sub>4</sub> N <sub>0</sub> M <sub>0</sub> was 1/5.	Significant complication in three (5%) patients undergoing RT.
Kao <sup>151</sup>	1994	24	62	75	The 5-year actuarial local failure rate 30% <sup>a</sup> ; DFS 62% <sup>a</sup> .	No patients who received RT after nephrectomy had locoregional recurrence <sup>a</sup> ; 5 year DFS 75% <sup>a</sup> .	No chronic complications resulted from RT.
Makarewicz <sup>152</sup>	1998	186	38	30	Local failure in T3N0 15.8%; T3N(+) 33.3%; T4N0 33.3%; T4N(+) 33.3%.	Local failure in T3N0 8.8%, T3N(+) was 33.3%, T4N0 was 33.3%, T4N(+) was 25.0%. The median time to local recurrence (27.0 vs 21.0 months) or distant metastases (16.0 vs 12.5 months) was improved with adjuvant RT compared to without <sup>a</sup> .	—
Ulutin <sup>66</sup>	2006	40	20	70	5-year DFS 16% <sup>a</sup> .	5-year DFS 66% <sup>a</sup> .	—

**Note:** <sup>a</sup>Denotes statistically significant difference.

**Abbreviations:** DFS, disease-free survival; RT, radiation therapy.

More recent therapies have demonstrated reduced risk for toxicity.<sup>67</sup> Additionally, in a meta-analysis of 12 clinical studies encompassing 1624 patients undergoing radical nephrectomy, there was some evidence that adjuvant radiation could reduce locoregional recurrence rates. Notably, however, there was no OS or PFS advantage conferred by adjuvant radiation.<sup>67</sup> Patients selected for radical nephrectomy can be associated with higher disease burden or higher tumor complexity, which can confound the survival results. Use of radiation following partial nephrectomy for microscopic disease poses an anatomic challenge and higher theoretical risk for complications. Adjuvant radiation can potentially increase likelihood for a negative surgical margin in those with high risk of recurrence. However, unlike systemic therapy, in appropriately selected patients and with ideal conditions, radiation can be further modified based on the size of the field and radiation dose.<sup>68,69</sup>

## Other Frontiers

### Systemic Therapies

Sunitinib (based on data from S-TRAC<sup>17</sup>) and pembrolizumab (based on data from KEYNOTE-564<sup>24</sup>) are the only systemic agents that are currently FDA-approved for adjuvant use in RCC. Despite approval of sunitinib based on the DFS benefit seen in S-TRAC, results were not reproducible in subsequent studies. Furthermore, the adverse event profile of sunitinib is substantial, with nearly 30% of patients withdrawing from the study due to a drug-related adverse event. It is therefore difficult to justify adjuvant treatment with sunitinib in the absence of measurable disease given an unfavorable risk/benefit ratio. Additional effective agents are clearly needed in this space.

Many of the recent attempts to utilize adjuvant therapy to improve outcomes in localized RCC at high risk of recurrence are predicated on treatment strategies that are effective in metastatic RCC (mRCC). Trials assessing the adjuvant use of axitinib,<sup>21,70,71</sup> pazopanib,<sup>19,72–74</sup> sunitinib,<sup>15,17,75,76</sup> sorafenib,<sup>15,77–79</sup> everolimus,<sup>23,80,81</sup> pembrolizumab,<sup>24,72–74</sup> nivolumab alone,<sup>28,82,83</sup> and nivolumab plus ipilimumab<sup>27,84,85</sup> are reviewed in this paper; all are included in the National Comprehensive Cancer Network guidelines on mRCC based on the support of clinical trial data.<sup>86</sup> High-dose IL-2, which is not covered in this paper, is also included as “useful in certain circumstances” for patients with mRCC,<sup>87–89</sup> and was found in a phase III trial to be unhelpful in the adjuvant setting for patients with high-risk RCC.<sup>90</sup>

There remain a number of guideline-directed agents utilized for mRCC that have not yet been studied in the adjuvant setting for patients with locally or regionally advanced RCC at high risk of recurrence.<sup>86</sup> Some of these regimens include single agents, such as cabozantinib,<sup>91–95</sup> temsirolimus,<sup>96</sup> tivozanib,<sup>97,98</sup> bevacizumab,<sup>99</sup> and belzutifan (phase III trial is ongoing).<sup>30,100,101</sup> Furthermore, a number of combined agent regimens have proven beneficial in mRCC, without trials to either support or contraindicate their adjuvant use in patients with high-risk RCC. The combined regimens of axitinib plus pembrolizumab,<sup>102,103</sup> cabozantinib plus nivolumab,<sup>104</sup> lenvatinib plus pembrolizumab,<sup>105</sup> axitinib plus avelumab,<sup>106–108</sup> and lenvatinib plus everolimus<sup>109,110</sup> have all been shown to improve outcomes in patients with mRCC and could conceivably be evaluated in trials in the adjuvant setting for patients with high-risk RCC.

There are additional potential avenues for intervention that could improve recurrence and survival rates in patients with localized RCC at high risk of recurrence. Although not typically offered to patients with resectable disease, neoadjuvant therapy has proven helpful in some aggressive tumors, including enabling nephrectomy in previously unresectable masses, or facilitating nephron-sparing surgery in patients who would previously have only been candidates for a radical nephrectomy.<sup>111</sup>

It is also possible that therapies that have failed to demonstrate recurrence or survival benefits in large populations may in fact yield some benefit for certain subsets of patients. In the ATLAS trial comparing axitinib to placebo, despite not meeting the primary DFS endpoint, those patients with the highest risk disease (pT3 with Fuhrman Grade  $\geq 3$  or pT4 and/or N+/any T/any Fuhrman Grade disease) did demonstrate DFS benefit on investigator review.<sup>21</sup>

In an exploratory analysis from the S-TRAC trial, single nucleotide polymorphisms (SNPs) were evaluated in 10 genes associated with RCC tumorigenesis. In this analysis, the investigators identified three SNPs that demonstrated improvements in DFS for patients receiving sunitinib compared to placebo.<sup>112</sup> If DNA differences on a tumor level are able to help predict responses to adjuvant therapy, patients who may benefit from such therapies could be offered treatment while sparing the likely non-responders from the potentially harmful adverse effects.

## Advanced Imaging for RCC

Locally and regionally advanced RCC may recur due to thus-far undetectable disease that is not eradicated at the time of resection. Therefore, an inability to detect early recurrence or metastases could confer poorer outcomes if there is a resultant delay in systemic treatment. The development of advanced imaging modalities may enable enhanced detection of primary or metastatic disease to facilitate more complete extirpation, earlier detection of metastatic disease, and/or help to better select patients for adjuvant therapy.<sup>113</sup> A number of molecular imaging strategies have been employed to leverage the unique metabolic processes inherent to the tumorigenesis of RCC in attempts to more accurately image the disease.

Since 1986, carbonic anhydrase IX (CA-IX) has been a target of molecular imaging.<sup>114–116</sup> PET utilizing CA-IX has demonstrated improved sensitivity and specificity over contrast-enhanced CT scan for the detection of clear cell RCC.<sup>117–119</sup>

In addition to being a target for treatment, VEGF and the VEGF receptor have also been used as targets in molecular imaging.<sup>113,120</sup> It has thus far been used to monitor tumor response to various agents in clinical trials.<sup>121,122</sup>

PSMA has gained traction for its use in prostate cancer but is expressed in RCC as well.<sup>113,123</sup> PSMA PET/CT has been found to have increased sensitivity compared to conventional imaging in the detection of RCC.<sup>124</sup> Its role may be in the detection of the primary RCC focus rather than the detection of metastatic disease,<sup>125–127</sup> or to assess response to TKIs or immunotherapy.<sup>128</sup>

Immune checkpoint inhibitors (ICIs) are being utilized in the treatment of mRCC and are actively being studied to assess their role in the adjuvant setting for patients with high-risk RCC. Although results have demonstrated some promise, not all patients respond to these agents.<sup>113</sup> Targeted imaging in this space could help predict response to ICI use and facilitate improved patient selection for treatment.<sup>129</sup>

Finally, targeting differences in the metabolic pathways of RCC cells as compared to healthy tissue has also been explored. <sup>18</sup>F-FLT, <sup>11</sup>C-acetate, <sup>11</sup>C/<sup>18</sup>F-labeled choline, <sup>11</sup>C-methionine, and <sup>18</sup>F-(2S,4R)4-fluoroglutamine have each been used or studied in this regard.<sup>113</sup>

## Molecular Biomarkers for RCC

In addition to advanced imaging modalities, the use of biomarkers could help identify patients who may be at risk of recurrence or progression of RCC. Various possible biomarkers have been identified; these include microRNAs (miRNA)s;<sup>130</sup> promoter methylation of certain genes (methylation of PCDH17 and NEFH);<sup>131</sup> DNA deamination (APOBEC3B expression);<sup>132</sup> chemokine receptors (CCR8 expression);<sup>133</sup> markers within the mTOR pathway (p-4E-BP1 expression);<sup>134</sup> cancer stem cells (OCT4 and NANOG expression);<sup>135</sup> metalloenzymes (superoxide dismutase 2 expression);<sup>136</sup> and cell cycle regulation proteins (activity of CDK1 and CDK2),<sup>137</sup> along with many others.<sup>138–140</sup> Multiple-gene panels have also been identified that positively correlate with both survival and recurrence metrics (ClearCode 34).<sup>141</sup> These biomarkers could augment current nomograms to help identify patients at increased risk of recurrence and could even potentially represent future targeted therapy. Translation to clinical practice is eagerly anticipated.

## Conclusions

Many patients with localized RCC will have recurrence of their disease after partial or radical nephrectomy. While some trials analyzing adjuvant systemic therapy following nephrectomy for patients with RCC have shown improvements in disease-free survival, this has not translated into an overall survival benefit. Radiation therapy, targeted therapy using population subgroups or tumor-level genetic differences, and ongoing trials examining other systemic therapies or combinations thereof represent possible interventions that may confer future recurrence and survival benefits in this space.

## Funding

There is no funding to report.

## Disclosure

The authors report no conflicts of interest in this work.

## References

1. PDQ® Adult Treatment Editorial Board. PDQ renal cell cancer treatment. PDQ Cancer Information Summaries. Bethesda (MD): National Cancer Institute; 2022. Available from: <https://www.cancer.gov/types/kidney/hp/kidney-treatment-pdq>. Accessed July 18, 2022.
2. Smaldone MC, Fung C, Uzzo RG, Haas NB. Adjuvant and neoadjuvant therapies in high-risk renal cell carcinoma. *Hematol Oncol Clin North Am*. 2011;25(4):765–791.
3. Lam JS, Shvarts O, Leppert JT, Figlin RA, Beldegrun AS. Renal cell carcinoma 2005: new frontiers in staging, prognostication and targeted molecular therapy. *J Urol*. 2005;173(6):1853–1862.
4. Tsui KH, Shvarts O, Smith RB, Figlin RA, deKernion JB, Beldegrun A. Prognostic indicators for renal cell carcinoma: a multivariate analysis of 643 patients using the revised 1997 TNM staging criteria. *J Urol*. 2000;163(4):1090–1095; quiz 1295.
5. Lam JS, Shvarts O, Leppert JT, Pantuck AJ, Figlin RA, Beldegrun AS. Postoperative surveillance protocol for patients with localized and locally advanced renal cell carcinoma based on a validated prognostic nomogram and risk group stratification system. *J Urol*. 2005;174(2):466–472; discussion 472; quiz 801.
6. Lane BR, Babineau D, Kattan MW, et al. A preoperative prognostic nomogram for solid enhancing renal tumors 7 cm or less amenable to partial nephrectomy. *J Urol*. 2007;178(2):429–434.
7. Jeldres C, Sun M, Liberman D, et al. Can renal mass biopsy assessment of tumor grade be safely substituted for by a predictive model? *J Urol*. 2009;182(6):2585–2589.
8. Kutikov A, Eggleston BL, Wong YN, Uzzo RG. Evaluating overall survival and competing risks of death in patients with localized renal cell carcinoma using a comprehensive nomogram. *J Clin Oncol*. 2010;28(2):311–317.
9. Yaycioglu O, Roberts WW, Chan T, Epstein JI, Marshall FF, Kavoussi LR. Prognostic assessment of nonmetastatic renal cell carcinoma: a clinically based model. *Urology*. 2001;58(2):141–145.
10. Cindolo L, de la Taille A, Messina G, et al. A preoperative clinical prognostic model for non-metastatic renal cell carcinoma. *BJU Int*. 2003;92(9):901–905. doi:10.1111/j.1464-410X.2003.04505.x
11. Raj GV, Thompson RH, Leibovich BC, Blute ML, Russo P, Kattan MW. Preoperative nomogram predicting 12-year probability of metastatic renal cancer. *J Urol*. 2008;179(6):2146–2151; discussion 2151.
12. Kattan MW, Reuter V, Motzer RJ, Katz J, Russo P. A postoperative prognostic nomogram for renal cell carcinoma. *J Urol*. 2001;166(1):63–67.
13. Sorbellini M, Kattan MW, Snyder ME, et al. A postoperative prognostic nomogram predicting recurrence for patients with conventional clear cell renal cell carcinoma. *J Urol*. 2005;173(1):48–51.
14. Zisman A, Pantuck AJ, Wieder J, et al. Risk group assessment and clinical outcome algorithm to predict the natural history of patients with surgically resected renal cell carcinoma. *J Clin Oncol*. 2002;20(23):4559–4566.
15. Haas NB, Manola J, Uzzo RG, et al. Adjuvant sunitinib or sorafenib for high-risk, non-metastatic renal-cell carcinoma (ECOG-ACRIN E2805): a double-blind, placebo-controlled, randomised, Phase 3 trial. *Lancet*. 2016;387(10032):2008–2016.
16. Haas NB, Manola J, Dutcher JP, et al. Adjuvant treatment for high-risk clear cell renal cancer: updated results of a high-risk subset of the ASSURE randomized trial. *JAMA Oncol*. 2017;3(9):1249–1252.
17. Ravaud A, Motzer RJ, Pandha HS, et al. Adjuvant Sunitinib in High-Risk Renal-Cell Carcinoma after Nephrectomy. *N Engl J Med*. 2016;375(23):2246–2254.
18. Motzer RJ, Ravaud A, Patard JJ, et al. Adjuvant sunitinib for high-risk renal cell carcinoma after nephrectomy: subgroup analyses and updated overall survival results. *Eur Urol*. 2018;73(1):62–68.
19. Motzer RJ, Haas NB, Donskov F, et al. Randomized phase III trial of adjuvant pazopanib versus placebo after nephrectomy in patients with localized or locally advanced renal cell carcinoma. *J Clin Oncol*. 2017;35(35):3916–3923.
20. Chamie K, Donin NM, Klopfer P, et al. Adjuvant weekly girentuximab following nephrectomy for high-risk renal cell carcinoma: the ARISER randomized clinical trial. *JAMA Oncol*. 2017;3(7):913–920.
21. Gross-Goupil M, Kwon TG, Eto M, et al. Axitinib versus placebo as an adjuvant treatment of renal cell carcinoma: results from the Phase III, randomized ATLAS trial. *Ann Oncol*. 2018;29(12):2371–2378.
22. Eisen T, Frangou E, Oza B, et al. Adjuvant sorafenib for renal cell carcinoma at intermediate or high risk of relapse: results from the SORCE randomized phase III intergroup trial. *J Clin Oncol*. 2020;38(34):4064–4075.
23. Ryan CW, Tangen C, Heath EI, et al. EVEREST: everolimus for renal cancer ensuing surgical therapy—A phase III study (SWOG S0931, NCT01120249). *J Clin Oncol*. 2022;40(17\_suppl):LBA4500–LBA4500.
24. Choueiri TK, Tomczak P, Park SH, et al. Adjuvant pembrolizumab after nephrectomy in renal-cell carcinoma. *N Engl J Med*. 2021;385(8):683–694.
25. Choueiri TK, Tomczak P, Park SH, et al. Pembrolizumab as post nephrectomy adjuvant therapy for patients with renal cell carcinoma: results from 30-month follow-up of KEYNOTE-564. *J Clin Oncol*. 2022;40(6\_suppl):290.
26. Pal SK, Uzzo R, Karam JA, et al. Adjuvant atezolizumab versus placebo for patients with renal cell carcinoma at increased risk of recurrence following resection (IMmotion10): a multicentre, randomised, double-blind, phase 3 trial. *Lancet*. 2022;400(10358):1103–1116.
27. Motzer RJ, Russo P, Gruenewald V, et al. LBA4 Adjuvant nivolumab plus ipilimumab (NIVO+IPI) vs placebo (PBO) for localized renal cell carcinoma (RCC) at high risk of relapse after nephrectomy: results from the randomized, phase III CheckMate 914 trial. *Annals Oncol*. 2022;33:S1430.
28. Allaf M, Kim SE, Harshman LC, et al. LBA67 Phase III randomized study comparing perioperative nivolumab (nivo) versus observation in patients (Pts) with renal cell carcinoma (RCC) undergoing nephrectomy (PROSPER, ECOG-ACRIN EA8143), a National Clinical Trials Network trial. *Annals Oncol*. 2022;33:S1432–S1433.
29. Oza B, Frangou E, Smith B, et al. RAMPART: a phase III multi-arm multi-stage trial of adjuvant checkpoint inhibitors in patients with resected primary renal cell carcinoma (RCC) at high or intermediate risk of relapse. *Contemp Clin Trials*. 2021;108:106482.
30. Choueiri TK, Bedke J, Karam JA, et al. LITESPARK-022: a phase 3 study of pembrolizumab + belzutifan as adjuvant treatment of clear cell renal cell carcinoma (ccRCC). *J Clin Oncol*. 2022;40(16\_suppl):TPS4602–TPS4602.
31. Shien T, Iwata H. Adjuvant and neoadjuvant therapy for breast cancer. *Jpn J Clin Oncol*. 2020;50(3):225–229.

32. Davies C, Godwin J; Early Breast Cancer Trialists' Collaborative G. Relevance of breast cancer hormone receptors and other factors to the efficacy of adjuvant tamoxifen: patient-level meta-analysis of randomised trials. *Lancet*. 2011;378(9793):771–784.
33. Davies C, Pan H, Godwin J, et al. Long-term effects of continuing adjuvant tamoxifen to 10 years versus stopping at 5 years after diagnosis of oestrogen receptor-positive breast cancer: ATLAS, a randomised trial. *Lancet*. 2013;381(9869):805–816.
34. Peto R, Davies C; Early Breast Cancer Trialists' Collaborative G. Comparisons between different polychemotherapy regimens for early breast cancer: meta-analyses of long-term outcome among 100,000 women in 123 randomised trials. *Lancet*. 2012;379(9814):432–444.
35. Jones S, Holmes FA, O'Shaughnessy J, et al. Docetaxel with cyclophosphamide is associated with an overall survival benefit compared with doxorubicin and cyclophosphamide: 7-year follow-up of US oncology research trial 9735. *J Clin Oncol*. 2009;27(8):1177–1183.
36. Blum JL, Flynn PJ, Yothers G, et al. Anthracyclines in early breast cancer: the ABC trials-USOR 06-090, NSABP B-46-I-USOR 07132, and NSABP B-49 (NRG Oncology). *J Clin Oncol*. 2017;35(23):2647–2655.
37. Slamon D, Eiermann W, Robert N, et al. Adjuvant trastuzumab in HER2-positive breast cancer. *N Engl J Med*. 2011;365(14):1273–1283.
38. von Minckwitz G, Procter M, de Azambuja E, et al. Adjuvant pertuzumab and trastuzumab in early HER2-positive breast cancer. *N Engl J Med*. 2017;377(2):122–131.
39. Cameron D, Piccart-Gebhart MJ, Gelber RD, et al. 11 years' follow-up of trastuzumab after adjuvant chemotherapy in HER2-positive early breast cancer: final analysis of the HERceptin Adjuvant (HERA) trial. *Lancet*. 2017;389(10075):1195–1205.
40. Deschavanne PJ, Fertl B. A review of human cell radiosensitivity in vitro. *Int J Radiat Oncol Biol Phys*. 1996;34(1):251–266.
41. Gunjur A, Duong C, Ball D, Siva S. Surgical and ablative therapies for the management of adrenal 'oligometastases' - A systematic review. *Cancer Treat Rev*. 2014;40(7):838–846.
42. Rühle A, Andrasschke N, Siva S, Guckenberger M. Is there a role for stereotactic radiotherapy in the treatment of renal cell carcinoma? *Clin Transl Radiat Oncol*. 2019;18:104–112.
43. Yoo GS, Park W, Pyo H, et al. Risk factors and patterns of locoregional recurrence after radical nephrectomy for locally advanced renal cell carcinoma. *Cancer Res Treat*. 2022;54(1):218–225.
44. Lee Z, Jegede OA, Haas NB, et al. Local recurrence following resection of intermediate-high risk nonmetastatic renal cell carcinoma: an anatomical classification and analysis of the ASSURE (ECOG-ACRIN E2805) adjuvant trial. *J Urol*. 2020;203(4):684–689.
45. Itano NB, Blute ML, Spotts B, Zincke H. Outcome of isolated renal cell carcinoma fossa recurrence after nephrectomy. *J Urol*. 2000;164(2):322–325.
46. Pierorazio PM, Johnson MH, Patel HD, et al. Management of renal masses and localized renal cancer: systematic review and meta-analysis. *J Urol*. 2016;196(4):989–999.
47. Andrews JR, Atwell T, Schmit G, et al. Oncologic outcomes following partial nephrectomy and percutaneous ablation for cT1 renal masses. *Eur Urol*. 2019;76(2):244–251.
48. Siva S, Daniels CP, Ellis RJ, Ponsky L, Lo SS. Stereotactic ablative body radiotherapy for primary kidney cancer: what have we learned from prospective trials and what does the future hold? *Future Oncol*. 2016;12(5):601–606.
49. Swaminath A, Chu W. Stereotactic body radiotherapy for the treatment of medically inoperable primary renal cell carcinoma: current evidence and future directions. *Can Urol Assoc J*. 2015;9(7–8):275–280.
50. Correa RJM, Rodrigues GB, Chen H, Warner A, Ahmad B, Louie AV. Stereotactic ablative radiotherapy (SABR) for large renal tumors: a retrospective case series evaluating clinical outcomes, toxicity, and technical considerations. *Am J Clin Oncol*. 2018;41(6):568–575.
51. Siva S, Louie AV, Warner A, et al. Pooled analysis of stereotactic ablative radiotherapy for primary renal cell carcinoma: a report from the International Radiosurgery Oncology Consortium for Kidney (IROCK). *Cancer*. 2018;124(5):934–942.
52. Correa RJM, Louie AV, Staehler M, et al. Stereotactic radiotherapy as a treatment option for renal tumors in the solitary kidney: a multicenter analysis from the IROCK. *J Urol*. 2019;201(6):1097–1104.
53. Siva S, Pham D, Kron T, et al. Stereotactic ablative body radiotherapy for inoperable primary kidney cancer: a prospective clinical trial. *BJU Int*. 2017;120(5):623–630.
54. Reynolds HM, Parameswaran BK, Finnegan ME, et al. Diffusion weighted and dynamic contrast enhanced MRI as an imaging biomarker for stereotactic ablative body radiotherapy (SABR) of primary renal cell carcinoma. *PLoS One*. 2018;13(8):e0202387.
55. Widdershoven CV, Aarts BM, Zondervan PJ, et al. Renal biopsies performed before versus during ablation of T1 renal tumors: implications for prevention of overtreatment and follow-up. *Abdom Radiol*. 2021;46(1):373–379.
56. Siva S, Jackson P, Kron T, et al. Impact of stereotactic radiotherapy on kidney function in primary renal cell carcinoma: establishing a dose-response relationship. *Radiother Oncol*. 2016;118(3):540–546.
57. Staehler M, Haseke N, Nuhn P, et al. Simultaneous anti-angiogenic therapy and single-fraction radiosurgery in clinically relevant metastases from renal cell carcinoma. *BJU Int*. 2011;108(5):673–678.
58. Siva S, Bressel M, Wood S, et al. Stereotactic radiotherapy and pembrolizumab for oligometastatic renal tumors: the RAPPORT trial. *J Clin Oncol*. 2021;39(6\_suppl):277.
59. Siva S, Bressel M, Wood ST, et al. Stereotactic radiotherapy and short-course pembrolizumab for oligometastatic renal cell carcinoma-the RAPPORT trial. *Eur Urol*. 2022;81(4):364–372.
60. Lin J, Song AJ, Hoffman-Censits J, et al. A pilot study of radiation therapy in combination with pembrolizumab in patients with metastatic renal cell cancer. *Am J Clin Oncol*. 2020;43(2):82–86.
61. Hammers HJ, Vonmerveldt D, Ahn C, et al. Combination of dual immune checkpoint inhibition (ICI) with stereotactic radiation (SBRT) in metastatic renal cell carcinoma (mRCC) (RADVAX RCC). *J Clin Oncol*. 2020;38(6\_suppl):614.
62. Masini C, Iotti C, De Giorgi U, et al. Nivolumab in combination with stereotactic body radiotherapy in pretreated patients with metastatic renal cell carcinoma. results of the phase II NIVES study. *Eur Urol*. 2022;81(3):274–282.
63. Darby S, McGale P; Early Breast Cancer Trialists' Collaborative G. Effect of radiotherapy after breast-conserving surgery on 10-year recurrence and 15-year breast cancer death: meta-analysis of individual patient data for 10,801 women in 17 randomised trials. *Lancet*. 2011;378(9804):1707–1716.
64. Kjaer M, Iversen P, Hvidt V, et al. A randomized trial of postoperative radiotherapy versus observation in stage II and III renal adenocarcinoma. A study by the Copenhagen Renal Cancer Study Group. *Scand J Urol Nephrol*. 1987;21(4):285–289.
65. Finney R. The value of radiotherapy in the treatment of hypernephroma—a clinical trial. *Br J Urol*. 1973;45(3):258–269.



66. Ulutin HC, Aksu G, Fayda M, Kuzhan O, Tahmaz L, Beyzadeoglu M. The value of postoperative radiotherapy in renal cell carcinoma: a single-institution experience. *Tumori*. 2006;92(3):202–206.
67. Rodriguez-Fernandez IA, Rodriguez-Romo L, Hernandez-Barajas D, et al. Adjuvant radiation therapy after radical nephrectomy in patients with localized renal cell carcinoma: a systematic review and meta-analysis. *Eur Urol Oncol*. 2019;2(4):448–455.
68. De Meerleer G, Khoo V, Escudier B, et al. Radiotherapy for renal-cell carcinoma. *Lancet Oncol*. 2014;15(4):e170–e177.
69. Escudier B, Eisen T, Porta C, et al. Renal cell carcinoma: ESMO Clinical Practice Guidelines for diagnosis, treatment and follow-up. *Ann Oncol*. 2012;23(Suppl 7):vii65–71.
70. Rini BI, Escudier B, Tomczak P, et al. Comparative effectiveness of axitinib versus sorafenib in advanced renal cell carcinoma (AXIS): a randomised phase 3 trial. *Lancet*. 2011;378(9807):1931–1939.
71. Hutson TE, Lesovoy V, Al-Shukri S, et al. Axitinib versus sorafenib as first-line therapy in patients with metastatic renal-cell carcinoma: a randomised open-label phase 3 trial. *Lancet Oncol*. 2013;14(13):1287–1294.
72. Sternberg CN, Davis ID, Mardiak J, et al. Pazopanib in locally advanced or metastatic renal cell carcinoma: results of a randomized phase III trial. *J Clin Oncol*. 2010;28(6):1061–1068.
73. Motzer RJ, Hutson TE, Cella D, et al. Pazopanib versus sunitinib in metastatic renal-cell carcinoma. *N Engl J Med*. 2013;369(8):722–731.
74. Motzer RJ, Hutson TE, McCann L, Deen K, Choueiri TK. Overall survival in renal-cell carcinoma with pazopanib versus sunitinib. *N Engl J Med*. 2014;370(18):1769–1770.
75. Motzer RJ, Hutson TE, Tomczak P, et al. Sunitinib versus interferon alfa in metastatic renal-cell carcinoma. *N Engl J Med*. 2007;356(2):115–124.
76. Motzer RJ, Hutson TE, Tomczak P, et al. Overall survival and updated results for sunitinib compared with interferon alfa in patients with metastatic renal cell carcinoma. *J Clin Oncol*. 2009;27(22):3584–3590.
77. Escudier B, Eisen T, Stadler WM, et al. Sorafenib in advanced clear-cell renal-cell carcinoma. *N Engl J Med*. 2007;356(2):125–134.
78. Escudier B, Eisen T, Stadler WM, et al. Sorafenib for treatment of renal cell carcinoma: final efficacy and safety results of the phase III treatment approaches in renal cancer global evaluation trial. *J Clin Oncol*. 2009;27(20):3312–3318.
79. Hutson TE, Escudier B, Esteban E, et al. Randomized phase III trial of temsirolimus versus sorafenib as second-line therapy after sunitinib in patients with metastatic renal cell carcinoma. *J Clin Oncol*. 2014;32(8):760–767.
80. Motzer RJ, Escudier B, Oudard S, et al. Efficacy of everolimus in advanced renal cell carcinoma: a double-blind, randomised, placebo-controlled phase III trial. *Lancet*. 2008;372(9637):449–456.
81. Motzer RJ, Escudier B, Oudard S, et al. Phase 3 trial of everolimus for metastatic renal cell carcinoma: final results and analysis of prognostic factors. *Cancer*. 2010;116(18):4256–4265.
82. Motzer RJ, Escudier B, McDermott DF, et al. Nivolumab versus everolimus in advanced renal-cell carcinoma. *N Engl J Med*. 2015;373(19):1803–1813.
83. Escudier B, Sharma P, McDermott DF, et al. CheckMate 025 randomized phase 3 study: outcomes by key baseline factors and prior therapy for nivolumab versus everolimus in advanced renal cell carcinoma. *Eur Urol*. 2017;72(6):962–971.
84. Motzer RJ, Tannir NM, McDermott DF, et al. Nivolumab plus ipilimumab versus sunitinib in advanced renal-cell carcinoma. *N Engl J Med*. 2018;378(14):1277–1290.
85. Quhal F, Mori K, Fajkovic H, Remzi M, Shariat SF, Schmidinger M. Immunotherapy-based combinations in the first-line treatment of metastatic renal cell carcinoma with sarcomatoid features: a systematic review and network meta-analysis. *Curr Opin Urol*. 2022;32(1):61–68.
86. Motzer RJ, Jonasch E, Agarwal N, et al. Kidney cancer, version 3.2022, NCCN clinical practice guidelines in oncology. *J Natl Compr Canc Netw*. 2022;20(1):71–90.
87. McDermott DF, Regan MM, Clark JI, et al. Randomized phase III trial of high-dose interleukin-2 versus subcutaneous interleukin-2 and interferon in patients with metastatic renal cell carcinoma. *J Clin Oncol*. 2005;23(1):133–141.
88. Rosenberg SA, Mule JJ, Spiess PJ, Reichert CM, Schwarz SL. Regression of established pulmonary metastases and subcutaneous tumor mediated by the systemic administration of high-dose recombinant interleukin 2. *J Exp Med*. 1985;161(5):1169–1188.
89. Yang JC, Sherry RM, Steinberg SM, et al. Randomized study of high-dose and low-dose interleukin-2 in patients with metastatic renal cancer. *J Clin Oncol*. 2003;21(16):3127–3132.
90. Clark JI, Atkins MB, Urbani WJ, et al. Adjuvant high-dose bolus interleukin-2 for patients with high-risk renal cell carcinoma: a cytokine working group randomized trial. *J Clin Oncol*. 2003;21(16):3133–3140.
91. Choueiri TK, Halabi S, Sanford BL, et al. Cabozantinib versus sunitinib as initial targeted therapy for patients with metastatic renal cell carcinoma of poor or intermediate risk: the alliance A031203 CABOSUN trial. *J Clin Oncol*. 2017;35(6):591–597.
92. Choueiri TK, Escudier B, Powles T, et al. Cabozantinib versus everolimus in advanced renal-cell carcinoma. *N Engl J Med*. 2015;373(19):1814–1823.
93. Choueiri TK, Escudier B, Powles T, et al. Cabozantinib versus everolimus in advanced renal cell carcinoma (METEOR): final results from a randomised, open-label, phase 3 trial. *Lancet Oncol*. 2016;17(7):917–927.
94. Motzer RJ, Escudier B, Powles T, Scheffold C, Choueiri TK. Long-term follow-up of overall survival for cabozantinib versus everolimus in advanced renal cell carcinoma. *Br J Cancer*. 2018;118(9):1176–1178.
95. Amzal B, Fu S, Meng J, Lister J, Karcher H. Cabozantinib versus everolimus, nivolumab, axitinib, sorafenib and best supportive care: a network meta-analysis of progression-free survival and overall survival in second line treatment of advanced renal cell carcinoma. *PLoS One*. 2017;12(9):e0184423.
96. Hudes G, Carducci M, Tomczak P, et al. Temsirolimus, interferon alfa, or both for advanced renal-cell carcinoma. *N Engl J Med*. 2007;356(22):2271–2281.
97. Rini BI, Pal SK, Escudier BJ, et al. Tivozanib versus sorafenib in patients with advanced renal cell carcinoma (TIVO-3): a phase 3, multicentre, randomised, controlled, open-label study. *Lancet Oncol*. 2020;21(1):95–104.
98. Szarek M, Needle MN, Rini BI, et al. Q-twist analysis of tivozanib versus sorafenib in patients with advanced renal cell carcinoma in the TIVO-3 study. *Clin Genitourin Cancer*. 2021;19(5):468 e461–468 e465.
99. Yang JC, Haworth L, Sherry RM, et al. A randomized trial of bevacizumab, an anti-vascular endothelial growth factor antibody, for metastatic renal cancer. *N Engl J Med*. 2003;349(5):427–434.



100. Jonasch E, Donskov F, Iliopoulos O, et al. Belzutifan for renal cell carcinoma in von Hippel-Lindau disease. *N Engl J Med.* 2021;385(22):2036–2046. doi:10.1056/NEJMoa2103425
101. Bauer TM, Choueiri TK, Papadopoulos KP, et al. The oral HIF-2  $\alpha$  inhibitor MK-6482 in patients with advanced clear cell renal cell carcinoma (RCC): updated follow-up of a phase I/II study. *J Clin Oncol.* 2021;39(6\_suppl):273. doi:10.1200/JCO.2021.39.6\_suppl.273
102. Rini BI, Plimack ER, Stus V, et al. Pembrolizumab plus axitinib versus sunitinib for advanced renal-cell carcinoma. *N Engl J Med.* 2019;380(12):1116–1127. doi:10.1056/NEJMoa1816714
103. Powles T, Plimack ER, Soulieres D, et al. Pembrolizumab plus axitinib versus sunitinib monotherapy as first-line treatment of advanced renal cell carcinoma (KEYNOTE-426): extended follow-up from a randomised, open-label, phase 3 trial. *Lancet Oncol.* 2020;21(12):1563–1573.
104. Choueiri TK, Powles T, Burotto M, et al. Nivolumab plus cabozantinib versus sunitinib for advanced renal-cell carcinoma. *N Engl J Med.* 2021;384(9):829–841.
105. Motzer R, Choueiri TK. Lenvatinib plus pembrolizumab for renal cell carcinoma. reply. *N Engl J Med.* 2021;385(3):287.
106. Motzer RJ, Penkov K, Haanen J, et al. Avelumab plus axitinib versus sunitinib for advanced renal-cell carcinoma. *N Engl J Med.* 2019;380(12):1103–1115.
107. Choueiri TK, Motzer RJ, Rini BI, et al. Updated efficacy results from the JAVELIN Renal 101 trial: first-line avelumab plus axitinib versus sunitinib in patients with advanced renal cell carcinoma. *Ann Oncol.* 2020;31(8):1030–1039.
108. Choueiri TK, Larkin J, Pal S, et al. Efficacy and correlative analyses of avelumab plus axitinib versus sunitinib in sarcomatoid renal cell carcinoma: post hoc analysis of a randomized clinical trial. *ESMO Open.* 2021;6(3):100101.
109. Motzer RJ, Hutson TE, Glen H, et al. Lenvatinib, everolimus, and the combination in patients with metastatic renal cell carcinoma: a randomised, Phase 2, open-label, multicentre trial. *Lancet Oncol.* 2015;16(15):1473–1482.
110. Motzer RJ, Hutson TE, Ren M, Dutcs C, Larkin J. Independent assessment of lenvatinib plus everolimus in patients with metastatic renal cell carcinoma. *Lancet Oncol.* 2016;17(1):e4–e5.
111. Borregales LD, Adibi M, Thomas AZ, Wood CG, Karam JA. The role of neoadjuvant therapy in the management of locally advanced renal cell carcinoma. *Ther Adv Urol.* 2016;8(2):130–141.
112. George DJ, Martini JF, Staehler M, et al. Phase III trial of adjuvant sunitinib in patients with high-risk renal cell carcinoma: exploratory pharmacogenomic analysis. *Clin Cancer Res.* 2019;25(4):1165–1173.
113. Wu Q, Huang G, Wei W, Liu J. Molecular imaging of renal cell carcinoma in precision medicine. *Mol Pharm.* 2022;19:3457–3470.
114. Oosterwijk E, Ruiter DJ, Hoedemaeker PJ, et al. Monoclonal antibody G 250 recognizes a determinant present in renal-cell carcinoma and absent from normal kidney. *Int J Cancer.* 1986;38(4):489–494.
115. Muselaers CH, Stillebroer AB, Desai IM, et al. Tyrosine kinase inhibitor sorafenib decreases <sup>111</sup>In-girentuximab uptake in patients with clear cell renal cell carcinoma. *J Nucl Med.* 2014;55(2):242–247.
116. Hekman MCH, Rijpkema M, Aarntzen EH, et al. Positron emission tomography/computed tomography with (89)Zr-girentuximab can aid in diagnostic dilemmas of clear cell renal cell carcinoma suspicion. *Eur Urol.* 2018;74(3):257–260.
117. Divgi CR, Pandit-Taskar N, Jungbluth AA, et al. Preoperative characterisation of clear-cell renal carcinoma using iodine-124-labelled antibody chimeric G250 (124I-cG250) and PET in patients with renal masses: a Phase I trial. *Lancet Oncol.* 2007;8(4):304–310.
118. Divgi CR, Uzzo RG, Gatsonis C, et al. Positron emission tomography/computed tomography identification of clear cell renal cell carcinoma: results from the REDECT trial. *J Clin Oncol.* 2013;31(2):187–194.
119. Verhoeff SR, van Es SC, Boon E, et al. Lesion detection by [(89)Zr]Zr-DFO-girentuximab and [(18)F]FDG-PET/CT in patients with newly diagnosed metastatic renal cell carcinoma. *Eur J Nucl Med Mol Imaging.* 2019;46(9):1931–1939.
120. Wei W, Ni D, Ehlerding EB, Luo QY, Cai W. PET imaging of receptor tyrosine kinases in cancer. *Mol Cancer Ther.* 2018;17(8):1625–1636.
121. Oosting SF, Brouwers AH, van Es SC, et al. 89Zr-bevacizumab PET visualizes heterogeneous tracer accumulation in tumor lesions of renal cell carcinoma patients and differential effects of antiangiogenic treatment. *J Nucl Med.* 2015;56(1):63–69.
122. van Es SC, Brouwers AH, Mahesh SVK, et al. (89)Zr-bevacizumab PET: potential early indicator of everolimus efficacy in patients with metastatic renal cell carcinoma. *J Nucl Med.* 2017;58(6):905–910.
123. Rowe SP, Gorin MA, Pomper MG. Imaging of Prostate-specific membrane antigen with small-molecule PET radiotracers: from the bench to advanced clinical applications. *Annu Rev Med.* 2019;70:461–477.
124. Rowe SP, Gorin MA, Hammers HJ, et al. Imaging of metastatic clear cell renal cell carcinoma with PSMA-targeted (1)(8)F-DCFPyL PET/CT. *Ann Nucl Med.* 2015;29(10):877–882.
125. Giesel FL, Will L, Lawal I, et al. Intraindividual Comparison of (18)F-PSMA-1007 and (18)F-DCFPyL PET/CT in the prospective evaluation of patients with newly diagnosed prostate carcinoma: a pilot study. *J Nucl Med.* 2018;59(7):1076–1080.
126. Marafi F, Sasikumar A, Aldaas M, Esmail A. 18F-PSMA-1007 PET/CT for initial staging of renal cell carcinoma in an end-stage renal disease patient. *Clin Nucl Med.* 2021;46(1):e65–e67.
127. Marafi F, Sasikumar A, Al-Terki A, Alfeeli M. 18F-PSMA 1007 in suspected renal cell carcinoma. *Clin Nucl Med.* 2020;45(5):377–378.
128. Mittlmeier LM, Unterrainer M, Rodler S, et al. (18)F-PSMA-1007 PET/CT for response assessment in patients with metastatic renal cell carcinoma undergoing tyrosine kinase or checkpoint inhibitor therapy: preliminary results. *Eur J Nucl Med Mol Imaging.* 2021;48(6):2031–2037.
129. Bouleau A, Lebon V, Truillet C. PET imaging of immune checkpoint proteins in oncology. *Pharmacol Ther.* 2021;222:107786.
130. Fasanella D, Antonaci A, Esperto F, et al. Potential prognostic value of miRNAs as biomarker for progression and recurrence after nephrectomy in renal cell carcinoma: a literature review. *Diagnosis.* 2021;9(2):157–165.
131. Koudonas A, Papaioannou M, Kampantais S, Anastasiadis A, Hatzimouratidis K, Dimitriadis G. Methylation of PCDH17 and NEFH as prognostic biomarker for nonmetastatic RCC: a cohort study. *Medicine.* 2022;101(28):e29599.
132. Xu L, Chang Y, An H, Zhu Y, Yang Y, Xu J. High APOBEC3B expression is a predictor of recurrence in patients with low-risk clear cell renal cell carcinoma. *Urol Oncol.* 2015;33(8):340 e341–348.
133. Fu Q, Chang Y, Zhou L, et al. Positive intratumoral chemokine (C-C motif) receptor 8 expression predicts high recurrence risk of post-operation clear-cell renal cell carcinoma patients. *Oncotarget.* 2016;7(7):8413–8421.
134. Nishikawa M, Miyake H, Harada K, Fujisawa M. Expression of molecular markers associated with the mammalian target of rapamycin pathway in nonmetastatic renal cell carcinoma: effect on prognostic outcomes following radical nephrectomy. *Urol Oncol.* 2014;32(1):49 e15–21.

135. Rasti A, Mehrazma M, Madjd Z, Abolhasani M, Saeednejad Zanjani L, Asgari M. Co-expression of cancer stem cell markers OCT4 and NANOG predicts poor prognosis in renal cell carcinomas. *Sci Rep*. 2018;8(1):11739.
136. Yoshida T, Kageyama S, Isono T, et al. Superoxide dismutase 2 expression can predict prognosis of renal cell carcinoma patients. *Cancer Biomark*. 2018;22(4):755–761.
137. Hongo F, Takaha N, Oishi M, et al. CDK1 and CDK2 activity is a strong predictor of renal cell carcinoma recurrence. *Urol Oncol*. 2014;32(8):1240–1246.
138. Ngo TC, Wood CG, Karam JA. Biomarkers of renal cell carcinoma. *Urol Oncol*. 2014;32(3):243–251.
139. Crispen PL, Boorjian SA, Lohse CM, Leibovich BC, Kwon ED. Predicting disease progression after nephrectomy for localized renal cell carcinoma: the utility of prognostic models and molecular biomarkers. *Cancer*. 2008;113(3):450–460.
140. Lakshminarayanan H, Rutishauser D, Schraml P, Moch H, Bolck HA. Liquid biopsies in renal cell carcinoma-recent advances and promising new technologies for the early detection of metastatic disease. *Front Oncol*. 2020;10:582843.
141. Ghatalia P, Rathmell WK. Systematic review: clearCode 34 - A validated prognostic signature in clear cell renal cell carcinoma (ccRCC). *Kidney Cancer*. 2018;2(1):23–29.
142. Swaminath A, Cheung P, Glicksman RM, et al. Patient-reported quality of life following stereotactic body radiation therapy for primary kidney cancer - results from a prospective cohort study. *Clin Oncol*. 2021;33(7):468–475.
143. Margulis V, Freifeld Y, Pop LM, et al. Neoadjuvant SABR for renal cell carcinoma inferior vena cava tumor thrombus-safety lead-in results of a phase 2 trial. *Int J Radiat Oncol Biol Phys*. 2021;110(4):1135–1142.
144. Tetar SU, Bohoudi O, Senan S, et al. The role of daily adaptive stereotactic MR-guided radiotherapy for renal cell cancer. *Cancers*. 2020;12(10):2763.
145. Siva S, Correa RJM, Warner A, et al. Stereotactic ablative radiotherapy for  $\geq T1b$  primary renal cell carcinoma: a report from the international radiosurgery oncology consortium for kidney (IROCK). *Int J Radiat Oncol Biol Phys*. 2020;108(4):941–949.
146. Senger C, Conti A, Kluge A, et al. Robotic stereotactic ablative radiotherapy for renal cell carcinoma in patients with impaired renal function. *BMC Urol*. 2019;19(1):96.
147. Grelier L, Baboudjian M, Gondran-Tellier B, et al. Stereotactic body radiotherapy for frail patients with primary renal cell carcinoma: preliminary results after 4 years of experience. *Cancers*. 2021;13(13):3129.
148. Grubb WR, Ponsky L, Lo SS, et al. Final results of a dose escalation protocol of stereotactic body radiotherapy for poor surgical candidates with localized renal cell carcinoma. *Radiother Oncol*. 2021;155:138–143.
149. Kjaer M, Frederiksen PL, Engelholm SA. Postoperative radiotherapy in stage II and III renal adenocarcinoma. A randomized trial by the Copenhagen Renal Cancer Study Group. *Int J Radiat Oncol Biol Phys*. 1987;13(5):665–672.
150. Stein M, Kuten A, Halpern J, Coachman NM, Cohen Y, Robinson E. The value of postoperative irradiation in renal cell cancer. *Radiother Oncol*. 1992;24(1):41–44.
151. Kao GD, Malkowicz SB, Whittington R, D'Amico AV, Wein AJ. Locally advanced renal cell carcinoma: low complication rate and efficacy of postnephrectomy radiation therapy planned with CT. *Radiology*. 1994;193(3):725–730.
152. Makarewicz R, Zarzycka M, Kulinska G, Windorbska W. The value of postoperative radiotherapy in advanced renal cell cancer. *Neoplasma*. 1998;45(6):380–383.

## OncoTargets and Therapy

Dovepress

### Publish your work in this journal

OncoTargets and Therapy is an international, peer-reviewed, open access journal focusing on the pathological basis of all cancers, potential targets for therapy and treatment protocols employed to improve the management of cancer patients. The journal also focuses on the impact of management programs and new therapeutic agents and protocols on patient perspectives such as quality of life, adherence and satisfaction. The manuscript management system is completely online and includes a very quick and fair peer-review system, which is all easy to use. Visit <http://www.dovepress.com/testimonials.php> to read real quotes from published authors.

Submit your manuscript here: <https://www.dovepress.com/oncotargets-and-therapy-journal>