

Clinical Observation of Sequential Laser Therapy Combined with Tension Reducer for Postoperative Tension Incision Scar Growth

Ting-Yu Wang, Zi-Qing Ye, Weiguo Xie

Department of Burns, Tongren Hospital of WuHan University & WuHan Third Hospital, WuHan, People's Republic of China

Correspondence: Zi-Qing Ye; Weiguo Xie, Department of Burns, Tongren Hospital of WuHan University & WuHan Third Hospital, 241 Pengliuyang Road, Wuchang District, WuHan, 430074, People's Republic of China, Tel +86 13277933698; +86 18071085225, Email 71737700@qq.com; wxie@hotmail.com

Objective: To investigate the clinical effectiveness of laser and secure wound-closure system (Tension reducer) in the treatment of postoperative scarring after tension incision.

Methods: A retrospectively observational study was conducted. Twenty-six patients who underwent surgical treatment in our department between June 2017 and December 2021 were selected, and those treated with laser and tension reducer were treated as a combined treatment group, and those treated with laser were treated as a conventional treatment group. Fifteen patients in the conventional group were treated with the pulsed dye laser and CO₂ fractional laser at 1–2 month intervals. Eleven people in the combined treatment group were treated with the laser in addition to a tension reducer for 3–6 months. The scar width, scar thickness, scar hardness, pruritus score, modified Vancouver scar scale and complication rates between the two treatment modalities were compared between the two groups at 6 months postoperatively.

Results: The scar thickness, scar hardness and modified Vancouver scar scale of 1.25 (0.14, 1.90) mm, 31.80 (21.00, 37.20) HA, (6.00 ± 2.17) in patients in the combined treatment group were less than those of patients in the conventional treatment group of 5.50 (4.00, 11.50) mm, 42.60 (32.50, 47.00) HA, (8.25±1.91), (Z=2.883, 2.718, t=2.904, p<0.05). The scar width and pruritus score in the combined treatment group, were 8.00 (5.00, 18.00) mm and 0 (0, 1) respectively, while the scar score and pruritus score in the conventional treatment group, were 5.50 (4.00, 11.50) mm respectively, with no statistically significant difference between the two groups. The complication rate was 55% in the combined treatment group and no adverse reactions occurred in the control group.

Conclusion: Sequential laser combined with tension reducer treatment can effectively inhibit the proliferation of postoperative tension incision scar.

Keywords: tension reducer, tension surgical incision, scar, CO₂ LASER, pulsed dye laser

Introduction

Scarring is a common post-operative complication, with a prevalence of over 60% in post-operative patients,¹ especially in procedures related to tissue excision, such as keloid excision, ulcerative wound excision and flap donor areas, which can lead to greater post-operative incisions tension and a higher probability of scar growth.² The proliferating scar loses its normal skin structure due to excessive deposition of collagen and other extracellular matrix proteins, resulting in a stiff surface texture and, in severe cases, even scar contracture, which affects the patient's limb function.³ In addition, scarring of specific areas such as the face can affect the patient's appearance and can cause a degree of psychological disturbance in the patient. In order to effectively inhibit the proliferation of post-operative scarring, a number of medical treatments are currently available to treat scarring. Among them, photoelectric therapy is the most effective, as it selectively acts on haemoglobin, pigment and tissue water in the scar through the principle of selective thermal ablation,⁴ promoting collagen rearrangement and thus improving the texture and symptoms of the scar, and is considered to be the first line of treatment for scarring.^{5,6} In addition, different kinds of lasers work together to improve the

appearance of scars, which are suitable for the early prevention and treatment of scars.⁷ However, in the face of tension incisions, it is difficult to completely control scar growth by laser treatment alone. As a new treatment method, a kind of tension reducer specially designed for surgical incision can transfer tension on both sides of the incision to inhibit scar hyperplasia, which is considered as Level I evidence recommendation.^{7,8} Therefore, the present study is intended to investigate the clinical effects of sequential laser therapy combined with a tension reducer to prevent postoperative scar growth in tension incisions.

Information and Methods

Inclusion Criteria

Inclusion Criteria

Patients who meet all of the following criteria: 1. Patients undergoing surgery for excision of ulcerated wounds, scar excision, excision of deep burn wounds and excision of flap donor areas. 2. Patients without postoperative incision infection. 3. Patients undergoing laser treatment or laser combined with tension reducer treatment. 4. Patients under 60 years of age, regardless of gender.

Exclusion Criteria

1. Patients who are unable to adhere to follow-up visits and have incomplete case data. 2. Patients with cognitive impairment and mental illness. 3. Patients with diabetes and immunodeficiency. 4. Patients who require reoperation at late observation sites.

Clinical Data

A retrospective observational study method was used to include 26 patients who underwent flap donor area excision, ulcer wound excision, scar excision, and deep wound excision in the burn unit between June 2017 and December 2020 at the Third Hospital of Wuhan City, and those who used a tension reducer combined with laser treatment were used as the combined treatment group, and those who used laser treatment only were used as the conventional treatment group, and all patients were followed up for more than 6 months. There were 11 patients in the combined treatment group, of which 1 person in the combined treatment group had two scars as the observation site, and 2 people with two scars were used as the combined treatment group and the conventional treatment group, respectively. There were 15 patients in the conventional treatment group, and one person in the conventional treatment group had two scars as the observation site. The general clinical data of the patients in the two groups, the differences were not statistically significant and were comparable. (The clinical observation followed the Declaration of Helsinki and was approved by the Medical Ethics Committee of the Wuhan Third Hospital under the ethics number: Wu San Medical Lun KY-2022-047, and all patients participating in this study and those under 18 years of age had their parents or guardians sign informed consent.) See [Table 1](#).

Main Instrument Sources

Skin stretching and Secure Wound-closure System (Shu Antai, Henan Huibo Medical Co., Ltd. See [Figure 1](#)), DC-8 Doppler ultrasound (Shenzhen Myriad Biomedical Electronics Co., Ltd.), HT-651000 Shore hardness tester (Guangzhou

Table 1 Comparison of General Clinical Information Between the Two Groups of Patients

Groups	Example	Male	Female	Face	Neck	Forequarters	Arms	Legs	Age	Number of Laser Treatments
Combined treatment group	11	4	7	1	0	6	2	3	7.5 (6.5,22)	3 (2, 3)
Conventional treatment group	15	9	6	1	5	6	1	3	6.5 (3.5,25)	3 (2.5, 4.5)
Test values		$\chi^2=2.181$		$\chi^2=4.861$					Z=0.443	Z=0.838
P		0.14		0.302					0.658	0.402

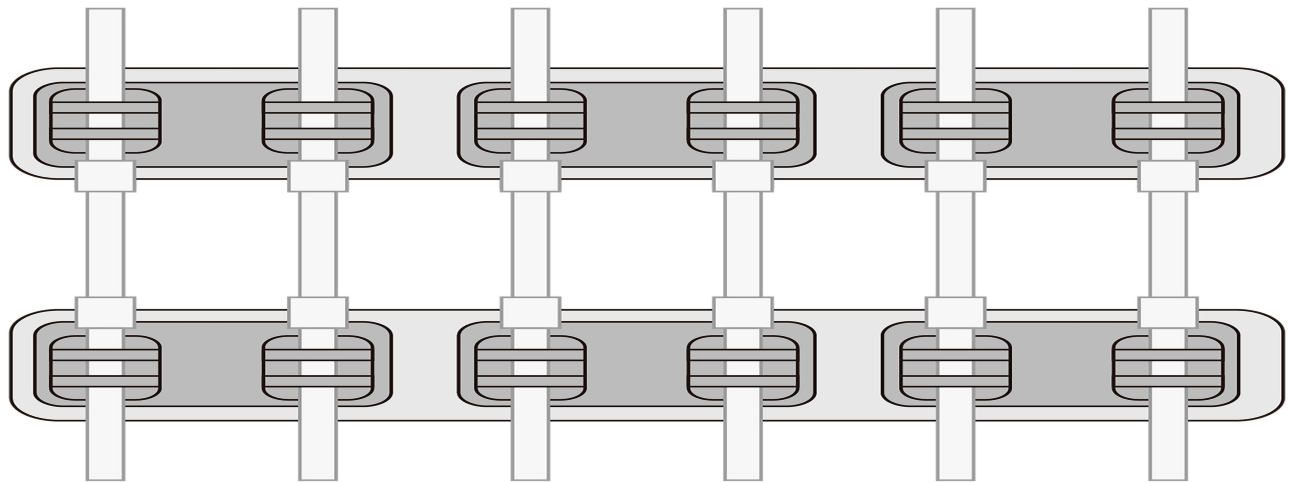


Figure 1 Schematic diagram of tension reducer.

Lantai Instruments Co., Ltd.), Vbeam Platinum type PDL laser therapy instrument (Candela, USA), UltraPulse Encor CO2 laser therapy instrument (Lumenis medical laser company).

Treatment Options

At three to five weeks post-operatively, all patients are given a choice of laser treatment modalities depending on the extent of scar growth. If the scar is severely congested (congestion score ≥ 2), pulsed laser treatment is given once a month. If the scar shows significant signs of hyperplasia, CO2 fractional laser treatment is chosen once every two months. If both conditions are found, a combination of pulsed laser treatment once a month and CO2 fractional laser treatment once every two months is used. Specific protocols for laser treatment and post-operative care can be found in previous articles published by our department.⁹ In the conventional treatment group, the sequential laser therapy was run as described above. The combined treatment group, the use of a tension reducer is added to the conventional treatment group. After the stitches have been removed, the skin around the wound is scrubbed with 75% medical alcohol 2–3 times and allowed to evaporate naturally. The tension reducers are then cut according to the length of the incision and applied symmetrically to both sides of the incision, and the latches on both sides of the tensioners are gently tightened until the skin is slightly wrinkled.

Assessment Indicators

Assessment Methods

Postoperative Follow-Up

Patients were all followed up at the time of outpatient laser treatment after discharge, at 1 month, 3 months and 6 months after surgery, respectively. Each patient's scar assessment index was also measured, recorded and photographed for documentation.

Observation Indexes

Scar Width

The scar was divided into three segments, and the width of the patient's scar was measured in segments to take the average value and recorded.

Scar Thickness

Using Doppler ultrasound, after selecting the L12-3E high frequency probe, applying coupling agent and placing it vertically on the scar surface, three measurement points were selected for each scar to measure the scar thickness, and the results were taken as the mean value.

Scar Hardness

Using a hardness tester, after pressing gently in the direction of the scar perpendicularly, measure three times to take the average value.

Modified Vancouver Scar Scale

Using our modified Vancouver scar scale, two doctors scored the degree of congestion, thickness and tenderness of the scar respectively, and took the average value. Degree of engorgement: The engorgement of the scar was shown as red color due to overfilling of capillaries, and the color of the scar faded after gentle pressure by hand and returned to red after release. No congestion is scored as 0, slight congestion is scored as 1, mild congestion is scored as 2, moderate congestion is scored as 3, severe congestion (red color due to overfilled capillaries) is scored as 4, and very severe congestion (purple color due to stagnant blood flow) is scored as 5. Scar thickness: 0 for normal skin, 1 for thickness 1mm, 2 for thickness 2mm, 3 for 3, 4 for 4mm, and 5 for >4mm. Scar tenderness: 0 points for normal skin, 1 point for soft (deformable under minimal resistance), 2 points for pliable (deformable under pressure), 3 points for harder (greater resistance to pressure, deformable under greater pressure, moving in a block), 4 points for hard (greater resistance to pressure, not deformable, moving in a block), and 5 points for scar contracture.⁹ Total score: 0–15 points.

Pruritus Score

Visual Simulation Scoring (VAS) was used to quantify the degree of pruritus at the patient's scar site on a scale of 0–10.¹⁰

Complication Rates

The complications arising during laser combined with tension reducer treatment, such as tension blisters, skin breakdown, and allergy, were recorded and their incidence was calculated.

Statistical Methods

Data were analyzed using SPSS 22.0 statistical program. Quantitative data with normal distribution were expressed as mean \pm standard deviation (\pm S), and independent samples *t*-test was performed for comparison between two groups; measurement data with non-normal distribution were expressed as median [M(P25, P75)], and non-parametric test was used for comparison between groups; count data were expressed as percentages (%), and Pearson chi-square test; $P < 0.05$ indicates that the difference is statistically significant.

Results

Scar Width

In both groups, the scar width was 8.00 (5.00, 18.00) mm for patients in the laser combined with tensioner treatment group and 5.50 (4.00, 11.50) mm for patients in the conventional laser treatment group, and the difference was not statistically significant ($Z=0.798$, $P>0.05$) when comparing the scar width of the two groups. See Table 2.

Table 2 Comparison of Scar Width, Scar Thickness, Scar Hardness, Modified Vancouver Score, and Pruritus Score Between Two Groups of Patients

Groups	Number of Scars	Width of Scar (mm)	Thickness of Scar (mm)	Scar Hardness (HA)	Modified Vancouver Scar Scale	Pruritus Score
Combined treatment group	12	8.00 (5.00, 18.00)	1.25 (0.14, 1.90)	31.80 (21.00, 37.20)	6.00 \pm 2.17	0 (0, 1)
Conventional treatment group	16	5.50 (4.00, 11.50)	2.90 (2.35, 3.50)	42.60 (32.50, 47.00)	8.25 \pm 1.91	0 (0, 2)
Test values		0.798	2.883	2.718	2.904	0.959
P		0.425	0.004	0.007	0.007	0.013

Scar Thicknesses

In both groups, the scar thickness of 1.25 (0.14, 1.90) mm in the laser combined with a tensioner treatment group was significantly smaller than that of 2.90 (2.35, 3.50) mm in the conventional laser treatment group, and the difference was statistically significant ($Z=2.883$, $P<0.05$) (See Table 2, Figure 2).

Scar Hardness

In both groups, the scar hardness was 31.80 (21.00, 37.20) HA in the laser combined with a tensioner treatment group and 42.60 (32.50, 47.00) HA in the conventional laser treatment group, and the scar hardness in the combined treatment group was smaller than that in the conventional laser treatment group, and the difference was statistically significant ($Z=2.718$, $P<0.05$). See Table 2.

Modified Vancouver Scar Scale

In both groups, the modified Vancouver score was (6.00 ± 2.17) in the laser combined with tensioner treatment group and (8.25 ± 1.91) in the conventional laser treatment group, and the modified Vancouver score in the laser combined with tensioner treatment group was significantly smaller than that in the conventional laser treatment group, and the difference was statistically significant ($t=2.904$, $P<0.05$) (See Table 2, Figure 3).

Pruritus Score

In both groups, the pruritus score was 0 (0, 1) in the laser combined with tensioner treatment group and 0 (0, 2) in the conventional laser treatment group, and there was no statistically significant difference between the pruritus scores of the two groups ($Z=0.959$, $P>0.05$) See Table 2.

Incidence of Complications

The incidence of complications in the laser combined with tension reducer treatment group was 55%, and four patients showed skin breakage and one rash when using the tension reducer, etc. No significant complications occurred in both groups of patients using the laser.

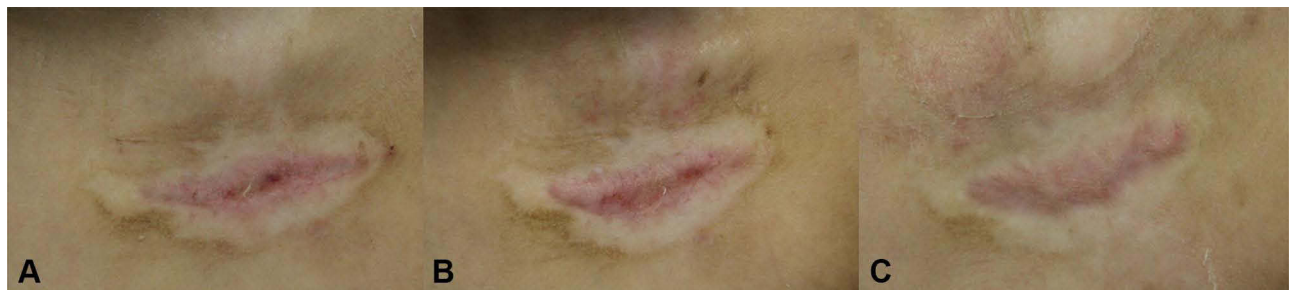

Figure 2 Female, 7 years old, (A) 1s one month post-treatment, (B) 1s three months post-treatment, and (C) 1s six months post-treatment.

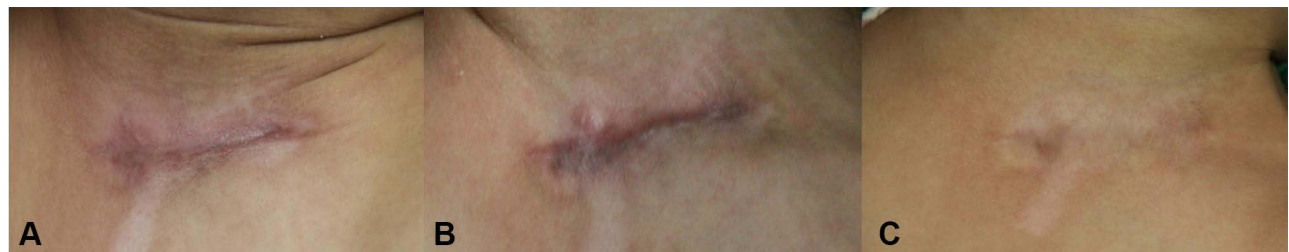

Figure 3 Female, 2 years old, (A) 1s one month post-treatment, (B) 1s three months post-treatment, and (C) 1s six months post-treatment.

Discussion

Problems related to the aesthetics of postoperative incisions are part of the hot topics of medical research. In general surgical incisions, the use of laser treatment alone can inhibit scar growth and achieve good results.¹¹ However, in the face of tension surgical incisions, the large amount of tissue removed results in higher tension in the incision. Tension is one of the most important factors affecting scar growth, the higher the tension the more severe the scar growth. By changing the microenvironment of the wound, tension affects changes in cell function, movement and signal transduction, which in turn promotes scar growth.¹² Therefore, postoperative scar growth is difficult to control with laser treatment alone for surgical incisions with high tension.^{13,14}

In this study, by comparing the degree of post-operative scar growth between the two groups of patients treated with different treatments, the results showed that the modified Vancouver score, scar thickness and scar hardness were significantly lower in the combined treatment group than in the conventional treatment group. Patients treated with the combination of tension reducer and sequential laser therapy showed a significant improvement in the scar, which was flatter and softer in texture. The greatest improvement in the degree of congestion, flexibility and thickness of the scar was seen with the combination of laser treatment with a tensioner, which was also consistent with the results we expected. A related study using CO₂ fractional laser to control scar growth after skin cancer surgery found that the CO₂ fractional laser was effective in controlling scar thickness and flexibility.¹⁵ Furthermore, studies have shown that the use of tension-reducing devices such as tension-reducing tape¹⁶ and tension reducers^{17,18} are also clinically effective in inhibiting postoperative scar growth. These devices not only reduce the thickness of the scar, but also the width of the scar. As both tension reducer and lasers can decrease the thickness and flexibility of the scar, the combination of the two has a synergistic effect, which explains why laser treatment in combination with tensioners is more effective than laser treatment.

In addition, most of the patients in both groups did not exhibit significant pruritus, with only a few patients exhibiting mild pruritus. On the one hand, this may be due to the small size of the scar growths of the patients in this study and the fact that the patients themselves had fewer risk factors for manifesting pruritus.¹⁹ On the other hand, it may be related to the fact that laser treatment reduces the pruritus symptoms of the patients,²⁰ so that no significant pruritus manifested itself in either group. Both treatment modalities not only have a synergistic effect by reducing the thickness as well as the tenderness of the scar, but also have their own unique effects, such as the laser reducing the patients' pruritus symptoms and the tension reducer reducing the width of the postoperative scar growth. However, the two groups of patients in this study showed no significant difference in scar width, which is at variance with other clinical observations.^{21–23} This may be linked to the small sample size and statistical analysis did not show a significant difference.

Despite the effectiveness of the combination of a tensioner and laser treatment for scarring, there are numerous problems in clinical practice. Skin breakdown or rash and other discomforts have been reported in 55% of patients with the use of tensioners, and this complication has been reported in other studies.²³ Eczema and skin breakdown associated with long-term use of a tension reducer may be related to the choice and quality of the material used in the tension reducer, so choosing a suitable tension reducer may also require several attempts by the patient and doctor to reduce side effects. In addition, the pain of the laser treatment, the psychological fear it causes in paediatric patients and the discomfort of going to have to wear a tensioner for long periods of time can make long-term adherence challenging.

The current study has certain limitations, firstly this study is a retrospective observational analysis and not a prospective randomised controlled trial, which inevitably leads to bias and an inadequate level of evidence. In addition because both treatment modalities require long-term patient adherence and have high requirements for patient compliance and financial situation, resulting in a small number of observers in this study, and secondly, in order to ensure the best interests of the patients, randomisation was not achieved.

Conclusions

In conclusion, sequential laser therapy combined with a tension reducer for post-operative tension incisions has a synergistic effect to further improve the texture and symptoms of post-operative tension incision scarring and is a good option to address post-tension incision scar.

Disclosure

The authors report no conflicts of interest in this work.

References

- Zhang Z, Chen J, Huang J, Wo Y, Zhang Y, Chen X. Experimental study of 5-fluorouracil encapsulated ethosomes combined with CO2 fractional laser to treat hypertrophic scar. *Nanoscale Res Lett*. 2018;13(1):26. doi:10.1186/s11671-017-2425-x
- Gold MH, Nestor MS, Berman B, Goldberg D. Assessing keloid recurrence following surgical excision and radiation. *Burns Trauma*. 2020;8:tkaa031. doi:10.1093/burnst/tkaa031
- Kuehlmann B, Stern-Buchbinder Z, Wan DC, Friedstat JS, Gurtner GC. Beneath the surface: a review of laser remodeling of hypertrophic scars and burns. *Adv Wound Care*. 2019;8(4):168–176. doi:10.1089/wound.2018.0857
- Anderson RR, Parrish JA. Selective photothermolysis: precise microsurgery by selective absorption of pulsed radiation. *Science*. 1983;220(4596):524–527. doi:10.1126/science.6836297
- Seago M, Shumaker PR, Spring LK, et al. Laser treatment of traumatic scars and contractures: 2020 international consensus recommendations. *Lasers Surg Med*. 2020;52(2):96–116. doi:10.1002/lsm.23201
- Chowdhury B, Kassir M, Salas-Alanis J, et al. Laser in surgical scar clearance: an update review. *J Cosmet Dermatol*. 2021;20(12):3808–3811. doi:10.1111/jocd.14325
- Chinese Association of Plastics and Aesthetics Scar Medicine Branch. 瘢痕早期治疗全国专家共识(2020版) [National expert consensus on early management of scars (2020 version)]. *Zhonghua Shao Shang Za Zhi*. 2021;37(2):113–125. Chinese. doi:10.3760/cma.j.cn501120-20200609-00300
- Wu X, Yang Y, Liu W, et al. Comprehensive strategy for keloid treatment: experience at Shanghai ninth people's hospital. *Chin J Plast Reconstr Surg*. 2020;2(02):88–92. doi:10.1016/S2096-6911(21)00017-0
- Xie WG, Lei F, Wang J, Xu J, Ruan JJ, Li Z. 序贯激光治疗早期增生性烧伤瘢痕的临床效果 [Clinical effects of sequential laser treatments on early stage hypertrophic burn scars]. *Zhonghua Shao Shang Za Zhi*. 2018;34(9):615–623. Chinese. doi:10.3760/cma.j.cn501120-201809011
- Huang SH, Wu KW, Lo JJ, Wu SH. Synergic effect of botulinum toxin Type A and triamcinolone alleviates scar pruritus by modulating epidermal hyperinnervation: a preliminary report. *Aesthet Surg J*. 2021;41(11):Np1721–Np1731. doi:10.1093/asj/sjab105
- Ibrahim SM, Saudi WM, Abozeid MF, Elsaie ML. Early fractional carbon dioxide laser intervention for postsurgical scars in skin of color. *Clin Cosmet Investig Dermatol*. 2019;12:29–34. doi:10.2147/CCID.S177622
- Zhao QN, Zhou YM, Sun CY. 机械张力对创伤后增生性瘢痕形成的影响研究进展 [Research advances on the effect of mechanical tension in post-traumatic hypertrophic scar formation]. *Zhonghua Shao Shang Za Zhi*. 2021;37(6):586–590. Chinese. doi:10.3760/cma.j.cn501120-20200315-00167
- Wong VW, Longaker MT, Gurtner GC. Soft tissue mechanotransduction in wound healing and fibrosis. *Semin Cell Dev Biol*. 2012;23(9):981–986. doi:10.1016/j.semcdb.2012.09.010
- Schnabl SM, Breuninger H, Iordanou E, et al. Patient satisfaction in 1827 patients following various methods of facial reconstruction based on age, defect size and site. *J Dtsch Dermatol Ges*. 2018;16(4):426–433.
- Wyss N, Graf N, Hafner J, Imhof L. Fractional CO(2) laser to improve noticeable scars after skin cancer surgery: an appraisal by the patients, laypersons, and experts. *Dermatol Ther*. 2021;34(4):e14999. doi:10.1111/dth.14999
- Ilori OS, Oladele AO, Ilori OR, Onilede DA. Efficacy of microporous tape in the prevention of abnormal post-surgical scars among a black population. *J Ayub Med Coll Abbottabad*. 2022;34(2):223–229. doi:10.55519/JAMC-02-10071
- Abbas DB, Lintel H, Griffin M, et al. Tension offloading improves cutaneous scar formation in Achilles tendon repair. *J Surg Case Rep*. 2022; 2022(3):rjac066. doi:10.1093/jscr/rjac066
- Chen Z, Jin Y, Zou Y, et al. Prolonged usage of an adhesive wound closure device in postoperative facial scar management: a split-wound randomized controlled trial. *Facial Plast Surg Aesthet Med*. 2021;23(5):389–392. doi:10.1089/fpsam.2020.0574
- Farrukh O, Goutos I. Scar symptoms: pruritus and pain. In: Téot L, Mustoe TA, Middelkoop E, Gauglitz GG, editors. *Textbook on Scar Management: State of the Art Management and Emerging Technologies*. Cham (CH): Springer Copyright 2020, The Author(s); 2020:87–101.
- Lv K, Liu H, Xu H, et al. Ablative fractional CO(2) laser surgery improving sleep quality, pain and pruritus in adult hypertrophic scar patients: a prospective cohort study. *Burns Trauma*. 2021;9:tkab023. doi:10.1093/burnst/tkab023
- Wang D, Ma N, Wang W, Chen W. Applying the Chinese Wood joinery mortise-and-tenon principle to repair widening surface scars. *J Craniofac Surg*. 2020;31(2):460–463. doi:10.1097/SCS.00000000000006012
- O'Reilly S, Crofton E, Brown J, Strong J, Ziviani J. Use of tape for the management of hypertrophic scar development: a comprehensive review. *Scars Burn Heal*. 2021;7:20595131211029206. doi:10.1177/20595131211029206
- Chen Z, Jin Y, Zou Y, et al. Scar prevention with prolonged use of tissue adhesive zipper immediately after facial surgery: a randomized controlled trial. *Aesthet Surg J*. 2022;42(5):Np265–Np272. doi:10.1093/asj/sjab407

Clinical, Cosmetic and Investigational Dermatology

Dovepress

Publish your work in this journal

Clinical, Cosmetic and Investigational Dermatology is an international, peer-reviewed, open access, online journal that focuses on the latest clinical and experimental research in all aspects of skin disease and cosmetic interventions. This journal is indexed on CAS. The manuscript management system is completely online and includes a very quick and fair peer-review system, which is all easy to use. Visit <http://www.dovepress.com/testimonials.php> to read real quotes from published authors.

Submit your manuscript here: <https://www.dovepress.com/clinical-cosmetic-and-investigational-dermatology-journal>