

Management of Delayed Eruption in Permanent Incisor Following Intrusion Injury of Primary Dentition: A Case Report

Jawza H Alfarraj¹, Faisal Alsaif², Sama A Alsaad³

¹Pediatric Dentistry Department, King Fahad Medical City, Riyadh, Saudi Arabia; ²General Dentist, Private Practice, Riyadh, Saudi Arabia; ³Pediatric Dentistry Department, King Saud Medical City, Riyadh, Saudi Arabia

Correspondence: Jawza H Alfarraj, Tel +966509948859, Email jalfarraj@kfmc.med.sa

Abstract: This article describes the clinical management of delayed eruption of the upper left permanent central incisor of an eight-year-old child with a history of overlooked intrusive trauma to the primary maxillary incisors. Initial conservative management involved simple extraction of the over-retained upper right primary left incisor. At the recall visit, the decision was made to expose permanent incisors surgically aiming to facilitate its eruption. Two years later, the upper right central and lateral incisors have been erupted into the oral cavity, improving patient aesthetics. This case report aims to demonstrate the clinical diagnosis and intervention for delayed eruption of maxillary permanent central incisor as a consequence of an overlooked intrusive trauma in the primary dentition. Additionally, to emphasize the importance of periodic radiographic examination in monitoring the sequence of eruption in mixed dentition.

Keywords: dental trauma, unerupted, delayed eruption, pediatric

Introduction

Traumatic dental injuries (TDIs) are relatively common in pediatric patients. Studies have shown that the prevalence of TDIs in primary dentition is 22.7%.¹ Luxation injuries are the most common type of dental injury in the primary dentition.² Moreover, they are the most severe type because they not only damage the traumatized tooth and its supporting tissues, but also present the potential risk of sequelae on the succeeding permanent teeth.³ Because of the close anatomic relationship with the apices of the primary incisors, permanent incisors have an increased risk of post-traumatic complications and the development of malformations.^{3,4} Dental trauma to the primary teeth disrupts the development of permanent teeth in 12–69% of the cases.³ The effect of such disruption may range from minimal enamel opacities to more severe presentations, such as arresting root development, delayed eruption, and non-eruption of the permanent tooth.^{4,5}

The recent International Association of Dental Traumatology (IADT) guidelines for management of primary teeth intrusion injuries indicates that the child should be followed up until the age of 6 for examining and monitoring.² The specific outcomes of the injury should be identified and recorded.²

This case report aims to demonstrate the clinical diagnosis and intervention for delayed eruption of maxillary permanent central incisor as a consequence of an overlooked intrusive trauma in the primary dentition. Moreover, the case report emphasizes the importance of periodic clinical and radiographic examination in monitoring the sequence of eruption in mixed dentition.

Case Description

An 8-year-old male presented to the Pediatric Dentistry Clinic, accompanied by his father, with the main concern of delayed exfoliation of the maxillary left primary central incisor (#61). The patient's medical history showed no remarkable findings. The dental history revealed that there was a history of TDI of the primary maxillary incisors when the child was two years old,

including intrusion of the upper left primary central incisor (#61). The parents did not seek any dental treatment at that time. A radiographic examination was not performed at the presentation. Informed consent was obtained from the child's father for all examinations, radiographs, and procedures. In addition, another informed consent was also obtained for taking photographs and publishing the case in a scientific journal. No institutional approval was required to publish this case report.

Clinical examination showed mixed dentition stage, poor oral hygiene, multiple carious teeth, multiple defective restorations, over-retained upper left primary central incisor (#61) with no mobility, and an upper left primary lateral incisor (#62) with grade II mobility. Maxillary right central incisor (#11) fully erupted in a good position. No buccal or palatal swellings were noticed in the region of the over-retained tooth (#61) and (#21) was not buccally palpable. The radiographic investigation, including panoramic radiography, showed that (#21) was present, but delayed in eruption, while (#61) was over-retained. A periapical radiograph showed a permanent central incisor (#21) with an open apex and partially resorbed root of the tooth (#61) (Figure 1A). A comprehensive treatment plan was established based on the child's treatment needs, including multiple extractions and restoration.

Initial management involved extraction of teeth (#61) and (#62) under local anesthesia to facilitate the eruption of teeth (#21) and (#22). The patient did not show-up for the three-month follow-up appointment. At the 6-month follow-up visit, the clinical examination revealed that (#21) and (#22) did not erupt, but a buccal bulge could be felt for (#22) but not for not (#21).

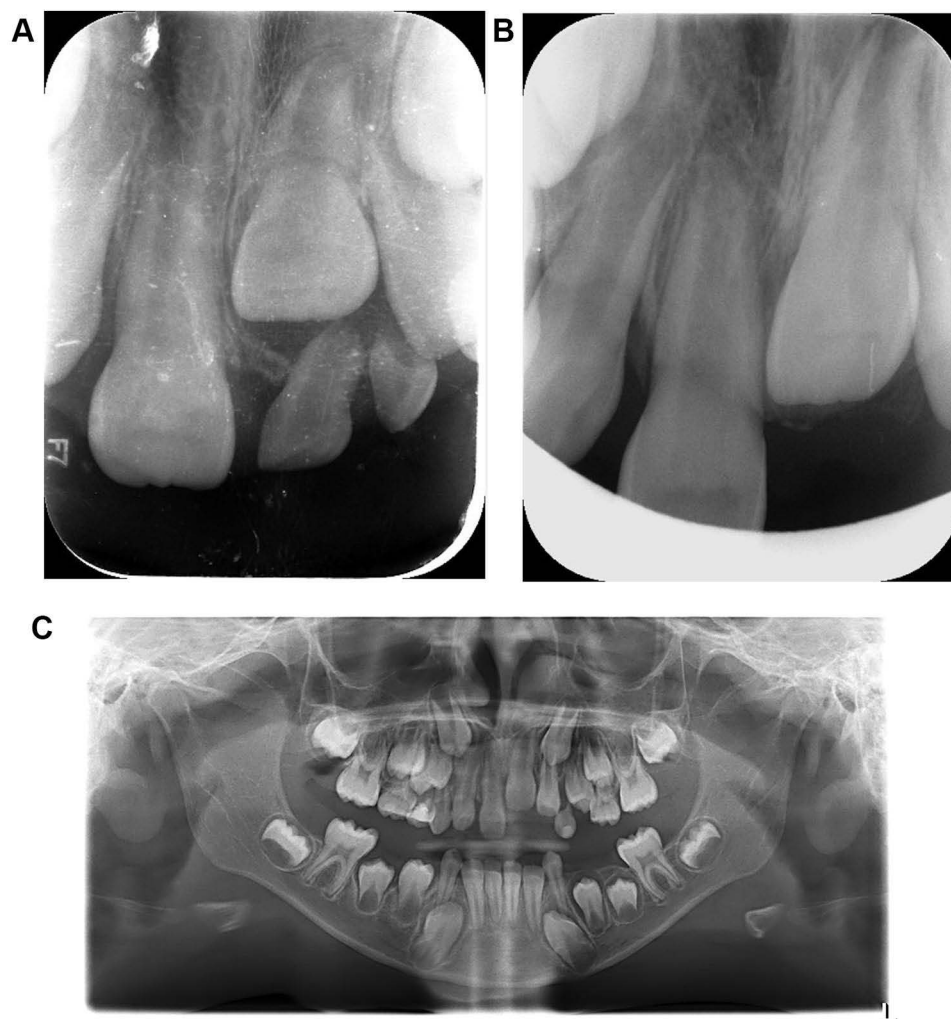


Figure 1 Radiographic Examination: (A) Periapical radiograph shows permanent central with immature roots and partially resorbed root of the primary left central incisor (#61). (B) Periapical radiograph taken at six-month recall shows permanent left central incisor (#21) with immature root. (C) Panoramic radiograph shows mixed dentition stage, localized disturbance of eruption as (#22) is more advanced than #21. Also, the permanent upper right canine (#23) is bypassing the midline of (#22).

A periapical radiograph was taken for (#21), and the root was found to be immature (**Figure 1B**). Panoramic radiographs showed a significant deviation of eruption sequence because tooth (#22) was more advanced than tooth (#21). In addition, the permanent upper left canine (#23) bypassed the midline of (#22), which was alarming for future canine impaction (**Figure 1C**).

An orthodontic consultation was Obtained. The orthodontist recommended early surgical intervention to facilitate the eruption of (#21) and (#22), as well as simple extraction of (#63) for more space to accommodate the erupting teeth.

The patient was referred to an oral and maxillofacial surgeon. Minor chair-side surgery was performed to expose the (#21) and (#22). Local anesthetic infiltration with (2% lidocaine with 1:100,000 epinephrine) in the left anterior area of the maxilla was achieved. Two parallel incisions were then performed on the ridge crest. The incisions were 3 mm apart. The strip of the fibrous keratinized gingival tissue was removed, and then the full buccal-mucoperiosteal flap of 3–4 mm was raised to expose the incisal edge of (#21) and (#22) (**Figure 2A**). Irrigation was performed, and hemostasis was achieved. Thereafter, the apical reposition flap was sutured opposite to the teeth (#21), (#22) using 3/0 Vicryl absorbable suture materials. Two interrupted sutures were also placed mesial and distal to the teeth (#21) and (#22) (**Figure 2B**). The patient tolerated the operation well. Five mL of paracetamol syrup was administered for an 8-hour interval for the initial 24 hours postoperatively.

At postoperative 1-week follow-up, clinical examination showed good healing, with one suture in place. The suture was removed, and irrigation was performed.

At postoperative 1-month follow-up, clinical examination showed that #21 had erupted palatally and that only its incisal tip was visible. Also, the tooth (#22) erupted in a good position (**Figure 2C**). The patient was followed up for future orthodontic treatment to correct the anterior crossbite. At the six-month recall visit, clinical examination showed self-correction of anterior crossbite (tooth #21). Enamel hypoplasia of the cervical part of the crown was also seen (**Figure 3A**). The periapical radiograph showed that the root was still immature which indicates a chance for more eruption (**Figure 3B**).

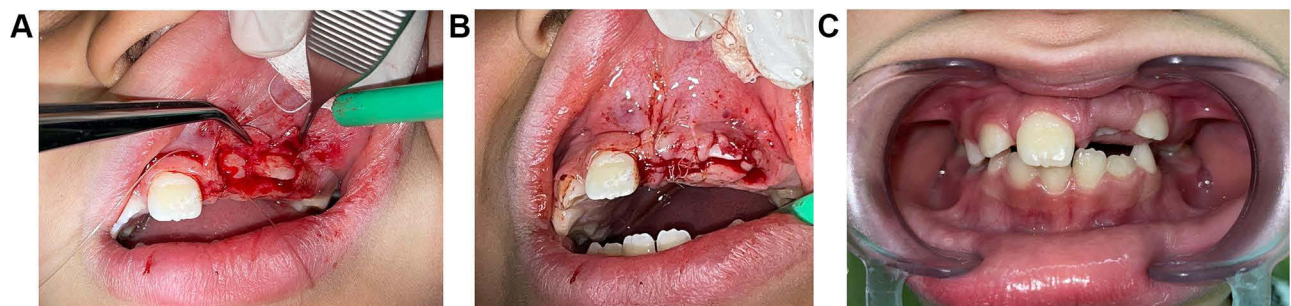

Figure 2 Clinical Photographs: (A) Intra-oral photograph shows raised the buccal flap and exposed upper permanent central and lateral incisors. (B) Intra-oral photograph shows the apical repositioned flap sutured opposite to the tooth 21, 22 using 3/0 Vicryl absorbable suture materials. (C) Intraoral photograph acquired at one-month recall shows partially erupted and lingually positioned #21 and good eruption of #22.

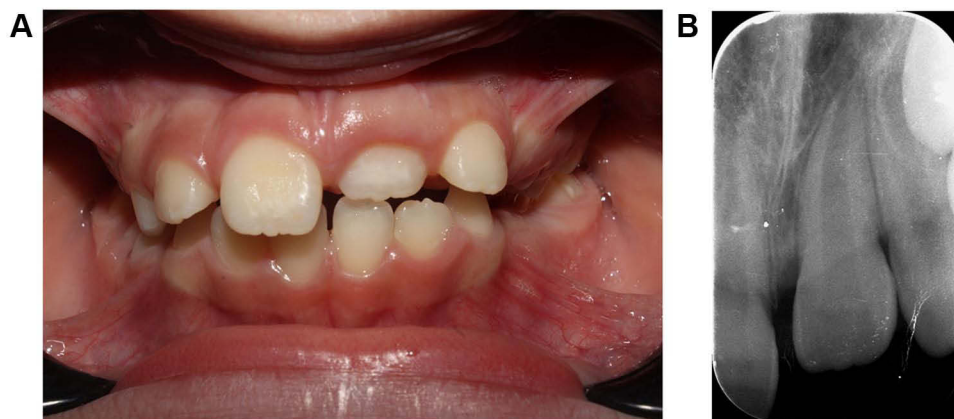


Figure 3 (A) Intraoral photograph acquired at six-month recall shows good eruption of #21, self-correction of crossbite, with enamel hypoplasia of the cervical part of the crown. (B) Intraoral radiograph acquired at six-month recall shows improved position with the roots still open.

Discussion

Impaction of maxillary permanent incisors is generally an uncommon condition.⁵ However, it should gain enough attention, seeing that the missing or unerupted maxillary incisors have a negative influence on facial esthetics, which may affect children's self-esteem and social interaction.^{6,7} Therefore, early diagnosis and interceptive treatment, as well as the need for a constant clinical and radiographic follow-up are important.⁵

A tooth is suspected to have delayed eruption clinically when the contralateral tooth has erupted for more than six months or when the sequence of eruption is disturbed.^{4,7} Radiographically, the delayed eruption can also be identified by periapical, occlusal, or panoramic radiographs, which can be helpful in other developmental anomalies or pathologies.⁴

TDIs to primary dentition most commonly caused by accidental falls, especially when children learn how to walk. They most frequently occur between 2 and 6 years of age.⁸ Furthermore, TDIs has a potential risk of damaging the succeeding permanent teeth because of the close anatomical relationship between the apices of the primary teeth and the germs of their successors.^{2,3,9} This risk can be explained by two main mechanisms: first, a direct injury to the permanent tooth germ by the apex of the primary tooth's root; second, an indirect injury caused by periapical infection of the primary tooth due to pulp necrosis.^{3,9}

One of the most common post-traumatic complications occurring in permanent teeth, is the ectopic eruption of the permanent incisors.⁸ In some cases, pulpal necrosis can displace or obstruct the eruption of a permanent tooth, as seen in the present report, since the presence of an abscess can cause bud deflection.^{4,9,10}

Delayed eruption may develop from the physical displacement of the permanent bud, the abnormal alterations in the connective tissue overlying the permanent tooth, or the formation of thick and fibrous gingiva post-traumatic healing.^{9,10} Teeth with immature roots, still have a chance for movement and hopefully eruption. However, in some cases, surgical exposure may be needed.⁵

In the present case, a conservative approach was attempted by extracting over-retained maxillary primary incisors followed by surgical exposure, was done since there was no improvement in the unerupted permanent maxillary incisors during the follow-up visits.

Surgical exposure procedure can be performed by a minimal approach, in which a small window is created by simple incision when the permanent incisor is close to the surface with a single tooth impaction; otherwise, as in our case, palatal or buccal mucosal flaps should be raised to expose the teeth.¹¹ In the case of a buccal flap, as in this case, the attached gingiva should be preserved using an apically positioned flap.^{11,12} This method is a well-known technique and is generally recommended in the periodontal management of buccally displaced teeth. Its main benefit is the better periodontal outcome compared to other techniques.¹²

The timing of intervention is critical to avoid the need for orthodontic forces to extrude impacted incisors, and also to avoid any further orthodontic complications.^{3,4} The limitation of this case report is that no Computed Tomography (CT) examination was undertaken due to financial issues.

Conclusively, following any dental trauma to primary teeth and especially intrusion injuries, parents should be educated about the possible complications on developing teeth. In all pediatric patients with a positive history of a traumatized primary tooth, pre-eruptive radiographs should be taken for early detection, and treatment of possible severe developmental disturbances is recommended.

Conclusion

TDIs to the primary dentition may cause deflection and delayed eruption of permanent dentition. It is important to monitor the position of unerupted permanent teeth following TDIs to primary teeth. The timing of surgical intervention is critical to avoid the need for future complicated orthodontic treatment.

Disclosure

All authors declare that they have no conflicts of interest.

References

1. Petti S, Glendor U, Andersson L. World traumatic dental injury prevalence and incidence, a meta-analysis-One billion living people have had traumatic dental injuries. *Dent Traumatol*. 2018;34:71–86. doi:10.1111/edt.12389
2. Levin L, Day PF, Hicks L, et al. International Association of Dental Traumatology guidelines for the management of traumatic dental injuries: general introduction. *Dent Traumatol*. 2020;36:309–313. doi:10.1111/edt.12574
3. Andreasen JO, Andreasen FM, Andersson L. *Textbook and Color Atlas of Traumatic Injuries to the Teeth*. New Jersey: Wiley-Blackwell; 2007.
4. De Amorim LFG, Estrela C, da Costa LR. Effects of traumatic dental injuries to primary teeth on permanent teeth – a clinical follow-up study. *Dent Traumatol*. 2010;28:1–5.
5. Andrade Jr. I Jr, Paschoal MA, Santos TO. Spontaneous eruption of severely impacted teeth: the report of two cases. *J Clin Exp Dent*. 2019;11(5):e491–e495. doi:10.4317/jced.55514
6. Güngör HC, Püsmen E, Uysal S. Eruption delay and sequelae in permanent incisors following intrusive luxation in primary dentition: a case report. *Dent Traumatol*. 2011;27:156–158. doi:10.1111/j.1600-9657.2011.00981.x
7. Seehra J, Yaqoob O, Patel S, et al. National clinical guidelines for the management of unerupted maxillary incisors in children. *Br Dent J*. 2018;224(10):779–785. doi:10.1038/sj.bdj.2018.361
8. Day PF, Flores MT, O'Connell AC, et al. International Association of Dental Traumatology guidelines for the management of traumatic dental injuries: 3. Injuries in the primary dentition. *Dent Traumatol*. 2020;36(4):343–359. doi:10.1111/edt.12576
9. Da Silva Assunção LR, Ferelle A, Iwakura ML, et al. Effects on permanent teeth after luxation injuries to the primary predecessors: a study in children assisted at an emergency service. *Dental Traumatol*. 2009;25:165–170. doi:10.1111/j.1600-9657.2008.00759.x
10. La Monaca G, Pranno N, Vozza I, et al. Sequelae in permanent teeth after traumatic injuries to primary dentition. *Minerva Stomatol*. 2019;68(6):332–340. doi:10.23736/S0026-4970.19.04297-3
11. Kaczor-Urbanowicz K, Zadurska M, Czochrowska E. Impacted teeth: an interdisciplinary perspective. *Adv Clin Exp Med*. 2016;25(3):575–585. doi:10.17219/acem/37451
12. Vermette ME, Kokich VG, Kennedy DB. Uncovering labially impacted teeth: apically positioned flap and closed-eruption techniques. *Angle Orthod*. 1995;65:23–32. doi:10.1043/0003-3219(1995)065<0023:ULITAP>2.0.CO;2

International Medical Case Reports Journal

Dovepress

Publish your work in this journal

The International Medical Case Reports Journal is an international, peer-reviewed open-access journal publishing original case reports from all medical specialties. Previously unpublished medical posters are also accepted relating to any area of clinical or preclinical science. Submissions should not normally exceed 2,000 words or 4 published pages including figures, diagrams and references. The manuscript management system is completely online and includes a very quick and fair peer-review system, which is all easy to use. Visit <http://www.dovepress.com/testimonials.php> to read real quotes from published authors.

Submit your manuscript here: <https://www.dovepress.com/international-medical-case-reports-journal-journal>