


# Atypical Forms of Pyoderma Gangrenosum in Inflammatory Bowel Disease: Report of Four Cases and Literature Review

Valéria Ferreira Martinelli<sup>1,2</sup>, Pedro Martinelli Barbosa<sup>3</sup>, Lucila Samara Dantas de Oliveira<sup>1</sup>,  
Luísa de Andrade Lima Vieira de Melo<sup>1</sup>, João Manoel Casa Nova<sup>1</sup>, Carlos Alexandre Antunes de Brito<sup>2,4,5</sup> 

<sup>1</sup>Department of Gastroenterology, Hospital das Clínicas, Federal University of Pernambuco, Recife, Pernambuco, Brazil; <sup>2</sup>Department of Gastroenterology, Member of Organização Brasileira de Doença de Crohn e Retocolite – GEDIB, São Paulo, Brazil; <sup>3</sup>Department of Internal Medicine, Medical Sciences Center, Pernambucana of Health College, Recife, Pernambuco, Brazil; <sup>4</sup>Department of Internal Medicine, Center of Medical Sciences of Federal University of Pernambuco, Pernambuco, Brazil; <sup>5</sup>Department of Immunology, Autoimmune Research Institute, Recife, Pernambuco, Brazil

Correspondence: Carlos Alexandre Antunes de Brito, Department of Immunology, Autoimmune Research Institute, Avenue Rui Barbosa 715, Recife, Pernambuco, 52011-040, Brazil, Tel +55 81 31480101, Email cbrtoc@gmail.com

**Background:** Cutaneous involvement is the second-most frequent extraintestinal manifestation of inflammatory bowel disease, with pyoderma gangrenosum (PG) a particularly relevant form because of its frequency, morbidity, and recurrence. The limited number of clinical trials involving PG increases the challenge to gastroenterologists in the management of this condition.

**Case Presentation:** Four cases of atypical presentations of PG are reported. A 25-year-old patient with ulcerative colitis presented an extensive chronic ulcerative lesion on her left leg that was associated with significant bleeding; the intestinal disease was in remission under the use of azathioprine. The patient was on long-term use of 60 mg corticosteroid with no improvement in the skin disease; however, initiation of cyclosporine induced remission. In the second case, a 52-year-old woman was a carrier of Crohn's disease, with a history of partial colectomy. The patient's skin condition had evolved with a cutaneous lesion localized in the perineal region, buttocks, and colostomy pouch, simulating a case of impetigo, and this had been treated with antibiotic cycles without improvement. Lesion biopsy suggested a diagnosis of PG. Consequently, the patient was started on biological therapy with infliximab, and the PG regressed. In the third case, a 38-year-old woman with a history of pancolitis presented a picture of PG with an extensive and deep ulcerative lesion in the right breast. The lesion regressed after treatment with oral corticosteroid. The final case was a 44-year-old woman with Crohn's disease suffering from Crohn's disease pancolitis. The patient's condition evolved with a mixed pattern with pustules, bullae, and ulcerative lesions in the vulva, oral cavity, gluteus, right auricular region, scalp, and left flank, and was resolved by administration of adalimumab.

**Conclusion:** PG is an important and frequent manifestation of inflammatory bowel disease, with a spectrum of clinical variants, significant morbidity, and requiring a variety of therapeutic approaches.

**Keywords:** inflammatory bowel disease, pyoderma gangrenosum, Crohn's disease, ulcerative colitis, extraintestinal manifestations

## Introduction

Ulcerative colitis and Crohn's disease are inflammatory bowel diseases (IBD) that have many causes, with a broad spectrum of clinical manifestations and complications, and the main therapeutic target is clinical control of the intestinal inflammatory activity.<sup>1,2</sup> In addition to intestinal involvement, approximately one-third of patients have extraintestinal manifestations. Cutaneous involvement is the second-most frequent manifestation after joint symptoms, with erythema nodosum and pyoderma gangrenosum (PG) being the most frequently reported cutaneous conditions.<sup>2-5</sup> The prevalence of PG ranges from 1 to 5%. PG is more frequent as a comorbidity of ulcerative colitis, among women, and among those with severe inflammatory disease. PG has greater relevance due to its clinical characteristics of recurrent skin lesions, which may occur regardless of the inflammatory activity of the intestine, and the clinical variants with varying degrees of severity, from mild to severe disease with extensive or deep lesions.<sup>6-9</sup> Consequently, PG can be difficult to control and

may require the use of different therapeutic approaches. The limited number of clinical trials involving this condition further increases the challenge to gastroenterologists in the management of PG.<sup>10–17</sup> Here, four cases of atypical PG are reported and a literature review is conducted, highlighting the aspects related to clinical approach and management of PG.

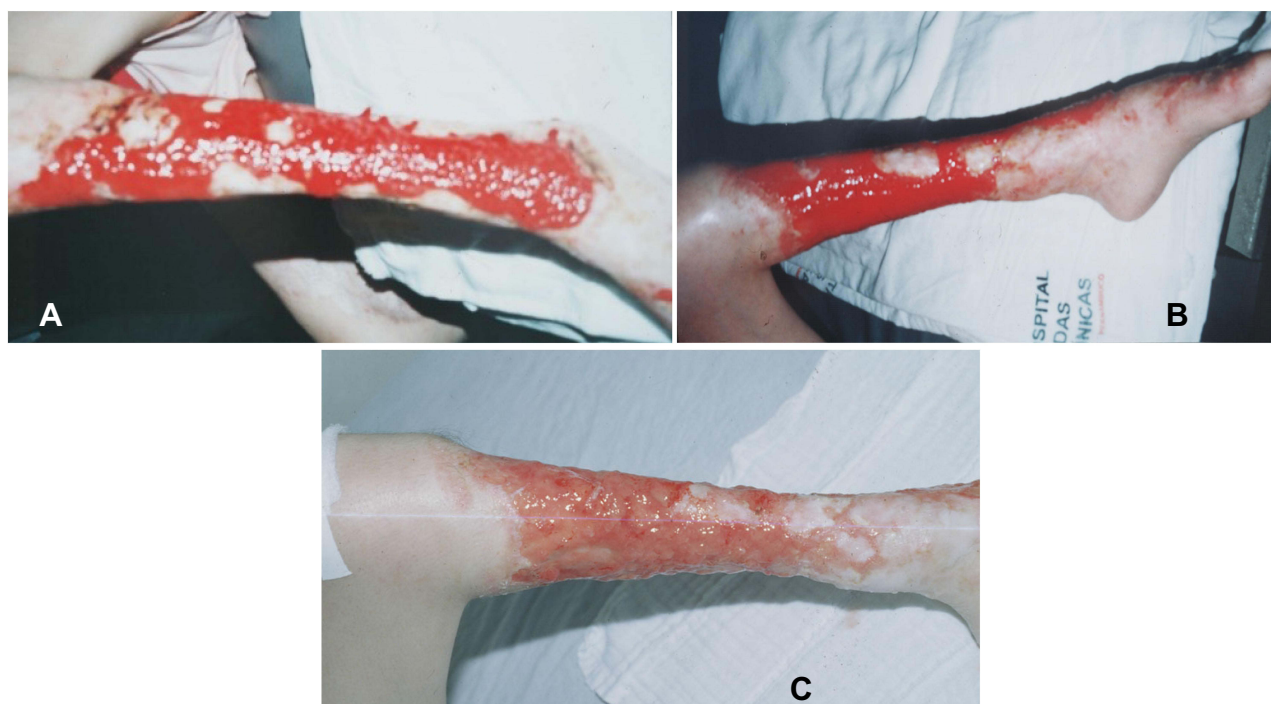
## Case Reports

### Case 1

A 25-year-old woman with ulcerative colitis attended our gastroenterology service because of an PG ulcerative extensive deep ulcerative lesion in her left leg associated with significant blood loss, in addition to some scarring areas and leg atrophy (Figure 1). The patient subsequently developed anemia and needed multiple blood transfusions. The intestinal disease was in remission at that time with the use of mesalazine 3,2g per day. The patient was treated for 1 year with 60 mg oral corticosteroid and 150 mg/day azathioprine, but this was unsuccessful and a leg deformity and active bleeding remained. Due to the severity of the condition, the patient was placed on a cyclosporine dose of 2 mg/kg/day for 14 days, followed by oral administration of the drug. Biological therapy was not available in our service at that time. The patient responded rapidly to the cyclosporine treatment, with progressive lesion healing and no bleeding. She was subsequently discharged from the hospital with continued use of oral cyclosporine.

### Case 2

The second case was a 52-year-old woman with colonic Crohn's disease who had a history of partial colectomy due to stricture complications and was ileostomized using azathioprine, resulting in her Crohn's disease being in remission. The patient had developed pustules and crusted and vesicular lesions predominantly on the buttocks, the perineal region, and around the colostomy pouch. Initially, she was diagnosed with impetigo and treated for 6 months with a topical antibiotic, potassium permanganate, and systemic antibiotics without response. Therefore, a histological study was performed and showed interstitial inflammatory infiltrate of the superficial and deep dermis, involving and



**Figure 1** A 25-year-old woman with ulcerative colitis presented with an extensive deep ulcerative lesion in the left leg associated with significant blood loss, in addition to some scarring areas and leg atrophy before treatment (A, B). After treatment, the patient presented with cessation of bleeding and remaining residual lesions (C).

permeating hair follicles and the perivascular space, with a predominance of neutrophils and some eosinophils, and accompanied by endothelial edema, vascular neoformation, and extravasation of erythrocytes. The overlying epidermis showed moderate regular acanthosis with spongiosis and leukocyte exocytosis, in addition to intra-epidermal and subcorneal microabscesses that exhibited erosion and necrosis foci. Collectively, these histological observations suggested a diagnosis of PG characterized as a variant of the disease with a predominant pustular pattern. Systemic corticosteroids were prescribed without improvement of the lesions. The patient then initiated biological anti-tumor necrosis factor (TNF) therapy—5 mg/kg at week 0, 2, and 6, then every 8 weeks—resulting in regression of the lesions.

### Case 3

A 38-year-old woman with ulcerative pancolitis treated with mesalazine (3.2 g) was hospitalized for relapse of the intestinal disease with severe activity accompanied by extraintestinal manifestations, including sacroiliitis and venous thrombosis on the leg and a picture of ulcerative PG with an extensive and deep ulcerative lesion in the right breast. The skin lesion regressed after treatment with 60 mg intravenous methylprednisone for 5 days followed by 60 mg oral prednisone, with no recurrence after weaning from the corticoid. The patient was given azathioprine and warfarin. Her intestinal disease went into remission after the immunosuppression treatment. Currently, she is taking adalimumab, 40 mg every 2 weeks, for ankylosing spondylitis. She is in complete remission without other extraintestinal manifestations.

### Case 4

A 44-year-old woman with colonic Crohn's disease with a history of PG in the classic form was in remission of intestinal disease and regression of the cutaneous lesion with the use of infliximab. She had been successfully treated with infliximab for 6 years when the medication was suspended due to adverse infusion reactions. Six months after discontinuing biological therapy, the patient developed pustule lesions on the scalp and left flank, which looked like PG. She was treated with topical neomycin and piperacillin/tazobactam, but these treatments failed. The lesions worsened, presenting a mixed pattern with pustules, bullae, and ulcerative lesions, and became more diffuse, also appearing in the vulva, oral cavity, gluteus, and right auricular region, with a combined clinical pattern with pustular, bullous and ulcerative lesions. Adalimumab was initiated as a maintenance therapy for IBD, which therapy with anti-TNF had been previously discontinued, and simultaneously the potential benefit of this drug for the treatment of PG was considered. Adalimumab was administered at 160 mg at week 0, 80 mg at week 2, then 40 mg every 2 weeks, and resulted in remission of the disease.

## Discussion and Review

PG is an ulcerative inflammatory skin disease of unknown etiology that belongs to the group of neutrophilic dermatoses. In up to 75% of cases, PG is associated with underlying systemic conditions such as hematological and joint diseases (rheumatoid arthritis, ankylosing spondylitis), collagen-vascular diseases (Takayasu's disease, Wegener's granulomatosis, systemic lupus erythematosus), neoplasms (colon, prostate, breast, bronchus, and carcinoid tumors), and IBD, the latter being the most common, co-occurring in up to 50% of patients with PG.<sup>7,9,18–20</sup> Cutaneous manifestations are the second-most common form of extraintestinal involvement in IBD, with erythema nodosum and PG being the most frequently observed cutaneous conditions. The prevalence of PG ranges from 1 to 5%. PG is more frequent as a comorbidity of ulcerative colitis, among women, and among those with severe inflammatory disease.<sup>3–5</sup> The disease activity of PG can be parallel to the activity of intestinal disease or can have an independent course.<sup>8</sup>

The pathophysiological mechanisms of the disease are similar to those described for IBD associated with dysregulation of the immune system, with an inflammatory component and abnormalities in the expression of cytokines with towards a Th1/Th17 phenotype with Th2 and T regulatory cells (Treg) downregulation. Other mechanisms involving increased expression of (IL)-1B and mutations in JAK-STAT signaling pathway receptors have been described associated with PG. These immune-mediated abnormalities justify the efficacy of drugs such as steroids, immunosuppressants, and more recently, biological therapy.<sup>18–20</sup>

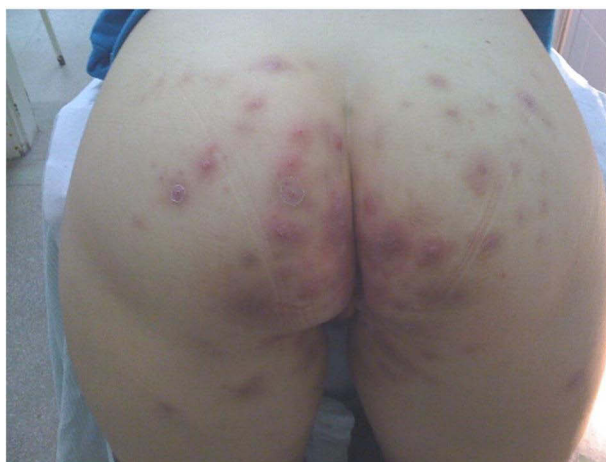Here, four cases of PG are reported, which all occurred in women, two of them in patients with ulcerative colitis and three of them occurring with inactive bowel disease, a pattern consistent with that described in the literature. Conversely, the extension and severity of the lesions make the cases atypical, requiring second- and third-line therapies to control the disease in some cases. PG is characterized by recurrent skin ulcerations with mucus-purulent or hemorrhagic exudate.<sup>7</sup> It begins as a painful nodule or a sterile hemorrhagic follicular pustule that rapidly progresses to an extremely painful ulcer of variable depth and size, with irregular and violet borders, necrotic and purulent centers, and a surrounding erythema with infiltration and edema. The ulcer may be single or multiple and may coalesce to form an irregular, multicentric ulceration. The pustule develops a purulent covering, progressing with a bad smell due to secondary infection.<sup>18</sup>

Of the four cases reported here, two patients had ulcerative forms but were atypical in their extent and severity (breast and legs), with deep lesions (Figures 1 and 2). Another patient had a pustular pattern that made diagnosis challenging because it affected different body segments, simulating skin infection related to immunosuppression (impetigo) (Figure 3). The final patient presented a mixed pattern with pustules, bullae, and ulcerative lesions (Figure 4).

There are four clinical patterns of PG. 1) Ulcerative (classic form): characterized by painful ulceration with a purulent base and an erythematous halo, located more frequently in the legs and trunk and may appear in areas of surgical procedure or trauma. 2) Pustular: rare form, with multiple sterile, discrete, self-limited pustules that usually regress leaving no scar; pustules occur on the trunk and extensor surfaces of the extremities, are often symmetrical, and often associated with fever and arthralgia; occurs more frequently in patients with IBD but also described in Behçet's disease and myelodysplastic disease. 3) Bullous: superficial blisters with development of ulcers, with necrosis and central erosion; forming principally on the dorsal surface of the hands, extensor surfaces of the arms, or the head; associated with IBD, rheumatoid arthritis, and mainly myeloproliferative diseases. 4) Vegetative: superficial erosions and ulcers, which transform into exophytic lesions with a non-purulent base, with a predilection for the trunk, head, and neck; It may arise regardless of underlying disease but has been reported in IBD and in chronic lymphocytic leukemia, polymyalgia, immunoglobulin A paraproteinemia, sarcoidosis, possible rheumatoid arthritis, and rheumatoid arthritis in association with Sjögren syndrome.<sup>6,7,9,18,19,21–23</sup> Some researchers also consider other clinical variants, such as peristomal (with the presence of lesions near the ostomy bag of IBD patients with ileostomy and colostomy), genital, and extracutaneous variants (lung, heart, central nervous system, other internal organs).<sup>18,19</sup>

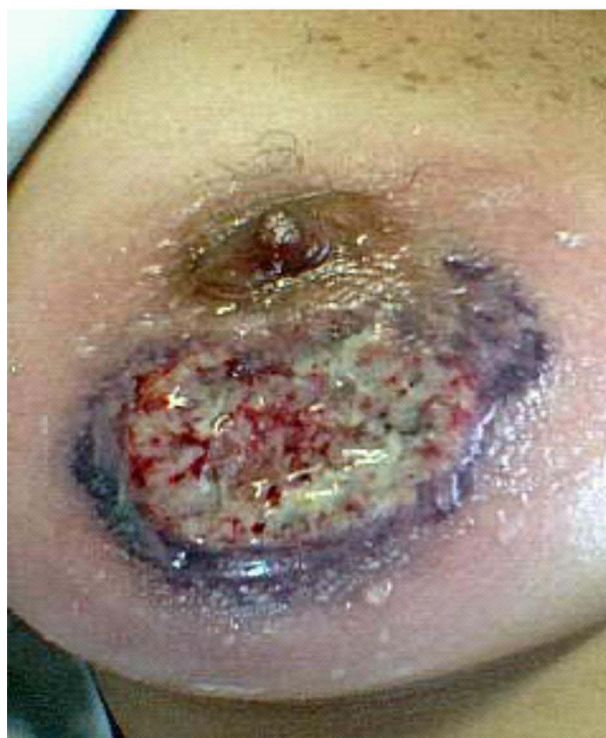Diagnosis of PG is based on clinical history and characteristics of the lesions, and the histology is somewhat auxiliary due to its non-specificity, often contributing to a differential diagnosis with other ulcerated lesions that may resemble PG. Consequently, the histology of PG may lead to diagnostic errors or may facilitate in the identification of atypical forms of PG (including drug reaction, infections, ischemic ulcers, and neoplasms).<sup>6,9</sup>

In one of the cases reported here, the atypical pattern of multiple pustular skin lesions hindered the diagnosis of PG, while the histology contributed to the diagnosis of PG. Histologically, there are no findings specific to PG. In typical

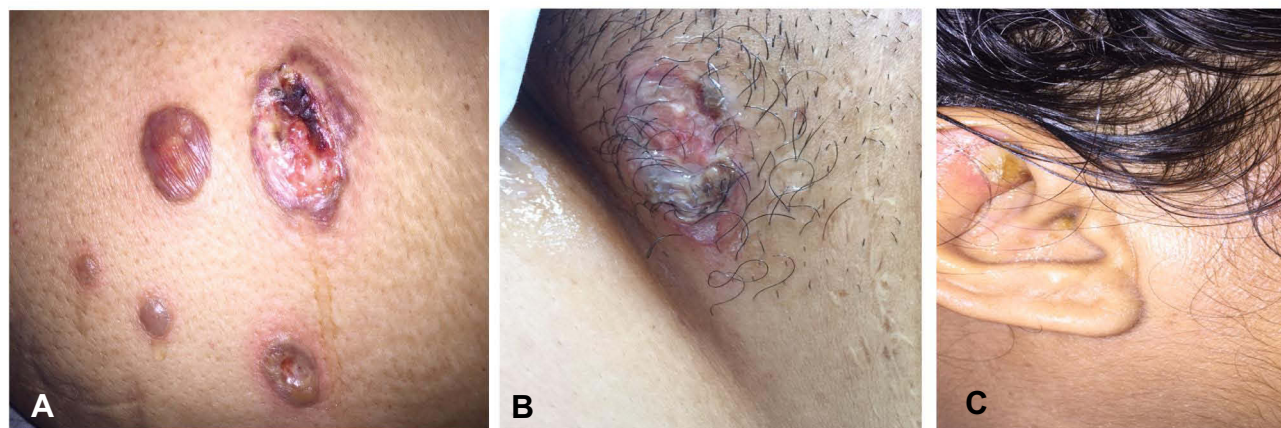


**Figure 2** A 52-year-old woman with Crohn's disease presented with pustules and crusted and vesicular lesions predominantly on the buttocks.





**Figure 3** A 38-year-old woman with ulcerative colitis presented with an extensive and deep lesion in the right breast.



**Figure 4** A 44-year-old woman with Crohn's disease presented with a mixed cutaneous pattern of pustules, bullae, and ulcerative lesions on the buttocks (A), vulva (B), and right auricular region (C).

lesions, there is a massive infiltration of neutrophils and edema in the dermis, as well as thrombosis, hemorrhage, and necrosis of the epidermis, in addition to neutrophilic pustules and formation of abscesses. Neutrophils are also visible around and within blood vessels. Leukocytoclastic vasculitis may appear on the edges of the lesions. Histopathological findings also vary according to the location of the biopsy, the evolutionary stage of the lesion, and the form of presentation.<sup>6,7,9,24</sup>

Treatment of PG involves dressings and topical and systemic medications. When PG emerges, the clinician should evaluate whether intestinal disease is active, since the control of intestinal activity can control skin disease in some cases. Introduction of therapy to induce intestinal remission may be indicated to treat the cutaneous disease.<sup>10–17</sup> Some clinical trials have evaluated treatments for PG based on case series results and service experience. The choice of

treatment is related to disease intensity. In forms with mild disease (few lesions or superficial), the use of local measurements is sufficient. For moderate and intense forms (multiple or deep lesions), systemic therapy is necessary.<sup>10–17</sup> In cases of moderate to severe disease, oral corticosteroids are the first-line therapy, and prednisone at a dose of 0.5 to 2.5 mg/kg/day or another corticosteroid with an equivalent dose is indicated. In severe disease that requires a rapid response, methylprednisolone at 1 mg/kg/day for 3–5 days followed by oral prednisone can be effective.<sup>10–12,16,17,25,26</sup> For patients with contraindications to corticosteroids or therapeutic failure, cyclosporine is an alternative that can be used at initial doses of 4–5 mg/kg orally or intravenously (IV) for induction in severe cases, followed by a dose reduction to 1.5 to 3 mg for 3–6 months. Regular serum dosages are necessary to maintain concentrations of 200 and 400 µg/L. However, cyclosporine can have side effects, including renal toxicity and hypertension, which need to be monitored.<sup>11,12,17,25,26</sup>

One of the patients reported here had severe disease, with extensive lesions in the legs that were refractory to corticosteroids and azathioprine. However, she exhibited a rapid response to cyclosporine, with cessation of bleeding after 7 days of treatment. In a series of 11 patients with PG, all received cyclosporine IV for 11 days on average, followed by oral administration of the drug. All patients subsequently exhibited pyoderma healing, with a mean response time of 4.5 days and a mean time to lesion closure of 1.4 months.<sup>27</sup> A randomized study involving 108 patients compared prednisone and cyclosporine as treatments for PG. Both drugs showed a similar healing rate of 50% after 6 months, although the risk of infection was more frequent in the prednisone group.<sup>12</sup>

Immunosuppressant drugs such as mycophenolate mofetil, methotrexate, and azathioprine are effective treatments for PG, but their slower onset of action means they are used as a second-line therapy after treatment failure with corticosteroids or are employed as corticosteroid-sparing drugs.<sup>17,25,28</sup> Two of the patients in this case series took anti-TNF drugs to control skin lesions after corticosteroid failure and also took immunosuppressants, which were used as third-line drugs.

New therapies with monoclonal antibodies have been used for the treatment of pyoderma in patients for whom corticosteroids and immunosuppressants failed or in cases of extensive and deep forms of the disease that did not respond to corticosteroids and cyclosporins and required a faster and more sustained response. Among such biologicals, inhibitors of TNF- $\alpha$ , especially infliximab, have been used most frequently. In a recent systematic review analyzing 354 patients using anti-TNF- $\alpha$  agents, the clinical response was 87%, and the complete response rate was 67%.<sup>29–31</sup> In a Swiss cohort of 366 patients with extraintestinal manifestations in 43% of cases, the onset of infliximab was indicated to treat extraintestinal manifestations rather than IBD, especially in axial spondyloarthritis and PG, reinforcing the relevance of these manifestations.<sup>29</sup> The review found that most patients were prescribed infliximab and adalimumab, and a few were prescribed etanercept and certolizumab, with similar responses seen between the different biologicals.<sup>31</sup> Although vedolizumab—an anti-integrin used exclusively in IBD—is not effective in treating extraintestinal cutaneous manifestations to date, it may be beneficial in the emergence of new episodes of PG and may be partly related to better control of intestinal disease.<sup>32</sup> Ustekinumab, an inhibitor of IL-12/IL-23, is a promising therapy.<sup>33,34</sup> In a systematic review by Giullo et al, ustekinumab could control skin manifestations; however, the small number of cases of PG included in the review necessitates further studies to evaluate the effectiveness of the drug.<sup>34</sup> Other cytokine-blocking pathways, including IL-17 antagonists (ixekizumab and brodalumab), inhibitors of phosphodiesterases (apremilast), and IL-1B blockers (such as canakinumab and gevokizumab), have been proposed as potential drugs for the treatment of PG.<sup>35–37</sup> Combination therapy involving more than one drug is necessary in cases refractory to monotherapy, and often includes the association of corticosteroids with biological therapy or immunosuppressants.<sup>11,17,25</sup>

The four patients reported here were treated at a gastroenterology service, referenced in IBD, and the therapeutic approach used follows systematized protocols according to the severity of the disease based on existing evidence from the literature and experience from our service. Extra-intestinal manifestations are frequent, including cutaneous manifestations, reinforcing the need for a multidisciplinary team (gastroenterologist, dermatologists, pathologists, etc.) capable of early identifying these manifestations and introducing the appropriate therapeutic approach.

## Conclusion

Four patients with severe and difficult-to-control PG who subsequently responded to corticoid, cyclosporine, and biological therapies are presented. The case reports and literature review reinforce the relevance of this extraintestinal manifestation of

IBD due to its frequency, morbidity, and requirement to use different therapies in many cases. Consequently, the systematization of protocols for adequate control of the disease is justified and recommended.

## Abbreviations

PG, pyoderma gangrenosum; IBD, inflammatory bowel diseases; TNF, tumor necrosis factor.

## Data Sharing Statement

All data generated or analyzed during this study are included in the published article.

## Ethics Approval

This article is a retrospective study and does not contain any studies performed with human subjects. The study was approved by the Research Ethics Committee of the Center of Medical Sciences, Federal University of Pernambuco (CAAE-Certificate of Presentation of Ethical Appreciation: 11844919.0.0000.8807).

## Consent for Publication

Written informed consent was obtained from the patients for publication of these case reports and any accompanying images.

## Acknowledgments

We thank the Autoimmune Research Institute for their support in the development of this report.

## Funding

There is no funding to report.

## Disclosure

The authors declare no conflicts of interest in relation to this work.

## References

1. Gomollón F, Dignass A, Annese V, et al. 3rd European evidence-based consensus on the diagnosis and management of Crohn's disease 2016: part 1: diagnosis and medical management. *J Crohn's Colitis*. 2017;11(1):3–25. doi:10.1093/ecco-jcc/jjw169
2. Magro F, Gionchetti P, Eliakim R, et al. Third European evidence-based consensus on diagnosis and management of ulcerative colitis. Part 1: definitions, diagnosis, extra-intestinal manifestations, pregnancy, cancer surveillance, surgery, and ileo-anal pouch disorders. *J Crohn's Colitis*. 2017;11(6):649–670. doi:10.1093/ecco-jcc/jjx008
3. Isene R, Bernklev T, Hoie O, et al. Extraintestinal manifestations in Crohn's disease and ulcerative colitis: results from a prospective, population-based European inception cohort. *Scand J Gastroenterol*. 2014;50(3):300–305. doi:10.3109/00365521.2014.99175
4. Yang BR, Choi NK, Kim MS, et al. Prevalence of extraintestinal manifestations in Korean inflammatory bowel disease patients. *PLoS One*. 2018;13(7):e0200363. doi:10.1371/journal.pone.0200363
5. States V, O'Brien S, Rai JP, et al. Pyoderma Gangrenosum in Inflammatory Bowel Disease: a Systematic Review and Meta-Analysis. *Dig Dis Sci*. 2020;65(9):2675–2685. doi:10.1007/s10620-019-05999-4
6. Conrad C, Trüeb RM. Pyoderma gangrenosum. *JDDG - J Ger Soc Dermatology*. 2005;3(5):334–342. doi:10.1111/j.1610-0387.2005.05022.x
7. Wollina U. Pyoderma gangrenosum - A review. *Orphanet J Rare Dis*. 2007;2:19. doi:10.1186/1750-1172-2-19
8. Greuter T, Navarini A, Vavricka SR. Skin Manifestations of Inflammatory Bowel Disease. *Clin Rev Allergy Immunol*. 2017;53(3):413–427. doi:10.1007/s12016-017-8617-4
9. George C, Deroide F, Rustin M. Pyoderma gangrenosum - a guide to diagnosis and management. *Clin Med J R Coll Physicians London*. 2019;19(3):224–228. doi:10.7861/clinmedicine.19-3-224
10. Aseni P, Di Sandro S, Mihaylov P, Lamperti L, De Carlis LG. Atypical presentation of pyoderma gangrenosum complicating ulcerative colitis: rapid disappearance with methylprednisolone. *World J Gastroenterol*. 2008;14(35):5471–5473. doi:10.3748/wjg.14.5471
11. Cozzani E, Gasparini G, Parodi A. Pyoderma gangrenosum: a systematic review. *G Ital di Dermatologia e Venereol*. 2014;149(5):587–600.
12. Ormerod AD, Thomas KS, Craig FE, et al. Comparison of the two most commonly used treatments for pyoderma gangrenosum: results of the STOP GAP randomised controlled trial. *BMJ*. 2015;350:h2958. doi:10.1136/bmj.h2958
13. Thomas K, Ormerod AD, Craig FE, et al. Clinical outcomes and response of patients applying topical therapy for pyoderma gangrenosum: a prospective cohort study. *J Am Acad Dermatol*. 2016;75(5):940–949. doi:10.1016/j.jaad.2016.06.016
14. Baltazar D, Haag C, Gupta AS, Marzano AV, Ortega Loayza AG. A comprehensive review of local pharmacologic therapy for pyoderma gangrenosum. *Wounds*. 2019;31(6):151–157.

15. Agarwal A, Andrews JM. Systematic review: IBD-associated pyoderma gangrenosum in the biologic era, the response to therapy. *Aliment Pharmacol Ther.* 2013;38(6):563–572. doi:10.1111/apt.12431
16. Herberger K, Dissemond J, Hohaus K, Schaller J, Anastasiadou Z, Augustin M. Treatment of pyoderma gangrenosum: retrospective multicentre analysis of 121 patients. *Br J Dermatol.* 2016;175(5):1070–1072. doi:10.1111/bjd.14619
17. Rodríguez-Zúñiga MJM, Heath MS, Gontijo JRV, Ortega-Loayza AG. Pyoderma gangrenosum: a review with special emphasis on Latin America literature. *An Bras Dermatol.* 2019;94(6):729–743. doi:10.1016/j.abd.2019.06.001
18. Ruocco E, Sangiuliano S, Gravina AG, Miranda A, Nicoletti G. Pyoderma gangrenosum: an updated review. *J Eur Acad Dermatology Venereol.* 2009;23(9):1008–1017. doi:10.1111/j.1468-3083.2009.03199.x
19. Marzano AV, Borghi A, Stadnicki A, Crosti C, Cugno M. Cutaneous manifestations in patients with inflammatory bowel diseases: pathophysiology, clinical features, and therapy. *Inflamm Bowel Dis.* 2014;20(1):213–227. doi:10.1097/01.MIB.0000436959.62286.f9
20. Alavi A, French LE, Davis MD, Brassard A, Kirsner RS. Pyoderma Gangrenosum: an Update on Pathophysiology, Diagnosis and Treatment. *Am J Clin Dermatol.* 2017;18(3):355–372. doi:10.1007/s40257-017-0251-7
21. Chia MW, Teo L, Tay YK, Poh WT. Pustular pyoderma gangrenosum: an uncommon variant which is easily misdiagnosed. *Dermatol Online J.* 2008;14(2):21.
22. Jin Y, Qu C, Shi T, Wang C, Yu H, Zhang F. A case of vegetative pyoderma gangrenosum. *Dermatologica Sin.* 2015;33(3):170–172. doi:10.1016/j.dsi.2014.12.009
23. Suvirya S, Pathania S, Singhai A. A case of bullous pyoderma gangrenosum. *BMJ Case Rep.* 2019;12(3):e228772. doi:10.1136/bcr-2018-228772
24. Lear JT. Neutrophilic dermatoses: pyoderma gangrenosum and Sweet's syndrome. *Postgrad Med J.* 1997;73(856):65–68. doi:10.1136/pgmj.73.856.65
25. Quist SR, Kraas L. Treatment options for pyoderma gangrenosum. *JDDG - J Ger Soc Dermatology.* 2017;15(1):34–40. doi:10.1111/ddg.13173
26. Ehrl DC, Heidekrueger PI, Broer PN. Pyoderma gangrenosum after breast surgery: a systematic review. *J Plast Reconstr Aesthetic Surg.* 2018;71(7):1023–1032. doi:10.1016/j.bjps.2018.03.013
27. Puchner TC, Kugathasan S, Kelly KJ, Binion DG. Intravenous cyclosporine in refractory pyoderma gangrenosum complicating inflammatory bowel disease. *Inflamm Bowel Dis.* 2001;7(1):1–7. doi:10.1097/00054725-200102000-00001
28. Hrin ML, Bashyam AM, Huang WW, Feldman SR. Mycophenolate mofetil as adjunctive therapy to corticosteroids for the treatment of pyoderma gangrenosum: a case series and literature review. *Int J Dermatol.* 2021;60(12):e486–e492. doi:10.1111/ijd.15539
29. Vavricka SR, Gubler M, Gantenbein C, et al. Anti-TNF Treatment for Extraintestinal Manifestations of Inflammatory Bowel Disease in the Swiss IBD Cohort Study. *Inflamm Bowel Dis.* 2017;23(7):1174–1181. doi:10.1097/MIB.0000000000001109
30. Partridge ACR, Bai JW, Rosen CF, Walsh SR, Gulliver WP, Fleming P. Effectiveness of systemic treatments for pyoderma gangrenosum: a systematic review of observational studies and clinical trials. *Br J Dermatol.* 2018;179(2):290–295. doi:10.1111/bjd.16485
31. Ben Abdallah H, Fogh K, Bech R. Pyoderma gangrenosum and tumour necrosis factor alpha inhibitors: a semi-systematic review. *Int Wound J.* 2019;16(2):511–521. doi:10.1111/iwj.13067
32. Chateau T, Bonovas S, Le Berre C, Mathieu N, Danese S, Peyrin-Biroulet L. Vedolizumab Treatment in Extra-Intestinal Manifestations in Inflammatory Bowel Disease: a Systematic Review. *J Crohn's Colitis.* 2019;13(12):1569–1577. doi:10.1093/ecco-jcc/jjz095
33. Guenova E, Teske A, Fehrenbacher B, et al. Interleukin 23 expression in pyoderma gangrenosum and targeted therapy with ustekinumab. *Arch Dermatol.* 2011;147(10):1203–1205. doi:10.1001/archdermatol.2011.168
34. Guillo L, D'Amico F, Danese S, Peyrin-Biroulet L. Ustekinumab for Extra-intestinal Manifestations of Inflammatory Bowel Disease: a Systematic Literature Review. *J Crohn's Colitis.* 2020;15(7):1236–1243. doi:10.1093/ecco-jcc/jjaa260
35. Kolios AGA, Maul JT, Meier B, et al. Canakinumab in adults with steroid-refractory pyoderma gangrenosum. *Br J Dermatol.* 2015;173(5):1216–1223. doi:10.1111/bjd.14037
36. Galimberti RL, Vacas AS, Bollea Garlatti ML, Torre AC. The role of interleukin-1 $\beta$  in pyoderma gangrenosum. *JAAD Case Reports.* 2016;2(5):366–368. doi:10.1016/j.jcdr.2016.07.007
37. Laird ME, Tong LX, Lo Siccio KI, Kim RH, Meehan SA, Franks AG. Novel use of apremilast for adjunctive treatment of recalcitrant pyoderma gangrenosum. *JAAD Case Reports.* 2017;3(3):228–229. doi:10.1016/j.jcdr.2017.02.019

## International Medical Case Reports Journal

Dovepress

## Publish your work in this journal

The International Medical Case Reports Journal is an international, peer-reviewed open-access journal publishing original case reports from all medical specialties. Previously unpublished medical posters are also accepted relating to any area of clinical or preclinical science. Submissions should not normally exceed 2,000 words or 4 published pages including figures, diagrams and references. The manuscript management system is completely online and includes a very quick and fair peer-review system, which is all easy to use. Visit <http://www.dovepress.com/testimonials.php> to read real quotes from published authors.

Submit your manuscript here: <https://www.dovepress.com/international-medical-case-reports-journal-journal>