

Influence of Clinically Active Graves' Ophthalmopathy on Spherical Equivalent and Visual Acuity

Jasenka Petrovic Jurcevic¹, Marko Jurcevic², Mateja Jagic³, Anamarija Jazbec⁴, Kresimir Mandic⁵, Jelena Juri Mandic⁵

¹Medical School University of Zagreb, PhD Candidate on the Programme "Biomedicine and Health", Zagreb, Croatia; ²University of Zagreb Faculty of Electrical Engineering and Computing, Department of Electrical Engineering Fundamentals and Measurements, Zagreb, Croatia; ³Special Hospital „Svjetlost“, Department of Refractive Surgery, Zagreb, Croatia; ⁴University of Zagreb Faculty of Forestry and Wood Technology, Department for Forest Inventory and Management, Zagreb, HR-10000, Croatia; ⁵Clinical Department of Ophthalmology, University Hospital Center Zagreb, Zagreb, Croatia

Correspondence: Jasenka Petrovic Jurcevic, Medical School University of Zagreb, Šalata 4a, Zagreb, Croatia, Email jpetrovic@mef.hr

Purpose: Clinical experience regarding the fluctuations of the refractive error of the eye during the different stages of Graves' ophthalmopathy observed through outpatient clinic frequent check-ups points towards an underestimated and often overlooked problem. Published data about it are sparse. The clinical manifestations of Graves' ophthalmopathy can be understood from the perspective of "compartment syndrome" and literature implies how such changes can affect the refractive error and consequently, the visual acuity. The purpose of the study was to explore how the clinical activity score of Graves' ophthalmopathy affects refractive error and visual acuity.

Patients and Methods: The study was prospective and observational, including 60 eyes of 30 patients with clinically active Graves' ophthalmopathy. All the patients were monitored and evaluated over a period of 36 months by the clinical activity score, spherical equivalent and visual acuity. All the observed parameters were statistically analyzed.

Results: The mean values of spherical equivalent and visual acuity throughout the observed period showed continuous fluctuation. Repeated measure analysis of variance showed statistically significant differences in visual acuity and spherical equivalent over the observed period. There was a statistically significant positive correlation between visual acuity and clinical activity score. The correlation between spherical equivalent and clinical activity score was also positive but not statistically significant.

Conclusion: A decrease in the clinical activity score is either the result of a spontaneously resolving course of Graves' ophthalmopathy or a consequence of treatment, so lowering in fluctuation of refractive error and improved visual acuity may be associated with a reduction in orbital inflammation.

Keywords: Graves' ophthalmopathy, clinical activity score, refractive error, spherical equivalent, visual acuity

Introduction

Graves' ophthalmopathy (GO) is an extrathyroidal manifestation of a systemic autoimmune disease affecting extraocular muscles, the fat tissue of the orbit, lacrimal gland, cornea, tear film, and optic nerve.^{1,2} Signs and symptoms usually peak approximately 6–24 months after the onset of GO and have a significant impact on visual function, including changes in visual acuity (VA), as well as changes in refractive error of the eye.³

Literature on refractive error changes in GO is scarce. Chandrasekaran et al report myopic shift as a result of necessary orbital decompression due to a progressive form of GO.⁴ As thyroid hormone receptors have been found to be present in all tissues and organs of the body except the brain, spleen, and testes, it is quite plausible to conclude that ciliary smooth muscle tonicity also depends on thyroid activity. This could be the reason why hyperthyroidism can cause refractive changes in the direction of myopic shift due to ciliary muscle spasm.⁵

In the research of Jankauskiene et al, a significant decrease in visual acuity was observed in both adolescents and adults with Graves' disease. The authors concluded that refractive error changes in GO could be the result of immune complexes accumulating on the lateral walls of the orbit due to the increased volume of extraocular muscles. Therefore, under mechanical pressure, the eyeball is remodeled by the growth of its longitudinal axis, resulting in a myopic shift.^{6,7}

Two case reports on Graves' ophthalmopathy involved two women, 42 and 58 years of age, respectively. In both cases, an acute significant change in refractive error was noticed, manifested as a progression of existing myopia. The author suggests edema and infiltration of the ciliary body with lymphocytes and plasma cells as the pathological-anatomical substrate responsible for the etiology of the disease.⁸

There are few papers that report changes in refractive error other than myopia. Normal corneal curvature is characterized by physiological with-the-rule astigmatism.⁹ The eyelids normally adhere to the surface of the cornea and thus exert a certain pressure on it.¹⁰ Wilson et al measured corneal astigmatism and found that astigmatism changed according to the pressure of the eyelids on the cornea.¹¹ Basically, three kinds of pathological processes can produce abnormal corneal astigmatism. These include corneal epithelial abnormalities, changes in stromal thickness, and external mass compression in the orbital space.¹²⁻¹⁴

Mombearts et al described corneal astigmatism in patients with GO younger than 55 years and compared the results with a control group of healthy individuals adjusted for gender and age. The eyes of patients with inactive GO showed a statistically significantly higher central corneal with-the-rule astigmatism compared to the eyes of healthy controls. The conclusion was that GO may be associated with greater corneal with-the-rule astigmatism, which is not due to orbital surgery, strabismus, or eyelid surgery.¹⁵

The eyelids put pressure on the cornea with their tension and position.¹⁶

Correspondingly, experiments with lifting the eyelids from the surface of the cornea show a shift of corneal astigmatism in the direction of with-the-rule astigmatism.¹⁷

Another probable mechanism for the development of corneal astigmatism may be the forces that result from tension in the extraocular muscles and are transmitted to the cornea through the sclera. In a study involving corneal topography analysis in five patients with Graves' ophthalmopathy, Kwitko et al found an elongation of the upper rectus and increased curvature of the lower part of the peripheral cornea a month after the recession of the lower rectus muscle.¹⁸

Some studies explain the occurrence of hyperopia as a consequence of "compartment syndrome" in diseases affecting the orbital apex.^{19,20}

However, in the reviewed literature we did not find any study that examined the pattern of how the clinical activity score (CAS) fluctuation affects changes in the eye's refractive error and VA, respectively.

Through GO outpatient clinics, we observed several things that were rationale for the study. Namely, patients with clinically active disease are more likely to seek help regarding visual disturbances during frequent check-ups than patients with non-clinically active disease. Patients with clinically active disease are more likely to complain about changed visual acuity even though they have neither keratopathy nor neurooptopathy. A significant number of patients after seeing an optometrist complaint about prescribed glasses during clinically active stage of disease.

Therefore, we considered that there might be a correlation between CAS and refractive error, as well as CAS and VA.

Materials and Methods

The study was conducted as prospective and observational, comprising overall 30 patients with clinically active GO. Twenty were females (66.67%) and 10 were males (33.33%), with 60 eyes analyzed. All the patients were monitored and evaluated over a period of 36 months at intervals of 3 months throughout the first year of observation, and at intervals of 6 months throughout the second and third years of observation, amounting to a total of 7 intervals.

Three of the patients were affected unilaterally, six of the eyes were not clinically active, respectively.

The study was performed at Referral Center for Orbital and Adnexal Surgery at University Hospital Center Zagreb according to all the ethical standards and was approved by Ethics Committee of Clinical University Hospital Zagreb. All the patients included in the study signed the informed consent and were treated according to The 2021 European Group on Graves' orbitopathy (EUGOGO) clinical practice guidelines for the medical management of Graves' orbitopathy.²¹

An inclusion criterion was clinically active disease on the beginning of the study.

Duration of GO was between 6 and 18 months.

Exclusion criteria were ophthalmic comorbidities that are not a consequence of the underlying disease; previous surgical procedures on the eye, eyelids, extraocular muscles, or orbit; amblyopia; refractive error greater than 6 diopters of myopia or hyperopia; keratoconus and keratoglobus.

Twenty-four patients finished the follow-up period completely. Six patients (20%) participated the follow-up visits partially due to personal reasons. Patients were evaluated by the CAS index, the objective measurement of the refractive error of a patient's eyes was expressed by spherical equivalent (SE), and VA was expressed by the logarithm of the minimum angle of resolution (logMAR).

The clinical activity score is a binary variable (yes/no), and by its definition, GO is active if CAS is $\geq 3/7$.

Activity was assessed according to the following signs and symptoms:

1. spontaneous retrobulbar pain,
2. pain on attempted upward or downward gaze,
3. redness of the eyelids,
4. redness of the conjunctiva,
5. swelling of the caruncle or plica,
6. swelling of the eyelids, and
7. swelling of the conjunctiva (chemosis).

A 10-item CAS, including an increase in exophthalmos ≥ 2 mm, a decrease in eye movements in any direction of gaze $\geq 8^\circ$, and a decrease in visual acuity ≥ 1 line on the Snellen chart during a period of 1–3 months were to evaluate recent progression and, consequently, the activity of GO.²¹

To reduce the possible bias to minimum during follow-up period, we performed the objective measurement of the refractive error on the same device by the same investigator and only after thorough evaluation of anterior eye segment condition (enabling exclusion of patients, eg with newly developed anterior eye segment comorbidity not related to GO).

None of the patients developed neuroopticopathy or keratopathy as a result of severe GO.

Descriptive statistics by months of observation were produced for all analyzed variables. In all statistical analyses, a significance level of 5% was considered statistically significant. The correlation among the observed VA, SE, and CAS variables over the months was tested by the Spearman rank correlation. The differences in VA and SE over months (autocorrelation of data) were tested using repeated measure analysis of variance (RM ANOVA). If the homogeneity of covariance matrices was not met, the “p” value was adjusted using a Greenhouse–Geisser epsilon. To test the differences in CAS during the analyzed months, the Friedman test was used.

Statistical analyses were performed using the statistical package SAS9.4. PROC GLM was used for RM ANOVA (<https://v8doc.sas.com/sashtml/stat/chap30/sect41.htm>).

Results

Descriptive statistics for age, VA in logMAR, and refractive error in SE by the observed intervals were performed. Twenty eyes of 10 male (55.5 ± 7.18) and 40 eyes of 20 female patients (54.65 ± 9.84), with a mean age of 54.933 years and a standard deviation of 8.986, were involved. There was no statistically significant difference in age by gender ($t = -0.342$; $p = 0.733$). The youngest patient was 39 and the oldest was 75 years of age.

VA expressed by logMAR was fluctuating from 0.1555 with a standard deviation of 0.1445, to 0.0740 with a standard deviation of 0.0725 throughout the observed period.

The distribution of refractive error expressed by SE was fluctuating from 0.4250 with a standard deviation of 1.6964, to 0.3771 with a standard deviation of 1.5512 throughout the observed period. The minimum SE was -3.0000 and the maximum was $+4.2500$.

The distribution of refractive error and VA throughout the observed period was shown in Figures 1 and 2, respectively. The results of observed VA (Figure 2) imply its recovery over the 36-month period. The distribution of CAS showed 27 eyes with score 1 and 1 eye with score 7 (Figure 3). From Figure 3 it is evident how at the beginning of

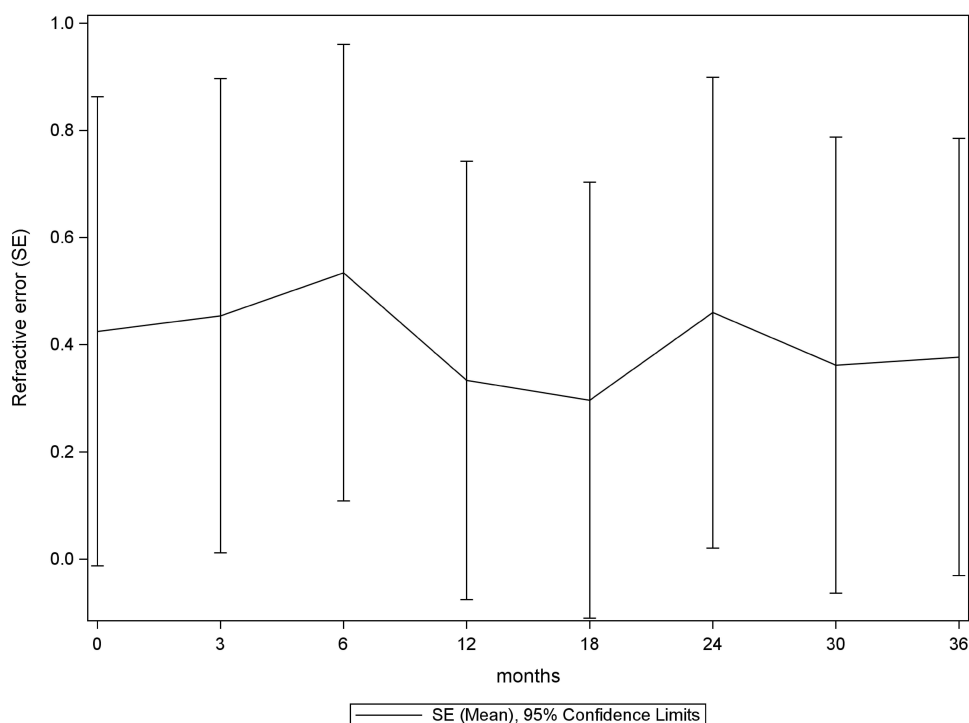


Figure 1 Distribution of refractive error throughout the observed period.

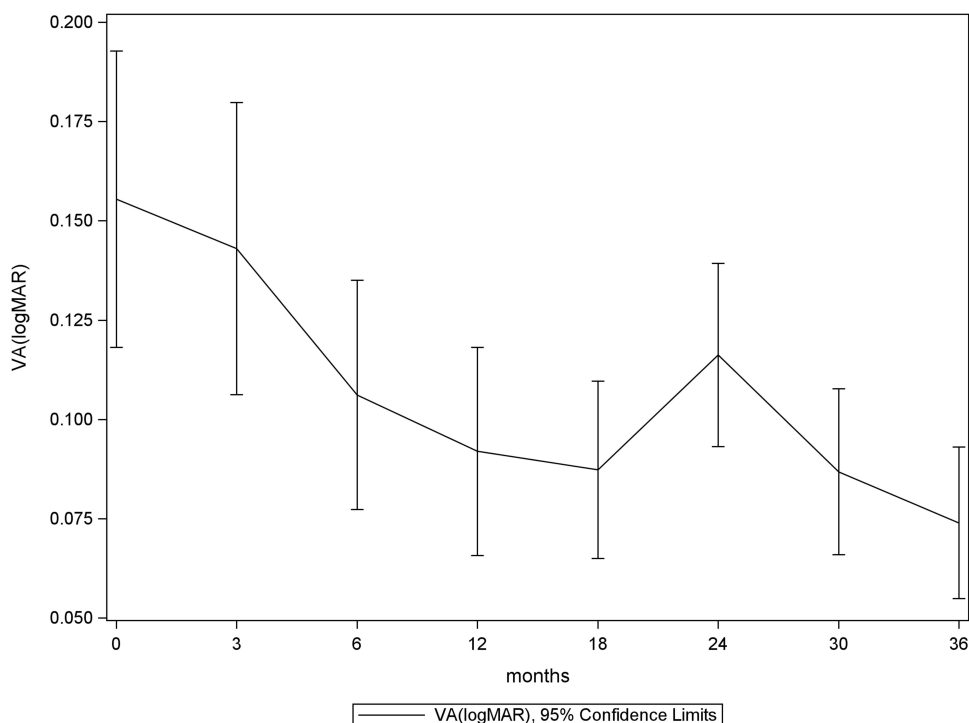


Figure 2 Distribution of VA throughout the observed period.

the observed period a number of eyes had a higher score (CAS) which decreased over time. [Figure 3](#) also shows that the number of eyes with a lower score increased over time. The decrease of CAS was a result of either the spontaneous resolution of GO or its efficient treatment.

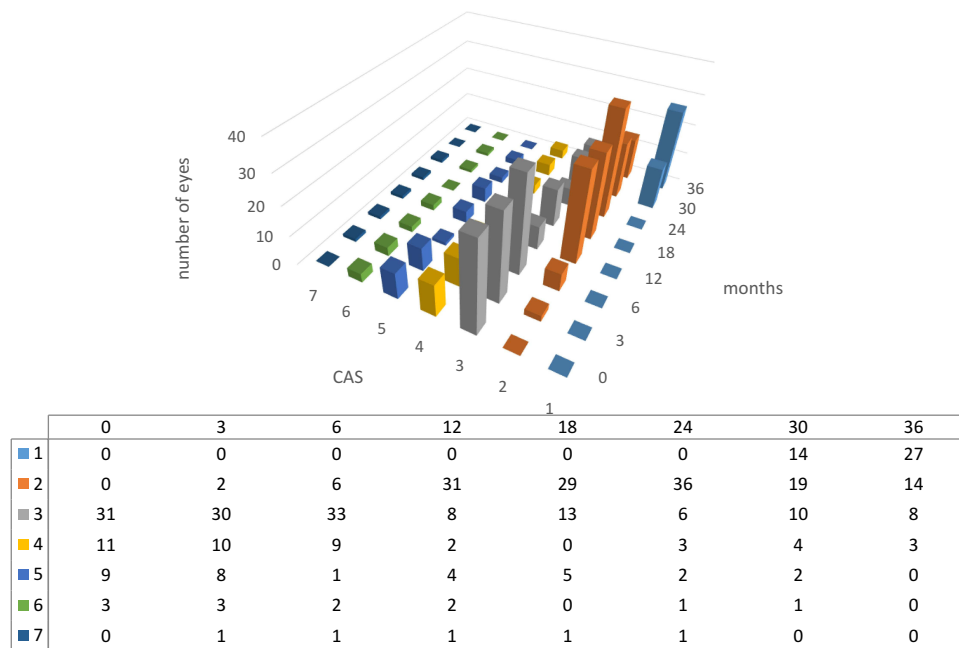


Figure 3 Distribution of CAS throughout the observed period.

The results of RM ANOVA showed statistically significant differences in VA ($p < 0.001$) and SE ($p < 0.001$) over the observed period of time.

There is a statistically significant positive correlation between VA and CAS for all the observed months (Figure 4). The Spearman rank correlation in the observed period ranges from 0.456 (36 months) to 0.764 at the beginning of the observed period (Table 1).

The correlation between SE and CAS is not statistically significant, but points out that CAS was decreasing in parallel with stabilizing of SE (Figure 4). The Spearman correlation coefficients ranges from -0.012 (30 months) to 0.237 (12 months) (Table 1).

The Friedman test ($Q = 201.019$; $df = 6$; $p < 0.001$) shows a statistically significant difference in CAS during the analyzed months. Statistical analyses were performed using the statistical package SAS9.4. PROC GLM was used for RM ANOVA.²²

Discussion

Our study confirmed the previous findings of changes in visual acuity and CAS during the development of disease. However, we also found a statistically significant correlation between VA and CAS (Figure 4). We showed that both variables changed in a similar trend, and in the course of the observed time, a decrease in CAS accompanied by the recovery of VA was noticed (Figures 3 and 4).

The correlation between SE and CAS was also positive but not statistically strong during the period of 18 months, after which the correlation began to slowly change direction (Figure 4).

Statistically significant differences in VA and SE over the observed period of time were found (RM ANOVA). Also, rather than determining for each individual subject whether the refractive error of the eye changed in the shift of hyperopia, myopia, or astigmatism, we tried to monitor if trends in refractive error changes correlated with changes in CAS.

The signs and symptoms of clinically manifest GO have a significant impact on visual function by altering the refractive error of the eye.²³

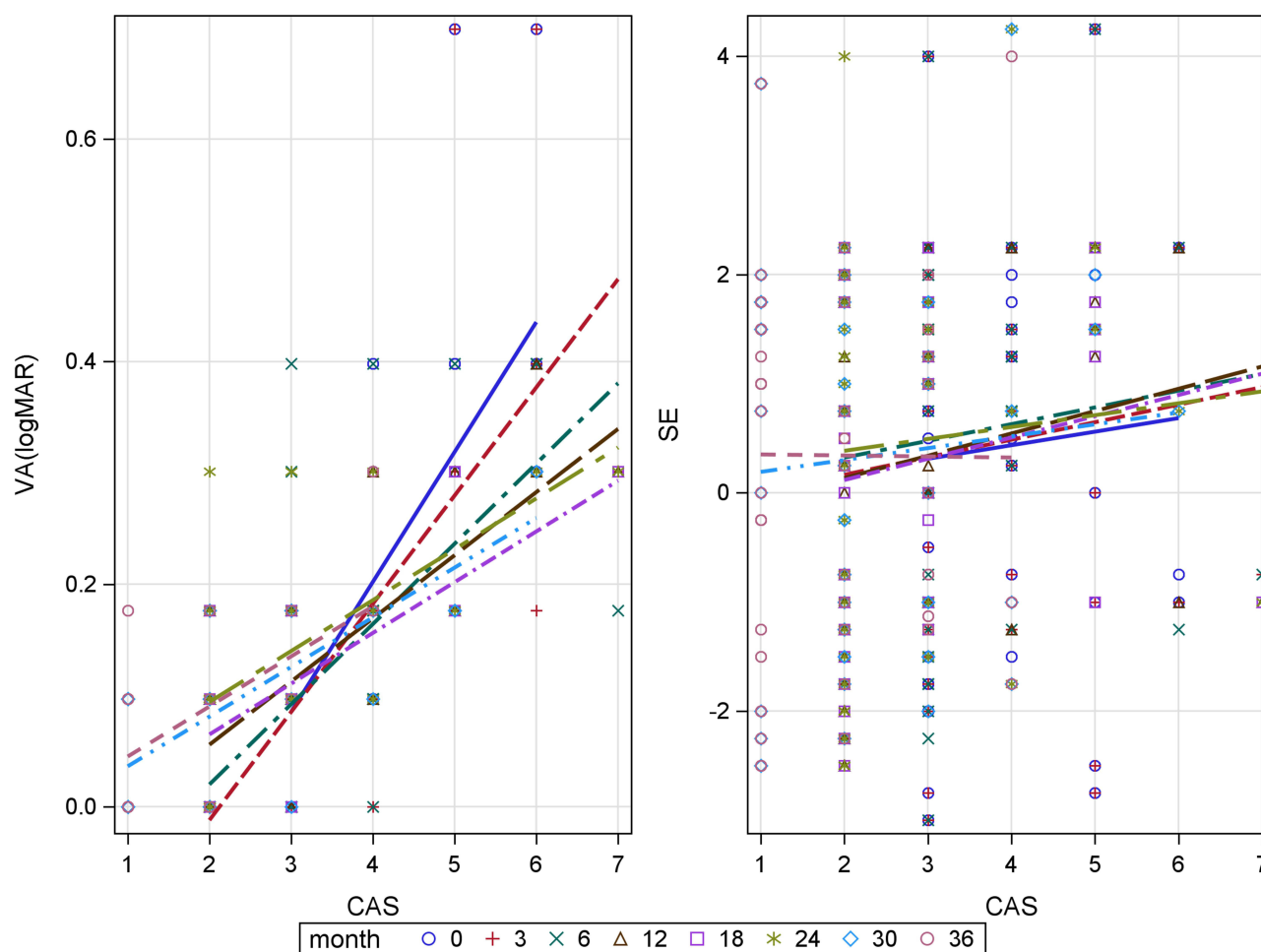


Figure 4 Correlation between VA and CAS, correlation between SE and CAS.

The surgical treatment of severe GO known as orbital decompression reduces venous congestion and leads to a decrease in eyelid edema and chemosis, ultimately resulting in significant changes in the corneal curvature and refractive values.²⁴

Also, it is known that inflammatory changes in the composition of the tear film are associated with complaints of blurred vision that cannot be explained by keratopathy and/or neuroopticopathy.^{25,26} The clinical manifestations of GO can be understood from the perspective of “compartment syndrome”. Proliferation of retrobulbar cells, adipose and connective tissue as well as lacrimal gland cells, and their infiltration by lymphocytes, plasma cells, macrophages, mucopolysaccharides, and numerous mediators of inflammation, as well as the increased volume of extraocular muscles, result in the development of exophthalmos.²⁷

A decrease in the CAS index is either the result of a spontaneously resolving course of GO or a consequence of treatment. An inflammatory reaction of the orbit in GO interpreted from the perspective of “compartment syndrome” changes mechanical pressure on the eye in different planes. The consequence of reducing active inflammation is a direct decrease in mechanical pressure. Since none of the observed patients developed neither neuroopticopathy nor keratopathy, the improvement of corrected VA over the observed time may be associated with a reduction in orbital inflammation and with the changes in the tear film.

Higher-order aberrations of the eye such as trefoil, coma, and spherical aberration are associated with clinical conditions manifested by changes both in the quality and quantity of the tear film, and by degree of corneal curvature, respectively.^{28,29}

Table I Spearman Rank Correlation Coefficients Among VA, SE, and CAS During the Observed Intervals

| Months | Variable | CAS |
|--------|----------|---------------------|
| 0 | VA | 0.764 P < 0.001 |
| | SE | 0.103 P = 0.457 |
| 3 | VA | 0.759 P < 0.001 |
| | SE | 0.145 P = 0.294 |
| 6 | VA | 0.622 P < 0.001 |
| | SE | 0.137 P = 0.331 |
| 12 | VA | 0.585 P < 0.001 |
| | SE | 0.237 P = 0.104 |
| 18 | VA | 0.399 P = 0.005 |
| | SE | 0.206 P = 0.159 |
| 24 | VA | 0.652 P < 0.001 |
| | SE | 0.07 P = 0.632 |
| 30 | VA | 0.663 P < 0.001 |
| | SE | -0.012 P = 0.938 |
| 36 | VA | 0.456 P < 0.001 |
| | SE | -0.023 P = 0.873 |

Abbreviations: GO, Graves' ophthalmopathy; CAS, clinical activity score; VA, visual acuity; SE, spherical equivalent.

These are clinical signs manifested by GO patients; thus in this case, the measurement of higher-order aberrations could more accurately express the change in the refractive value of the eye.

Koh et al quantified the optical impact of tear film breakup.³⁰ In the normal eye, a smooth precorneal surface formed by blinking is maintaining a quality optical medium across the cornea. If the precorneal tear film is disrupted, its break can cause an irregular corneal surface and affect the ocular optical system; thus, a tear film breakup increases the higher-order aberrations and degrades the quality of vision.³¹

Given the above, refractive errors of the eye expressed through higher-order eye aberrations might more clearly correlate with CAS.

Conclusion

Literature on the changes in refractive errors of the eye in GO patients is scarce. In this study, we demonstrated that the VA in GO patients statistically significantly correlated with CAS, while SE correlated with CAS positively but not statistically significant. A decrease in the clinical activity score is either the result of a spontaneously resolving course of GO or a consequence of treatment, so lowering in fluctuation of refractive error and improved visual acuity may be associated with a reduction in orbital inflammation.

These findings should be explored by further research that would look at higher-order eye aberrations and their correlation with CAS, and compare them with higher-order aberrations in the healthy population.

In our study, CAS was observed and statistically analyzed cumulatively; hence, we did not consider how classes of CAS singularly correlate with changes in refractive error. This correlation should be desirable consequence of a further research.

It would also be useful to investigate whether refractive error changes in patients with Graves' disease without ophthalmopathy, as imaging methods reveal abnormalities in 90% of the patients with Graves' disease without symptomatic orbital disease,³² and to compare it with the refractive error changes in GO.

It is important to inform the patient about the transience of changes in visual function as a normal course of the disease and to avoid unnecessary costs of glasses prescription while the clinically active phase of the disease lasts.

Ethics Approval

The study was performed at Referral Center for Graves' ophthalmopathy at University Hospital Center Zagreb according to all the ethical standards and was approved by the Ethics Committee of Clinical University Hospital Zagreb and complies with the Declaration of Helsinki.

Author Contributions

All authors made a significant contribution to the work reported, whether that is in the conception, study design, execution, acquisition of data, analysis and interpretation, or in all these areas; took part in drafting, revising or critically reviewing the article; gave final approval of the version to be published; have agreed on the journal to which the article has been submitted; and agree to be accountable for all aspects of the work.

Funding

The authors did not receive any financial support for this work.

Disclosure

Hereby we confirm that there are no conflicts of interest or competing interests for any of the authors involved in this paper.

References

1. Asman P. Ophthalmological evaluation in thyroid-associated ophthalmopathy. *Acta Ophthalmol Scand*. 2003;81(5):437–448. doi:10.1034/j.1600-0420.2003.00147.x
2. Bartley GB, Fatourechi V, Kadrmas EF, et al. Clinical features of Graves' ophthalmopathy in an incidence cohort. *Am J Ophthalmol*. 1996;121:284–290. doi:10.1016/S0002-9394(14)70276-4
3. Park JJ, Sullivan TJ, Mortimer RH, Wagenaar M, Perry-Keene DA. Assessing quality of life in Australian patients with Graves' ophthalmopathy. *Br J Ophthalmol*. 2004;88(1):75–78. doi:10.1136/bjo.88.1.75
4. Chandrasekaran S, Petsoglou C, Billson FA, Selva D, Ghabrial R. Refractive change in thyroid eye disease (a neglected clinical sign). *Br J Ophthalmol*. 2006;90:307–309. doi:10.1136/bjo.2005.078295
5. Zhang J, Lazar MA. The mechanism of action of thyroid hormones. *Annu Rev Physiol*. 2000;62:439–466. doi:10.1146/annurev.physiol.62.1.439
6. Jankauskiene J, Jarsaitiene D. Assessment of visual acuity, refraction changes, and proptosis in different ages of patients with thyroid diseases. *Int J Endocrinol*. 2012;2012:643275. doi:10.1155/2012/643275

7. Jankauskiene J, Jakstaite V, Smalinskas V. Changes of vision and refraction in patients with thyroid pathology. *Medicina*. 2009;45(5):378–381. doi:10.3390/medicina45050048
8. Huismans H. Conspicuous change of refraction in endocrine orbitopathy. *Klin Monatsbl Augenheilkd*. 1991;198:215–216. doi:10.1055/s-2008-1045955
9. Fledelius HC, Stubgaard M. Changes in refraction and corneal curvature during growth and adult life. *Acta Ophthalmol*. 1986;64:487–491. doi:10.1111/j.1755-3768.1986.tb06959.x
10. Lieberman DM, Grierson J. The lids influence on corneal shape. *Cornea*. 2000;19(3):336–342. doi:10.1097/00003226-200005000-00016
11. Wilson G, Bell C, Chato S. The effect of lifting the lids on corneal astigmatism. *Am J Optom Physiol Opt*. 1982;59:670–674. doi:10.1097/00006324-198208000-00008
12. Plager DA, Snyder SK. Resolution of astigmatism after surgical resection of capillary hemangiomas in infants. *Ophthalmology*. 1997;104:1102–1106. doi:10.1016/S0161-6420(97)30178-X
13. Swinger CA, Troutman RC, Forman JS. Keratophakia–postoperative astigmatism. *Cornea*. 1987;6(3):202–206. doi:10.1097/00003226-198706030-00009
14. Brown MS, Siegel IM, Lisman RD. Prospective analysis of changes in corneal topography after upper eyelid surgery. *Ophthalmic Plast Reconstr Surg*. 1999;15:378–383. doi:10.1097/00002341-199911000-00002
15. Mombaerts I, Vandelanotte S, Koornneef L. Corneal astigmatism in Graves' ophthalmopathy. *Eye*. 2006;20(4):440–446. doi:10.1038/sj.eye.6701898
16. Vihlen FS, Wilson G. The relation between eyelid tension, corneal toricity, and age. *Invest Ophthalmol Vis Sci*. 1983;24:1367–1373.
17. Cuttone JM, Durso F, Miller M, Evans LS. The relationship between soft tissue anomalies around the orbit and globe and astigmatic refractive errors: a preliminary report. *J Pediatr Ophthalmol Strabismus*. 1980;17:29–36. doi:10.3928/0191-3913-19800101-08
18. Kwitko S, Feldon S, McDonnell PJ. Corneal topographic changes following strabismus surgery in Graves' disease. *Cornea*. 1992;11:36–40. doi:10.1097/00003226-199201000-00005
19. Murdoch D, Merriman M. Acquired hyperopia with choroidal folds. *Clin Exp Ophthalmol*. 2002;30(4):292–294. doi:10.1046/j.1442-9071.2002.00536.x
20. Dailey RA, Mills RP, Stimac GK, Shultz WT, Kalina RE. The natural history and CT appearance of acquired hyperopia with choroidal folds. *Ophthalmology*. 1986;93:1336–1342. doi:10.1016/S0161-6420(86)33577-2
21. Bartalena L, Kahaly GJ, Baldeschi L, et al. The 2021 European Group on Graves' orbitopathy (EUGOGO) clinical practice guidelines for the medical management of Graves' orbitopathy. *Eur J Endocrinol*. 2021;185(4):G43–G67. doi:10.1530/EJE-21-0479
22. Der G, Everitt BS. *Statistical Analysis of Medical Data Using SAS*. Chapman&Hall; 2006.
23. Eckstein A, Quadbeck B, Mueller G, et al. Impact of smoking on the response to treatment of thyroid associated ophthalmopathy. *Br J Ophthalmol*. 2003;87(6):773–776. doi:10.1136/bjo.87.6.773
24. Kim WS, Chun YS, Cho BY, Lee JK. Biometric and refractive changes after orbital decompression in Korean patients with thyroid-associated orbitopathy. *Eye*. 2016;30(3):400–405. doi:10.1038/eye.2015.242
25. Gilbard JP, Farris RL. Ocular surface drying and tear film osmolarity in thyroid eye disease. *Acta Ophthalmol*. 1983;61(1):108–116. doi:10.1111/j.1755-3768.1983.tb01401.x
26. Khurana AK, Sunder S, Ahluwalia BK, Malhotra KC. Tear film profile in Graves' ophthalmopathy. *Acta Ophthalmol*. 1992;70(3):346–349. doi:10.1111/j.1755-3768.1992.tb08576.x
27. Boulos PR, Hardy I. Thyroid-associated orbitopathy: a clinicopathologic and therapeutic review. *Curr Opin Ophthalmol*. 2004;15(5):389–400. doi:10.1097/01.icu.0000139992.15463.1b
28. Artal P, Berrio E, Guirao A, Piers P. Contribution of the cornea and internal surfaces to the change of the ocular aberrations with age. *J Opt Soc Am a Opt Image Sci Vis*. 2002;19(1):137–143. doi:10.1364/JOSAA.19.000137
29. Kosaki R, Maeda N, Bessho K, et al. Magnitude and orientation of Zernike terms in patients with keratoconus. *Invest Ophthalmol Vis Sci*. 2007;48(7):3062–3068. doi:10.1167/iovs.06-1285
30. Koh S, Maeda N, Kuroda T, et al. Effect of tear film break-up on higher order aberrations measured with wavefront sensor. *Am J Ophthalmol*. 2002;134:115–117. doi:10.1016/S0002-9394(02)01430-7
31. Tutt R, Bradley A, Begley C, Thibos LN. Optical and visual impact of tear break-up in human eyes. *Invest Ophthalmol Vis Sci*. 2000;41:4117–4123.
32. Müller-Forell W, Pitz S, Mann W, et al. Neuroradiological diagnosis of thyroid-associated orbitopathy. *Exp Clin Endocrinol Diabetes*. 1999;107(Suppl 5):S177–S183. doi:10.1055/s-0029-1212180

Clinical Ophthalmology

Dovepress

Publish your work in this journal

Clinical Ophthalmology is an international, peer-reviewed journal covering all subspecialties within ophthalmology. Key topics include: Optometry; Visual science; Pharmacology and drug therapy in eye diseases; Basic Sciences; Primary and Secondary eye care; Patient Safety and Quality of Care Improvements. This journal is indexed on PubMed Central and CAS, and is the official journal of The Society of Clinical Ophthalmology (SCO). The manuscript management system is completely online and includes a very quick and fair peer-review system, which is all easy to use. Visit <http://www.dovepress.com/testimonials.php> to read real quotes from published authors.

Submit your manuscript here: <https://www.dovepress.com/clinical-ophthalmology-journal>