

Identification of a Novel *OFD1* Variant in a Patient with Primary Ciliary Dyskinesia

Binyi Yang^{1-3*}, Cheng Lei^{1-3*}, Danhui Yang¹⁻³, Chenyang Lu¹⁻³, Yingjie Xu¹⁻³, Lin Wang¹⁻³, Ting Guo¹⁻³, Rongchun Wang¹⁻³, Hong Luo¹⁻³

¹Department of Pulmonary and Critical Care Medicine, The Second Xiangya Hospital, Central South University, Changsha, Hunan, 410011, People's Republic of China; ²Research Unit of Respiratory Disease, The Second Xiangya Hospital, Central South University, Changsha, Hunan, 410011, People's Republic of China; ³Hunan Diagnosis and Treatment Center of Respiratory Disease, The Second Xiangya Hospital, Central South University, Changsha, Hunan, 410011, People's Republic of China

*These authors contributed equally to this work

Correspondence: Rongchun Wang; Hong Luo, Department of Pulmonary and Critical Care Medicine, The Second Xiangya Hospital, Central South University, Changsha, Hunan, 410011, People's Republic of China, Email 198202060@csu.edu.cn; luohonghuxi@csu.edu.cn

Background: *OFD1* encodes a protein with 1012 amino acids, which is a component of basal bodies and centrioles, essential for cilia biogenesis. *OFD1* was reported to be associated with X-chromosome linked dysmorphology syndrome in early studies and recent studies reported a few cases with primary ciliary dyskinesia (PCD) caused by *OFD1* deficiency.

Case Presentation: We report a 31-year-old man who suffered from recurrent respiratory infections with typical manifestations of primary ciliary dyskinesia. In addition to respiratory manifestations, the patient also had situs inversus, obesity, gastroesophageal reflux, and hearing impairment. Clubbing fingers and mild streblomicrodactyly were also observed.

Examination Result: We performed whole-exome sequencing to identify a novel variant c.2795delA:p.(Lys932Argfs*3) in *OFD1*. The hemizygous variant was predicted to be likely pathogenic by bioinformatic analysis software and ACMG guideline. High-speed video microscopy (HSVM), transmission electron microscopy (TEM), and immunofluorescence were performed to analyze the respiratory cilia. A high beating frequency and a stiff beating pattern were observed under HSVM, while there were no significant abnormalities in TEM and immunofluorescence. The sperm flagella examinations were also generally normal.

Conclusion: Our study identified a novel frameshift variant in *OFD1* causing PCD, enriched the genetic spectrum of *OFD1* variants, and verified that *OFD1* mutation can lead to only a PCD characteristic phenotype, while other *OFD1*-associated syndromic symptoms such as dysmorphic features and renal symptoms were not present.

Keywords: *OFD1*, primary ciliary dyskinesia, cilia, situs inversus

Primary ciliary dyskinesia (PCD, MIM 244400) is an inherited genetic motile ciliopathy with a global prevalence estimated at least 1 in 7554 individuals.¹ So far, more than 50 genes that affect ciliary structure and function have been reported to be associated with PCD.² PCD is characterized by recurrent respiratory infections. Since cilia in the respiratory tract, embryonic node, fallopian tube, and flagella shared similar components, patients with PCD may have symptoms involving multiple systems such as bronchiectasis, sinusitis, situs inversus, and infertility.^{3,4}

OFD1, located on chromosome Xp22.2, encodes a protein with 1012 amino acids, which has been known to be associated with dysmorphology syndrome and oral-facial-digital syndrome type I (OFDS1). This male-lethal syndrome inherited in an X-linked dominant pattern was first described in 1954.⁵ Despite controversy exists, two X-linked recessive diseases, Simpson-Golabi-Behmel syndrome type 2 and Joubert syndrome type 10, were also reported to be related to *OFD1*.^{6,7} Dysmorphic features, skeletal abnormalities, and renal symptoms are characteristic of these syndromes and the clinical manifestations of *OFD1* hemizygous mutation are highly variable between different syndromes or the same syndrome. The *OFD1* is essential for cilia biogenesis as a component of centriolar satellites, the particles surrounding centrosomes and basal bodies.⁸ Patients with a frameshift hemizygous variant of the *OFD1* gene exhibiting recurrent

respiratory infections were reported in 2006. The typical clinical manifestations of the respiratory system and high-speed video microscopy (HSVM) results of the family suggested that the variant of *OFDI* is associated with PCD.⁹

Herein, we present a case of a patient with a novel variant of *OFDI*, who has typical respiratory manifestations but no associated syndromic symptoms such as dysmorphic features and renal symptoms.

Case Presentation

The patient is a 31-year-old male who works as a motor mechanic. His mother died in a car accident and both his father and mother did not have respiratory symptoms (Figure 1A). He has been suffering from coughing and expectoration for 2 years. He was admitted to the hospital because of the aggravation of cough, expectoration and sudden hemoptysis (40 mL). His CT examination revealed bronchiectasis, sinusitis, and situs inversus (Figure 1B–C). Sputum culture showed *Staphylococcus aureus* and *Pseudomonas aeruginosa* infection. The symptoms improved after piperacillin-tazobactam treatment.

We also carried out a detailed examination of the patient. The patient's height was 158 cm with a weight of 70 kg (body mass index: 28.04), indicating obesity. However, there was no obesity history in the patient's family. The patient also had fatty liver and hypodensity lipoprotein cholesterolemia. He complained that he had gastroesophageal reflux and hearing impairment in recent years. Lung function test showed predicted forced vital capacity (FVC): 72%, predicted forced expiratory volume during the first second (FEV1): 51%, FEV1/FVC: 73%. His nasal nitric oxide concentration (nNO) was normal: 135.3 nL/min (normal >77nL/min).¹⁰ No obvious abnormality was found in the immune system (immunoglobulin and lymphocyte subsets). The patient had clubbing fingers and mild streblomicrodactyly in the distal interphalangeal joint, but no obvious deformity was found in his head and face (Figure 1D–E).

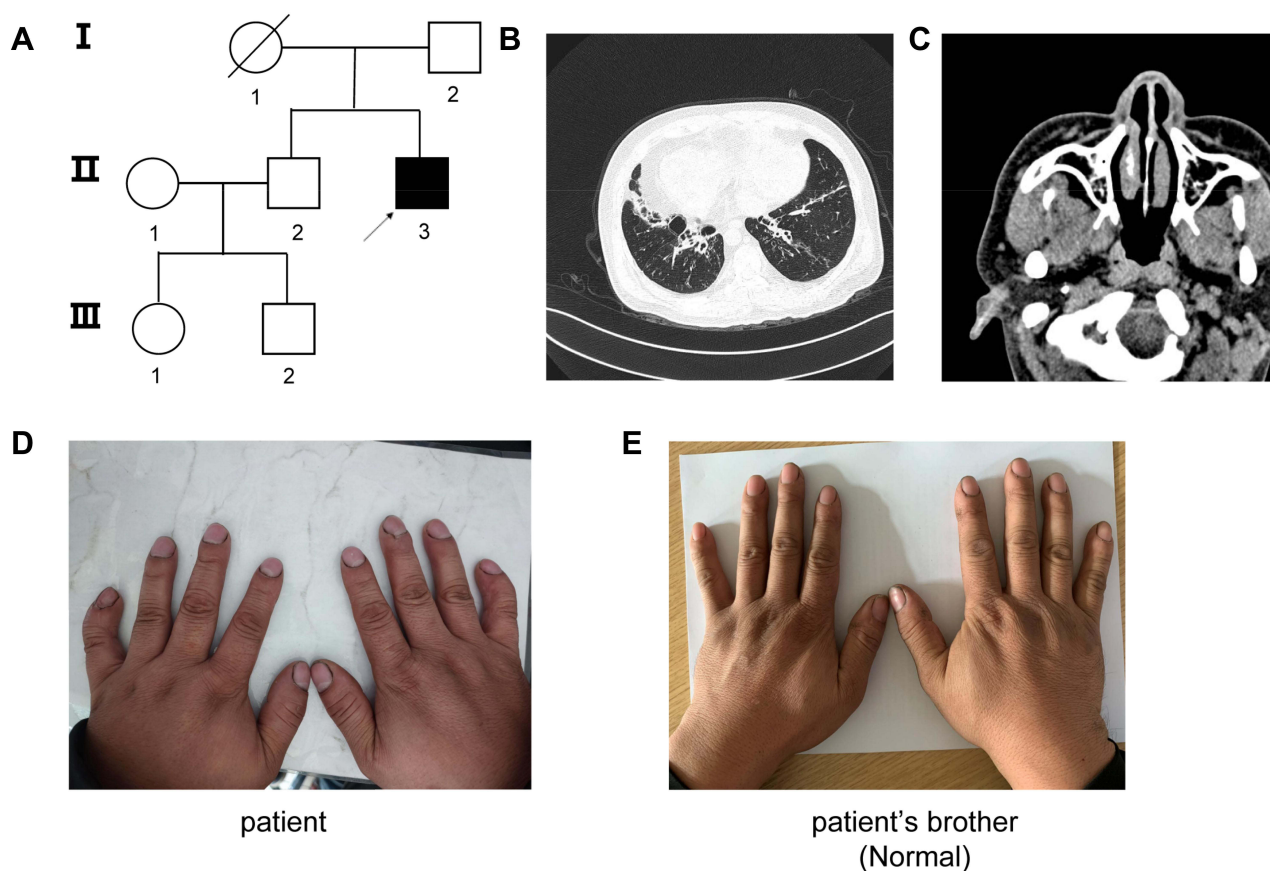


Figure 1 (A) Pedigree of the family with inherited *OFDI* variant. Black arrow, proband; solid symbol, affect family members; crossed-out symbols subject who has passed away. (B) CT scan showed bronchiectasis with infection and situs inversus. (C) CT scan showed sinusitis. (D) The clubbing fingers and mild streblomicrodactyly of the patient. (E) The fingers of patient's brother. No significant deformity has been found.

Genetic Analysis and Detailed Examinations

Identification of the *OFD1* Variant

To further clarify the patient's etiology, whole-exome sequencing was performed and a hemizygous variant of *OFD1* was identified after the selection of rare variation (minor allele frequency <1%) related to PCD. The hemizygous variant c.2795delA:p.(Lys932Argfs*3) happened in Exon 21 which was predicted to be disease-causing by Mutationtaster (<http://www.mutationtaster.com>), which might be associated with the patient's disease. The variant was classified as likely pathogenic according to the ACMG guideline (PVS1 + PM2).¹¹ Sanger sequencing confirmed that the variant was found in the patient while not in his brother (Figure 2A–B). The primer sequences were designed as follows: forward, 5'-CTGTACTTGAAGGATCGGGATT-3'; reverse, 5'-ATGGCACTGGCACCTTATCT-3'.

Detailed Examination of the Respiratory Cilia and the Sperm Flagella

We also collected respiratory epithelium from patients and performed motile cilia analysis including HSV, transmission electron microscopy (TEM), and immunofluorescence. The nasal brush sample was suspended in Gibco Medium 199 (12350039 Gibco). Strips of ciliated epithelium were imaged using an upright Olympus BX53 microscope (Olympus, Tokyo, Japan) with a 40x objective lens. Videos were recorded using a scientific complementary metal oxide semiconductor (sCMOS) camera (Prime BSI, Teledyne Photometrics Inc, USA) at a rate of 500 frames per second at room temperature as described.¹² The ciliary beat frequency was calculated using CiliarMove, a validated software.¹³ A mix of normal cilia beating and stiff beating was observed and the beat frequency of the patient with the *OFD1* variant was higher than that of the healthy control (13.02 ± 3.61 Hz vs 9.52 ± 0.52 Hz) (Figure 3A and [Supplementary video 1](#) and [2](#)). The normal ultrastructure of the axoneme was confirmed in TEM. The normal 9+2 pattern and the presence of dynein arms were observed in all the analyzed cross sections (Figure 3B). Also, both inner and outer dynein arms (DNALI1 and DNAH5) seem normal under the immunofluorescence (Figure 3C). The patient also underwent the fertility examination. The patient had no genital abnormalities. Semen evaluations were performed and more than 200 spermatozoa were observed under the microscope after Papanicolaou staining for morphology analysis. The computer-aided sperm analysis (CASA) and morphological analysis were generally normal except the CASA showed abnormal progressive motility and morphological examination showed that the rate of short flagella deformity was slightly higher than normal (Table 1 and Figure 3D).

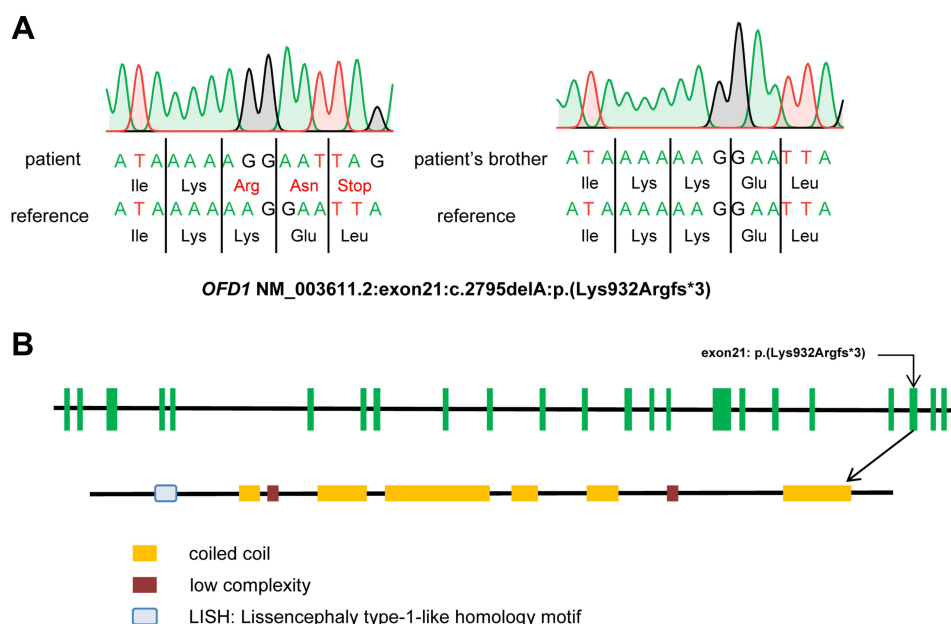


Figure 2 (A) The result of Sanger sequencing of our proband and his brother. The variant c.2795delA:p.(Lys932Argfs*3) was found by whole-exome sequencing and validated by Sanger sequencing in our proband. **(B)** Structure of the *OFD1* gene and protein.

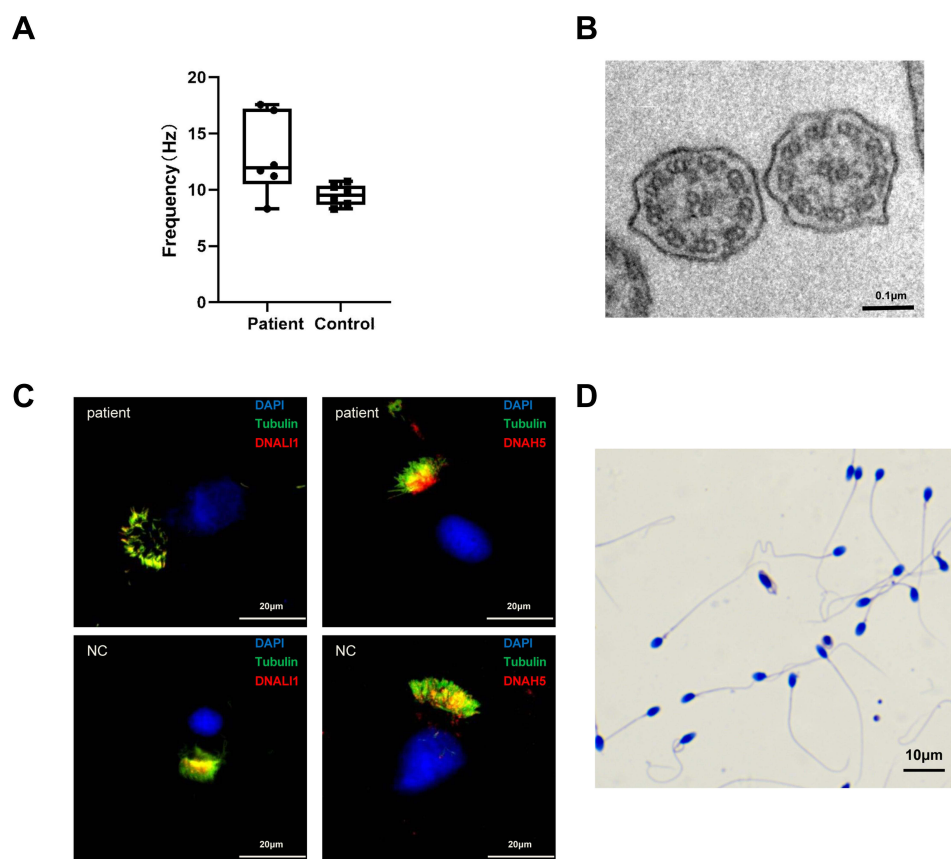


Figure 3 (A) HSVM of nasal brush biopsy samples indicated that the nasal epithelial ciliary beat frequency of the patient with the *OFD1* variant was higher than that of the healthy control (13.02 ± 3.61 Hz vs 9.52 ± 0.52 Hz). (B) The TEM cross-section of respiratory cilia from the patient showed a normal 9+2 structure of the axoneme. (C) The immunofluorescence indicates both inner and outer dynein arms stained by DNALI1 (outer dynein arms) and DNAH5 (inner dynein arms) were normal. Nuclei were stained with DAPI and the structure of tubulin in cilia was normal. (D) The Papanicolaou staining for ejaculated spermatozoa of the patient. Most of the spermatozoa had normal morphology.

Discussion

PCD is caused by the dysfunction of respiratory cilia, which can also involve motile cilia present on the surface of other organs in the human body.¹⁴ Motile cilia have a highly conserved complexed 9+2 axonemal structure among different species that generate functional ciliary motility. The dysmotility and dysfunction of cilia in the respiratory epithelium result in impaired mucociliary clearance, leading to recurrent sinusitis and bronchiectasis. The abnormal flagella in spermatozoa results in male infertility, and the immotility of cilia in the embryonic node causes laterality defects.¹⁵ Clinical features of PCD include respiratory distress, pneumonia, and nasal obstruction during the neonatal period. In childhood, PCD patients typically have chronic coughs with sputum, rhinosinusitis, otitis media, pneumonia, and bronchiectasis. The clinical diagnosis of PCD requires typical clinical manifestations combined with pathological changes in TEM or biallelic pathogenic variants in a known gene associated with PCD. The European Respiratory Society recommended that a diversity of technically demanding methods (including nNO, HSVM, TEM and genetic testing) are necessary for the diagnosis of PCD.¹⁶ Although the clinical symptoms of PCD have certain characteristics, it is difficult to diagnose PCD early and the diagnostic rate has been low due to the lack of understanding of the disease and the limitations of detection methods.

As a component of basal bodies and centrioles, *OFD1* has been demonstrated to promote primary cilium biogenesis by autophagy.⁸ Cep90 (centrosomal protein of 90 kD), MNR (moonraker) and *OFD1* work together as DISCO (distal centriole complex) to promote cilia formation by limiting the length of centriole.¹⁷ In earlier reports, mutations in *OFD1* were thought to be associated with severe ciliopathy syndrome. These syndromes often involve the skeleton, nervous system, and kidney. However, the typical respiratory manifestations and situs inversus of PCD are rarely reported in *OFD1* mutation. A family with *OFD1* mutation that had complications of severe mental retardation, macrocephaly and

Table 1 The Result of Semen Analysis for the Patient

	Semen Parameters				Sperm Morphology				
	Semen Volume (mL)	Sperm Count (10 ⁶ /mL)	Motility (%)	Progressive Motility (%)	Normal Flagella (%)	Absent Flagella (%)	Short Flagella (%)	Coiled Flagella (%)	Angulation (%)
Patient	7.0	107.6	65.6	30.6	77.2	4.4	5.6	8.4	9.6
Reference	>1.5	>15.0	>40.0	>32.0	>23.0	<5.0	<1.0	<17.0	<13.0

Notes: Semen parameters were evaluated according to the World Health Organization guidelines,²⁶ and reference limits of morphologically abnormal spermatozoa observed in fertile individuals.²⁷ More than 200 spermatozoa were observed after Papanicolaou staining for morphology analysis.

recurrent respiratory tract infections was reported in 2006.⁹ Later, *OFDI* mutation was considered to be a pathogenic gene of PCD and was added to the screening panel of whole-exome sequencing of PCD.¹⁶ We reviewed all previously reported cases of *OFDI* mutations, and only 4 patients had only typical PCD symptoms and no other facial or finger abnormalities. All patients are male and three of them have situs inversus. The ultrastructure of the respiratory cilia was normal and the HSVA revealed a stiff beating pattern. Moreover, all mutations were located in exons 20 and 21 (Table 2).

Table 2 The Clinical Feature of This Case and Previous 4 Patients with *OFDI* Mutations Who Had Only Typical PCD Symptoms and No Other Facial or Finger Abnormalities

	This Case	Case 1 ²⁴	Case 2 ²²	Case 3 ²²	Case 4 ²¹
Sex	Male	Male	Male	Male	Male
Age at diagnosis	31	32	17	17	5
<i>OFDI</i> mutation	c.2795delA, p. Lys932ArgfsTer3	c.2868delT, p. Pro957LeufsTer2	c.2615_19delAAATT, p. Gln872fsTer26	c.2797G>T, p.Glu933Ter	c.2852delC, p. Ser951LeufsTer8
Sinusitis	Y	Y	Y	Y	Y
Conductive hearing impairment/recurrent otitis media	Y	N	Y	Y	N
Situs inversus	Y	Y	Y	N	Y
Gastroesophageal reflux	Y	NA	Y	NA	NA
Mental development	Normal	Normal	Normal	Normal	Normal
Facial or digital abnormalities	Mild streblomicrodactyly	N	N	N	N
Obesity	Y	NA	Y	Y	N
nNO (nL/min)	135.3	54.5	61.3	59.1	NA
HSVM	Stiff beating	NA	Sparse cilia, stiff beating, reduced bending, immotile or nearly immotile cilia	Sparse cilia, stiff beating, reduced bending	Stiff beating, 5.5Hz
TEM	Normal 9 + 2 structure of cilia	Normal	NA	Sparse cilia, cytoplasmic accumulation of basal bodies	Microtubular disarrangement
Immunofluorescence	Normal	NA	Sparse or abnormally long cilia	Sparse or abnormally long cilia	NA
Pathogens	<i>S. aureus</i> , <i>P. aeruginosa</i>	<i>H. influenza</i>	<i>H. influenza</i> , <i>P. aeruginosa</i> , <i>S. aureus</i>	<i>H. influenzae</i> , <i>S. pneumoniae</i>	NA

Abbreviations: Y, yes; N, no; NA, not available.

This suggests that the mutations near the C-terminal of OFD1 protein will lead to the classic PCD respiratory phenotype without other severe skeletons, nervous system, and renal symptoms. Compared with other patients with *OFD1* mutation, these patients have normal intelligence, and only present with respiratory symptoms, gastroesophageal reflux, and obesity. Auditory problems have been reported in 8 of 135 OFDS I cases before, which can be attributed to abnormal development of the nervous system and craniofacial developmental malformations.¹⁸ However, in PCD patients with *OFD1* variants, chronic sinusitis can also cause otitis media, resulting in hearing impairment.¹⁹

In this study, the patient has typical bronchiectasis, sinusitis, and situs inversus. A hemizygous variant in PCD-related gene *OFD1* was identified, which is the basis for the diagnosis of PCD in this patient, whereas most other PCD-related examinations such as nNO and TEM do not meet the diagnostic criteria. The nNO of the patient (135.3 nL/min) was normal and significantly different from the criteria for the diagnosis of PCD (normal >77nL/min).¹⁰ However, given the typical clinical symptoms of PCD, we continued to carry out other tests of PCD according to the guidelines, although the patient's nNO value was inconsistent with PCD. The different nNO values could be explained by the interference of age, health status, and other environmental or genetic factors.²⁰ The TEM is an important method for direct observation of ciliary ultrastructural abnormalities. In line with the previous studies, the normal 9 + 2 structure of cilia in our patient with *OFD1* variant was seen under TEM. The stiff beating of cilia under HSVM in our patients illustrated the effect of *OFD1* variant on ciliary function. These phenomena have also been reported in previous patients with *OFD1* variants.^{21,22} Nevertheless, in previous reports, *OFD1* can lead to the abnormal anchoring of cilia and reduction of cilia on the surface of epithelial cells, which cannot be seen in the TEM and immunofluorescence in our patients.²² So far, the relationship between clinical manifestations, ciliary ultrastructural defects, genotypes, and ciliary beating patterns in patients with PCD has not been clearly established because of the heterogeneity of the disease, contributing to the extreme difficulty to diagnose PCD.

Infertility is common in male PCD patients. The reason behind infertility is that the flagella of sperm may be involved, such as immotile spermatozoa and multiple morphological abnormalities of the sperm flagella (MMAF).²³ In this study, the patient's sperm examination was basically normal, with slight abnormalities in the sperm progressive motility and the rate of short flagella. Considering the current results of sperm examinations, it is rather difficult to determine whether the *OFD1* variant will lead to infertility. Only one male with *OFD1* variant who had offsprings has been reported before, but the author declared that it was uncertain whether the patient had used assisted reproductive technologies.²⁴ The frameshift *OFD1* variant may lead to abnormal ciliary function and affect sperm progressive motility and sperm morphology, which in turn, results in infertility. Besides, in previous reports, some patients with *OFD1* variants showed genitourinary malformations.²⁵ We will continue to track whether patients can reproduce in the future follow-up, and suggest that PCD patients who carry *OFD1* variants should monitor the morphology and function of sperm in adolescence in addition to routine genital examination at birth. Fertility counseling and appropriate assisted reproductive technologies are necessary for PCD infertile patient care.

In the present study, we describe a male with PCD that carries a novel hemizygous variant in the *OFD1*. This patient presented chronic sinusitis, bronchiectasis, and situs inversus. Notably, he has only shown chronic cough in the last two years without obvious symptoms of the respiratory system before, which is inconsistent with the clinical manifestations of classic PCD patients in the past. The patient has obvious clubbing fingers and mild streblomicrodactyly, and the sperm examination results seem to be normal. Our case expanded the mutation spectrum of *OFD1* in PCD and verified that *OFD1* mutation can lead to only a PCD characteristic phenotype, while other associated syndromic symptoms were not present.

Data Sharing Statement

The data that support the findings of this study are available from the corresponding author Hong Luo upon reasonable request.

Ethical Compliance

The Review Board of the Second Xiangya Hospital of Central South University in China approved the study protocol. The patient and his brother were given informed consent for publication and for the use of any associated images. All

experiments strictly followed the relevant guidelines and provisions. The clinical data of the subjects, including nasal nitric oxide (nNO) level, computed tomography (CT) and chest radiographs were collected for reviewing.

Acknowledgments

We thank the patient and his families who participated in this study.

Author Contributions

All authors made a significant contribution to the work reported, whether that is in the conception, study design, execution, acquisition of data, analysis and interpretation, or in all these areas; took part in drafting, revising or critically reviewing the article; gave final approval of the version to be published; have agreed on the journal to which the article has been submitted; and agree to be accountable for all aspects of the work.

Funding

This study was supported by the National Natural Science Foundation of China 82070003 to H.L., 81900002 to T.G., Natural Science Foundation of Hunan Province, China (2020JJ5805 to T.G., 2021JJ30943 to H.L.), the Hunan Province Health Commission Scientific Research Project (B2019159 to H.L.), the Science and Technology Program of Changsha, China (kq1901120 to H.L.), and Xiangya Medical Big Data of Central South University (Pulmonary Inflammatory Disease).

Disclosure

The authors declare that the research was conducted in the absence of any commercial or financial relationships that could be construed as a potential conflict of interest.

References

1. Hannah WB, Seifert BA, Truty R, et al. The global prevalence and ethnic heterogeneity of primary ciliary dyskinesia gene variants: a genetic database analysis. *Lancet Respir Med*. 2022;10(5):459–468. doi:10.1016/S2213-2600(21)00453-7
2. Lucas JS, Davis SD, Omran H, Shoemark A. Primary ciliary dyskinesia in the genomics age. *Lancet Respir Med*. 2020;8(2):202–216. doi:10.1016/S2213-2600(19)30374-1
3. Vieira JP, Lopes P, Silva R. Primary ciliary dyskinesia and hydrocephalus with aqueductal stenosis. *J Child Neurol*. 2012;27(7):938–941. doi:10.1177/0883073811429856
4. Wallmeier J, Nielsen KG, Kuehni CE, et al. Motile ciliopathies. *Nat Rev Dis Primers*. 2020;6(1):77. doi:10.1038/s41572-020-0209-6
5. Papillon-Leage PJ. Dysmorphie des freins buccaux: huit observations. *Actual Odontostomatol*. 1954;8(25):7–26.
6. Coene KL, Roepman R, Doherty D, et al. OFD1 is mutated in X-linked Joubert syndrome and interacts with LCA5-encoded lebercilin. *Am J Hum Genet*. 2009;85(4):465–481. doi:10.1016/j.ajhg.2009.09.002
7. Fauth C, Toutain A. Comment on “Whole exome sequencing and array-based molecular karyotyping as aids to prenatal diagnosis in fetuses with suspected Simpson-Golabi-Behmel syndrome”. *Prenat Diagn*. 2017;37(10):1055–1056. doi:10.1002/pd.5137
8. Tang Z, Lin MG, Stowe TR, et al. Autophagy promotes primary ciliogenesis by removing OFD1 from centriolar satellites. *Nature*. 2013;502(7470):254–257. doi:10.1038/nature12606
9. Budny B, Chen W, Omran H, et al. A novel X-linked recessive mental retardation syndrome comprising macrocephaly and ciliary dysfunction is allelic to oral-facial-digital type I syndrome. *Hum Genet*. 2006;120(2):171–178. doi:10.1007/s00439-006-0210-5
10. Collins SA, Gove K, Walker W, Lucas JS. Nasal nitric oxide screening for primary ciliary dyskinesia: systematic review and meta-analysis. *Eur Respir J*. 2014;44(6):1589–1599. doi:10.1183/09031936.00088614
11. Richards S, Aziz N, Bale S, et al. Standards and guidelines for the interpretation of sequence variants: a joint consensus recommendation of the American College of Medical Genetics and Genomics and the Association for Molecular Pathology. *Genet Med*. 2015;17(5):405–424. doi:10.1038/gim.2015.30
12. Lei C, Yang D, Wang R, et al. DRC1 deficiency caused primary ciliary dyskinesia and MMAF in a Chinese patient. *J Hum Genet*. 2022;67(4):197–201. doi:10.1038/s10038-021-00985-z
13. Sampaio P, da Silva MF, Vale I, et al. CiliarMove: new software for evaluating ciliary beat frequency helps find novel mutations by a Portuguese multidisciplinary team on primary ciliary dyskinesia. *ERJ Open Res*. 2021;7(1). doi:10.1183/23120541.00792-2020
14. Leigh MW, Pittman JE, Carson JL, et al. Clinical and genetic aspects of primary ciliary dyskinesia/kartagener syndrome. *Genet Med*. 2009;11(7):473–487. doi:10.1097/GIM.0b013e3181a53562
15. Zariwala MA, Knowles MR, Omran H. Genetic defects in ciliary structure and function. *Annu Rev Physiol*. 2007;69:423–450. doi:10.1146/annurev.physiol.69.040705.141301
16. Lucas JS, Barbato A, Collins SA, et al. European respiratory society guidelines for the diagnosis of primary ciliary dyskinesia. *Eur Respir J*. 2017;49(1):1–54. doi:10.1183/13993003.01090-2016

17. Kumar D, Rains A, Herranz-Pérez V, et al. A ciliopathy complex builds distal appendages to initiate ciliogenesis. *J Cell Biol.* 2021;220(9): e202011133. doi:10.1083/jcb.202011133
18. Macca M, Franco B. The molecular basis of oral-facial-digital syndrome, type 1. *Am J Med Genet C Semin Med Genet.* 2009;151C(4):318–325. doi:10.1002/ajmg.c.30224
19. Goutaki M, Meier AB, Halbeisen FS, et al. Clinical manifestations in primary ciliary dyskinesia: systematic review and meta-analysis. *Eur Respir J.* 2016;48(4):1081–1095. doi:10.1183/13993003.00736-2016
20. Bustamante-Marin XM, Yin WN, Sears PR, et al. Lack of GAS2L2 causes PCD by impairing cilia orientation and mucociliary clearance. *Am J Hum Genet.* 2019;104(2):229–245. doi:10.1016/j.ajhg.2018.12.009
21. Guo Z, Chen W, Wang L, Qian L. Clinical and genetic spectrum of children with primary ciliary dyskinesia in China. *J Pediatr.* 2020;225:157–165. e5. doi:10.1016/j.jpeds.2020.05.052
22. Bukowy-Bieryllo Z, Rabiasz A, Dabrowski M, et al. Truncating mutations in exons 20 and 21 of OFD1 can cause primary ciliary dyskinesia without associated syndromic symptoms. *J Med Genet.* 2019;56(11):769–777. doi:10.1136/jmedgenet-2018-105918
23. Coutton C, Escoffier J, Martinez G, Arnoult C, Ray PF. Teratozoospermia: spotlight on the main genetic actors in the human. *Hum Reprod Update.* 2015;21(4):455–485. doi:10.1093/humupd/dmv020
24. Hannah WB, DeBrosse S, Kinghorn B, et al. The expanding phenotype of OFD1-related disorders: hemizygous loss-of-function variants in three patients with primary ciliary dyskinesia. *Mol Genet Genomic Med.* 2019;7(9):e911. doi:10.1002/mgg3.911
25. Tsurusaki Y, Kosho T, Hatasaki K, et al. Exome sequencing in a family with an X-linked lethal malformation syndrome: clinical consequences of hemizygous truncating OFD1 mutations in male patients. *Clin Genet.* 2013;83(2):135–144. doi:10.1111/j.1399-0004.2012.01885.x
26. Cooper TG, Noonan E, von Eckardstein S, et al. World Health Organization reference values for human semen characteristics. *Hum Reprod Update.* 2010;16(3):231–245. doi:10.1093/humupd/dmp048
27. Auger J, Jouannet P, Eustache F. Another look at human sperm morphology. *Hum Reprod.* 2016;31(1):10–23. doi:10.1093/humrep/dev251

Pharmacogenomics and Personalized Medicine

Dovepress

Publish your work in this journal

Pharmacogenomics and Personalized Medicine is an international, peer-reviewed, open access journal characterizing the influence of genotype on pharmacology leading to the development of personalized treatment programs and individualized drug selection for improved safety, efficacy and sustainability. This journal is indexed on the American Chemical Society's Chemical Abstracts Service (CAS). The manuscript management system is completely online and includes a very quick and fair peer-review system, which is all easy to use. Visit <http://www.dovepress.com/testimonials.php> to read real quotes from published authors.

Submit your manuscript here: <https://www.dovepress.com/pharmacogenomics-and-personalized-medicine-journal>