

Refractive Correction After Penetrating Keratoplasty by a New Soft Contact Lens with a Special Design for Astigmatism: A Case Report

Tomoto Kasahara¹, Hiroshi Toshida¹, Kohei Ichikawa¹, Yusuke Matsuzaki¹, Junji Ono²

¹Department of Ophthalmology, Juntendo University Shizuoka Hospital, Shizuoka, 410-2295, Japan; ²Ono Eye Clinic, Shizuoka, 410-0056, Japan

Correspondence: Hiroshi Toshida, Department of Ophthalmology, Juntendo University Shizuoka Hospital, Izunokuni, Shizuoka, 410-2295, Japan, Tel +81 55 948 3111, Fax +81 55 948 3351, Email toshida@juntendo.ac.jp

Abstract: YOUSOFT is a new soft contact lens (CL) specifically designed for the correction of astigmatism. It is a conventional FDA Group II soft contact lens (SCL) and the optical zone in its centre is thick, and on its rear surface it has a prism ballast structure to prevent rotation. This lens was prescribed for a 59-year-old male on the eye with irregular corneal astigmatism after receiving penetrating keratoplasty (PKP) for refractive correction, whose eye was difficult to wear hard CLs (HCLs). After following the directions in the fitting manual provided by the manufacturer, fitting was good in the right eye and corrected visual acuity was 20/25 in Snellen Chart. He could continue wearing without CL discomfortable YOUSOFT may be useful in patients who have received PKP.

Keywords: soft contact lens, irregular astigmatism, penetrating keratoplasty, keratoconus

Introduction

Corneal astigmatism can be broadly divided into regular astigmatism and irregular astigmatism. Regular astigmatism can be corrected with glasses. However, in the case of irregular astigmatism, light is scattered, and an image cannot be formed with glasses and hard contact lenses (HCLs) are the first choice for correction of refraction.¹ For eyes with corneal astigmatism, such as in patients with keratoconus or those who have undergone corneal transplantation, not a few patients stop wearing HCL due to contact lens (CL) discomfort,² or intolerant to CLs.³ In cases such as these, it may be possible to wear a lens and correct visual acuity with a piggyback CL system, in which an HCL is worn on top of a SCL.^{4,5} Examples of special CLs include scleral lenses,⁶ hybrid lenses having a central rigid gas permeable portion bonded to the SCL,⁷⁻¹³ and an SCL specially designed for irregular astigmatism.¹⁴⁻¹⁶

For our patient, we prescribed YOUSOFT, a new conventional SCL specifically designed for irregular astigmatism, which was released by Seed Co., Ltd. (Tokyo, Japan). Successful results were obtained in this patient with corneal astigmatism following penetrating keratoplasty (PKP), for whom wearing a HCL was difficult. In this report, we detail this case and explain the possible benefits and disadvantages of this new lens.

Materials and Methods

The characteristics of YOUSOFT are shown in Table 1. Figure 1A shows the scheme of this lens. The optical zone in the centre of this lens is thick (0.4 mm) to aid the correction of astigmatism. It has a prism ballast structure on its rear surface as a mechanism to prevent lens rotation and stabilize the lens axis. The indications recommended by the manufacturer are cases with irregular corneal astigmatism including PKP, as in the present case. However, there are no reports explained in this lens. The lens composition is classified as Group II of the Food & Drug Administration SCL category. Water content is 80%, and oxygen permeability (Dk) is 44×10^{-11} (cm²/sec) (mLO²/mlmmHg). For the selection of the trial lens, we chose the one that best approximated a value in which the mean corneal curvature radius added by +1.0 mm. After

Table I Characteristics of YOUSOFT

Base Curve	7.80 to 8.40 (0.20 Steps)
Diameter	14.50mm
Power range	Sphere: +30.00 D to −30.00D (in 0.25 steps) Cylinder: −0.25 to −6.00 D (in 0.25 steps)
Axis	5°- 180° (in 5° steps)
Thickness in the centre of lens	0.4mm
FDA group	Group 2, 80% Water
Dk	44×10^{-11} (cm ² /sec) [mLO ₂ / (mL x mmHg)]
Materials	N, N-Dimethylacrylamide, N-vinyl-pyrrolidone, methyl methacrylate, Alkyl methacrylate-based compounds, Ethylene glycol dimethacrylate

wearing of the trial lens, lens movement and stability were checked. If the fit was too tight or loose, the lens was replaced until the best fit was obtained.

In the present study, YOUSOFT was prescribed for the 59-year-old male on the eye after receiving PKP. The Ethics Committee of Juntendo University Shizuoka Hospital approved the study (study protocol, Rin 833). He provided informed consent after they received an explanation of the possible consequences of the study, which adhered to the tenets of the Declaration of Helsinki.

Results

At the age of 34, the patient was diagnosed with bilateral keratoconus by a local doctor and started wearing HCLs. At the age of 46, after the onset of acute edema in the cornea of the right eye, the patient was referred to our hospital because of

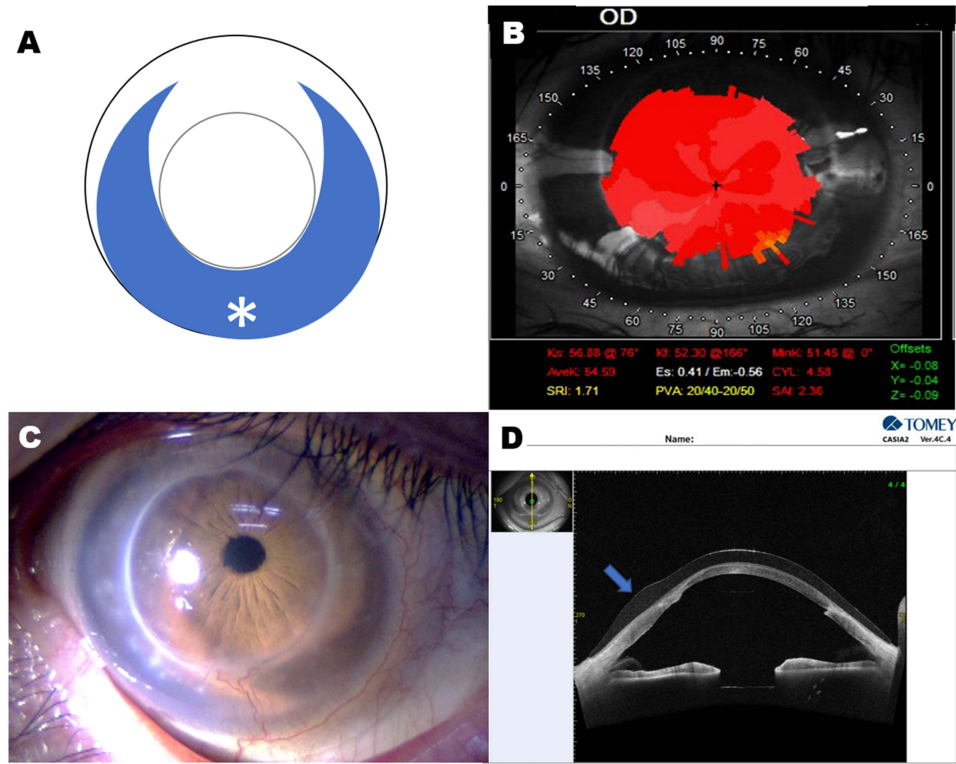


Figure 1 (A) Figure 1: Scheme of YOUSOFT. The circle in the middle is the optical zone. Prizm ballast design (asterisk) is adopted in the lower area of the lens. (B) Corneal videokeratograph after cataract surgery in the right eye. Irregularities are shown. (C) Ocular images in the right eye wearing YOUSOFT. The fitting parameters of the base curve, total diameter, spherical and cylinder power, and axis were 7.80 mm, 14.5 mm, −2.00 D, −0.25D, 180° for YOUSOFT, respectively. (D) Vertical Meridian image of YOUSOFT on the cornea obtained by anterior segment optical coherence tomography. Thicker part of the lens on the lower area of the cornea (Arrow).

decreased vision in his right eye. At his first visit, the visual acuity in his right eye was the counting fingers (uncorrected). He wore an HCL in his left eye; his uncorrected visual acuity was 20/100 in Snellen chart, and his HCL-corrected visual acuity was 20/25. Examination of the anterior segments of the eyes showed opacity of the entire cornea of the right eye and keratoconus of the left eye. No significant changes were observed in the intermediate translucent body or in the intraocular pressure. The fundus of the right eye could not be visualized, while no significant changes were observed in the left eye. As clinical therapy, at the age of 47, the patient underwent a PKP to treat the corneal opacity that remained in his right eye. Thereafter, an attempt was made to wear an HCL again for the correction of postoperative astigmatism in the right eye, but since the HCL on its own was not stable, we opted for a piggyback CL system in which the HCL was worn on top of a daily disposable SCL. In addition, in the left eye, a HCL with a multistep curve was a good fit. The CL-corrected visual acuity was 20/20 in the right eye and 20/25 in the left eye.

At the age of 58, a cataract in the right eye had progressed, so cataract surgery was performed. After the operation, we considered resuming treatment with a piggyback CL system, but we were informed that YOUSOFT, an SCL specifically designed for irregular astigmatism, was about to be launched. Half a year later, we tested YOUSOFT in the right eye. [Figure 1B](#) showed the corneal videokeratograph (TMS-4, Tomey, Aichi, Japan) after cataract surgery in the right eye. The objective refraction value was measured by automated refraction and keratometry (ARK-1a, Nidek, Aichi, Japan). KM, Kmax, Kmin, cylinder power, and axis were 6.10mm, 6.56mm, 5.64mm, -8.25D, and 171° in the right eye. For the selection of the trial lens, we followed the directions in the fitting manual provided by the manufacturer. A good fit was then obtained so YOUSOFT was prescribed ([Figure 1C](#)). Anterior segment optical coherence tomography (CASIA SS-1000TM, Tomey, Aichi, Japan) also revealed the proper fitting pattern in this case ([Figure 1D](#)). When wearing CLs, the corrected visual acuity was 20/25 in the right eye. Although the CL wearing methods and lens care procedures were different for the right and left eyes, the patient became skillful in the handling of the lenses since the discomfort associated with wearing CLs had lessened. A good fit and corrected visual acuity have been maintained for half a year since the initial fitting.

Discussion

With regard to alternatives to HCLs for corneal astigmatism, for example after PKP, several reports have been published about recently available hybrid lenses^{7–13} and SCL specially designed for eyes with irregular astigmatism.^{14–16} Generally, the visual correction of corneal irregular astigmatism by the specially designed SCL is inferior to that by the HCL. Indications for these specially designed CLs include keratoconus, corneal ectasia, post-corneal posterior radial incision, anterior corneal radial incision, post-LASIK ectasia, and post-PKP. Special CLs include: (1) scleral lenses and sclerocorneal lenses with larger lens diameters than standard HCLs; (2) piggyback CL systems; and (3) specially designed CLs for irregular astigmatism. Among the CLs specially designed for astigmatism, there are several hybrid lenses, for example, Synergeyes (SynergeEyes Inc., Carlsbad, CA),^{7,12,13} EyeBrid Silicone (LCS Laboratories, Caen, France)^{9,10,13} and AirFlex (SwissLens, Prilly, Switzerland).^{9,10} On the other hand, KeraSoft is a specially designed SCLs for astigmatism.^{14–16} In Japan, they are difficult to obtain because they have not been approved by the Ministry of Health, Labor and Welfare. However, in June 2020, YOUSOFT was released as a SCL specially designed for irregular astigmatism similar to KeraSoft. In the present case, a good fit was achieved with the first trial lens. The prescription was issued after some adjustment and as described above, good visual acuity was achieved. In addition, no issues were reported with continued wearing. YOUSOFT SCL is equipped with a rotation prevention mechanism in the form of a prism ballast structure, and the anterior eye optical coherence tomography (OCT) performed when wearing the SCL confirmed good stability, since the thick part of the lens was located at the bottom. Corrected visual acuity with YOUSOFT was good but did not, however, reach the level of corrected visual acuity obtained with the piggyback CL system used prior to the onset of the cataract. Although our patient is satisfied with his treatment, HCLs may offer better visual acuity correction. A hybrid HCL/SCL lens may thus be a better choice once it officially becomes available.

Since KeraSoft is not available in Japan, it is not possible to compare it with YOUSOFT. However, a review of the lens specifications suggests that KeraSoft is superior for parameters such as type of base curve, lens diameter, astigmatism power, and axis. Moreover, KeraSoft is made of silicon hydrogen rather than hydrogel with YOUSOFT. As such, a potential concern of long-term YOUSOFT use is oxygen penetration. Although Dk is 44, if used for an

extended period of time, its influence on corneal endothelial cells and corneal vascularization must be carefully monitored for hypoxia-induced effects. In addition, YOUSOFT is not a disposable SCL, but a conventional SCL. Therefore, proper lens care is important, and durability may be a potential issue.

A problem unique to this case could have been the different lens care agents and lens care methods required for the right and left eyes. However, the patient became familiar with the lens care method and continued to wear this lens 6 months after prescription without any problem because it offered good corrected visual acuity, a secure fit, and a reduction in CL discomfort. Our patient used to wear a daily disposable SCL to help insert and remove his YOUSOFT. Other than lens care, there was little else that needed to be mastered, which may explain why this lens was easy to use.

As YOUSOFT is a very thick, conventional hydrogel SCL, we will continue to evaluate its effects on the cornea and its durability over the long term. The level of satisfaction with YOUSOFT was high in this patient with keratoconus, although this is just a case report. YOUSOFT SCLs may thus be useful in patients with irregular corneal astigmatism who cannot wear HCLs. It seemed that the evaluation with more cases was necessary in future.

Conclusion

YOUSOFT is a new SCL specifically designed for the correction of astigmatism. The optical zone in its centre is thick and it has a prism ballast structure to prevent rotation on its rear surface similar to KeraSoft. Although YOUSOFT is a conventional FDA Group II SCL unlike KeraSoft which is consisted of silicone hydrogel monomers, it may be one of the choices for patients whose eyes have irregular corneal astigmatism.

Ethics Statement

This report was approved by the review board of Shizuoka Hospital, Juntendo University (No. 833). The authors certify that they have obtained appropriate written patient consent form. In the form the patient has given his consent for his images and other clinical information to be reported in the journal. The patient understood that his name and initial will not be published and due efforts will be made to conceal their identity.

Funding

This work was supported in part by a Grant-in-Aid for Special Research in Subsidies for ordinary expenses of private schools from the Promotion and Mutual Aid Corporation for Private Schools of Japan.

Disclosure

The authors declare that they have no conflicts of interest in this work.

References

1. O'Riordan M. Hard contact lenses. Medical aspects. *Trans Ophthalmol Soc U K*. 1977;97(1):129–130.
2. Jackson AJ, Wolsley C, Briggs JL, Frazer DG. Acute rigid gas permeable contact lens intolerance. *Cont Lens Anterior Eye*. 2001;24(4):161–167.
3. Stapleton F, Bakkar M, Carnt N, et al. CLEAR -Contact lens complications. *Cont Lens Anterior Eye*. 2021;44(2):330–367.
4. Kohn AN. Piggyback contact lenses for reducing postkeratoplasty astigmatism. *Arch Ophthalmol*. 1980;98(12):2246.
5. Acar BT, Vural ET, Acar S. Effects of contact lenses on the ocular surface in patients with keratoconus: piggyback versus ClearKone hybrid lenses. *Eye Contact Lens*. 2012;38(1):43–48.
6. Abou Samra WA, Badawi AE, Kishk H. Fitting Tips and Visual Rehabilitation of Irregular Cornea with a New Design of Corneoscleral Contact Lens: objective and Subjective Evaluation. *J Ophthalmol*. 2018;1(2018):3923170.
7. Abou Samra WA, El-Emam DS, Kasem MA. Clinical Performance of a Spherical Hybrid Lens Design in High Regular Astigmatism. *Eye Contact Lens*. 2018;44(Suppl 1):S66–S70.
8. Harbiyeli II, Erdem E, Isik P, Yagmur M, Ersoz R. Use of new-generation hybrid contact lenses for managing challenging corneas. *Eur J Ophthalmol*. 2021;31(4):1802–1808.
9. Uçakhan ÖÖ, Yeşiltaş YS. Correction of Irregular Astigmatism With New-Generation Hybrid Contact Lenses. *Eye Contact Lens*. 2020;46(2):91–98.
10. Ozlem D, Sibel K, Mehmet CM. Evaluation of Visual Acuity Outcomes and Corneal Alterations of New Generation Hybrid Contact Lenses in Patients With Advanced Keratoconus. *Cornea*. 2020;39(11):1366–1370.
11. Carracedo G, González-Méijome JM, Lopes-Ferreira D, Carballo J, Batres L. Clinical performance of a new hybrid contact lens for keratoconus. *Eye Contact Lens*. 2014;40(1):2–6.

12. Lipson MJ, Much DC. Synergeyes versus soft toric lenses: vision-related quality of life. *Optom Vis Sci*. 2007;84(7):593–597.
13. Dave K, Carina K, Elke OK. Clinical Outcome of Hybrid Contact Lenses in Keratoconus. *Eye Contact Lens*. 2021;47(5):283–287.
14. Fernandez-Velazquez FJ. Kerasoft IC compared to Rose-K in the management of corneal ectasias. *Cont Lens Anterior Eye*. 2012;35(4):175–179.
15. Uçakhan ÖÖ, Bayraktutar B. KeraSoft 3 contact lenses in corneal ectasia. *Eye Contact Lens*. 2014;40(6):390–394.
16. Nicula C, Nicula D, Suci CC. Results in keratoconus correction with Kerasoft 3 Contact lenses. *Rom J Ophthalmol*. 2020;64(2):122–127.

International Medical Case Reports Journal

Dovepress

Publish your work in this journal

The International Medical Case Reports Journal is an international, peer-reviewed open-access journal publishing original case reports from all medical specialties. Previously unpublished medical posters are also accepted relating to any area of clinical or preclinical science. Submissions should not normally exceed 2,000 words or 4 published pages including figures, diagrams and references. The manuscript management system is completely online and includes a very quick and fair peer-review system, which is all easy to use. Visit <http://www.dovepress.com/testimonials> to read real quotes from published authors.

Submit your manuscript here: <https://www.dovepress.com/international-medical-case-reports-journal-journal>