

Serum NSE is Early Marker of Transformed Neuroendocrine Tumor After EGFR-TKI Treatment of Lung Adenocarcinoma

Xiaowei Mao^{1,2,*}, Jiabing Liu^{3,*}, Fang Hu^{1,*}, Yanjie Niu¹, Feng Pan¹, Xiaolong Fu³, Liyan Jiang¹

¹Pulmonary and Critical Care Medicine, Shanghai Jiao Tong University, Shanghai Chest Hospital, Shanghai, People's Republic of China; ²Department of Pulmonary and Critical Care Medicine, Regional Medical Center for National Institute of Respiratory Diseases, Sir Run Run Shaw Hospital, School of Medicine, Zhejiang University, Hangzhou, Zhejiang, People's Republic of China; ³Department of Radiation Oncology, Shanghai Jiao Tong University, Shanghai Chest Hospital, Shanghai, People's Republic of China

*These authors contributed equally to this work

Correspondence: Liyan Jiang; Xiaolong Fu, Email jiang_liyan2000@126.com; xlfu1964@126.com

Background: Transformation to a lung neuroendocrine tumor (LNET) is a mechanism of resistance to epidermal growth factor receptor (EGFR) tyrosine kinase inhibitors (TKI). Serum neuron-specific enolase (NSE) is a useful marker in the detection of LNET. Therefore, we explored the clinical significance of serum NSE levels in the detection of transformed neuroendocrine tumors after EGFR-TKI therapy.

Methods: We report a cohort of 5 cases in our treatment group. The characteristics of the patients, pathological diagnoses, immunohistochemistry with molecular detection, laboratory examination, and treatment histories are analyzed. The tumor markers of serum NSE were analyzed. Additionally, we reviewed the publications reporting the tumor markers before and after LNET transformation during EGFR-TKI therapy.

Results: Most patients are female (3/5), aged <60 years old (4/5), nonsmokers (4/5) and harbor the EGFR 19 exon deletion (4/5). The median time of LNET transformation was 19 months (range: 12–31 months). The clinical characteristics were similar to those reported in previous studies. Laboratory examination revealed an increased NSE level before the LNET is defined. Sixteen publications were reviewed. Of those, 86.67% (13/15) publications showed an increased level of NSE when the LNET transformation was defined.

Conclusion: Adenocarcinoma tumors in non-smokers, young patients harboring the EGFR 19 exon deletion tended to transform to LNETs after EGFR-TKI therapy. Combining our findings and a review of the literature, we suggest that serum NSE may be a useful tumor marker to predict neuroendocrine tumor transformation.

Keywords: transformation, EGFR-TKI, target therapy, lung neuroendocrine tumor, neuron-specific enolase

Introduction

Lung cancer is the leading cause of cancer-related death in China and worldwide.^{1,2} Based on its biological behavior and morphological characteristics, lung cancer is classified into two histological subgroups: non-small cell lung cancer (NSCLC) and small cell lung cancer (SCLC).^{3,4} Epidermal growth factor receptor (EGFR) gene mutations are observed in approximately 50% of patients with advanced adenocarcinoma (ADC) in Asian populations.⁵ The first-line treatment for patients with advanced NSCLC with EGFR mutations is the EGFR tyrosine kinase inhibitor (TKI), such as gefitinib or osimertinib.^{6–9}

However, most patients who initially respond to EGFR-TKI therapy subsequently report disease progression. Several studies have reported the histological transformation from NSCLC to lung neuroendocrine tumors (LNETs) as a mechanism of EGFR-TKI resistance.^{10,11} LNETs are tumor originating from neuroendocrine cells of the lung.¹² The transformed LNETs can be SCLC or large cell neuroendocrine carcinoma. During target therapy, about 5% of patients with NSCLC tumors transform into LNETs, at which point treatment plans must change. SCLC and large cell neuroendocrine carcinoma are considered the most aggressive types of malignant lung cancer. The treatments for

SCLC and NSCLC are different. Despite a high rate of positive responses to first-line treatments, these cases show rapid growth and metastasis and acquire multidrug resistance. Thus, it is important to identify transformed LNETs.

However, despite the significance in detecting cancer transformation during EGFR-TKI therapy, rebiopsies are not routinely performed in lung cancer patients who show resistance to TKI treatment. Previous studies have reported that the rebiopsy rate is about 50%.^{13,14} Monitoring tumor markers may be a potential alternative method. Serum neuron-specific enolase (NSE) is a good marker for SCLC.¹⁵ NSE is a key enzyme in glycolysis. In tumors derived from neuroectoderm or neuroendocrine tissues, higher levels of NSE can be detected in serum.¹⁶ Previous studies believe that the increased NSE at initial diagnosis is an important negative prognostic factor for worse response to chemotherapy, radiotherapy, or immunotherapy.^{17–19} However, to date, only some cases have reported the role of tumor markers (including NSE) in the detection of LNET transformation, although to date no systematic analysis has been performed evaluating its clinical role.

Herein, we report 5 cases of LNET transformed from pulmonary ADC after EGFR-TKI therapy in a single institute, in addition to a review of the previous literature. We found elevated NSE levels before transformed LNETs were clinically defined.

Materials and Methods

Patients and Follow Up

From 2015–2020, we reviewed the pathological records of LNET cases, and identified 5 cases of ADC who received EGFR-TKI therapy that had transformed into lung LNETs. Pathology samples used to diagnose ADC and LNET were reviewed by at least two experienced pathologists. Immunohistochemistry markers, including TTF-1, p40, CD56, and CK, were used to distinguish subtypes if hematoxylin and eosin (H&E) staining was not sufficient. All patients were treated in the Pulmonary and Critical Care Medicine or Thoracic Oncology Departments, Shanghai Chest Hospital, Shanghai, China. Clinical and follow-up data were obtained for retrospective analysis, including age, sex, smoking history, clinical stage, and treatment. During therapy, patients were advised to see a doctor every two months to evaluate their condition. Chest computed tomography (CT) scans, B-mode ultrasonography (abdomen, supraclavicular lymph node), and samples for tumor markers were obtained when patients visited the hospital. A rebiopsy was carried out if the target lesion was diagnosed as progressive disease.

Pathology Diagnosis and EGFR Mutation Test

All samples were fixed in 4% formaldehyde, and 5 mm sections were stained with H&E. Sections were examined with an Olympus microscope. If pathologists were unable to distinguish the subtype of lung cancer, then immunohistochemistry was used. Immunohistochemical staining of CD56, TTF-1, CK, and p40, was performed. Pathologists examined each section using a double-blind procedure.

Before testing for EGFR mutations, tumor cells were evaluated. A minimum of 100 cancer cells were used. Two kits were used to detect EGFR mutations. The first was the EGFR mutation kit (Amoydx, Xiamen, China), and the second was the capture-based targeted sequencing panel (Burning Rock Biotech, Guangzhou, China). The tests were carried out according to the manufacturer's instructions.

NSE Detection

A 3mL sample of venous blood was collected from each patient, and the serum was obtained after centrifugation. The serum NSE level was detected by Roche Elecsys 2010 automatic electrochemiluminescence immunoanalyzer. In the event of rupture of red blood cells, which will lead to a false increase in NSE, samples with evidence of hemolysis were discarded and a new blood sample was obtained.

Review of the Literature

All studies before 1 October 2021, describing the LNET transformation and tumor markers were reviewed and analyzed. Detailed data, including author, year published, the pathology diagnosis before and after transformation, and LNET specific tumor markers (NSE, progastrin gastrin releasing peptide [ProGRP]) before and after transformation.

Ethical Statement

This study was conducted following the Helsinki Declaration, and was approved by The Ethics Committee of Shanghai Chest Hospital (KS1752). All included patients signed informed consent forms of providing the case details and medical images. The authors are responsible for all aspects of the work in ensuring that questions related to the accuracy or integrity of any part of the work are appropriately investigated and resolved.

Results

Five patients were included in our study: two males and three females. The median age was 47 years. Most patients were non-smokers who harbored an EGFR 19 exon deletion (4/5, 80%). Four patients translated to SCLC after therapy, and one patient transformed to lung LNET. One patient received five biopsies, the pathology types were ADC-SCLC-NSCLC-ADC-LNET, respectively. Three patients received only EGFR-TKI prior to LNET transformation, while two patients received both EGFR-TKI and chemotherapy. The response to EGFR-TKI was a partial response (PR) of four patient. Tumors from four patients were found to be transformed to LNET at the second biopsy, and the fifth at the third biopsy. ADC transformed to SCLC in four patients, and poorly differentiated LNETs were present in two patients. The median time of LNET transformation was 19 months (range: 12–31 months; [Tables 1](#) and [2](#), and [Figure 1](#)). The immunohistochemistry of the transformed LNETs showed that CD56 was positive in each case, and TTF-1 was also expressed ([Figure 2](#)). Four patients detected EGFR in transformed LNETs. The transformed LNETs retained the initial EGFR mutation in those four cases. In the fifth biopsy from case 3, and the second biopsy from case 4, next-generation sequencing (NGS) was performed on the transformed LNET. In addition to the EGFR mutation, MYC amplification, and co-mutations of TP53 and BRCA2 were also detected ([Table 1](#)).

Detailed treatment histories are described for each case in the [Supplemental materials](#).

We analyzed tumor markers of NSE during EGFR-TKI treatment. As shown in [Figure 3](#), at the start of treatment with EGFR-TKIs, NSE was present at normal levels, but gradually increased during treatment to above the normal range in the final laboratory examination before transformed LNETs were detected.

Before 1 October 2021, total of 16 reports, describing 16 patients, were enrolled ([Table 3](#)). Most cases were male (9/16, 56.25%), aged <60 years old (12/16, 75.00%), never smokers (10/16, 62.50%), harbored the EGFR 19del (12/16, 75.00%). Nine patients received EGFR-TKI treatment only, six patients received EGFR-TKI and chemotherapy, while the remaining patient received EGFR-TKI, chemotherapy and local radiation therapy. The median duration of response (DOR) of LNET transformation was 16.5 months (range 1–45 months). Fifteen studies reported the level of NSE during treatment, and 13 (86.67%) patients showed an increased level of NSE when LNET transformation was defined. Seven studies reported ProGRP levels, and 6 (85.71%) patients showed increased levels of ProGRP in LNET transformation.

Discussion and Review of the Literature

EGFR mutations are the most common mutation in NSCLC, and mutations are considered to be the drivers of NSCLC carcinogenesis.³⁶ Half of Asian NSCLC patients, especially nonsmoking females, harbor EGFR mutations.³⁷ EGFR-TKIs are a class of drugs that has been widely used in clinical practice to block EGFR signaling pathways and inhibit tumor cell proliferation and migration.³⁸ Several studies have shown prolonged progression-free survival after first-line EGFR-TKI therapy,^{5–9} but patients gradually develop drug resistance. Different mechanisms have been described to explain this, including new EGFR mutations, amplification of the MET gene, epithelial-mesenchymal transitions, and transformation to LNETs.³⁹ These mechanisms are also responsible for resistance to third-generation EGFR-TKIs.³² Histological transformation is found in approximately 5% of EGFR-TKI therapy-resistant patients.⁴⁰ The most common type of transformation that results from EGFR-TKI therapy is ADC to SCLC, which is an aggressive cancer usually treated by chemotherapy and radiotherapy.

In our study, all cases were diagnosed as ADC with sensitive EGFR mutations. Subsequent biopsies showed that TKI treatment was associated with the transformation to SCLC. A previous study reported that there is a high incidence of SCLC transformation among non-smoking, younger aged, EGFR-mutated NSCLC patients.⁴¹ Similarly, in our study the patients were mostly young (<60 years old), harbored the EGFR 19 deletion, and had never smoked. The median time for

Table I Pathological Characteristics of the Initial ADC and Transformed Neuroendocrine Tumors

| No | Age | Sex | Smoking History | Biopsy | Biopsy Result | | | | | | Other |
|----|-----|-----|-----------------|---------------|---------------|----------------------------|----------------------|----------|-------|----------------|--|
| | | | | | Pathology | | Sample Type | TTF-I | CD56 | EGFR | |
| 1 | 55 | F | No | First biopsy | ADC | Mediastinal lymph node | Needle biopsy | NA | NA | 19del | TP53 mutation MYC amplification BRCA2 mutation |
| | | | | Second biopsy | ADC | Pleura | Needle biopsy | (+) | (-) | 19del T790M | |
| 2 | 46 | M | Former | Third biopsy | SCLC | Primary cancer | Needle biopsy | (+) | (+) | 19del | |
| | | | | First biopsy | ADC | Primary cancer | Needle biopsy | | | 19del | |
| 3 | 47 | M | No | Second biopsy | SCLC | Pleural effusion | Pleural effusion | (+) | (+/-) | | |
| | | | | First biopsy | ADC | Primary cancer | Needle biopsy | (+) | (-) | L858R | |
| | | | | Second biopsy | SCLC | Primary cancer | Needle biopsy | Part (+) | (+) | NA | |
| | | | | Third biopsy | NSCLC | Primary cancer | Tracheoscopic biopsy | Part (+) | NA | L858R | |
| | | | | Forth biopsy | ADC | Primary cancer | Tracheoscopic biopsy | (+) | (-) | L858R | |
| | | | | Fifth biopsy | LNET | Primary cancer | Tracheoscopic biopsy | Part (+) | (+) | L858R | |
| 4 | 76 | F | No | First biopsy | ADC | Pleural effusion | Pleural effusion | (+) | (-) | 19del | |
| | | | | Liquid biopsy | | | | | | T790M | |
| | | | | Second biopsy | LNET | Primary cancer | Needle biopsy | (+) | (+) | 19del | |
| 5 | 47 | F | No | First biopsy | ADC | Primary cancer | Surgery resected | NA | NA | 19del | |
| | | | | Second biopsy | SCLC | Supraclavicular lymph node | Needle biopsy | Part (+) | (+) | 19del | |

Abbreviations: ADC, adenocarcinoma; NSCLC, non-small cell lung cancer; SCLC, small cell lung cancer; LNET, lung neuroendocrine tumor; EGFR, epidermal growth factor receptor.

Table 2 Treatment Before and After Transformation

| No | Initial Tumor | Initial Stage | Treatment Before Transformation | | | | Transformed Tumor | Transformed Stage | Treatment After Transformation | |
|----|---------------|---------------|---------------------------------|--------------|----------|------|-------------------|-------------------|--------------------------------|--------------|
| | | | TKI | Chemotherapy | Response | PFS | | | TKI | Chemotherapy |
| 1 | ADC | IV | Gefitinib, Osimertinib | TS-I | PR | 12.7 | SCLC | IV | - | EC |
| 2 | ADC | IV | Erlotinib, Osimertinib | AP | PR | 23.1 | SCLC | IV | - | EC |
| 3 | ADC | IV | Gefitinib | - | PR | 19 | SCLC | IV | Gefitinib | EC, AP |
| 4 | ADC | IV | Icotinib, Osimertinib | - | PR | 10.5 | LNCT | IV | - | AP, EC |
| 5 | ADC | IV | Gefitinib | - | SD | 12 | SCLC | IV | - | EC |

Abbreviations: ADC, adenocarcinoma; SCLC, small cell lung cancer; LNCT, lung neuroendocrine tumor; TKI, tyrosine kinase inhibitor; PFS, progression free survival; PR, partial response; SD, stable disease; TS-I, tegafur.

SCLC transformation was reported to be 17.8 months (range 14.3–26.2 months),¹¹ and the transformed LNCT always retained their original EGFR-activating mutations,^{21,32,41,42} which was consistent with our findings. Although transformed LNCTs harbored the initial EGFR mutation, most patients did not continue EGFR-TKI therapy. In only one patient the histological type was NSCLC after chemotherapy for transformed SCLC, after which EGFR-TKI therapy was continued for about nine months.

Different theories have been proposed to explain the mechanism of histological transformation. One theory proposed that tumors that transform to LNCT are not pure NSCLC. As the tumor is heterogeneous, samples obtained from bronchoscopy, fine-needle aspiration or pleural effusion may not provide sufficient material to detect the presence of combined histology at diagnosis.^{43,44} Niederst et al also proposed a cladistic evolution model: a precursor cell at baseline may transform into SCLC in response to EGFR-TKIs.¹⁰ The signaling pathway for this process may include TP53, RB1, Notch, and MYC.^{45–50} In our study, NGS was conducted on two patients with transformed LNCTs and revealed the presence of TP53 and MYC, which was consistent with previous findings.

Although it is important to detect cancer transformation during EGFR-TKI therapy, additional biopsies are not routinely performed in lung cancer patients who show resistance to TKI treatment. Previous studies have reported that the rebiopsy rate is about 50%.^{13,14} Additional biopsies are not usually performed due to inaccessible tumors, deterioration of performance status, or patient refusal.⁵¹ Thus tumor markers may play a key role in monitoring cancer transformation. NSE and ProGRP are widely used to monitor SCLC treatment. NSE is a key enzyme in glycolysis. In tumors derived from neuroectoderm or neuroendocrine tissues, higher levels of NSE can be detected in serum.¹⁶ Gastrin




Figure 1 Treatment history, pathology, and other characteristics. Five cases received comprehensive treatment based on epidermal growth factor receptor-tyrosine kinase inhibitor targeted therapy, and the LNCT transformation was confirmed in the rebiopsy specimen.

Abbreviations: ADC, adenocarcinoma; SCLC, small cell lung cancer; LNCT, lung neuroendocrine tumor; TS-I, tegafur.

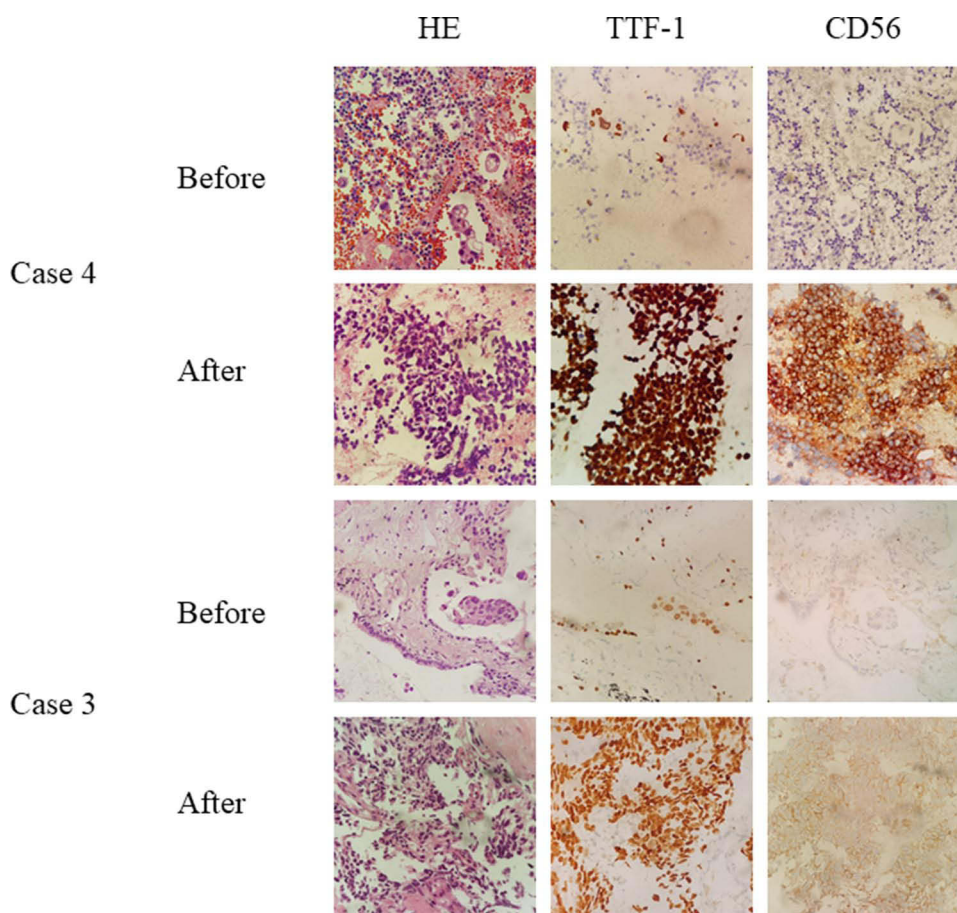


Figure 2 Representative pictures before and after transformation. The hematoxylin-eosin and immunohistochemistry staining showed that adenocarcinoma was transformed to lung neuroendocrine tumor. CD56, a neuroendocrine marker, was negative before transformation and strongly positive after transformation.

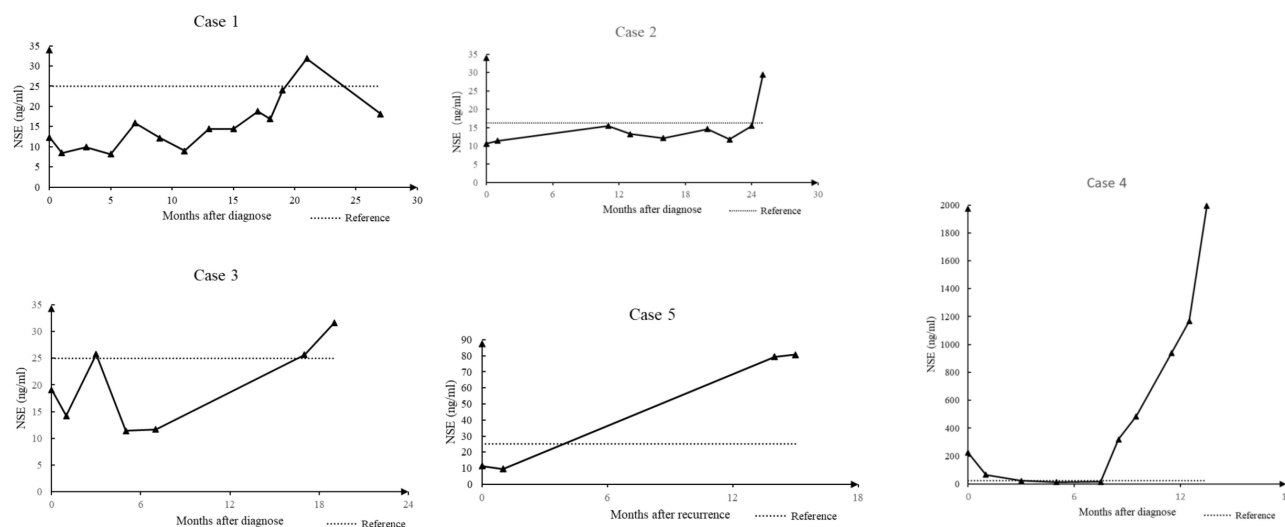


Figure 3 NSE detection of each patient. NSE levels gradually increased during epidermal growth factor receptor-tyrosine kinase inhibitor therapy and exceeded the reference level before the clinical definition of lung neuroendocrine tumor.

Abbreviation:NSE, neuron-specific enolase.

Table 3 Review of NSE and ProGRP in Detecting Neuroendocrine Tumor Transformation After EGFR-TKI Treatment of Lung Adenocarcinoma

| Author | Year | Age | Sex | Smoking | EGFR | TKI | Chemotherapy | Histopathology | EGFR | DOR | NSE | ProGRP | Ref |
|--------------------|------|-----|-----|---------|-------|--------------------------|--|----------------|-------|------|-----------------|-----------------|------|
| Zhang Yan | 2013 | 80 | M | No | L9del | Icotinib | — | SCLC | L9del | 1 | ↑ | NA | [20] |
| Watanabe Satoshi | 2013 | 52 | F | No | L9del | Erlotinib | Pemetrexed+cisplatin | SCLC | L9del | 20 | ↑ | ↑ | [21] |
| Xue Shuping | 2015 | 49 | F | No | L9del | Icotinib | | SCLC | NA | 23 | ↑ | ↑ | [22] |
| Furugen Makoto | 2015 | 63 | M | No | L9del | Erlotinib | | SCLC+ADC | L9del | 10 | ↑ | ↑ | [23] |
| Fang Liying | 2016 | 74 | M | Yes | L9del | Gefitinib | | SCLC | NA | 12 | ↑ | NA | [24] |
| Lin Quan | 2016 | 49 | M | Yes | L858R | Gefitinib | Pemetrexed+cisplatin Docetaxel+ cisplatin | SCLC | L858R | 15 | ↑ | NA | [25] |
| Xu Yanjun | 2017 | 37 | F | No | L9del | Gefitinib | Pemetrexed+cisplatin | SLCL | NA | 7 | ↑ | NA | [26] |
| Lu Hongyang | 2018 | 55 | M | Yes | L858R | Icotinib | | NEC | L858R | 19 | ↑ | NA | [27] |
| Shiroyama Takayuki | 2018 | 35 | M | Yes | L9del | Afatinib | | SCLC | L9del | 7 | — ^{\$} | — ^{\$} | [28] |
| Liu Yangyang | 2018 | 38 | M | No | L858R | Erlotinib | | SLCL | NA | 18 | ↑ | NA | [29] |
| Iijima Yuki | 2018 | 52 | F | No | L9del | Gefitinib | Pemetrexed+carboplatin | SCLC | L9del | 45 | ↑ | ↑ | [30] |
| | | | | | T790M | Erlotinib Osimertinib | Gemcitabine | | | | | | |
| Han Chaonan | 2019 | 58 | F | No | L9del | Icotinib | Pemetrexed | SCLC | L9del | 10 | ↑ | NA | [31] |
| Chen Shen | 2019 | 49 | M | No | L858R | Gefitinib | Pemetrexed+cisplatin | SCLC | NA | 30.7 | ↑ | NA | [32] |
| | | | | | T790M | Osimertinib | | | | | | | |
| Kato Yasuhiro | 2019 | 74 | F | No | L9del | Afatnib | | SCLC | L9del | 20 | NA | ↑ | [33] |
| Fiore Michele* | 2019 | 56 | F | Yes | L9del | Gefitinib | Pemetrexed+cisplatin | SCLC | L9del | 20 | ↑ | ↑ | [34] |
| Xie Zhanhong | 2019 | 53 | M | Yes | L9del | Erlotinib | | SCLC | L9del | 11 | — | NA | [35] |

Notes: *Local radiotherapy was added; ^{\$}NSE and ProGRP were elevated after the first cycle of chemotherapy.

Abbreviations: EGFR, epidermal growth factor receptor; TKI, tyrosine kinase inhibitor; DOR, duration of response; NSE, neuron-specific enolase; ProGRP, progastrin-releasing peptide; NA, not available.

releasing peptide has been identified in nerve fibers, brain and neuroendocrine cells of the fetal lung. It proved challenging because gastrin releasing peptide is unstable in blood, however ProGRP has been found to be more stable,⁵² and has been shown to be a sensitive and specific marker of SCLC.⁵³

We reviewed and analyzed all the literature reporting LNET transformation and tumor markers. A total of sixteen reports including sixteen patients were enrolled (Table 3). The patients described in those literatures most are male, younger aged, never smoking, who harbored the EGFR 19Del mutation. The media DOR of LNET transformation was 16.5 months, which was similar to that observed in our findings. Most studies reported an increased NSE level (13/15, 86.67%) or ProGRP level (6/7, 85.71%) once LNET transformation was defined. This is consistent with our findings. In our cohort of these five cases, increased NSE levels may indicate pathological transformation. In the present study, NSE increased gradually during treatment to above the reference value prior to detection of transformed LNETs. Although NSE and ProGRP were good markers for the detection of LNET transformation, in some studies, NSE or ProGRP were normal during transformation.^{32,35} Therefore, our findings suggested that NSE is an accurate predictor of the transformation to LNETs. But a rebiopsy was encouraged to confirm the type of cancer.

In summary, we report 5 cases of transformation to LNETs following EGFR-TKI treatment of ADC. The clinical characteristics and pathological findings described here are consistent with previous studies. We found that the NSE levels can be good predictors of cancer transformation.

Conclusion

Serum NSE can be a useful tumor marker to predict neuroendocrine tumor transformation during EGFR-TKI therapy.

Acknowledgment

The authors thank Dr. Lai Jinglei (Department of thoracic surgery, Shanghai Cancer Hospital, Fudan University) for his kindly help!

This work was supported by National Key Research and Development Program of China: 2018YFC1313600, Chinese Society of Clinical Oncology (CSCO): Y-2019AZD-0038, the Medical Engineering Cross Research Foundation of Shanghai Jiao Tong University (ZH2018QNA67), the Scientific Research Project of Shanghai Municipal Health Commission (20194Y0168).

Disclosure

The authors report no conflicts of interest in this work.

References

- Bray F, Ferlay J, Soerjomataram I, et al. Global cancer statistics 2018: GLOBOCAN estimates of incidence and mortality worldwide for 36 cancers in 185 countries. *CA Cancer J Clin*. 2018;68(6):394–424. doi:10.3322/caac.21492
- Chen W, Zheng R, Baade PD, et al. Cancer statistics in China, 2015. *CA Cancer J Clin*. 2016;66(2):115–132. doi:10.3322/caac.21338
- Travis WD, Brambilla E, Nicholson AG, et al. The 2015 World Health Organization classification of lung tumors: impact of genetic, clinical, and radiologic advances since the 2004 classification. *J Thorac Oncol*. 2015;10(9):1243–1260. doi:10.1097/JTO.0000000000000630
- Fisseler-Eckhoff A, Demes M. Neuroendocrine tumors of the lung. *Cancers*. 2012;4(3):777–798. doi:10.3390/cancers4030777
- Shi Y, Au JS, Thongprasert S, et al. A prospective, molecular epidemiology study of EGFR mutations in Asian patients with advanced non-small-cell lung cancer of adenocarcinoma histology (PIONEER). *J Thorac Oncol*. 2014;9(2):154–162. doi:10.1097/JTO.0000000000000033
- Mok TS, Wu YL, Thongprasert S, et al. Gefitinib or carboplatin-paclitaxel in pulmonary adenocarcinoma. *N Engl J Med*. 2009;361(10):947–957. doi:10.1056/NEJMoa0810699
- Zhou C, Wu YL, Chen G, et al. Erlotinib versus chemotherapy as first-line treatment for patients with advanced EGFR mutation-positive non-small-cell lung cancer (OPTIMAL, CTONG-0802): a multicentre, open-label, randomised, Phase 3 study. *Lancet Oncol*. 2011;12(8):735–742. doi:10.1016/S1470-2045(11)70184-X
- Shi YK, Wang L, Han BH, et al. First-line icotinib versus cisplatin/pemetrexed plus pemetrexed maintenance therapy for patients with advanced EGFR mutation-positive lung adenocarcinoma (CONVINCE): a phase 3, open-label, randomized study. *Ann Oncol*. 2017;28(10):2443–2450. doi:10.1093/annonc/mdx359
- Soria JC, Ohe Y, Vansteenkiste J, et al. Osimertinib in untreated EGFR-mutated advanced non-small-cell lung cancer. *N Engl J Med*. 2018;378(2):113–125. doi:10.1056/NEJMoa1713137
- Niderst MJ, Sequist LV, Poirier JT, et al. RB loss in resistant EGFR mutant lung adenocarcinomas that transform to small-cell lung cancer. *Nat Commun*. 2015;6:6377. doi:10.1038/ncomms7377

11. Marcoux N, Gettinger SN, Okane G, et al. EGFR-mutant adenocarcinomas that transform to small-cell lung cancer and other neuroendocrine carcinomas: clinical outcomes. *J Clin Oncol*. 2019;37(4):278–285. doi:10.1200/JCO.18.01585
12. WHO Classification of Tumours Editorial Board. *Thoracic Tumours*. 5th ed. Lyon (France): International Agency for Research on Cancer; 2021.
13. Kawamura T, Kenmotsu H, Taira T, et al. Rebiopsy for patients with non-small-cell lung cancer after epidermal growth factor receptor-tyrosine kinase inhibitor failure. *Cancer Sci*. 2016;107(7):1001–1005. doi:10.1111/cas.12963
14. Ichihara E, Hotta K, Kubo T, et al. Clinical significance of repeat rebiopsy in detecting the EGFR T790M secondary mutation in patients with non-small cell lung cancer. *Oncotarget*. 2018;9:29525–29531. doi:10.18632/oncotarget.25705
15. Karnak D, Beder S, Kayacan O, et al. Neuron-specific enolase and lung cancer. *Am J Clin Oncol*. 2005;28(6):586–590. doi:10.1097/01.coc.0000177915.51805.6e
16. Cooper EH, Splinter TA, Brown DA, et al. Evaluation of a radioimmunoassay for neuron specific enolase in small cell lung cancer. *Br J Cancer*. 1985;52(3):333–338. doi:10.1038/bjc.1985.198
17. van Zandwijk N, Jassem E, Bonfrer JM, et al. Serum neuron-specific enolase and lactate dehydrogenase as predictors of response to chemotherapy and survival in non-small cell lung cancer. *Semin Oncol*. 1992;19(1 Suppl 2):37–43.
18. Li L, Zhang Z, Hu Y. Neuron - specific enolase predicts the prognosis in advanced small cell lung cancer patients treated with first-line PD-1/PD-L1 inhibitors. *Medicine*. 2021;100(36):e27029. doi:10.1097/MD.00000000000027029
19. Tian Z, Liang C, Zhang Z, et al. Prognostic value of neuron-specific enolase for small cell lung cancer: a systematic review and meta-analysis. *World J Surg Oncol*. 2020;18(1):116. doi:10.1186/s12957-020-01894-9
20. Zhang Y, Li XY, Tang Y, et al. Rapid increase of serum neuron specific enolase level and tachyphylaxis of EGFR-tyrosine kinase inhibitor indicate small cell lung cancer transformation from EGFR positive lung adenocarcinoma? *Lung Cancer*. 2013;81(2):302–305. doi:10.1016/j.lungcan.2013.04.005
21. Watanabe S, Sone T, Matsui T, et al. Transformation to small-cell lung cancer following treatment with EGFR tyrosine kinase inhibitors in a patient with lung adenocarcinoma. *Lung Cancer*. 2013;82(2):370–372. doi:10.1016/j.lungcan.2013.06.003
22. Xue SP, Yu TT, Zhang D, et al. Clinical observation of translating to small cell lung cancer following treatment with egfr-tyrosine kinase inhibitors in lung adenocarcinoma. *Chin J Lung Cancer*. 2015;18(10):656–660. doi:10.3779/j.issn.1009-3419.2015.10.10
23. Furugen M, Uechi K, Hirai J, et al. An autopsy case of two distinct, acquired drug resistance mechanisms in epidermal growth factor receptor-mutant lung adenocarcinoma: small cell carcinoma transformation and epidermal growth factor receptor T790M mutation. *Intern Med*. 2015;54(19):2491–2496. doi:10.2169/internalmedicine.54.5481
24. Fang L, He J, Xia J, et al. Resistance to epithelial growth factor receptor tyrosine kinase inhibitors in a patient with transformation from lung adenocarcinoma to small cell lung cancer: a case report. *Oncol Lett*. 2017;14(1):593–598. doi:10.3892/ol.2017.6229
25. Lin Q, Cai GP, Yang KY, et al. Case report: small cell transformation and metastasis to the breast in a patient with lung adenocarcinoma following maintenance treatment with epidermal growth factor receptor tyrosine kinase inhibitors. *BMC Cancer*. 2016;16:593. doi:10.1186/s12885-016-2623-4
26. Xu Y, Huang Z, Gong L, et al. A case of resistance to tyrosine kinase inhibitor therapy: small cell carcinoma transformation concomitant with plasma-genotyped T790M positivity. *Anticancer Drugs*. 2017;28(9):1056–1061. doi:10.1097/CAD.0000000000000540
27. Lu H, Chen B, Qin J, et al. Transformation to small-cell lung cancer following treatment with icotinib in a patient with lung adenocarcinoma. *Oncol Lett*. 2018;15(4):5799–5802. doi:10.3892/ol.2018.8040
28. Shiroyama T, Nasu S, Tanaka A, et al. Transformation to small cell lung cancer after first-line Afatinib treatment. *Respir Med Case Rep*. 2018;23:188–190. doi:10.1016/j.rmcr.2018.02.011
29. Liu Y. Small cell lung cancer transformation from EGFR-mutated lung adenocarcinoma: a case report and literatures review. *Cancer Biol Ther*. 2018;19(6):445–449. doi:10.1080/15384047.2018.1435222
30. Iijima Y, Hirotsu Y, Mochizuki H, et al. Dynamic changes and drug-induced selection of resistant clones in a patient with egfr-mutated adenocarcinoma that acquired t790m mutation and transformed to small-cell lung cancer. *Clin Lung Cancer*. 2018;19(6):e843–e847. doi:10.1016/j.clcc.2018.07.002
31. Han CN, Meng SY, Lv MJ, et al. Small-cell lung cancer transformation in a pulmonary adenocarcinoma patient as an acquired resistance mechanism to icotinib: a case report and review. *Int J Clin Exp Med*. 2019;12(1):1086–1093.
32. Chen S, He YY, Liu J, et al. Third-generation TKI resistance due to SCLC transformation: a case report and brief review. *Onco Targets Ther*. 2019;12:11305–11311. doi:10.2147/OTT.S228301
33. Kato Y, Tanaka Y, Hino M, et al. ProGRP as early predictive marker of non–small-cell lung cancer to small cell lung cancer transformation after EGFR-TKI treatment. *Respir Med Case Rep*. 2019;27:100837. doi:10.1016/j.rmcr.2019.100837
34. Fiore M, Trecca P, Perrone G, et al. Histologic transformation to small-cell lung cancer following gefitinib and radiotherapy in a patient with pulmonary adenocarcinoma. *Tumori*. 2019;105(6):NP12–NP16. doi:10.1177/0300891619832261
35. Xie ZH, Gu YY, Lin XQ, et al. Unexpected favorable outcome to etoposide and cisplatin in a small cell lung cancer transformed patient: a case report. *Cancer Biol Ther*. 2019;20(9):1172–1175. doi:10.1080/15384047.2019.1617561
36. Rothschild S. Targeted therapies in non-small cell lung cancer-beyond EGFR and ALK. *Cancers*. 2015;7(2):930–949. doi:10.3390/cancers7020816
37. Mitsudomi T. Molecular epidemiology of lung cancer and variations with special reference to EGFR mutations. *Transl Lung Cancer Res*. 2014;3(4):205–211. doi:10.3978/j.issn.2218-6751.2014.08.04
38. Xia N, Hu CP. Research progress on drug resistance mechanisms of EGFR-TKIs in non-small cell lung cancer. *World Clin Drugs*. 2012;33(4):202–205.
39. Camidge DR, Pao W, Sequist LV. Acquired resistance to TKIs in solid tumors: learning from lung cancer. *Nat Rev Clin Oncol*. 2014;11(8):473–481. doi:10.1038/nrclinonc.2014.104
40. Oser MG, Niederst MJ, Sequist LV, et al. Transformation from non-small cell lung cancer to small-cell lung cancer: molecular drivers and cells of origin. *Lancet Oncol*. 2015;16(4):e165–e172. doi:10.1016/S1470-2045(14)71180-5
41. Jiang SY, Zhao J, Wang MZ, et al. Small-cell lung cancer transformation in patients with pulmonary adenocarcinoma: a case report and review of literature. *Medicine*. 2016;95(6):e2752. doi:10.1097/MD.00000000000002752
42. Sequist LV, Waltman BA, Dias-Santagata D, et al. Genotypic and histological evolution of lung cancers acquiring resistance to EGFR inhibitors. *Sci Transl Med*. 2011;3(75):75ra26. doi:10.1126/scitranslmed.3002003
43. Dagogo-Jack I, Shaw AT. Tumour heterogeneity and resistance to cancer therapies. *Nat Rev Clin Oncol*. 2018;15(2):81–94. doi:10.1038/nrclinonc.2017.166

44. Tatematsu A, Shimizu J, Murakami Y, et al. Epidermal growth factor receptor mutations in small cell lung cancer. *Clin Cancer Res*. 2008;14(19):6092–6096. doi:10.1158/1078-0432.CCR-08-0332
45. Lee JK, Lee J, Kim S, et al. Clonal history and genetic predictors of transformation into small-cell carcinomas from lung adenocarcinomas. *J Clin Oncol*. 2017;35(26):3065–3074. doi:10.1200/JCO.2016.71.9096
46. Offin M, Chan JM, Tenet M, et al. Concurrent RB1 and TP53 alterations define a subset of EGFR-mutant lung cancers at risk for histologic transformation and inferior clinical outcomes. *J Thorac Oncol*. 2019;14(10):1784–1793. doi:10.1016/j.jtho.2019.06.002
47. Tenjin Y, Nakamura K, Ishizuka S, et al. Small cell lung cancer derived from adenocarcinoma with mutant epidermal growth factor receptor provides a signature of transcriptional alteration in tumor cells. *Intern Med*. 2019;58(22):3261–3265. doi:10.2169/internalmedicine.2988-19
48. George J, Lim JS, Jang SJ, et al. Comprehensive genomic profiles small cell lung cancer. *Nature*. 2015;524(7563):47–53. doi:10.1038/nature14664
49. Peifer M, Fernandez-Cuesta L, Sos ML, et al. Integrative genome analyses identify key somatic driver mutations of small-cell lung cancer. *Nat Genet*. 2012;44(1):1104–1110. doi:10.1038/ng.2396
50. Rudin CM, Durinck S, Stawiski EW, et al. Comprehensive genomic analysis identifies SOX2 as a frequently amplified gene in small-cell lung cancer. *Nat Genet*. 2012;44(10):1111–1116. doi:10.1038/ng.2405
51. Zhou J, Zhao C, Zhao J, et al. Re-biopsy and liquid biopsy for patients with non-small cell lung cancer after EGFR-tyrosine kinase inhibitor failure. *Thorac Cancer*. 2019;10:957–965. doi:10.1111/1759-7714.13035
52. Stovold R, Blackhall F, Meredith S, et al. Biomarkers for small cell lung cancer: neuroendocrine, epithelial and circulating tumour cells. *Lung Cancer*. 2012;76(3):263–268. doi:10.1016/j.lungcan.2011.11.015
53. Oh HJ, Park HY, Kim KH, et al. Progastrin-releasing peptide as a diagnostic and therapeutic biomarker of small cell lung cancer. *J Thorac Dis*. 2016;8(9):2530–2537. doi:10.21037/jtd.2016.08.72

Cancer Management and Research

Dovepress

Publish your work in this journal

Cancer Management and Research is an international, peer-reviewed open access journal focusing on cancer research and the optimal use of preventative and integrated treatment interventions to achieve improved outcomes, enhanced survival and quality of life for the cancer patient. The manuscript management system is completely online and includes a very quick and fair peer-review system, which is all easy to use. Visit <http://www.dovepress.com/testimonials.php> to read real quotes from published authors.

Submit your manuscript here: <https://www.dovepress.com/cancer-management-and-research-journal>