




Superior Rectus Transposition in the Management of Duane Retraction Syndrome: Current Insights

Mithila Negalur ¹
Virender Sachdeva ²
Ramesh Kekunnaya ¹

¹Jasti V Ramanamma Children's Eye Care Centre, Child Sight Institute, L V Prasad Eye Institute, Hyderabad, India;

²Nimmagadda Prasad Children's Eye Care Centre, Child Sight Institute, L V Prasad Eye Institute, Vizag, India

Abstract: Various surgical approaches have been described for the management of Duane retraction syndrome (DRS), a type of congenital cranial dysinnervation disorder (CCDD), the goals of which include correcting the primary position deviation and abnormal head posture (AHP), minimizing globe retraction and overshoots and improving the ocular rotations. Vertical rectus transposition (VRT) is one such technique, found more effective in improving abduction and thereby expanding the field of binocular vision, as compared to horizontal muscle surgery. VRT, however, is associated with the risk of inducing vertical deviations and also poses a risk for development of anterior segment ischemia. To overcome these concerns, transposition of only the superior rectus to the lateral rectus was proposed and evaluated to reveal improvement in alignment, AHP and motility comparable to VRT but with lesser surgical time and fewer post-operative complications. With promising results in the management of DRS, superior rectus transposition (SRT) has been extensively studied and has evolved over the last decade with several modifications to further increase the efficiency and reduce the risk of post-operative complications. This article focusses on the pre-operative considerations while planning SRT in DRS, various approaches and surgical techniques described, and the outcomes and complications of SRT in DRS. The role of SRT in the management of other CCDDs may be explored with further studies.

Keywords: Duane syndrome, SRT, transposition surgery

Introduction

Various surgical approaches have been described for the management of Duane Retraction Syndrome (DRS). Goals of surgery for DRS include correcting the primary position deviation and abnormal head posture (AHP), minimizing globe retraction and overshoots and improving the ocular rotations, thereby enhancing the binocular field of vision.¹ Of the various approaches reviewed, vertical rectus transposition (VRT), both full or partial rectus muscle transposition, have shown to improve ocular alignment and AHP in esotropic DRS.^{2,3} Also, compared to the commonly performed horizontal muscle surgery, these are more effective in improving abduction and expanding the field of binocular single vision.⁴ However, VRT is associated with the risk of inducing a vertical deviation^{2,5} and also comes with a small risk of anterior segment ischemia, especially if concomitant horizontal rectus surgery is required.⁶

To overcome these concerns, Johnston et al in 2006 proposed performing only a superior rectus transposition (SRT) temporally to the lateral rectus (LR) in type 1 DRS and reported good results without inducing a significant vertical deviation.⁷ Mehendale et al reviewed the outcomes of this approach in patients with esotropic DRS and sixth

Correspondence: Ramesh Kekunnaya
Tel +91-40-68102645
Fax +91-40-23548271
Email rameshak@lvpei.org

nerve palsy. The improvement in alignment, AHP and abduction limitation was comparable to that achieved with VRT, and also had the advantages of a shorter surgical time and fewer post-operative complications.⁸

With promising results in the management of DRS, Superior rectus transposition (SRT) has been extensively studied and has evolved over the last decade with several modifications.

This article focusses on pre-operative considerations while planning SRT in DRS, various approaches and surgical techniques described, and the outcomes and complications of SRT in DRS.

Pre-Operative Considerations, Indications and Contra-Indications of SRT

The principles of performing SRT in a patient with DRS can be understood by revisiting the underlying etiopathology of DRS. DRS is a type of congenital cranial dysinnervation disorder (CCDD), characterised by the absence or hypoplasia of the abducens nerve along with misdirection of fibres from the oculomotor nerve to the lateral rectus.^{9,10} This paradoxical innervation leads to co-contraction of the horizontal rectus muscles, and based on its severity gives rise to varying amounts of globe retraction, overshoots and the different patterns of alignment and motility limitation.

A relatively straight forward surgical option to correct the primary position deviation and improve this co-contraction is recession of the tight and over-acting muscle. In most patients with esotropic DRS type 1, unilateral Medial Rectus (MR) recession has shown good results in correcting esotropia of up to 20 PD.^{11,12} Similarly, in patients with larger deviations and cases with bilateral esotropic DRS,¹³ good post-operative alignment has been reported following bimedial recession (5–6 mm), which in turn also aids in preventing MR contracture in the affected eye.¹⁴ However, MR recession does not lead to significant improvement in abduction,¹⁵ with minor improvement (up to grade 1) noted in about 28–30% of cases.^{12,16,17} In addition, large recessions of medial rectus, might in turn limit motility in its own field of action, and convert type I to type III DRS.⁹

On the contrary, as noted above, SRT leads to improvement in primary position deviation as well as abduction. However, it alters the muscle vector force leading to possibility of a new-onset vertical deviation⁴ and creates an additional

force towards the lateral rectus, which might result in a long-term exo-drift.¹⁷ Similarly, cases with significant co-contraction pre-operatively might also need tackling of the LR.¹⁸

Thus, indications and contraindications for SRT in DRS, summarized in Table 1, are as follows:

Indications

- 1. Primary procedure for unilateral Esotropic DRS without significant co-contraction (grade 2 or better as explained in Table 2).¹⁹ This is the primary and most common indication in DRS. Isolated SRT may be planned for small deviations when the MR is not significantly tight, while in moderate to large angle deviations, SRT may be combined with unilateral or bilateral MR recession.^{7,8,17}
- 2. Primary procedure for bilateral esotropic DRS especially in cases with severe abduction limitation and absence of significant globe retraction.²⁰
- 3. As a re-operation for residual esodeviation or residual AHP, in cases with residual AHP despite previous horizontal muscle surgery.²¹

Table 1 Indications and Contra-Indications for SRT in DRS

Indications
1. Primary surgery (+/- with MR recession) for uni/bilateral esotropic DRS without significant co-contraction (grade 2 or better)
2. To treat residual esotropia or residual AHP after MR recession
3. In cases where abduction limitation is more severe in upgaze than downgaze
4. Following LR inactivation for severe co-contraction
5. Nasal SRT in exotropic DRS
Contraindications:
Absolute:
1. Esotropic DRS with exotropia in adduction
2. Esotropic DRS with larger eso-deviation for near
3. In cases where abduction limitation is more severe in downgaze than upgaze
Relative:
1. Patients with significant co-contraction & overshoots (grade 3 or worse)
2. Patients with marked globe retraction & enophthalmos (grade 3 or worse)
3. Patients with significant hypertropia or intorsion
4. Patients with pre-existing hypotropia in attempted abduction

Abbreviations: SRT, Superior rectus transposition; DRS, Duane retraction syndrome; MR, Medial rectus; AHP, abnormal head posture; LR, Lateral rectus.

Table 2 Novel Grading Method for Retraction and Overshoot in DRS

Grading for globe retraction:	
With the involved eye in the maximum adducted position, the palpebral aperture height in the centre of the palpebral fissure is compared with that of the fellow eye in abduction.	Grade 0 No narrowing Grade 1 <25% Grade 2 25% to <50% Grade 3 50% to <75% Grade 4 ≥ 75%
Grading for overshoots:	
With the involved eye in adducted position, a straight line is drawn from the pupillary centre of the fellow eye, parallel to the intermedial canthal line.	Grade 0 Line bisects the pupil of the involved eye Grade 1 Line lies between pupillary centre and pupillary margin Grade 2 Line lies between pupillary margin and limbus Grade 3 Line lies at limbus or over sclera Grade 4 Cornea disappearing below the lid (pumpkin seed sign)

Notes: Data from Kekunnaya R, Moharana R, Tibrewal S, Chhablani PP, Sachdeva V.¹⁹

Abbreviation: DRS, Duane retraction syndrome.

- To treat cases where abduction limitation is more severe in upgaze than in downgaze (A pattern of motility).²²
- To improve alignment and enhance abduction following LR inactivation for severe co-contractions and overshoots in both esotropic as well as exotropic DRS.^{23–25}
- As a nasal transposition procedure to correct exodeviation and improve adduction in exotropic DRS. This is a relatively new indication with limited literature available making further studies necessary.²⁶

Contra-Indications

As discussed above, certain motility patterns might become worse following SRT. Therefore, SRT MUST be avoided or planned cautiously as described below:

- Patients with severe co-contraction and globe retraction (grade 3 or worse)¹⁹ as evidenced by overshoots and significant enophthalmos on attempted adduction.

- Esotropic DRS but with associated exotropia in adduction. This is suggestive of an associated tight LR and might have a tendency for post-operative diplopia in contralateral gaze.^{3,27}
- Esotropic DRS with larger eso-deviation for near. This indicates an underlying adduction deficiency which may worsen with SRT.^{20,27}
- In cases with severe globe retraction, as SRT may further increase the enophthalmos if the tight LR is not been addressed.^{22,28}
- In cases where abduction limitation is more severe in downgaze than in upgaze (V pattern of motility).²²
- Cases with pre-existing hypertropia or intorsion as they might be more likely to have post-operative diplopia following SRT.²⁹
- Cases with pre-existing hypotropia in attempted abduction as the weakening effect of SRT on elevation might worsen this phenomenon.

Surgical Techniques of SRT

The surgical technique of VRT with its variations has been described in detail for the management of patients with DRS and 6th nerve palsy.^{30,31}

SRT, however, involves transposing only the superior rectus (SR) muscle to the insertion of the lateral rectus muscle along the spiral of Tillaux (described further in detail), leaving the inferior rectus (IR) muscle untouched.

Prior to the surgery, ideally a forced duction test should be performed, especially in an awake, alert patient whenever possible to determine precisely where the restriction to abduction starts, indicating the motility improvement expected with the transposition.⁴ However, this is possible only in cooperative adults and older children.

Also, SRT may be planned alone or in combination with ipsilateral MRc (fixed or adjustable), with or without an augmentation suture and the technique is as described below.

Based on the surgeon's preference, a forniceal or limbal conjunctival incision is made between the superior and lateral rectus muscles and the SR is isolated. However, forniceal or limited paralimbal conjunctival incisions allow for good visualisation and surgical manipulations with much less dissection.

The SR muscle is secured using double armed 6–0 vicryl (polyglactin 910 suture) or non-absorbable suture according to the surgeon's preference. Its attachments to

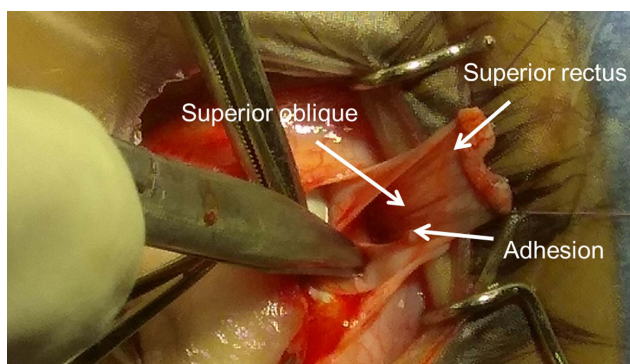


Figure 1 Figure showing the role of meticulous dissection to separate the superior rectus muscle from the underlying superior oblique muscle. This helps to minimize the risk of induced post-operative vertical deviations and ptosis.

the levator palpebrae superioris and the superior oblique (SO) tendon are observed by elevating the SR after disinsertion and these should be carefully dissected as shown in Figure 1. Meticulous dissection before transposition minimizes the risk of induced vertical deviations and ptosis due to dragging of the levator palpebrae superioris.³²

This dis-inserted SR is then attached adjacent to the superior border of the LR along the spiral of Tillaux. A temporary knot may be tied first and intra-operative forced duction test done to identify a tight SR. If restriction is observed to attempted infraduction, the SR may be recessed by up to 3 mm till it is relieved. The suture could then be permanently tied.^{3,4}

Techniques of Augmentation

In general, SRT procedure leads to an increase in the abducting capacity of the eye. This primarily results from mechanical effect due to change in the vector of the force generated by the eye. This overall leads to average correction of about 14 to 16 PD esotropia in the primary position.^{3,32} However, various other additional techniques (Table 3, Figure 2) have been described to augment the effect of the SRT.^{4,33,34} These are described in brief below.

Table 3 Various Strategies for Augmenting the Superior Rectus Transposition (SRT)

1. Posterior fixation suture
2. Suture myopexy
3. Multiple augmentation sutures
4. Resection of the superior rectus before transposition
5. Weakening of the medial rectus
6. Resection of the lateral rectus

1. Posterior scleral fixation suture (PFS) – In this technique, an augmentation suture (5–0 or 6–0 polyester) is passed 8–12 mm behind the lateral rectus insertion, incorporating one-fourth thickness of each of the superior and lateral rectus muscles and the underlying sclera, fixing the lateral one-fourth of the transposed SR muscle to the sclera.³²
2. Myopexy suture – In this technique, an augmentation suture (5–0 or 6–0 polyester) is passed 8–12 mm behind the lateral rectus insertion, incorporating one-fourth thickness of each of the superior and lateral rectus muscles and simply uniting the two muscles as a loop myopexy with no scleral pass.⁸
3. Multiple augmentation sutures - Magli et al²¹ also suggested that in cases with a more prominent face turn one may use two augmentation sutures, at 8 and 10 mm behind the LR insertion for better long term improvement after the SRT.
4. Resection of the muscle before transposition - Another technique of augmentation includes resecting the SR before transposing it (Brooks modification).³⁵

To provide further guidelines, Sener et al²² suggested resecting the SR by 2 mm for deviations up to 15 PD, by 3 mm in deviations ranging between 20–30 PD, and 3.5–4.0 mm resection in deviations greater than 35 PD. Sener et al further noted in their series that resections greater than 3.5 mm sometimes lead to an overcorrection, and therefore, recommend advancing the temporal border of the transposed SR by 1–2 mm underneath the upper border of LR, if further augmentation was deemed necessary.²²

1. Weakening of the ipsilateral medial rectus - This may be achieved either surgically by recessing the MR or pharmacologically using botulinum toxin.³⁴
2. Strengthening of the lateral rectus – This may be obtained by the muscle resection or preferably plication if significant LR activity is noted.³⁵

Modifications to Reduce the Risk of Induced Deviations

One of the issues with SRT, is the possibility of inducing a post-operative vertical deviation or incyclotropion, as it is considered to be an imbalanced transposition. In an attempt to reduce these risks and

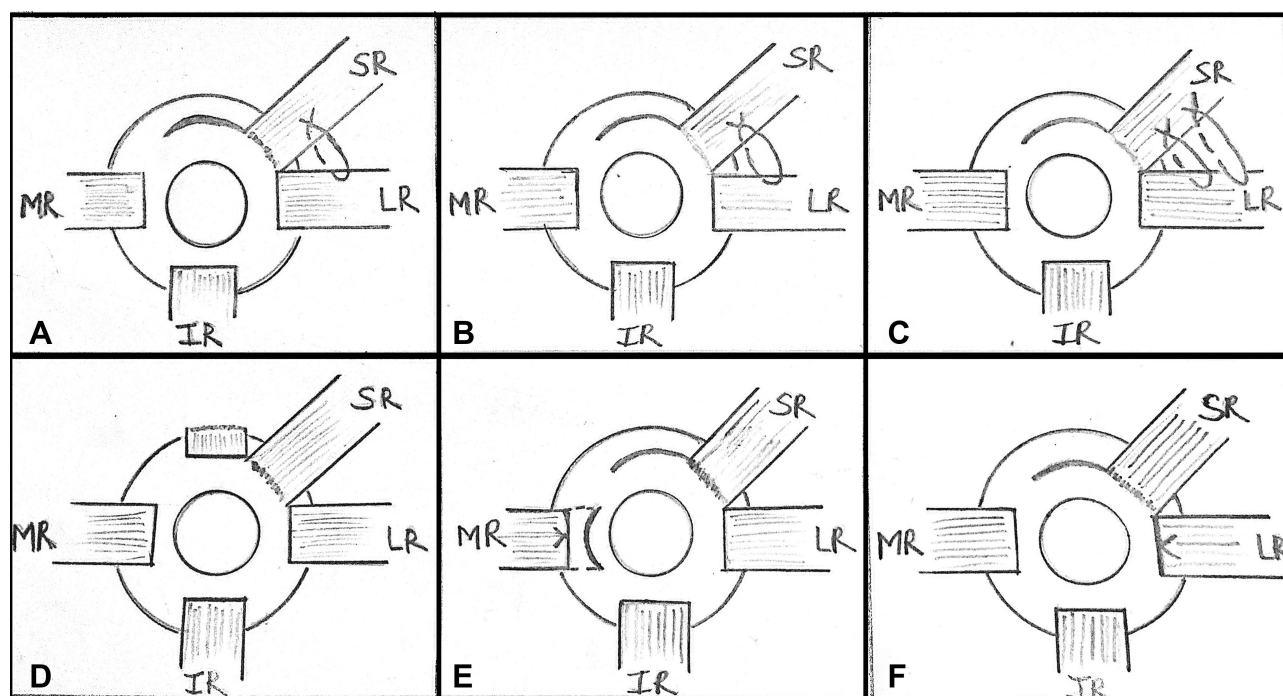


Figure 2 Various approaches for augmenting the superior rectus transposition (SRT). (A) Posterior fixation suture. (B) Suture myopexy. (C) Multiple augmentation sutures. (D) Resection of the superior rectus before transposition. (E) Weakening of the medial rectus. (F) Resection of the lateral rectus.

enhance safety of the procedure with more predictable outcomes, a few other surgical modifications have been described, as below:

Adjustable Posterior Fixation Myopexy

In 2018 Velez and Pineles³⁶ described a new technique for performing SRT with an adjustable posterior fixation myopexy suture under topical anaesthesia. In this technique, the border of the SR that is placed adjacent to the lateral rectus muscle is placed on an adjustable suture, following which a single-armed 6-0 vicryl suture is used on an adjustable suture to unite the superior and lateral rectus muscles, approximately 10 mm posterior to insertion of the LR, uniting the two muscles temporally. A cover test performed at this point can reveal any induced vertical deviation, which can then be managed by adjusting the myopexy suture till the deviation is corrected. Similarly, any overcorrection can be managed by releasing the myopexy suture, and if needed, adjusting the SR muscle suture till the deviation is corrected.

Intra-Operative Torsion Monitoring

The incidence of post-operative deviations may also be reduced by marking the 12 and 6o' clock positions at the limbus before beginning the procedure, and monitoring

intra-operative torsion as described by Holmes, Hatt and Leske.³⁷

Adjustable Graded Augmentation

In 2020, Dagi and Elhusseiny³⁸ reported an adjustable graded augmentation of SRT to reduce post-operative vertical or torsional diplopia. After completing an adjustable MR recession, this technique uses a corneal toric marker to denote the 6 and 12o' clock axis, extending the markings onto the skin and drapes. The SR is transposed adjacent to the LR along the spiral of Tillaux and any torsion induced is noted by correlating the corneal and skin markings. Following this, 2 or 3 augmentation myopexy sutures are sequentially taken uniting the SR and LR at 4 mm, 6 mm and 8 or 10 mm from the insertion, measuring the induced torsion with each suture. If the induced torsional change poses a risk of post-operative diplopia, the suture responsible for it is released intra-operatively. Post-operative vertical or torsional diplopia or induced overcorrection can be managed by sequentially releasing of the distal most augmentation suture.

Outcomes

The outcomes of any surgical procedure can be reviewed based on the goals it aims to achieve. Table 4 summarizes

Table 4 Table Outlining Results of Previous Studies Analysing Outcomes of SRT and MR Recession in Esotropic DRS

Study, Year	Eso DRS - Number of Patients	Surgical Intervention (Number of Patients)	Mean Change				Significant Complications (Number of Patients)
			ET (PD)	AHP (Degrees)	Abduction Deficiency (Units of Improvement)	Adduction deficit (unit)	
Mehendale, ⁸ 2012	10	SRT with or without augmentation+ MRc	27	21	2	0.6	Consecutive exotropia 1
Yang et al, ¹⁷ 2014	37	Augmented SRT ± MRc (19)	26	20	1.5	NA	Hypotropia 2
		Uni/Bilateral MRc (18)	10	16	0.5	0.7	
Velez, ⁴⁵ 2014	4	Augmented SRT ± MRc (4)	26	9.3	1.4	NA	Hypertropia 1, Hypotropia 3
Tibrewal, ³² 2015	21	Augmented SRT ± MRc (8)	17	12	1.2	1.1	–
		Uni/Bilateral MRc (13)	20	15	0.3	1.5	–
Akbari, ³⁹ 2018	11	Augmented SRT (11)	7.8	5.9	0.8	NA	Hypotropia 3
Agarwal, ⁴⁰ 2018	9	SRT ± MRc (9)	23.9	16	2	1	Residual esotropia 1
Abdallah, ²⁸ 2020	20	Augmented SRT ± MRc (10)	19.8	11	0.8	0.15	Hypertropia 2
		Unilateral MRc (10)	21.6	10.5	0.3	0.10	
Farid, ⁴¹ 2021	11	Augmented SRT ± MRc (11)	31.3	28.6	2	0.4	Hypertropia 2

Abbreviations: SRT, Superior rectus transposition; MR, Medial rectus; Eso, Esotropic; DRS, Duane retraction syndrome; MRc, Medial rectus recession.

the results of SRT as seen in various studies in DRS (including studies comparing SRT versus non-SRT groups in DRS).

Majority of the studies suggest that SRT leads to a good correction of the esotropia with an improvement in the AHP and abduction, without inducing significant post-operative vertical deviation.⁷

Mehendale et al⁸ later described their series of patients with esotropic DRS and chronic sixth nerve palsy, undergoing SRT augmented by a muscle union suture between the SR and LR and adjustable MR recession with good surgical outcomes, that were comparable to the results of VRT.

The authors reported the following major results in their study:

1. For patients with severe abduction limitation, SRT with MRc was preferable to isolated MRc, so as to have a smaller dose of MRc, thus decreasing the risk of adduction deficiency.
2. SRT however, was found to be more effective in correcting the binocular alignment in patients with 6th nerve palsy as compared to DRS.^{8,39}
3. In this study, the average dose effect for SRT was 7.8 ± 2.2 PD in the DRS group and 19.2 ± 4.6 PD in the sixth nerve palsy group.
4. Also, in cases where SRT was combined with MRc, an adduction limitation was noted in some patients in the DRS group, but none in the 6th nerve palsy group⁴⁰ which the authors hypothesized to be due to

the difference in the underlying etiopathology in both these disease entities.

Other studies comparing the results of augmented SRT with or without MR recession, with MR recession alone (unilateral or bilateral) for the treatment of esotropic DRS, found both these procedures to be equally effective for correction of the esotropia and the AHP.^{17,20,31} The SRT group, however, was more effective than the isolated MR recession group with regard to improving abduction (Figure 3). Improvement in abduction by at least 1 unit was seen in approximately 80–87% of patients with SRT versus 20–28% in those with MRc only. This was comparable to the outcomes with vertical rectus transposition, as seen in related studies.³² In addition, the amount of MRc performed when combined with SRT was lesser than that required with MRc alone (3.3mm in SRT vs 5.3 mm in MRc), thereby reducing the risk of post-operative adduction deficit.

Among these studies, Yang et al¹⁷ also found that the improvement in abduction was more prominent in elevation compared to depression possibly due to the direction of force of the transposed SR muscle. Hence, it has been suggested to prefer SRT in cases where limitation of abduction is more marked in elevation (A pattern).²²

Effect on Globe Retraction and Co-Contraction

Isolated SRT was noted to have variable results with respect to its effect on globe retraction, with improvement in some cases and worsening in others, though most studies included patients with only mild-moderate retraction of grade 2 or better.^{20–22,32} However, when MR recession was also performed, even in the absence of a very tight MR, improvement in the co-contraction has been noted.^{3,9}

Outcomes of Isolated SRT vs Combined with MR Recession

The decision to combine SRT with MRc would mainly depend upon the total deviation and the medial rectus tightness. While the response to surgery may vary with these aforementioned factors, studies recommend doing only SRT for patients having esotropia up to 15 PD,^{3,8,32} beyond which it is recommended to add an MR recession. Combination of MR recession and SRT was found to be effective in correcting up to 45 PD of esotropia. In addition, in these studies, MR recession was limited to less than 5–5.5 mm to prevent an adduction deficit.^{32,41}

Another consideration is that even if the MR is not very tight, recessing it has an added benefit of relieving some amount of co-contraction, thus contributing further to the surgical success.

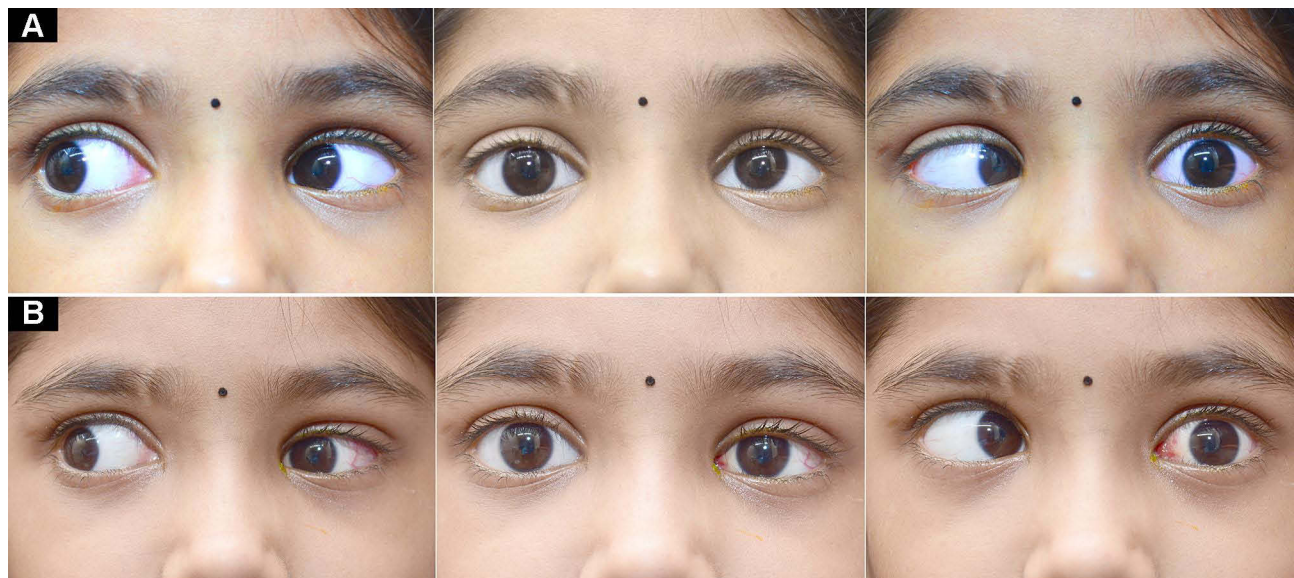


Figure 3 Surgical outcome of superior rectus transposition (SRT) in Duane retraction syndrome (DRS). **(A)** Pre-operative image showing primary position esotropia and –4 abduction limitation in the left eye in a case of esotropic Duane retraction syndrome. **(B)** Post-operative image showing improvement in both, primary position deviation and abduction limitation to –3 following SRT with medial rectus recession in the left eye.

Long-Term Eso-Drift v/s Exo-Drift

Yang et al¹⁷ reported a likelihood of long term undercorrection with isolated MR recession due to the inelastic, fibrotic nature of MR in DRS causing further contracture of the muscle, leading to slow eso-drift. Likewise, they cautioned, that due to the outward directed force of SRT, there can be a gradually progressive improvement in the eso-deviation and the AHP, posing a risk of late over-correction. Hence, they recommend that overcorrection must never be targeted in these patients. However, Akbari et al have also reported that long term eso-drift following augmented SRT with MR recession which can correct immediate post-operative exotropia if any.⁴² Therefore, at this point of time, most authorities recommend performing a small undercorrection for esotropic DRS, to avoid long term exodrift.

Outcomes of Bilateral SRT

Sachdeva et al²⁰ reported the outcomes of bilateral SRT in cases of bilateral esotropic DRS with improvement in alignment, comparable to that achieved with bilateral VRT and MRc, but the improvement in abduction was better with SRT than MRc. They recommend bilateral SRT with unilateral MRc in patients with esotropia of up to 25 PD and bilateral MRc in esotropia greater than 30 PD. However, one needs to remember that the deviation

measured in bilateral DRS is often secondary deviation and one should plan carefully to avoid overcorrection.

Outcomes of SRT as a Secondary Procedure

SRT has also been found to be an effective technique for re-surgery in esotropic DRS for those who have previously undergone unilateral/bilateral MRc, with a residual esotropia and anomalous head position. It resulted in improvement of esotropia, head turn and partial recovery of abduction in a significant percentage of patients (30%) with no post-operative vertical deviations.²¹

Nasal Transposition of the SR

Nasal transposition of the SR to the medial rectus for the management of exotropic DRS has been proposed to enhance the adduction of the eye in exotropic DRS. Schneider et al used nasal SRT in 2 patients with exotropic DRS and found this technique to improve eye motility and range of binocular single vision in these patients.²⁶ However, nasal SRT in a patient described by Mehendale et al⁸ (excluded from the study) caused intolerable torsional diplopia mandating reversal of the procedure. Thus, long-term safety and efficacy of nasal SRT for exotropic DRS is yet to be determined.

Table 5 Table Summarizing Post-Operative Complications of SRT and Preventive and Management Strategies

Complication	Prevention	Treatment
1. Induced vertical deviations (hypodeviation more common than hyperdeviation)	<ul style="list-style-type: none"> • Meticulous dissection to isolate SR, proper positioning and anchoring to sclera along the Spiral of Tillaux, placement of augmentation, and consistent surgical technique • Adjustable posterior fixation myopexy • Adjustable graded augmentation of SRT 	<ul style="list-style-type: none"> • Observation for asymptomatic cases • Prism glasses • Revision of SRT +/- removal of augmentation suture
2. Induced incyclotorsion	<ul style="list-style-type: none"> • Adjustable posterior fixation myopexy or graded augmentation of SRT 	<ul style="list-style-type: none"> • Most often clinically insignificant • May need surgical revision of SRT in severe and symptomatic cases
3. Consecutive exotropia	<ul style="list-style-type: none"> • Identify at risk cases pre-operatively (infants, exotropia in adduction, smaller esotropia at near) 	<ul style="list-style-type: none"> • Surgical revision of SRT if SR-LR complex is tight on FDT • If not, MR advancement could be planned
4. Adduction limitation	<ul style="list-style-type: none"> • Perform smaller MR recession when combining with SRT • Not exceed 5.5 mm of MR recession 	
5. Hypotropia in attempted abduction	<ul style="list-style-type: none"> • Identifying this finding pre-operatively to consider IRT instead of SRT 	<ul style="list-style-type: none"> • Observation mostly (as it is usually present pre-operatively due to dysinnervation)

Abbreviations: SR, Superior rectus; LR, Lateral rectus; MR, Medial rectus; SRT, Superior rectus transposition; IRT, Inferior rectus transposition.

Other Outcomes

Being an asymmetrical transposition with change in the direction of a vertical rectus muscle, there is a concern that SRT might cause new onset vertical deviations or lead to increased incyclotorsion. However, significant vertical or torsional misalignment has been noted infrequently following SRT and is described in detail in the next section.

Lastly, sensory outcomes of SRT have been studied using the Worth Four Dot test, Titmus fly test and Randot stereotest in co-operative patients.^{8,39} Post-operatively, none of the patients had a reduction in stereopsis and there was an increase in number of patients with fusion and stereopsis in esotropic DRS.

Complications

The post-operative complications of SRT in DRS (Table 5) are as described below:

Induced Vertical Deviations

Although SRT is an asymmetrical and potentially imbalanced transposition, vertical deviations causing diplopia have been noted infrequently. Escuder et al reported induced/new onset vertical deviation in 7% in 69 patients with DRS or 6th nerve palsy undergoing SRT.⁴³ Similarly, in the series by Sachdeva et al,²⁰ none of the patients undergoing bilateral SRT had any new onset vertical deviation in the primary position.

Both hypertropia^{28,44,45} and hypotropia^{8,17,41} have been observed following SRT, although there is a greater tendency for the development of hypodeviation. Escuder et al⁴³ observed that the onset of vertical diplopia was generally within the first few days or weeks after the surgery and did not develop beyond 3 months.

Mechanism of Induced Hypotropia

A hypotropia may be induced as the elevating force of SR is decreased by the transposition or if there is inadvertent advancement of the SO with the SR. Rarely, there may be intrinsic weakness of the orbital connective tissues causing slippage of the belly of the SR, causing it to align parallel to the LR, diminishing its vertical force.^{4,46}

Mechanism of Induced Hypertropia

On the other hand, the vertical action of SR may be strengthened after SRT due to its advancement when re-inserted along the spiral of Tillaux or due to dysinnervation of the muscles.⁴³ This can compensate the propensity

of the transposition to cause a hypodeviation or can even lead to hypertropia especially in a tight SR.

Management

Often, these vertical deviations are small and asymptomatic.^{17,45} However, some of these patients may require post-operative prism glasses or sometimes may need a revision of the transposition procedure or an ipsilateral IRT to treat the hypertropia.^{29,44,47}

Induced Cyclotorsion

Lateral transposition of the superior rectus muscle would also be expected to intort the eye, raising concern over induced torsional diplopia. While studies analysing torsion^{22,41,43,45} using double Maddox rod or by direct fundus observation, before and after SRT have reported post-operative intorsion, clinically significant torsional diplopia was nearly absent in these studies. This can be possibly explained by the patient's fusion capacity (<8 PD) or by modelling of the orbital forces to prevent diplopia. They also reported that the extent of induced torsion did not correlate with the use of augmentation or its technique, the pre-operative esotropic deviation or the post-operative vertical deviation, if any.⁴³

Vertical Misalignment in affected Lateral Gaze

Vertical misalignment in the affected lateral gaze has also been reported following SRT.^{8,40,41} Mehendale et al noted clinically insignificant hypotropia in attempted abduction in several cases after surgery. However, as explained by Rhiu et al,⁴⁸ this finding was present pre-operatively in all of them. This may be caused by a pre-existing dysinnervation leading to IR activation or SR relaxation in attempted abduction or due to the differential activation of the superior and inferior parts of the LR. As a result, post-operative hypertropia in lateral gaze has also been reported. All these patients have also been found to have a more severe abduction deficiency.

Consecutive Exotropia

Another concern with augmented SRT is the development of consecutive exotropia, especially when combined with MRc. Some of the risk factors that may lead to overcorrection include preoperative exotropia in attempted adduction, smaller esodeviation at near and lesser MR restriction on forced duction.²⁷ Studies have also reported

significant overcorrection in those undergoing SRT at a younger age (operated at 10 months,⁴⁵ 1 year⁸ and 4 years⁴¹). Hence some may suggest avoiding surgery in DRS in patients under 1 year of age unless absolutely necessary for development of fusion.³

These cases could be a result of either over recession of the medial rectus and an excessive correction from Transposition. These patients need early intervention (preferably within 1–2 weeks), forced duction test on the table for a tight SR-LR complex or a lax medial rectus. If the medial rectus is lax and FDT is negative, MR can be advanced. On the contrary, if the MR is normal, and SR-LR complex is tight, a staged procedure with the release of the posterior fixation suture and recession of the SR can be done.

To avoid this, many authorities recommend performing medial rectus recession on an adjustable suture.

Post-Operative Adduction Limitation

Post-operative adduction limitation affecting the binocular field of single vision has also been reported following SRT when combined with large MRc for esotropic DRS.^{17,28,32} Hence MR recession more than 5–5.5 mm should be avoided when combining with SRT.

Considerations for Inferior Rectus Transposition (IRT)

While SRT has been shown to have its advantages over horizontal muscle surgery in DRS, it may not be suitable and might even adversely affect the outcomes in certain situations like pre-existing incyclotropia or hypertropia.²⁹

Hence inferior rectus transposition (IRT) has been studied as a possible surgical option in such cases. These include:

1. Esotropic DRS with pre-existing hypertropia or incyclotropia.²⁹
2. Esotropic DRS where abduction in depression is worse than primary position or in elevation (V pattern of motility).²²
3. As a secondary procedure to correct residual esotropia following SRT.⁸

The surgical technique of IRT involves steps similar to SRT.⁴ When isolating the IR for the transposition, it is equally important to thoroughly separate the capsulopalpebral fascial attachments to the IR to prevent vertical

deviations or distortion of the lower lid. After transposition, the insertion of the inferior rectus muscle is placed along the spiral of Tillaux, between the lower edge of the lateral rectus muscle and the temporal edge of inferior rectus muscle insertions. Augmentation of this transposition has been studied using a posterior fixation suture²⁹ and by partial resection of the IR (2–4 mm) before reinserting it.²²

Sener et al²² studied the outcomes of primary IRT in esotropic DRS and found that the mean esotropic correction was 18.5 PD with a reduction in face turn and a mean improvement in abduction by 1.4 units. The V pattern of motility also improved following IRT. However, while 2 cases developed residual esotropia, 2 developed post-operative hypertropia (one of these had a prior MR recession and also developed consecutive exotropia). IRT has also been found to further improve the primary position esotropia when used as a secondary procedure following SRT.^{8,47} However, further studies with longer follow-ups are needed to determine the long-term safety and efficacy of this procedure.

Conclusions

Thus, SRT is an efficient transposition technique to correct primary position deviation, AHP and improve abduction in esotropic DRS, yet is safer and less time consuming than VRT. However, the complex etiopathology of DRS and its diverse clinical presentations must be kept in mind while opting for this procedure and it should be planned carefully especially in the younger age group. Further studies investigating the outcomes of SRT in exotropic DRS and its role in the management of other CCDDs as well may be explored.

Disclosure

Dr Virender Sachdeva reports being principal investigator for the QRK 207 trial; A PHASE 2/3, RANDOMIZED, DOUBLE-MASKED, SHAM-CONTROLLED TRIAL OF QPI-1007 DELIVERED BY SINGLE OR MULTI-DOSE INTRAVITREAL INJECTION(S) TO SUBJECTS WITH ACUTE NONARTERITIC ANTERIOR ISCHEMIC OPTIC NEUROPATHY (NAION), grants from HABRI grant, outside the submitted work. The authors report no other conflicts of interest in this work.

References

1. Kekunnaya R, Kraft R, Rao VB, Velez FG, Sachdeva V, Hunter DG. Surgical management of strabismus in Duane retraction syndrome. *J AAPOS*. 2015;19:63–69. doi:10.1016/j.jaapos.2014.10.019

2. Velez FG, Foster RS, Rosenbaum AL. Vertical rectus muscle augmented transposition in Duane syndrome. *J AAPOS*. 2001;5:105–113. doi:10.1067/mpa.2001.112677
3. Doyle JJ, Hunter DG. Transposition procedures in Duane retraction syndrome. *J AAPOS*. 2019;23(1):5–14. doi:10.1016/j.jaapos.2018.10.008
4. Rosenbaum AL. Costenbader lecture: the efficacy of rectus muscle transposition surgery in esotropic Duane syndrome and VI nerve palsy. *J AAPOS*. 2004;8:409–419. doi:10.1016/j.jaapos.2004.07.006
5. Ruth AL, Velez FG, Rosenbaum AL. Management of vertical deviations after vertical rectus transposition surgery. *J AAPOS*. 2009;13:16–19. doi:10.1016/j.jaapos.2008.08.015
6. Pineles SL, Chang MY, Oltra EL, et al. Anterior segment ischemia: etiology, assessment, and management. *Eye*. 2018;32(2):173–178. doi:10.1038/eye.2017.248
7. Johnston SC, Crouch ER Jr, Crouch ER. An innovative approach to transposition surgery is effective in treatment of Duane's syndrome with esotropia. *Invest Ophthalmol Vis Sci*. 2006;47:2475.
8. Mehendale RA. Superior rectus transposition and medial rectus recession for Duane syndrome and sixth nerve palsy. *Arch Ophthalmol*. 2012;130(2):195–201. doi:10.1001/archophthol.2011.384
9. DeRespinis P, Caputo A, Wagner R, et al. Duane's retraction syndrome. *Surv Ophthalmol*. 1993;38:257–288. doi:10.1016/0039-6257(93)90077-K
10. Parsa CF, Grant E, Dillon WP Jr, et al. Absence of the abducens nerve in Duane syndrome verified by magnetic resonance imaging. *Am J Ophthalmol*. 1998;125(3):399–401. doi:10.1016/S0002-9394(99)80158-5
11. Kraft SP. Surgery for Duane's syndrome. *Am Orthopt J*. 1993;43:18–26.
12. Kaban TJ, Smith K, Day C, et al. Single medial rectus recession in unilateral Duane syndrome type I. *Am Orthopt J*. 1995;45(1):108–114. doi:10.1080/0065955X.1995.11982051
13. Sachdeva V, Kekunnaya R, Gupta A, Bhoompally VR. Surgical management of bilateral esotropic Duane syndrome. *J AAPOS*. 2012;16(5):445–448. doi:10.1016/j.jaapos.2012.06.008
14. Wilcox LM, Gittinger JW, Breinin GM. Congenital adduction palsy and synergistic divergence. *Am J Ophthalmol*. 1981;91(1):1–7. doi:10.1016/0002-9394(81)90342-1
15. Natan K, Traboulsi EI. Unilateral rectus muscle recession in the treatment of Duane syndrome. *J AAPOS*. 2012;16(2):145–149. doi:10.1016/j.jaapos.2011.11.012
16. Merino P, Merino M, Gómez De Liaño P, Blanco N. Horizontal rectus surgery in Duane syndrome. *Eur J Ophthalmol*. 2012;22(2):125–130. doi:10.5301/ejo.5000002
17. Yang S, MacKinnon S, Dagi LR, Hunter DG. Superior rectus transposition vs medial rectus recession for treatment of esotropic Duane syndrome. *JAMA Ophthalmol*. 2014;132:669–675. doi:10.1001/jamaophthol.2014.358
18. Farid MF. Y-split recession vs isolated recession of the lateral rectus muscle in the treatment of vertical shooting in exotropic Duane retraction syndrome. *Eur J Ophthalmol*. 2016;26(6):523–528. doi:10.5301/ejo.5000746
19. Kekunnaya R, Moharana R, Tibrewal S, Chhablani PP, Sachdeva V. A simple and novel grading method for retraction and overshoot in Duane retraction syndrome. *Br J Ophthalmol*. 2016;100(11):1451–1454. doi:10.1136/bjophthol-2016-309194
20. Sachdeva V, Jain M, Badakere A, Kekunnaya R. Bilateral augmented superior rectus transposition with medial rectus recession for bilateral esotropic Duane retraction syndrome. *J AAPOS*. 2021;S1091-8531(21)-00020-3.
21. Magli A, Rombetto L, Esposito Veneruso P. Reoperation in esotropic Duane retraction syndrome: long-term motor outcome of superior rectus transposition. *Eur J Ophthalmol*. 2021;31(2):722–726. doi:10.1177/1120672119897889
22. Sener EC, Yilmaz PT, Fatihoglu ÖU. Superior or inferior rectus transposition in esotropic Duane syndrome: a longitudinal analysis. *J AAPOS*. 2019;23(1):21.e1–21.e7. doi:10.1016/j.jaapos.2018.10.010
23. Velez FG, Thacker N, Britt MT, Alcorn D, Foster RS, Rosenbaum AL. Rectus muscle orbital wall fixation: a reversible pro-found weakening procedure. *J AAPOS*. 2004;8:473–480. doi:10.1016/j.jaapos.2004.06.011
24. Britt MT, Velez FG, Thacker N, Alcorn D, Foster RS, Rosenbaum AL. Surgical management of severe cocontraction, globe retraction, and pseudo-ptosis in Duane syndrome. *J AAPOS*. 2004;8(4):362–367. doi:10.1016/j.jaapos.2004.04.004
25. Sharma P, Tomer R, Menon V, Saxena R, Sharma A. Evaluation of periosteal fixation of lateral rectus and partial VRT for cases of exotropic Duane retraction syndrome. *Indian J Ophthalmol*. 2014;62:204–208. doi:10.4103/0301-4738.121145
26. Schneider JL, Crouch ER Jr, Crouch ER III. An innovative approach to transposition surgery is effective in treatment of type III Duane's syndrome. *Invest Ophthalmol Vis Sci*. 2010;51:E- Abstract 3012.
27. Velez FG, Laursen JK, Pineles SL. Risk factors for consecutive exotropia after vertical rectus transposition for esotropic Duane retraction syndrome. *J AAPOS*. 2011;15:326–330. doi:10.1016/j.jaapos.2011.05.006
28. Abdallah MEI, Eltoukhi EM, Awadein AR, Zedan RH. Superior rectus transposition with medial rectus recession versus medial rectus recession in esotropic Duane retraction syndrome. *J Pediatr Ophthalmol Strabismus*. 2020;57(5):309–318. doi:10.3928/01913913-20200506-02
29. Velez FG, Chang M, Pineles SL. Inferior rectus transposition: a novel procedure for abducens palsy. *Am J Ophthalmol*. 2017;177:126–130. doi:10.1016/j.ajo.2017.02.021
30. Akar S, Gokyigit B, Pekel G, Demircan A, Demirok A. Vertical muscle transposition augmented with lateral fixation (foster) suture for Duane syndrome and sixth nerve palsy. *Eye*. 2013;27(10):1188–1195. doi:10.1038/eye.2013.167
31. Britt MT, Velez FG, Thacker N, Alcorn D, Foster RS, Rosenbaum AL. Partial rectus muscle-augmented transpositions in abduction deficiency. *J AAPOS*. 2003;7(5):325–332. doi:10.1016/S1091-8531(03)00180-0
32. Tibrewal S, Sachdeva V, Hasnat Ali M, Kekunnaya R. Comparison of augmented superior rectus transposition with medial rectus recession for surgical management of esotropic Duane retraction syndrome. *J AAPOS*. 2015;19:199–205. doi:10.1016/j.jaapos.2015.02.006
33. Foster RS. Vertical muscle transposition augmented with lateral fixation. *J AAPOS*. 1997;1(1):20–30. doi:10.1016/S1091-8531(97)90019-7
34. Wright KW. Transposition surgery for rectus muscle palsy. In: *Color Atlas of Strabismus Surgery: Strategies and Techniques*. 2nd ed. New York: Springer; 2007:164–165.
35. Brooks SE, Olitsky SE, Ribeiro GD. Augmented hummelsheim procedure for paralytic strabismus. *J Pediatr Ophthalmol Strabismus*. 2000;37:189–195. doi:10.3928/0191-3913-20000701-04
36. Velez FG, Pineles SL. Adjustable posterior fixation suture technique in adjustable superior rectus transposition. *J Binocul Vis Ocul Motil*. 2018;68(4):154–155. doi:10.1080/2576117X.2018.1529452
37. Holmes JM, Hatt SR, Leske DA. Intraoperative monitoring of torsion to prevent vertical deviations during augmented vertical rectus transposition surgery. *J AAPOS*. 2012;16(2):136–140. doi:10.1016/j.jaapos.2011.11.010
38. Dagi LR, Elhusseiny AM. Adjustable graded augmentation of superior rectus transposition for treatment of abducens nerve palsy and Duane syndrome. *J AAPOS*. 2020;24(5):268.e1–268. doi:10.1016/j.jaapos.2020.05.013
39. Akbari M, Shomali S, Mirmohammadsadeghi A, Aghsaei Fard M. Augmented superior rectus transposition procedure in Duane retraction syndrome compared with sixth nerve palsy. *Graefes Arch Clin Exp Ophthalmol*. 2018;256:983–987. doi:10.1007/s00417-017-3885-5

40. Agarwal R, Sharma M, Saxena R, Sharma P. Surgical outcome of superior rectus transposition in esotropic Duane syndrome and abducens nerve palsy. *J AAPOS*. 2018;22:12–16. doi:10.1016/j.jaapos.2017.10.004
41. Farid MF, Daifalla AEM, Awwad MA. Augmented superior rectus muscle transposition in management of defective ocular abduction. *BMC Ophthalmol*. 2021;21(1):50. doi:10.1186/s12886-020-01779-1
42. Akbari MR, Masoumi A, Mirmohammadsadeghi A. Superior rectus transposition and medial rectus recession for treatment of Duane retraction syndrome and sixth nerve palsy. *J Binocul Vis Ocul Motil*. 2021;71(2):45–49. doi:10.1080/2576117X.2021.1879985
43. Escuder AG, Kazlas MA, Heidary G, Hunter DG, Zurakowski D, Dagi LR. Incidence of symptomatic vertical and torsional diplopia after superior rectus transposition for esotropic Duane syndrome and abducens nerve palsy. *J AAPOS*. 2020;24(5):270.e1–270.e5. doi:10.1016/j.jaapos.2020.05.014
44. Merino P, de Liaño PG, Kim YA. Complications of augmented superior rectus transposition in Duane syndrome. *Arch Soc Esp Ophthalmol*. 2017;92(4):175–177. doi:10.1016/j.oftal.2016.07.003
45. Velez FG, Oltra E, Isenberg SJ, Pineles SL. Assessment of torsion after superior rectus transposition with or without medial rectus recession for Duane syndrome and abducens nerve palsy. *J AAPOS*. 2014;18(5):457–460. doi:10.1016/j.jaapos.2014.06.008
46. Tibrewal S, Pehere N, Sachdeva V, Kekunnaya R. Inferior oblique transposition for large hypertropia after vertical rectus transposition. *J AAPOS*. 2013;17(3):312–314. doi:10.1016/j.jaapos.2012.12.154
47. Liu Y, Wen W, Zou L, et al. Application of SRT plus MR recession in supra-maximal esotropia from chronic sixth nerve palsy. *Graefes Arch Clin Exp Ophthalmol*. 2018;4:1–7.
48. Rhiu S, Michalak S, Phanphruk W, Hunter DG. Anomalous vertical deviations in attempted abduction occur in the majority of patients with esotropic Duane syndrome. *Am J Ophthalmol*. 2018;195:171–175. doi:10.1016/j.ajo.2018.07.046

Clinical Ophthalmology

Dovepress

Publish your work in this journal

Clinical Ophthalmology is an international, peer-reviewed journal covering all subspecialties within ophthalmology. Key topics include: Optometry; Visual science; Pharmacology and drug therapy in eye diseases; Basic Sciences; Primary and Secondary eye care; Patient Safety and Quality of Care Improvements. This journal is indexed on PubMed

Central and CAS, and is the official journal of The Society of Clinical Ophthalmology (SCO). The manuscript management system is completely online and includes a very quick and fair peer-review system, which is all easy to use. Visit <http://www.dovepress.com/testimonials.php> to read real quotes from published authors.

Submit your manuscript here: <https://www.dovepress.com/clinical-ophthalmology-journal>