


Characterization of Sonic Hedgehog/Gli1 Signal Expression in Human Ureter Either Un-Stented or Fitted with Double-Pigtail Stent or a Thread

Benoît Vogt¹
Ilham Chokri²

¹Department of Urology, Polyclinique de Blois, La Chaussée Saint-Victor, 41260, France; ²Laboratory of Anatomocytopathology, Laboratoire Léonard de Vinci, Chambray-lès-Tours, 37170, France

Introduction: The Sonic Hedgehog/Gli1 signal is involved in smooth muscle activity. An experiment showed that the double-pigtail stent caused ureteral inflammation and decreased Gli1 expression in smooth muscle cells. The innovative pigtail-suture stent (JFil[®] or MiniJFil[®]) with a thin 0.3F suture thread significantly decreased stent-related symptoms. Fortuitously, a dilation of the ureter containing the sutures was discovered, and a previous study confirmed that the sutures caused less ureteral inflammation than the double-pigtail stent. However, the mechanisms involved in the ureteral dilation are still unknown. In this study, we assessed ureteral Gli1 expression in the human ureter when it was un-stented or when fitted with a double-pigtail stent or a suture thread.

Material and Methods: After consent and inclusion of patients in the protocol, nine segments of ureters were collected during cystectomy procedures for bladder cancers. There was no selection or exclusion, and patients with large tumors were included. Gli1 expression was assessed on the histological section to control the reflection of an active hedgehog signal. The expression of Gli1 in smooth muscle cells of the stented ureter was subjectively compared to un-stented ureter.

Results: A decrease in the intensity of Gli1 expression of smooth muscle cells was observed in all cases of ureter fitted with a double-pigtail stent. For the un-stented ureters and the ureters fitted with the thin 0.3F suture thread, Gli1 staining of smooth muscle cells was heterogeneous, and the small number of cases did not allow us to conclude.

Conclusion: Apart from the cases of ureters fitted with the double-pigtail stent, Gli1 expression of smooth muscle was heterogeneous. The Shh/Gli1 pathway may not be involved in ureteral dilation by the thread. A broader exploration of molecular mechanisms could make it possible to obtain the mechanisms involved in the dilation of the ureter by the thread.

Keywords: Sonic Hedgehog, suture, thread, ureter, ureteral stent, pigtail-suture stent

Introduction

Double-pigtail stents are frequently implanted in the ureter in urological practice. There are few studies on the interactions between the ureteral stent and the ureter, especially the human one.

In a preliminary study, we assessed ureteral inflammation in the human ureter when it was healthy or when fitted with a double-pigtail stent or a thread.¹ The study confirmed that a marked ureteral inflammatory reaction was observed in all cases of ureter fitted with a double-pigtail stent and that the thin 0.3F suture thread caused less ureteral inflammation.

Correspondence: Benoît Vogt
Department of Urology, Polyclinique de Blois, 1 rue Robert Debré, La Chaussée Saint-Victor, 41260, France
Tel +33 663220844
Fax +33 254906566
Email message@benoitvogt.fr

Other studies showed that a marked ureteral inflammatory reaction was also observed with a double-pigtail stent in the ureter of pigs.^{2,3}

The pigtail-suture stent (JFil[®] or MiniJFil[®]) was developed as a means of decreasing urinary symptoms.^{4,5} Fortuitously, we discovered that the sutures had surprising properties, and a clear dilation of the ureter without inflammation was observed around the suture.⁴ However, the mechanisms involved in the ureteral dilation are still unknown. The pelvic pressure does not appear to be crucial because there were no significant differences in pelvic or ureteral pressure between suture and double-pigtail stented systems in pigs.² This suggests that other mechanisms may lead to ureteral dilation.

Natalin et al suggested that ureteral stents disrupt ureteral peristalsis and produce hydronephrosis with a dilation of the ureter in pigs. Reduction of ureteric peristalsis persisted during stenting, reflecting maintained ureteric inflammation due to stent presence.⁶

Another study focused on the understanding of the effects of double-pigtail stent on ureteral physiology and its function in pigs.⁷ The authors decided to investigate ureteral inflammation and expression of Sonic Hedgehog (Shh) and Gli1 in mediating ureteral stent-induced aperistalsis. Shh is a protein within the Hedgehog family of growth factors. Gli1 is the primary target of Hedgehog pathway activation and serves as a reliable indicator of Hedgehog signaling.⁵

The authors were interested in Shh signaling because inactivating Shh in the mouse fetus resulted in hydroureter and overall aperistalsis.⁸ Moreover, Shh signaling was important in regulating injury repair and wound healing after tissue damage.⁹

In their works, a loss of Gli1 expression in smooth muscle cells, with a concomitant increase in ureteral inflammation, was observed in animals fitted with double-pigtail stent. The authors concluded that the study is the first to show that indwelling stents negatively affect ureteral smooth muscle activity and identify a role for the specific molecular mechanisms involved.⁷

In the present study, the objective was to estimate Gli1 expression in the human ureter when it was un-stented or when fitted with a double-pigtail stent or a thread.

Materials and Methods

The study design has been approved by French Ethical Committee (2017.09.02 bis). From September 2017 to December 2018 in a single institution, nine patients about

to have a cystectomy with ileal conduit urinary diversion agreed to be included in the protocol and signed an informed consent form. There was no selection or exclusion, and all patients were included, even those with large tumors.

If gathering a human ureteral segment fitted with a double-pigtail stent is feasible, it is exceptionally rare for a ureter with a thin thread. In urological practice, cystectomy with removal of a part of the ureter is the only pathology to obtain a ureteral segment fitted with a thread. The analysis of the ureters fitted with a thread can be altered by the presence of a pelvic tumor. To avoid a bias, the comparison with un-stented or stented ureters was made with patients who also had a pelvic tumor.

The MiniJFil[®] stent was previously described in other studies.^{4,10} In the procedure, two 0.3 F sutures were used to extend a simple renal loop, and the ureter was fitted exclusively with the threads. Patients requiring no ureteral drainage served as un-stented ureter controls. Patients requiring ureteral drainage for obstructive ureteral orifice were fitted with a 7 F double-pigtail stent. Patients without ureteral obstruction but requiring cystoscopic control before cystectomy were fitted with a MiniJFil[®] with the aim of facilitating the suture of the dilated ureter in the ileal conduit urinary diversion.

Nine segments of ureters were gathered during cystectomy. The collection of ureters was prospective, but the choice of Gli1 was guided by the study of Janssen et al. The authors studied the relation between ureteral peristalsis and Gli1. Since Gli1 was involved in the contractions of smooth muscles, it seemed interesting to test Gli1 in human in ureters fitted with different stent shapes.

Ureters were fixed in 4% formalin, embedded in paraffin, serially cut, and stained with hematoxylin–eosin. Nine segments were stained with Gli1. Immunohistochemical staining was conducted by Ventana Autostainer model Discover XT (Ventana Medical System, Tuscan, AZ) using Gli1 polyclonal antirabbit antibody (1/200) (Abcam ab151796) with detection by standard secondary biotin-labeled anti-rabbit IgG/avidin-peroxidase/3,3'-diaminobenzidine (DAB) staining. All histologic analyses were performed by an experienced pathologist.

The expression of Gli1 in smooth muscle cells of the stented ureter was subjectively compared to un-stented ureter, and ureteral segments were too few to be statistically considered.

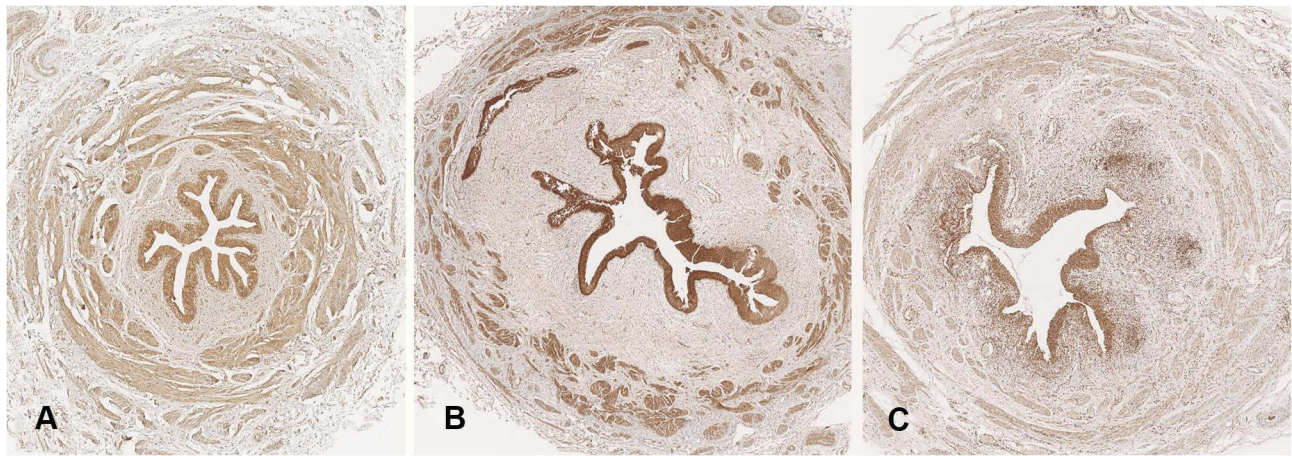


Figure 1 Histological appearance with Gli1 staining (Original magnification $\times 3$). (A) Un-stented control ureter. (B) Ureter with 0.3 F suture thread. (C) Ureter with the double-pigtail stent.

Results

Nine patients had bladder cancer (6 patients) and bladder sarcoma (3 patients).

Three patients had no ureteral obstruction and did not require drainage with a stent. They were evaluated as a control group. In three patients, an obstruction was located in the ureteral orifice, and these patients were fitted with an indwelling 7F double-pigtail stent 1 to 2 months before cystectomy. Three patients were fitted with the MiniJFil[®] during control cystoscopy two weeks before cystectomy.

All ureteral segments of ureters were iliac and were gathered during cystectomy. No tumor was observed on these ureteral segments.

Of the three un-stented control segments, Gli1 staining of smooth muscle cells was truly perceptible in two cases (Figures 1A and 2A).

In the ureter fitted with the thin 0.3F suture thread, Gli1 staining of smooth muscle cells was truly preserved in one case (Figures 1B and 2B) but seemed to have decreased in the other cases compared to the most stained control.

For the un-stented ureters and the ureters fitted with the thin 0.3F suture thread, the small number of cases did not allow us to conclude. However, a decrease in the intensity of Gli1 staining of smooth muscle cells was observed in all cases of ureter fitted with a double-pigtail stent (Figures 1C and 2C).

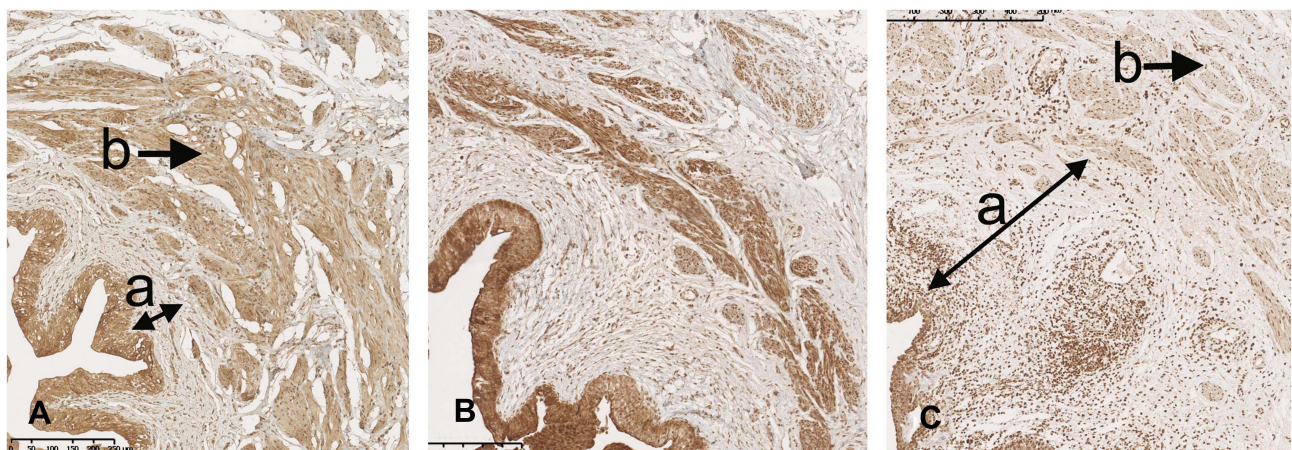


Figure 2 Histological appearance with Gli1 staining (Original magnification $\times 7$). (A) Un-stented control ureter. (B) Ureter with 0.3 F suture thread. (C) Ureter with the double-pigtail stent showing a decrease in the intensity of Gli1 expression of smooth muscle cells. Arrow (a) shows marked ureteral inflammation reaction and pronounced submucosal edema, and arrow (b) shows weak positive Gli1 staining in stented ureter compared to un-stented ureter.

Discussion

In the control, only two cases showed truly perceptible Gli1 expression of smooth muscle cells. Apart from the cases of ureters fitted with the double-pigtail stent, the results seem heterogeneous. However, the small number of patients, the heterogeneity of bladder diseases, and edematous infiltration due to the tumor mass burden may explain the variations observed. Janssen et al already pointed out that Gli1 expression of smooth muscle cells was sometimes similar between stented and contralateral un-stented sides or different between un-stented controls and the contralateral un-stented sides of stented animals. The authors suggested some level of cross talk between the two sides that requires further investigation.⁷

Moreover, Shh/Gli1 pathway has been implicated in the tumorigenesis of a large number of human tumors. But the role of Shh signaling in bladder cancer remains controversial.¹¹ Indeed, Sverrisson et al indicated that Gli1 expression may be a marker of low-stage and low-grade bladder tumors.¹² On the contrary, He et al found that the positive expression of Gli1 was correlated with pathological stage, venous invasion and lymph node metastasis. In addition, the authors confirmed that the expression of Gli1 was seen in normal tissues around the bladder cancer but was greater in bladder cancer tissues.¹¹

Janssen et al found that 6F double-pigtail stent induced severe ureteral dilation with scuffed epithelium in pigs that increased with indwelling time.⁷ In the present study in humans, no major dilation was observed. The gross ureteric circumferential measurements reached 4.6 mm with a 6F double-pigtail stent in pigs.⁶ The native diameter of the ureter of the pig may be much lower than that of man, thus making the dilation more moderate in man and producing excessive ureteral overstretching in the pig.

In previous studies, it turned out that the double-pigtail stent induced ureteral inflammation in all cases.^{1–3} Decreased Gli1 expression in stented ureteral smooth muscle cells was observed in all cases in the present study and in the study of Janssen et al.⁷ Thus, it appears that ureteral inflammation and the decrease in Gli1 were associated. Janssen et al suggested that the decrease in Gli1 expression of smooth muscle was unexpected, just as in the case of tissue damage, and Shh/Gli1 signaling should mediate tissue repair.⁷ Conversely, Shh signaling was induced during renal fibrosis in a mouse model of obstructive nephropathy, and inhibition of Gli1 expression mitigated renal fibrotic lesions.⁹ Consequently, the Shh/Gli1 signal is

a complex process, and as Janssen et al suggested, improving our understanding of specific molecular mechanisms leading to stent-associated ureteral dysfunction may identify targets for future therapeutic agents. Thereby, the functionality of the stented ureter may be improved, stent-related symptoms may be decreased and passage of stone fragments around the stent may be facilitated.⁷

There were several limitations to the present study. First, the small number of patients did not allow us to conclude and requires more targeted studies, but if gathering ureteral segment fitted with a double-pigtail stent is easy, it is exceptionally rare for a ureter with a thin thread. Second, the heterogeneity of the bladder diseases may explain the heterogeneity of the results. Third, the Shh/Gli1 pathway may not be involved in ureteral dilation by the thread.

Conclusions

Apart from the cases of ureters fitted with the double-pigtail stent, Gli1 expression of smooth muscle was heterogeneous. The small number of patients did not allow us to conclude. The Shh/Gli1 pathway may not be involved in ureteral dilation by the thread, but the present study is an open door for further research by testing specific molecular mechanisms involved in smooth muscle contractions. A broader exploration of molecular mechanisms could make it possible to obtain the mechanisms involved in the dilation of the ureter by the thread of the pigtail-suture stent.

Abbreviations

Shh, Sonic Hedgehog.

Ethics Approval and Informed Consent

All procedures performed in studies involving human participants were in accordance with the ethical standards of the institutional and/or national research committee (French Ethical Committee: 2017.09.02 bis) and with the 1964 Helsinki Declaration and its later amendments or comparable ethical standards. Written informed consent and accompanying images published were obtained from the patients included in the study.

Acknowledgments

I thank Professor Janine Dove-Rum , English Department at the University of Tours, for re-reading the text.

Author Contributions

All authors made substantial contributions to conception and design, acquisition of data, or analysis and interpretation of data; took part in drafting the article or revising it critically for important intellectual content; agreed to submit to the current journal; gave final approval of the version to be published; and agreed to be accountable for all aspects of the work.

Disclosure

Benoît Vogt received royalties from Rocamed for the treatment of ureteral stones but there are no financial competing interests in the manuscript. The authors report no other conflicts of interest in this work.

References

1. Vogt B, Chokri I. Histological inflammation in human ureter either healthy or fitted with double-pigtail stent or a thin 0.3 F suture thread: a preliminary study. *Adv Urol*. 2020;2020:1204897. doi:10.1155/2020/1204897
2. Majdalany SE, Aldoukhi AH, Jung H, Mehra R, Roberts WW, Ghani KR. In vivo evaluation of a novel pigtail suture stent. *Urology*. 2021;148:83–87. doi:10.1016/j.urol.2020.11.031
3. Soria F, de la Cruz JE, Budia A, Serrano A, Galan-Llopis JA, Sanchez-Margallo FM. Experimental assessment of new generation of ureteral stents: biodegradable and antireflux properties. *J Endourol*. 2020;34:359–365. doi:10.1089/end.2019.0493
4. Vogt B, Desgrippes A, Desfemmes FN. Changing the double-pigtail stent by a new suture stent to improve patient's quality of life: a prospective study. *World J Urol*. 2015;33:1061–1068. doi:10.1007/s00345-014-1394-2
5. Betschart P, Piller A, Zumstein V, et al. Reduction of stent-associated morbidity by minimizing stent material: a prospective, randomized, single-blind superiority trial assessing a customized 'suture stent'. *BJU Int*. 2021;127:596–605. doi:10.1111/bju.15290
6. Natalin RA, Hruby GW, Okhunov Z, et al. Pilot study evaluating ureteric physiological changes with a novel "ribbon stent" design using electromyographic and giant magnetoresistive sensors. *BJU Int*. 2009;103:1128–1131. doi:10.1111/j.1464-410X.2008.08184.x
7. Janssen C, Buttyan R, Seow CY, et al. A role for the hedgehog effector Gli1 in mediating stent-induced ureteral smooth muscle dysfunction and aperistalsis. *Urology*. 2017;104:242.e1–242.e8. doi:10.1016/j.urol.2017.01.029
8. Yu J, Carroll TJ, McMahon AP. Sonic hedgehog regulates proliferation and differentiation of mesenchymal cells in the mouse metanephric kidney. *Development*. 2002;129:5301–5312.
9. Ding H, Zhou D, Hao S, et al. Sonic hedgehog signaling mediates epithelial-mesenchymal communication and promotes renal fibrosis. *J Am Soc Nephrol*. 2012;23:801–813. doi:10.1681/ASN.2011060614
10. Vogt B, Desfemmes FN, Desgrippes A, Ponsot Y. MiniJFil®: a new safe and effective stent for well-tolerated repeated extracorporeal shockwave lithotripsy or ureteroscopy for medium-to-large kidney stones? *Nephrourol*. 2016;8:e40788. doi:10.5812/numonthly.40788
11. He HC, Chen JH, Chen XB, et al. Expression of hedgehog pathway components is associated with bladder cancer progression and clinical outcome. *Pathol Oncol Res*. 2012;18:349–355. doi:10.1007/s12253-011-9451-2
12. Sverrisson EF, Zens MS, Fei DL, et al. Clinicopathological correlates of Gli1 expression in a population-based cohort of patients with newly diagnosed bladder cancer. *Urol Oncol*. 2014;32:539–545. doi:10.1016/j.urolonc.2014.03.006

Research and Reports in Urology

Dovepress

Publish your work in this journal

Research and Reports in Urology is an international, peer-reviewed, open access journal publishing original research, reports, editorials, reviews and commentaries on all aspects of adult and pediatric urology in the clinic and laboratory including the following topics: Pathology, pathophysiology of urological disease; Investigation and

treatment of urological disease; Pharmacology of drugs used for the treatment of urological disease. The manuscript management system is completely online and includes a very quick and fair peer-review system, which is all easy to use. Visit <http://www.dovepress.com/testimonials.php> to read real quotes from published authors.

Submit your manuscript here: <https://www.dovepress.com/research-and-reports-in-urology-journal>