



Rapid Wound Healing and Acne Scar Improvement After Ablative Fractional Carbon Dioxide Laser Treatment Combined with the Application of Platelet-Lyophilized Treatment (PLT)

Chieh-Chen Huang 

Haw-Yueh Thong 

Department of Dermatology, Shin Kong
Wu Ho Su Memorial Hospital, Taipei,
Taiwan

Objective: There are several clinical cases on the application of PRP (platelet-rich plasma) therapies. To improve disadvantages such as the inability to be standardized and stored long term, we proposed a novel platelet-lyophilized treatment (PLT) to enhance the wound healing rate and improve acne scarring.

Study Design: A single-blinded study at a single health care center was performed. All subjects were treated with a fractional carbon dioxide laser. On the right side of the face, 2 mL PLT solution (dissolved in normal saline) was applied, while on the left side of the face (control group), 2 mL normal saline was applied. The treatment described above was repeated every 3 to 4 weeks, and 4 treatments were performed in total. Assessments were performed prior to each treatment and at the one-month follow-up after the fourth treatment. Subjective assessments included questionnaires administered by the principal investigator and a self-assessment questionnaire completed by the subjects. Moreover, VISIA complexion analysis was used for objective data collection, and spots, wrinkles, texture, pores, UV spots, brown spots, red areas, and porphyrins were objectively analyzed.

Results: Our data indicated that the PLT side showed a more rapid recovery than the saline side; on average, the sloughing off of the crusts was noted on day 5 and day 6. The improvement rate for skin spots, texture, and pores was significantly increased on the PLT side, with the pigment and pore size both having a statistically significant improvement of $p < 0.001$, while the texture had a significant improvement of $p < 0.01$.

Conclusion: The results suggested that the application of PLT could be a novel method to enhance wound healing and improve acne scarring after laser skin rejuvenation.

Keywords: platelet-lyophilized treatment, PLT, wound healing, acne scars, ablative fractional carbon dioxide laser

Introduction

Acne scarring is a common problem that can potentially impact acne patients' psychological and social activities. The scar types can be characterized as atrophic or hypertrophic, which are defined by the collagen volume.¹ Conventional ablative lasers are commonly used to treat acne scars, but the treatment is often associated with complications such as bleeding, edema, infection, and scarring.² Nonablative laser therapies such as 1550-nm erbium glass and ablative CO₂ lasers are well recognized for the treatment of acne scars and skin rejuvenation, have fewer

Correspondence: Haw-Yueh Thong
Department of Dermatology, Shin Kong
Wu Ho Su Memorial Hospital, No. 95,
Wenchang Road, Shilin Dist., Taipei City,
111045, Taiwan (R.O.C.)
Tel +886-926-612-880
Email drkellytang@gmail.com

complications, and have become state-of-the-art laser therapies for acne scars in recent years.³

Platelet-rich plasma (PRP), also known as autologous conditioned plasma, is a concentrate of platelet-rich plasma protein derived from whole blood. Different PRP systems contain variable platelet concentrations: from a lower concentration of 2.5–3 times the baseline concentration to a high concentration of 5–9 times the baseline concentration. Platelets contain a variety of proteins, cytokines, and other bioactive factors, such as platelet-derived growth factor (PDGF), vascular endothelial growth factor (VEGF), fibroblast growth factor (FGF), transforming growth factor (TGF), and epidermal growth factor (EGF).⁴ PRP is indicated for use in various dermatologic conditions, such as acne scarring, skin rejuvenation and wound healing.⁵ Studies have shown that the highly concentrated growth factors (GFs) in PRP can promote the wound healing process.^{6,7}

PRP is usually obtained via single-use centrifuge tubes; therefore, each time, the patients have to undergo the blood collection process prior to treatment. A novel option is the freeze-dried, stabilized form of platelets, which are easily stored and can remain stable for months or years. Lyophilization has great advantages for storage and allows for a long shelf life. Studies have indicated that freeze-dried PRP maintains platelet activity and growth factor levels.^{8,9}

In this study, we performed platelet-lyophilized treatment (PLT) on fractional CO₂ laser-treated areas. We aimed to evaluate the benefits of PLT as a novel approach to increase the wound healing rate and improve acne scarring after laser treatment.

Patients and Methods

Study Design

This was a single-blinded clinical study. All subject faces were separated in a split-face study to compare lyophilized PRP with saline after CO₂ laser resurfacing. All subjects underwent fractionated CO₂ laser resurfacing of the entire face with the subsequent application of PLT or saline immediately after laser treatment. Subjects received four laser treatments at a 3- to 4-week interval, and a total of 4 treatments were performed. The subjects were evaluated before and after each treatment and one month after the fourth treatment. Each subject responded to questionnaires. Clinical photos were also taken with VISIA® Imaging System. The local institutional review board

(IRB; Independent Ethics Committee, Shin Kong Wu Ho-Su Memorial Hospital, Taipei, Taiwan) approved the trial protocol on November 03, 2017 (clinical trial registration number: NCT04829370). The study was conducted in accordance with the ethical principles of the Declaration of Helsinki and consistent with the Good Clinical Practice (GCP) regulatory requirements. In addition, all subjects provided signed informed consent.

Subjects

Fifteen subjects aged 20–40 years with acne scars were included. All subjects with acne scars with grades of 1, 2, and 3 [Goodman and Baron Grading scale] [10] were enrolled in the study.

Exclusion criteria included treatment with any laser device on the face within 1 month, use of systemic retinoids within 3 months, pregnancy or lactation, a history of hypertrophic scarring or keloids, cancer therapies, uncontrolled diabetes, chronic liver or kidney disease, cardiovascular disease or hematologic disorders. Subjects were asked to avoid using any topical products containing alpha-hydroxy acids and salicylic acid on the face during the study period.

Platelet-Lyophilized Treatment Preparation

Platelet-lyophilized treatment (PLT) was prepared in the central laboratory of Spirit Scientific Co., Ltd. (PLT™,

Table 1 Acne Grade and Sloughing off of the Crusts on Day

	PLT	Saline
Acne grade		
Baseline (mean score±std)	1.66±0.61	1.66±0.61
After 4 treatment sessions (mean score±std)	1.26±0.59	1.4±0.63
Sloughing off of the crusts on day		
Subject 1	6	7
Subject 2	6	6
Subject 3	5	7
Subject 4	5	5
Subject 5	6	7
Subject 6	6	7
Subject 7	5	7
Subject 8	6	7
Subject 9	6	6
Subject 10	7	7
Subject 11	5	7
Subject 12	5	7
Subject 13	6	7
Subject 14	5	5
Subject 15	6	6

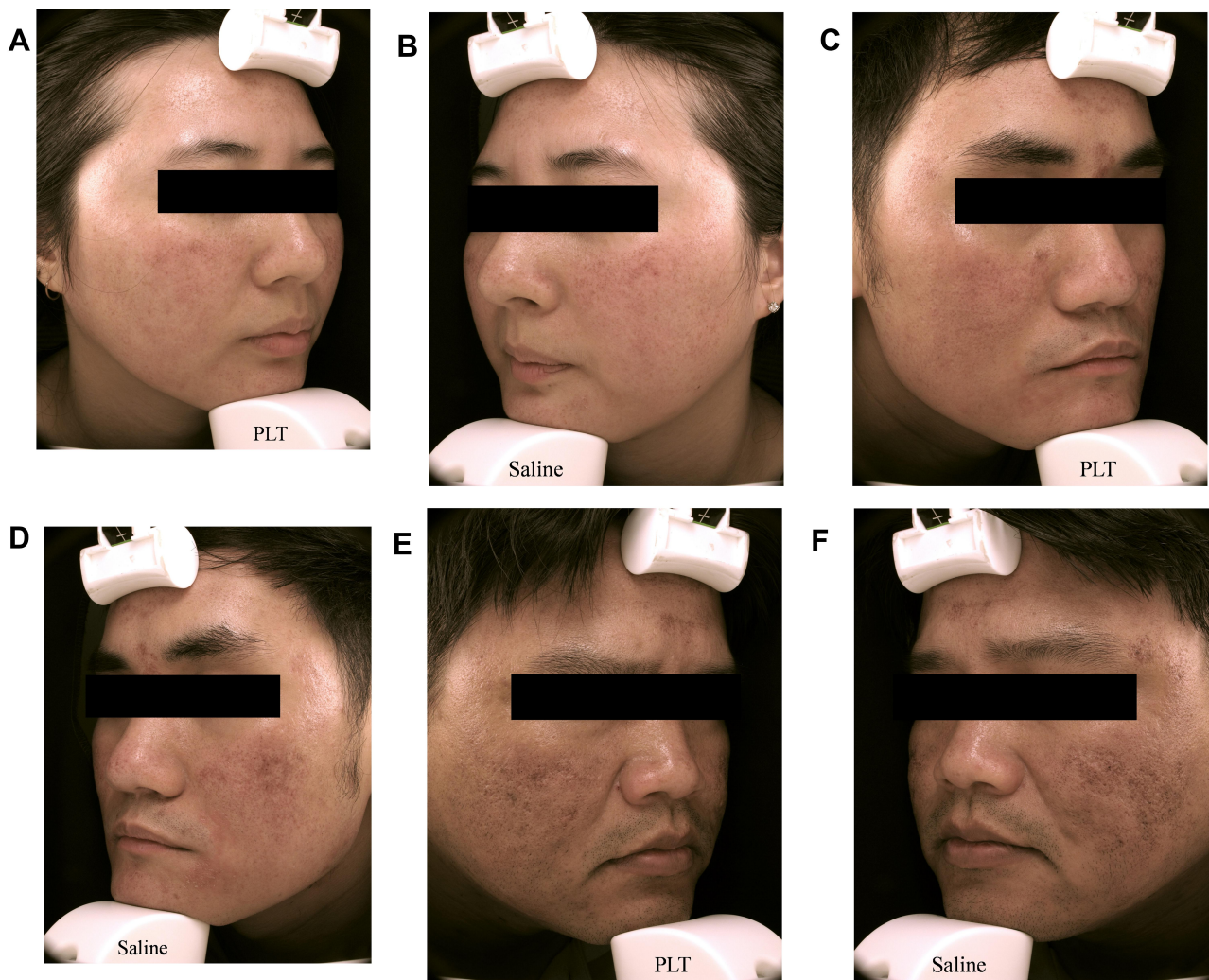


Figure 1 Face images of fractional carbon dioxide laser treatment after 2 days. The Platelet-lyophilized treatment (PLT)-treated side shows fewer scars.

Taipei, Taiwan). Upon receiving the 250-mL blood bag, platelets were separated with serial centrifugal steps. The platelets were quantified and placed into vials (1×10^9 per vial) before the vacuum freeze-drying process. After gamma-ray sterilization, PDGF-BB was measured using the enzyme-linked immunosorbent assay method and was quantified. The kits were purchased from R&D Systems (Human PDGF-BB Quantikine[®] ELISA kit; DBB00), and assays were performed according to the manufacturer's instructions.

Intervention

After CO₂ laser resurfacing, the right side of the face was treated with PLT, and the left side was treated with normal saline. This was a single-blinded clinical study, ie, the subjects did not know which side of the face was treated with PLT. All subjects were treated using a 10,600-nm

CO₂ laser (eCO₂, Lutronic, Seoul, Korea) at 20 mJ on the entire face. After CO₂ laser resurfacing, the right side of the face was treated with PLT, and the left side was treated with saline. Immediately after laser treatment, 2 vials of PLT were applied by the study nurse with a sterile cotton swab to the right side of the face, and 2 vials of normal saline were applied to the left side of the face. The subjects were advised to use sunscreen and aloe gel for the next 7 days. Each subject received a total of four treatments at 3- to 4-week intervals.

Assessment

Clinical images of both sides of the participants' faces were taken with a VISIA[®] (Canfield Imaging Systems, New Jersey, USA) at baseline and at the 1st, 2nd, 3rd, 4th, and 5th months posttreatment. A digital photograph was taken with the same lighting and positioning for

consistency in all serial photographs. Prior to VISIA photo collection, all subjects removed makeup and used a gentle facial cleanser (*BioreTM*) to wash their face. After 10 minutes, photographs were taken with a VISIA.

The assessment of subjective improvement was performed using questionnaires completed by the subjects and a severity score based on Goodman and Baron's qualitative acne scar grading system[10] by the same board certified dermatologist throughout the study period. The acne score was recorded on day 0 and at the 1st, 2nd, 3rd, 4th treatment and 5th visit (1 month after the 4th treatment).

The wound healing rate was recorded after each treatment from day 1 to day 7.

Subjective wound-healing scores (poor [0] to excellent [4]) that compared the current healing experience with the subject's past experiences were also recorded.

Statistical Analysis

Recorded data from 15 subjects were analyzed. Statistical tests were performed using t-tests. A P-value of 0.05 or less was considered significant.

Results

Subjects

Among the 15 subjects enrolled in the study, the average age was 32 years (range, 22–39 years), and 66.6% were men. The investigator used the Goodman and Baron grading system to rate the acne scar severity of all subjects, with the baseline scar severity grades were grade 3 (1 patient), grade 2 (8 patients), and grade 1 (6 patients). Subjects were selected with an equal mean baseline acne scar grade (1.66) on both sides of the face. This was to ensure consistency on both sides of the face to avoid bias. The right side (PLT) showed a 24% improvement in the Goodman and Baron Qualitative grade in comparison to a 16% improvement on the left side (saline) (Table 1).

Figure 1 shows clinical photographs of the subjects on day 2 after the 4th CO₂ laser treatment. PLT was applied to the right side of the face, whereas saline was applied to the left side of the face (Figure 1A–F). The PLT-treated side showed a more rapid sloughing off of the crusts after laser treatment. All subjects commented on the adverse effects associated with fractional CO₂ laser treatment. The most common side effects were pain, erythema, edema, and crusting or scaling. However, no side effects, such as infection or allergies, were observed on the PLT-treated side.

The PLT and saline areas were recorded consecutively for 7 days after treatment, and the percentage of healing days per side was calculated. Our data indicated that the PLT side showed a more rapid recovery than the saline side; on average, the sloughing off of the crusts was noted on day 5 and day 6 (Figure 2, Table 1).

All subjects' photos were taken and analyzed using VISIA complexion analysis to observe characteristics including pigment, texture, and pore size. The feature counts of each dimension were recorded from baseline up to 4 treatment sessions. The improvement of all features was observed on both sides. However, the improvement rates of skin spots, texture, and pores were significantly increased on the PLT side, with the pigment and pore size both having a statistically significant improvement of $p < 0.001$, while the texture had a significant improvement of $p < 0.01$ (Figure 3A–C).

Discussion

In the field of wound healing, recent studies have indicated that PRP plays a critical role in the wound healing of chronic skin ulcers in diabetic patients.¹⁰ In addition, the application of L-PRP powder shortened the wound healing time and enhanced the epithelization of deep second-degree burn wounds.¹¹ Platelets contain various growth factors that contribute to collagen synthesis and skin rejuvenation. The most important growth factors in skin rejuvenation are platelet-

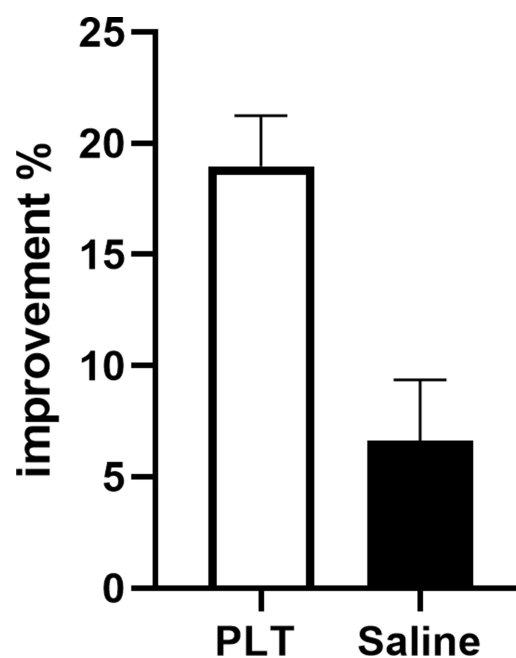


Figure 2 The improvement rate of PLT is higher than saline.
Abbreviation: PLT, Platelet-lyophilized treatment.

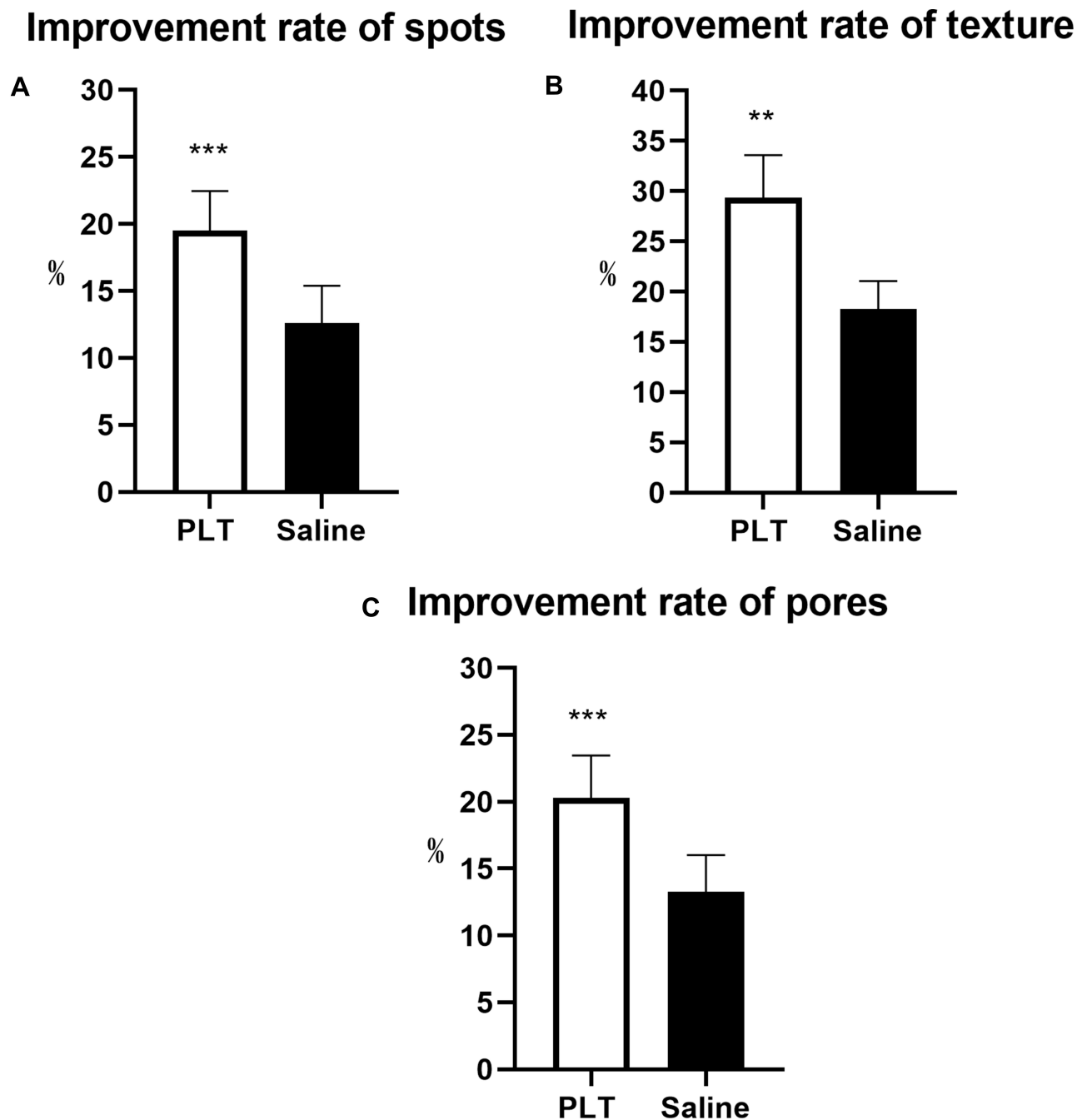


Figure 3 Figure 3 Spots (A), texture (B) and pores (C) after fractional carbon dioxide (CO₂) laser treatment. All improvement rates of PLT-treated sites were significantly increased compared with those of saline-treated sites after 4 treatment sessions. ** $p < 0.01$ with the paired t -test. *** $p < 0.001$ with the paired t -test.

Abbreviation: PLT, Platelet-lyophilized treatment.

derived growth factor (PDGF), transforming growth factor-beta (TGF- β), and vascular endothelial growth factor (VEGF). These growth factors trigger skin rejuvenation through the above process, stimulate the proliferation of epidermal cells and fibroblasts, promote angiogenesis, and induce collagen synthesis.¹² Our data demonstrated that a single application

of PLT immediately after each CO₂ laser treatment positively promoted the wound healing rate and enhanced the treatment results for acne scars. These results could help to improve the quality of life of patients after laser treatment. As shown in our study, the PLT-treated side showed greater improvement than the saline-treated side in all subjects. We concluded that

enhanced wound healing after laser treatment can be achieved with the application of PLT.

In aesthetic medicine, combination therapy is a new trend and an option for skin rejuvenation. Research in 2019 demonstrated that PRP with fractional laser treatment was beneficial for skin rejuvenation.¹³ Keratinocytes and fibroblasts play a critical role in skin cell proliferation and collagen production. These processes explain why PRP contributes to collagen production by those cells and increases dermal elasticity.¹⁴ For acne-related aesthetic treatment, ablative CO₂ laser treatment has been considered one of the most effective treatments for acne scars. However, adverse effects of ablative laser treatments were reported, such as prolonged erythema, edema, and post inflammatory hyperpigmentation (PIH).^{15,16} Wound care after CO₂ laser treatment may cause stress and may affect a patient's daily activities¹⁷. Recent clinical studies have also focused on exploring the combination of a CO₂ laser with other therapies, such as PRP and adipose tissue stem cells, to enhance the effectiveness and safety and decrease the incidence of adverse reactions to acne scar treatment.^{9,18,19} Several studies suggested that fractional CO₂ laser treatment combined with PRP could reduce edema and prolonged erythema after laser treatment.^{20–22} The majority of studies available demonstrated that using PRP in combination with CO₂ for the management of atrophic acne scars could be superior to topical intradermal PRP alone.^{23,24} Consistent with such findings, our study showed that with the application of PLT, the erythema and edema associated with CO₂ laser treatment were able to resolve completely within 2 days.

In conclusion, our study showed that PLT application helped to promote wound healing after CO₂ laser treatment and also contributed to acne scar improvement. However, we noticed that superficial acne scars responded more favorably to this combination treatment than icepick scars, which are deeper and have a greater extent of fibrosis. This was a preliminary study and was subject to a few limitations, such as a small sample size of 15 subjects and a lack of comparison regarding whether the intradermal injection of PLT solution could more effectively stimulate wound healing and enhance acne scar improvement. Further studies are needed to study the effect of the intradermal injection of PLT for treating deep acne scars. A large-scale study may be necessary to establish a protocol for acne scar treatment using combination therapy with a CO₂ laser and PLT application.

Conclusion

In summary, the results of the present study suggested that the application of

PLT could be a safe and effective method for enhancing wound healing and improving acne scarring after laser treatment.

Data Sharing Statement

The authors do not intend to share individual's deidentified participant data nor other study-related documents.

Disclosure

The authors report no conflicts of interest in this work.

References

- Petrov A, Pljakovska V. Fractional carbon dioxide laser in treatment of acne scars. *Maced J Med Sci*. 2016;4(1):38–42.
- Elcin G, Yalici-Armagan B. Fractional carbon dioxide laser for the treatment of facial atrophic acne scars: prospective clinical trial with short and long-term evaluation. *Lasers Med Sci*. 2017;32(9):2047–2054. doi:10.1007/s10103-017-2322-7
- Wat H, Wu DC, Hin Lee Chan H. Fractional resurfacing in the Asian patient: current state of the art. *Lasers Surg Med*. 2017;49(1):45–59. doi:10.1002/lsm.22579
- Everts P, Onishi K, Jayaram P, et al. Platelet-rich plasma: new performance understandings and therapeutic considerations in 2020. *Int J Mol Sci*. 2020;21(20):7794. doi:10.3390/ijms21207794
- Dhurat R, Sukesh M. Principles and methods of preparation of platelet-rich plasma: a review and author's perspective. *J Cutan Aesthet Surg*. 2014;7(4):189–197. doi:10.4103/0974-2077.150734
- Weed B, Davis MDP, Felty CL, et al. Autologous platelet lysate product versus placebo in patients with chronic leg ulcerations: a pilot study using a randomized, double-blind, placebo controlled trial. *Wounds*. 2004;16(9):273–282.
- Martinez-Zapata MJ, Marti-Carvajal AJ, Solà I, et al. Autologous platelet-rich plasma for treating chronic wounds. *Cochrane Database Syst Rev*. 2012;10:CD006899. doi:10.1002/14651858.CD006899.pub2
- Shiga Y, Kubota G, Orita S, et al. Freeze dried human platelet rich plasma retains activation and growth factor expression after an eight week preservation period. *Asian Spine J*. 2017;11(3):329–336. doi:10.4184/asj.2017.11.3.329
- Kohl E, Steinbauer J, Landthaler M, Szeimies RM. Skin ageing. *J Eur Acad Dermatol Venereol*. 2011;25(8):873–884.
- Tarroni G, Tessarin C, De Silvestro L, et al. [Local therapy with platelet-derived growth factors for chronic diabetic ulcers in haemodialysis patients]. *G Ital Nefrol*. 2002;19(6):630–633. [Portuguese]
- Yeung C-Y, Hsieh P-S, Wei L-G, et al. Efficacy of lyophilised platelet-rich plasma powder on healing rate in patients with deep second degree burn injury: a prospective double-blind randomized clinical Trial. *Ann Plast Surg*. 2018;80(Suppl 2S):S66–S69. doi:10.1097/SAP.0000000000001328
- Arsiwala NZ, Inamadar AC, Adya KA. A comparative study to assess the efficacy of fractional carbon dioxide laser and combination of fractional carbon dioxide laser with topical autologous platelet-rich plasma in post-acne atrophic scars. *J Cutan Aesthet Surg*. 2020;13(1):11–17. doi:10.4103/JCAS.JCAS_142_19
- Abdul-Aziz IAIT, Abdul-Aziz ASAR, Ahmed MH, et al. Comparative study of the efficacy of platelet-rich plasma combined with carboxytherapy vs its use with fractional carbon dioxide laser in atrophic acne scars. *J Cosmet Dermatol*. 2019;18(1):150–155. doi:10.1111/jocd.12561

14. Abu-Ghname A, Perdanasari AT, Davis MJ, et al. Platelet-rich plasma: principles and applications in plastic surgery. *Semin Plast Surg.* **2019**;33(3):155–161. doi:10.1055/s-0039-1693400
15. Yaqin X, Deng Y. Ablative fractional CO₂ laser for facial atrophic acne scars. *Facial Plast Surg.* **2018**;34(02):205–219. doi:10.1055/s-0037-1606096
16. Zhang -D-D, Zhao W-Y, Fang -Q-Q, et al. The efficacy of fractional CO₂ laser in acne scar treatment: a meta-analysis. *Dermatol Ther.* **2021**;34(1):e14539. doi:10.1111/dth.14539
17. Na J-I, Choi J-W, Choi H-R, et al. Rapid healing and reduced erythema after ablative fractional carbon dioxide laser resurfacing combined with the application of autologous platelet-rich plasma. *Dermatol Surg.* **2011**;37(4):463–468. doi:10.1111/j.1524-4725.2011.01916.x
18. Faghihi G, Keyvan S, Asilian A, et al. Efficacy of autologous platelet-rich plasma combined with fractional ablative carbon dioxide resurfacing laser in treatment of facial atrophic acne scars: a split-face randomized clinical trial. *Indian J Dermatol Venereol Leprol.* **2016**;82(2):162–168. doi:10.4103/0378-6323.174378
19. Abdel A, Ibrahim IM, Sami NA, et al. Evaluation of autologous platelet rich plasma plus ablative carbon dioxide fractional laser in the treatment of acne scars. *J Cosmet Laser Ther.* **2018**;20(2):106–113. doi:10.1080/14764172.2017.1368667
20. Mazid El-Hamd Neinaa Y, Abd-Elzaher Al-Khayat L, Momen Suliman GA, et al. Fractional carbon dioxide laser-assisted delivery of lyophilized-growth factors is a promising treatment modality of post-acne scars. *Dermatol Ther.* **2020**;e14488.
21. Min S, Yoon JY, Park. SY, et al. Combination of platelet rich plasma in fractional carbon dioxide laser treatment increased clinical efficacy of for acne scar by enhancement of collagen production and modulation of laser-induced inflammation. *Lasers Surg Med.* **2018**;50(4):302–310. doi:10.1002/lsm.22776
22. Galal O, Tawfik AA, Abdalla N, Soliman M. Fractional CO₂ laser versus combined platelet-rich plasma and fractional CO₂ laser in treatment of acne scars: image analysis system evaluation. *J Cosmet Dermatol.* **2019**;18(6):1665–1671. doi:10.1111/jocd.12909
23. Alser OH, Goutos I. The evidence behind the use of platelet-rich plasma (PRP) in scar management: a literature review. *Scars Burn Heal.* **2018**;18(4):2059513118808773.
24. Lynch MD, Bashir S. Applications of platelet-rich plasma in dermatology: a critical appraisal of the literature. *J Dermatolog Treat.* **2016**;27(3):285–289.

Clinical, Cosmetic and Investigational Dermatology

Dovepress

Publish your work in this journal

Clinical, Cosmetic and Investigational Dermatology is an international, peer-reviewed, open access, online journal that focuses on the latest clinical and experimental research in all aspects of skin disease and cosmetic interventions. This journal is indexed on CAS.

The manuscript management system is completely online and includes a very quick and fair peer-review system, which is all easy to use. Visit <http://www.dovepress.com/testimonials.php> to read real quotes from published authors.

Submit your manuscript here: <https://www.dovepress.com/clinical-cosmetic-and-investigational-dermatology-journal>