

The One2I Technique: An Individualized Treatment for Glabellar Lines Based on Clinical and Anatomical Landmarks [Corrigendum]

de Sanctis Pecora C, Pinheiro MVB, Ventura Ferreira K, Jacobino de Barros Nunes G, Miot HA. *Clin Cosmet Invest Dermatol*. 2021;14:97–105.

The authors apologize for this error and advise it does not affect the results of the paper.

The authors have advised due to an error at the time of figure assembly, Figure 5 on page 103 is incorrect. The correct Figure 5 is shown below.

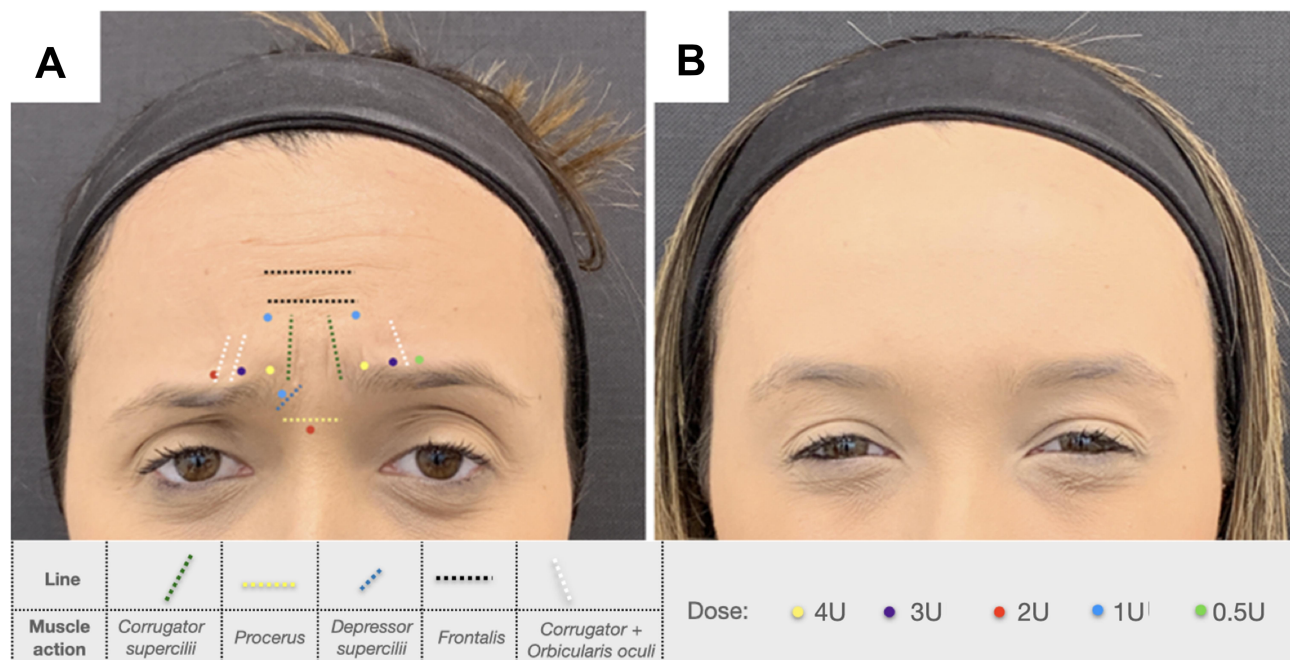


Figure 5 One2I assessment and personalized treatment plan based on glabellar line patterns. (A) Schematic mapping of the One2I technique for treating the procerus, corrugators, orbicularis oculi, depressor supercilii, and frontalis. (B) Complete of glabellar frown wrinkles 28 days after the treatment.