

# The Safety of Medicinal Plants Used in the Treatment of Vitiligo and Hypermelanosis: A Systematic Review of Use and Reports of Harm

This article was published in the following Dove Press journal:  
*Clinical, Cosmetic and Investigational Dermatology*

Irshad Hussain

Institute of Pharmacy, Shaheed Mohtarma  
Benazir Bhutto (SMBB) Medical  
University, Larkana, Pakistan

**Introduction:** Vitiligo is disfiguring and devastating condition that can humans feel stigmatic and devalued. Melasma is a general condition of hyperpigmentation particularly involving the face. The pigmentation disorders of vitiligo (hypopigmentation or depigmentation) and melasma (Hypermelanosis) are common among the world's population (around 1% for vitiligo).

**Objective:** The identification of medicinal plants used in the treatment of vitiligo and hypermelanosis. A systematic literature review on harms associated with the medicinal plants used in the treatment of vitiligo and hypermelanosis. To review and summarize information on reported adverse drug reactions (ADRs) associated with these medicinal plants contained in (where access is available) national and global individual case safety report databases.

**Methods:** A systematic review of the literature with special reference to all types of clinical trial and case reports using biomedical databases including Medline, EMBASE, Scopus, International Pharmaceutical Abstracts and so forth to identify medicinal plants alone or as an adjuvant with other treatments and their safety/tolerability in the treatment of vitiligo and Hypermelanosis. Other sources of this search were medicinal plants text books, pharmacopoeias and authentic websites discussing possible treatments for vitiligo/hypermelanosis. It also included databases such as VigiAccess containing data from spontaneous reporting schemes for ADRs.

**Results:** A total of 55 articles (47 clinical trials and 8 case reports) met the inclusion criteria. Some trials did not reported safety information, some did report, but not very well. Reports of blistering, erythema, acute hepatitis and mutagenesis with *Psoralea corylifolia*. Adverse effects of erythema (mild to severe), phototoxic reactions, mild raise in liver transaminases, gastrointestinal disturbances, burns, itching, scaling, depigmented macules, pruritis, and giddiness with the use of psoralens. Khellin-related erythema, perilesional hyperpigmentation, gastrointestinal disturbances, mild raise in liver transaminases and orthostatic complaints. Infrequent side effects with Ginkgo biloba. Lower grade of erythema and edema reported with the use of *Polypodium leucotomos*.

**Conclusion:** Primarily the retrieved clinical studies were efficacy oriented and safety parameters were secondary in priority whilst the general protocol of clinical trials requires the screening of drugs/medicinal plants on the basis of safety studies before testing the clinical aspects of efficacy. Thereby it is recommended that efficacy studies may be followed once the safety has been established for a particular medicinal plant in treating vitiligo and hypermelanosis.

**Keywords:** vitiligo, hypermelanosis, skin diseases, safety of medicinal plants, harm of herbs

Correspondence: Irshad Hussain  
Institute of Pharmacy, Shaheed Mohtarma  
Benazir Bhutto (SMBB) Medical  
University, 7 Doctors Colony, Along VIP  
Road, Larkana, 77150, Sindh, Pakistan  
Tel +92 31 27214112  
Email irshadpharmacist@yahoo.com

## Introduction

Vitiligo is disfiguring and devastating condition that can make humans feel stigmatic and devalued.<sup>1</sup> Melasma is a general condition of hyperpigmentation and particularly involves the face.<sup>2</sup> The pigmentation disorders of vitiligo (hypopigmentation or depigmentation) and melasma (Hypermelanosis) are common among the world's population (around 1% for vitiligo). The exact cause of both of the diseases is unclear, though various factors have been suggested in predisposition of vitiligo and melasma. Both of the conditions negatively effect the physical image of the affected individual, and there have been major cosmetic concerns, particularly for females. This affects them psychologically and economically by increasing their visits to dermatology/skin care clinics.<sup>1,2</sup> The use of natural products (complimentary/alternative medicines) for chronic health conditions is common and individuals may seek this approach for the treatment of vitiligo and melasma. Natural health products are promoted for use in these conditions. For the past few decades these products have been gaining popularity and there is an increase in demand because of their vast chemical diversity. These are believed to be relatively safe, reliable, easily accessible, and affordable to the public.<sup>3</sup> There have been studies regarding the use of medicinal plants in the conditions of vitiligo and hypermelanosis, but these were found to have limited evidence to support their efficacy in these uses.<sup>4,5</sup> Generally, public perception, particularly in under-developing countries, that topical/oral use of herbs has no untoward effects and thus there is lack of proper rules and regulations regarding the monitoring of manufacturing and sales of these natural pharmaceutical products. Plenty of beauty creams/ointments are advertized in print/electronic media and are available over the counter and many herbal practitioners use for them.<sup>6</sup> There are fewer clinical investigations of medicinal plants with respect to their safety when used in the vitiligo and hypermelanosis. To the best of the author's knowledge there has been no systematic research previously published. Thus, the novel systematic review has focused on exploring reports relating to possible harm associated with medicinal plants and some of the constituents derived from plants (psoralens) used in the treatment of vitiligo and hypermelanosis. The aims of the project were to identify and summarize harm associated with the medicinal plants used in the treatment of vitiligo and hypermelanosis through literature searches from databases.

## Methods

### Time Frame

Six months.

### Setting

School of Pharmacy, University of Auckland, New Zealand.

### Procedure

1. The following procedure was adopted to identify medicinal plants used in the treatment of vitiligo and hypermelanosis and their mode of use (topical or oral) for this treatment.

1a. The first step was to conduct a literature search to identify medicinal plants used in vitiligo/melasma (V/M). A systematic review of the literature was carried out using biomedical databases, including Medline, EMBASE, Scopus, International Pharmaceutical Abstracts, and so on to identify medicinal plants used in the treatment of vitiligo and hypermelanosis. Once the results were obtained (August 7, 2017), a search of the titles and abstracts to find the papers which discussed medicinal plants in V/M. The title and the abstract of the particular research paper was viewed to extract the key words representing the botanical or common name of that plant used to treat V/M. The plants included were either those having reports of clinical usage or those having in vitro anti-vitiligo/anti-melasma activity. After doing this, there was compilation of a table (medicinal plants used in vitiligo and/or melasma) listing the names of the medicinal plants used in V/M, and some other details (e.g., other names for the plants, use in V/M, the reference, method of preparation/delivery, i.e., topical or internal.

1b. Some other sources were also searched (e.g., authoritative medicinal plant textbooks, publicly available websites and pharmacopoeia) where possible to see if other medicinal plants were listed as being used in V/M and added them to the Table.

Books to be searched were those available at MedicinesComplete especially Herbal Medicine, Stockley's Herbal Medicines Interactions, Clarke's Analysis of Drugs and Poisons, Martindale and Melasma and vitiligo in brown skin. Pharmacopoeias to be searched out were Indian pharmacopoeia (IPC) and Hamdard pharmacograph.

**Table 1** Publicly Available Websites

Serial No.	Publicly Available Website (URL)	Name of Organization
1	<a href="https://nccih.nih.gov/health/herbsataglance.htm">https://nccih.nih.gov/health/herbsataglance.htm</a> ,	National center for complimentary and integrative health (NIH)
2	<a href="https://www.nps.gov/plants/medicinal/">https://www.nps.gov/plants/medicinal/</a>	Medicinal Plant Working Group (MPWG)
3	<a href="http://medicinalplantgenomics.msu.edu/">http://medicinalplantgenomics.msu.edu/</a>	Medicinal Plants Genomics resource.
4	<a href="http://www.pfaf.org/user/default.aspx">http://www.pfaf.org/user/default.aspx</a>	Plants for a future (PFAF)
5	<a href="http://abc.herbalgram.org/site/PageServer">http://abc.herbalgram.org/site/PageServer</a>	American botanical council (ABC)
6	<a href="https://www.medicinalplants-pharmacognosy.com/">https://www.medicinalplants-pharmacognosy.com/</a>	Pharmacognosy, s Topics Medicinal Plants.
7	<a href="http://www.medicinalplants.in/">http://www.medicinalplants.in/</a>	The national medicinal plants board (NMPB)
8	<a href="http://www.healthy.net/clinic/therapy/herbal/herbic/herbs/index.asp">http://www.healthy.net/clinic/therapy/herbal/herbic/herbs/index.asp</a>	Healthy.net
9	<a href="http://www.webmd.com/">http://www.webmd.com/</a>	WebMD

## Publicly Available Websites

There had been a general look on publicly available websites and the following sites (see Table 1) have been found leading, informative and relevant to retrieve the information on safety and harm of medicinal plants.

1. The following procedure was performed to undertake a literature review on harm associated with the use of medicinal plants in the treatment of vitiligo and hypermelanosis. 2a. Once part 1a/1b was finished, the list of medicinal plants was used in the table to do another literature search. This involved entering all the plant names (as well as their common names) and combine with “OR,.. To find clinical information on harm, the search was limited to all the clinical information types (i.e., all the clinical trial, case reports, systematic reviews, etc.). The results of this search were combined using “AND,, with the list obtained by combining the disease terms with “OR,, to get the relevant data. Other limits were applied at this stage, e.g., “human,, and in the English language. Then the pooled medicinal plants group were combined with the “clinical” group with “AND,,. This then provided the set of literature to work on for Aim 2, i.e., the systematic review on harms associated with the use of med plants in V/M. Psoralens were included in the review by

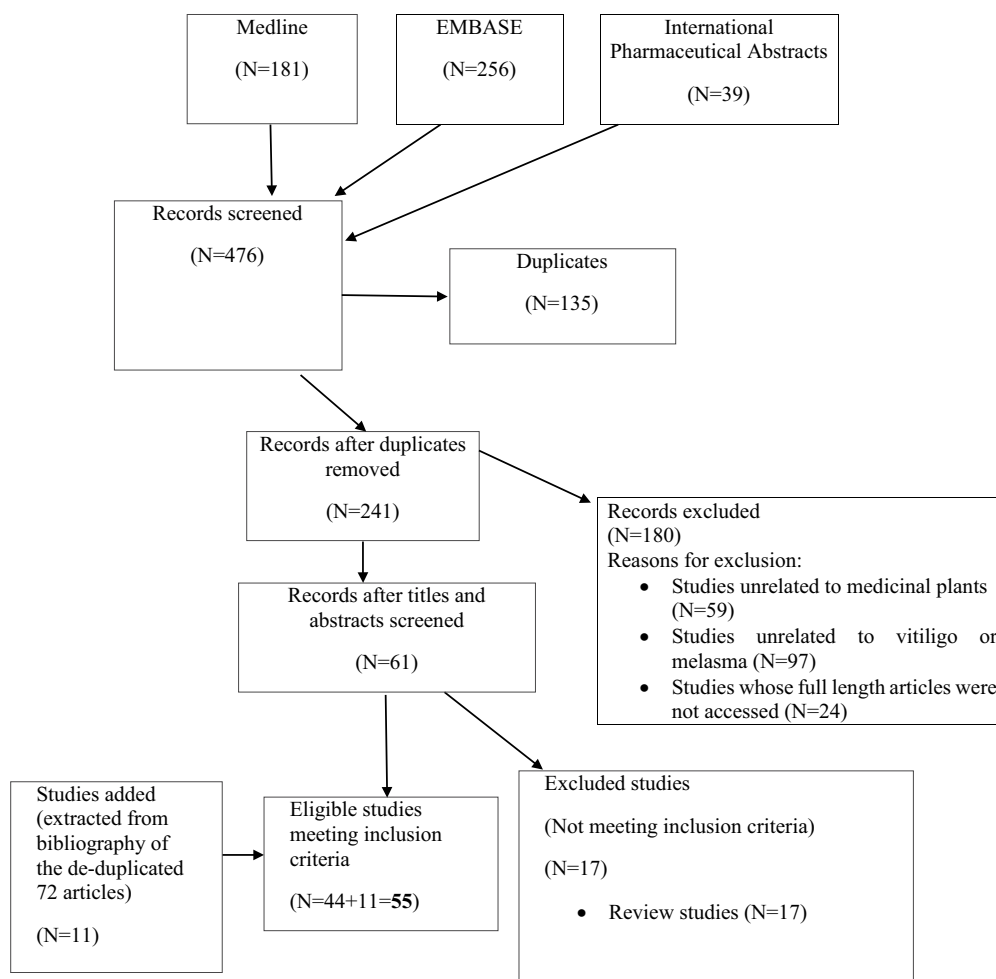
adding the search terms for these into plant names at this stage (Figure 1).

2b. To look through the titles and abstracts of this group and to select the papers that contained information on harms/adverse effects came from clinical trial reports, or from case reports with these medicinal plants, or other types of papers. Using the relevant papers to summarise the information on harms/adverse effects for each of the medicinal plant.

1. Using the list of medicinal plants in the Table from 1b above, there was a search of the ADR databases to find reports of suspected adverse drug reactions (ADRs) submitted to national medicines agencies/pharmacovigilance centres. Systematic searches of WHO VigiAccess database (the publicly available version of the WHO’s individual case safety report database) and other databases containing data from spontaneous reporting schemes for ADRs, such as EudraVigilance (the European database of suspected ADR reports), SMARS (Suspected Medicine Adverse Reaction Scheme (NZ).

## Inclusion Criteria

Articles containing information on adverse events or other safety-related information associated with the use of



**Figure 1** Flow chart of study selection process.

medicinal plant preparations for the treatment of vitiligo and hypermelanosis in humans.

## Exclusion Criteria

Publications where full length articles were not available, articles other than English language and articles describing preclinical studies only. Journals discontinued/articles not found online from journal archives.

## Results

The results have been summarized in [Tables 3](#), [Tables 2–4](#).

## Discussions

The study included all types of clinical trials and case reports retrieved according to protocol and the literature search strategy. It was found that adverse effects were poorly reported in most of the studies. Some research papers mentioned safety in abstract but did not provide

details, some trials did not report safety information, some did report, but not very well. The topical gel Aloe vera was reported safe without any significant dermatological reactions by Masoumech and Ali<sup>7</sup> in a randomized double blind controlled trial. On Aloe vera VigiAccess reported 204 cases of total adverse events including 29 reports on skin and subcutaneous reactions and 1 report on pigmentation disorders specifically the discoloration of skin. The report about discoloring/hypopigmentation effect of *Aloe vera* pointed out the use of *Aloe vera* in skin care and anti-aging effects. Debbie<sup>9</sup> worked on topical lotion of *Coffea Arabica*; fruit, vegetables extract in hyperpigmentation and reported no side effects. The study was on a limited number of patients (40 females) for a short period of time (5 weeks). Hussain et al<sup>11</sup> reported skin irritation effects with topical ointment contained powdered form of *Psoralea corylifolia* (PC). Maurice and

Table 2 Summary of Clinical Studies on Vitiligo and Melasma

Author (Year)	Study Design	Condition	Participants (M=Males, F=Females) (Age Range in Years)	No of Participants	Control	Interventions	Primary Outcome	Safety Outcomes Monitored Y(Yes)/N(No)	Summary of Safety Information
Masoumeh and Ali. <sup>7</sup> (2017)	Double blind randomized	Melasma, Subjects completing 1st trimester of pregnancy	F	180	AGE controlled	Topical gel of Aloe vera, soybean lecithin (SLP-White, 1.0 wt 15%) Duration: 5 weeks.	Skin care and anti-aging effects	Y	No significant dermatological allergic reactions
Shahla et al. <sup>8</sup> (2015)	Double blind Randomized	Melasma (epidermal) years)	(age range 19–55)	54	Hydroquinone controlled	Petroselinum crispum (topical) used every night in brewed form, Hydroquinone topical cream (4%), Duration: 8 weeks.	Decreased severity of melasma	N	
Debbie. <sup>9</sup> (2010)	Double-blind, randomized, Controlled clinical	Hyperpigmentation, wrinkles, etc., Skin type I-IV	F	40	Facial wash controlled	Topical lotion of <i>Coffea arabica</i> fruit and vegetable extracts, duration: 5 weeks, usage- twice a day: morning and evening	Significant improvements of photodamaged skin	Y	No side effects
Gionata et al. <sup>10</sup> (2012)	Open trial symmetrical vitiligo,	Active lesions ≤ 10% skin Skin type II and III	(age range 18–72)			Topical gel containing <i>Cucumis melo</i> extract as one of the ingredients, Duration: 5 weeks, irradiation doses 70–480mj/cm <sup>2</sup> .	Repigmentation effects	Y	No side effects
Hussain et al. <sup>11</sup> (2016)	Each patient serves as his/her own control (self control)	Vitiligo	M/F (age range 18–60)	20	Self controlled	Topical ointment containing powdered seeds of <i>Psoralea corylifolia</i> (10% w/w)	Repigmentation of small circular	Y	Skin irritation

(Continued)

Table 2 (Continued).

Author (Year)	Study Design	Condition	Participants (M=Males, F=Females) (Age Range in Years)	No of Participants	Control	Interventions	Primary Outcome	Safety Outcomes Monitored Y(Yes)/N(No)	Summary of Safety Information
Orest et al <sup>12</sup> (2011)	Prospective Open-label pilot non randomized	Vitiligo vulgaris VASI= 3cm <sup>2</sup> or 6cm <sup>2</sup>	M/F (age range 12–18)	12	No control	Standardized Ginkgo biloba (oral), supplement (60mg twice a day duration: 12 weeks	White lesions of skin	Y	One case of watery diarrhea (mild) that was resolved within 24 hours without discontinuing treatment. No adverse events in other patients.
Ahmed et al <sup>13</sup> (2013)	Prospective randomized single blind placebo	Vitiligo (small patches), onset < 2 years VASI= 10–20%	M/F (age range 18–58)	50	Placebo controlled	Ginkgo biloba (oral), capsule (75 mg) twice a day, duration: 8 weeks.	No changes in vasi between Ginkgo biloba and placebo group	Y	No side effects
Parsad et al <sup>14</sup> (2003)	Randomized, placebo-controlled double blind	Vitiligo (focal, vulgaris, acrofacial) Surface area ≤10cm <sup>2</sup>	M/F	52	Controlled	Ginkgo biloba (oral) extract, capsule (40 mg), three times daily, duration: 6 months	Marked to complete repigmentation	Y	Infrequent side effects (mild nausea in two patients) No side effect in control group.
Jun et al <sup>15</sup> (2004)	Open design	Chloasma	F	12	No control	Grape seed extract (GSE Oral), 67 mg of GSE (54 mg of proanthocyanidin), duration: 6 month	Reduction of hyperpigmentation	Y	No side effect

K.L. Bedi et al <sup>16</sup> (1989)	Each patient serves as his/her own control	Vitiligo	M/F (age range 6-42)	30	Placebo controlled	Picrorhiza kurroa (dried powder) 200 mg capsule/oral twice a day Methoxsalen 10-20 mg tablet/oral single dose once a day along with local application of 0.75% ointment/lotion of methoxsalen. Duration: up to 07 months.	Re-pigmentation	N	16 reported cases of erythema, itching, pruritus
Glen et al <sup>17</sup> (2011)	Randomized single blind placebo controlled	Melasma (epidermal/mixed)	M/F (1:49)	50	Placebo controlled	Mulberry extract oil (topical),	Improvement of melasma		
Ammar et al <sup>18</sup> (2013)	Randomized, double blind placebo controlled	Facial melasma (moderate to severe) melanin index $\geq 30$	F (Hispanic)	40	Placebo controlled	<i>Polypodium leucotomos</i> extract (PLE), 240 mg (oral) three times daily for 12 weeks. broad-spectrum, standard topical sunscreen used in morning during the treatment.	Improvement in melanin index		
Lucy et al <sup>19</sup> (2012)	Randomized, double blind placebo controlled	Melasma (epidermal)	F	21	Controlled	<i>Polypodium leucotomos</i> (oral) sunscreen SPF 45. Duration 12 weeks	Antimelasma effects	N	

(Continued)



Table 2 (Continued).

Author (Year)	Study Design	Condition	Participants (M=Males, F=Females) (Age Range in Years)	No of Participants	Control	Interventions	Primary Outcome	Safety Outcomes Monitored Y(Yes)/N(No)	Summary of Safety Information
Eduardo et al <sup>20</sup> (2005)	Pilot randomized double blind placebo controlled	Generalized vitiligo. vitiligo since 8.69 ±5.69 years Skin type II–III	M/F (age range 19–59)	19		<i>Polypodium leucotomos</i> (PL) adjuvant to PUVA, PL (oral) 720 mg/day, UVA (8 J/CM <sup>2</sup> ), 8-Methoxypsoralen (0.6 mg/kg body weight), frequency of PUVA sessions (three times per week), duration: 12 weeks.	Repigmentation response	Y	
Martiza et al <sup>21</sup> (2004)	Open trial	PUVA induced phototoxicity, skin type II–III	M/F (age range 24–47)	10	No control	<i>Polypodium leucotomos</i> extract (oral), PUVA, PL capsule (180 mg) 7.5 mg/kg body weight, 8-methoxypsoralen 0.6 mg/kg per oral	Chemoprotection	Y	Lower grade erythema and edema with PL in combination with PUVA when compared to PUVA alone. PL provides skin protection against damaging effects of PUVA.
Mark et al <sup>22</sup> (2015)	Randomized double blind placebo controlled birth control in women subjects, during trial.	Healthy Subjects, skin type I and IV	M/F (age range 18–65)	40	Controlled	<i>Polypodium leucotomos</i> extract oral capsule (240 mg), twice a day, UV radiation, duration: 8 weeks.	Reducing the damaging effect	Y	



Roberta et al <sup>23</sup> (2015)	Open trial	non-segmental vitiligo, vitiligo duration > 1 year.	M/F (age ≥ 18)	130	No control	Oral supplement tablet containing <i>Phyllanthus emblica</i> (100 mg), Vit.E (10 mg) and Carotenoids (4.7 mg). One Tablet three times a day. duration: 6 month.	Signs of follicular repigmentation	Y	
Adilson et al <sup>24</sup> (2009)	Prospective comparative randomized mono blind	Melasma, (epidermal/mixed), skin type I and IV.	F (age range 18–60)		Controlled	Topical cream with emblica licorice and Belides (7%) used twice a day for 8 weeks. Hydroquinone cream (2%) used at night for 8 weeks.	Hypopigmentation effects	Y	Two patients of group A while burning, erythema and erythematous papules in 7 patients of group B.
Zni et al <sup>25</sup> (2002)	Open design	Melasma	F (age range 29–59)	30	No control	Oral tablet containing anti-melasma effects <i>Pinus pinaster</i> extract (25 mg), used with meal, three times a day. duration: 30 days.		Y	No side effects
Clarisse et al <sup>26</sup> (2014)	Randomized double-blind placebo-controlled	Melasma (epidermal and mixed) (mild to moderate)	M/F (age range 18–60)	45	Placebo controlled	Topical creams containing <i>Rumex occidentalis</i> (3%), Hydroquinone (4%), applied, twice daily for 8 weeks.	Anti-melasma effects of R.occidentalis comparable to hydroquinone	Y	Mild peeling in one subject using R. occidentalis cream. No side effect in control group.
Morag et al <sup>27</sup> (2015)	Randomized double-blind	Melasma/lentigo	F (age range 26–55)	102	Placebo controlled	Topical cream containing <i>Serratulae quinquefoliae folium</i> (2.51% arbutin), twice a day for 8 weeks.	Lightening of skin discolorations	Y	No side effects

(Continued)

Table 2 (Continued).

Author (Year)	Study Design	Condition	Participants (M=Males, F=Females) (Age Range in Years)	No of Participants	Control	Interventions	Primary Outcome	Safety Outcomes Monitored Y(Yes)/N(No)	Summary of Safety Information
De Leeuw et al <sup>28</sup> (2011)	Open trial Vitiligo	Vitiligo, (refractory, stable, segmental)	M/F (age range 25–68)	19	No control	Liposomes containing khellin, ultraviolet light. Spray containing Khellin (0.005%) twice a day. UV treatment three sessions per week, each session not exceeding 15 minutes.	Repigmentation	N	
Saraceno et al <sup>29</sup> (2009)	Open prospective pilot controlled	Vitiligo (localized/generalized)	M/F (age range 10–72)	48	Pilot (vitamin E) controlled	Topical ointment (4%) containing khellin (K), oral vitamin E capsule, monochromatic excimer light (MEL) 308 nm duration: 12 weeks.	Enhanced response in combination therapy of MEL and K.	Y	Erythema (group I: 6/16 patients; group II: 12/16 patients), pain/burning (group I: 3/16; group II: 6/16), perilesional hyperpigmentation (group I: 5/16; group II: 8/16). NO side effect in control.
Valkova et al <sup>30</sup> (2004)	Controlled (group assignment by alteration).	Vitiligo (localized, generalized, acrofacial), skin type II–IV duration of disease: 0.5–32 years	M/F (age range 6–59)	33	PUVA controlled	Topical emulsion containing khellin, and UVA (KUVA) comparison with PUVA	KUVA may effectively induce repigmentation comparable to PUVA.	Y	In group II PUVA patients 11 (64.7%) the appearance of erythema along with mild to moderate itch. 6 of them (35.3%) with slight pain and abdominal pain in 9 (52.9%), dizziness. No side effect in KUVA treated group I patients.

Orecchia et al. <sup>31</sup> (1998)	Self controlled double blind	Vitiligo (generalized, acrofacial, facial and acral),	M/F (age range 9–60)	36	Self controlled	Topical gell (1%) containing khellin, and photochemotherapy. trial duration: 6 months	Clinical improvement of vitiligo	Y	No side effects
Procaccini et al. <sup>32</sup> (1995)	Controlled trial	Vitiligo (localized or generalized)	M/F (age range 7–54)	72	Placebo controlled	Topical creams containing khellin, and photochemotherapy. Khellin cream (5%), khellin (3%) in PYR 1-methyl-2-pyrrolidinone. dose of phototherapy (range 100–950 J/cm <sup>2</sup> ). Trial duration: up to 6 month	No repigmentation with topical khellin	Y	In all patients no pre-treatment phototoxic reaction with khellin
Bernhard et al. <sup>33</sup> (1988)	Open trial	Vitiligo (focal/ acrofacial)	M/F (age range 12–60)	28	Non controlled	Khellin used topically (2% solution) and orally (100 mg capsule) along with UVA (three times weekly). Topical Solution applied an hour before UV (10–15 joules/cm <sup>2</sup> ). Trial duration: up to 18 weeks.	Follicular pigmentation	Y	6(21%) of the volunteers ingesting Khellin reported episodes of nausea (mild) and 2 (7%) reported orthostatic complaints. In 7 (25%) of 28 patients, a mild raise in liver transaminases.

(Continued)

Table 2 (Continued).

Author (Year)	Study Design	Condition	Participants (M=Males, F=Females) (Age Range in Years)	No of Participants	Control	Interventions	Primary Outcome	Safety Outcomes Monitored Y(Yes)/N(No)	Summary of Safety Information
Mofy et al <sup>34</sup> (2013)	Randomized controlled	Vitiligo (generalized) normal liver function, normal eye fundus.	M/F (age range 13–60)	45	Randomized controlled	Oral tablet containing 8-methoxyypsoralen, broadband UVA, BB-UVA 8-methoxyypsoralen 10 tablet 0.5–0.7 mg/kg, UVA UVA dose range 10–15 J/cm <sup>2</sup> /session, three sessions per week. Duration: 5 month.	PUVA related perifollicular pigmentation. UVA related lesional tannin PUVA (group C) as compared to patients receiving UVA.	Y	Phototoxic reactions were significantly higher in subjects
Shivani et al <sup>35</sup> (2013)	Randomized	Vitiligo >5% involvement of BSA- V; Duration of disease $\pm$ SD 10.8 $\pm$ 6.9, no topical/systematic treatment, in previous 2 months.	M/F (age range 13–70)	45	No controlled	Oral tablet contain 8-methoxyypsoralen (10 mg), plus narrow band UVB vs UVB alone. Psoralen 0.6 mg/kg take 2 hrs prior each session. Initial UVB dose 0.33 J/cm <sup>2</sup> (increased up to 10%). Duration 6 months or 60 treatment session- (whichever earlier)	Repigmentation	Y	In NBUVB group four patients developed side effects comparative to 10 patients in P-NBUVB group. Nausea, phototoxic reaction, depigmented macules and hyperpigmentation were reported.

Ranjeeta et al <sup>36</sup> (2012)	Observer-blinded, randomized controlled	Vitiligo, (focal vitiligo, acrofacial vitiligo, vitiligo vulgaris), skin type III–V. >5% involvement of BSA-V, duration of disease 1–12 years	M/F (age range 13–70)	56	Randomized controlled	Systematic PUVA vs narrow band UVB, 8-methoxypsoralen (oral) 0.6 mg/kg, with food, two hrs prior UV session. UVA dose range 0.5–2.5 J/cm <sup>2</sup> . Initial UVB dose 280 mJ/cm <sup>2</sup> only in few patients. with 15% increments from previous dose session till erythema appeared. Therapy continued till complete pigmentation or 6 month completion (whichever first).	Repigmentation	Y	Adverse effects more common in PUVA group (57.2%) e.g., pruritis, hyperpigmentation, giddiness, erythema, thickening and nausea while less common in NB-UVB group (7.4%) e.g., pruritis.
Sami et al <sup>37</sup> (2007)	Double-blind randomized	Non-segmental vitiligo skin types I-VI, Duration of disease 6–10 years. (2–70% of BSA-V).	M/F (age range 18–70 years)	54	Non controlled	Oral psoralen-UV-A therapy vs NB-UV 5-MOP 20 mg tablet, dose 50 mg/m <sup>2</sup> (range 60–80 mg) 3 hrs before phototherapy. Dose of UVA (0.1 J/cm <sup>2</sup> ) and UVB (0.5 J/cm <sup>2</sup> ), 20% increment at each visit if tolerated. Trial duration:4 months	Repigmentation	Y	Adverse effects of erythema were more common in PUVA (96%) group as compared to NB-UVB (68%) treated group.

(Continued)

Table 2 (Continued).

Author (Year)	Study Design	Condition	Participants (M=Males, F=Females) (Age Range in Years)	No of Participants	Control	Interventions	Primary Outcome	Safety Outcomes Monitored Y(Yes)/N(No)	Summary of Safety Information
Bhatnagar et al <sup>38</sup> (2007)	Open prospective	Vitiligo (focal, vulgaris, acrofacial) Skin type IV, V.	M/F (age range 12–50)	50	Non controlled	PUVA and NBUVB, trimethylpsoralen (oral) 0.6 mg/kg with food. UVA initial dose 2 J/cm <sup>2</sup> by increasing 0.5 J/cm <sup>2</sup> for subsequent visit. NBUVB initial dose 280 Mj/cm <sup>2</sup> .	Repigmentation	N	
Ermis et al <sup>39</sup> (2001)	Placebo controlled double blind	Generalized vitiligo skin type II–IV, BSA-V 10–50% Disease duration 2–20 years	M/F (age range 16–64 years)	35		Placebo controlled PUVA plus topical calcipotriol, 8-MOP (oral) dose 0.5–0.6 mg/kg, UVA dose (mean) 52.52 ±6.10 J/cm <sup>2</sup> , calcipotriol cream dose 0.05 mg/g. Trial duration uration 8 weeks.	Calcipotriol potentiated efficacy of PUVA in treating vitiligo and earlier pigmentation.	Y	Erythema (mild to moderate), itching and xerosis in two cases treated with calcipotriol and three cases of placebo.
Ameen et al <sup>40</sup> (2001)	Open study	Vitiligo (symmetrical) Spread of disease 5–40%	M/F (age range 5–61)	26	Non controlled	Calcipotriol, psoralen plus UVA, oral or topical 8-methoxypsoralen, PUVA three times in a week. Trial duration: 6–9 months.	Repigmentation	Y	No adverse effects

Parsad et al <sup>41</sup> (2004)	Open trial	Vitiligo (vulgaris, focal, segmental, acrofacial)	M/F (age range 5–61 years)	125	Non controlled	Topical and systematic PUVA, topical and systemic steroids, topical calcipotriol. Trial duration: 3 months.	Perifollicular repigmentation	N	
Parasad et al <sup>42</sup> (1998)	Randomized double blind) right/left comparative	Vitiligo (bilateral symmetrical)	M/F age range 14–39	19	Placebo controlled	PUVAsol and topical calcipotriol, 8-MOP (oral) 0.6mg/kg prior 2 hour, exposure to sunlight three sessions per week. Calcipotriol ointment (50 ug/g). Trial Duration: 18 month.	Additive effect of PUVA and calcipotriol	N	
Wiete et al <sup>43</sup> (1997)	Before and after trial with two arms	Vitiligo (generalized, active, extensive) skin type II–V. Duration of disease $\pm$ SD 11.7 $\pm$ 5.6	M/F	181	Non controlled	0.005% topical gel containing psoralen, UV-A and UV-B radiation. Dose of UVA (0.5J/cm <sup>2</sup> ) and UVB (0.075 J/cm <sup>2</sup> ), was increased in 20% until erythema developed.	Repigmentation	Y	Burns, erythema, itching and scaling in 10% patients using psoralen gel, treatment discontinued in the patients.
ElMofly et al <sup>44</sup> (1994)	Open trial	Vitiligo, psoriasis, hypopigmentation, duration of disease 3–26 years.	(age range 12–60)	53	Non controlled	Oral hard gelatine capsule containing ultramicronized 8-MOP (10 mg dose 0.25 mg/kg given after low fat diet. 30 sittings for treating vitiligo patients.	Repigmentation	Y	No side effects

(Continued)



Table 2 (Continued).

Author (Year)	Study Design	Condition	Participants (M=Males, F=Females) (Age Range in Years)	No of Participants	Control	Interventions	Primary Outcome	Safety Outcomes Monitored Y(Yes)/N(No)	Summary of Safety Information
J. Africk and Fulton. <sup>45</sup> (1971)	Open trial	Vitiligo, duration of disease 1–35 years	M/F	24	Non controlled	Topical lotion containing 0.1% trimethylpsoralen and sunlight. Trial duration up to 6 months	Repigmentation	Y	Severe erythema in two patients, excessive dryness of skin in one patient.
Sehgal and M.A.M.S <sup>46</sup> (1971)	Retrospective clinical report	Vitiligo	M/F	87	Non controlled	Oral tablets(10 mg) containing trimethylpsoralen psoralen and 8-methoxyypsoralen. One tablet daily in morning with milk, exposed to morning sunshine after 2.5 hours for 15 minutes. Increasing the light exposure to a point of tolerance.	Repigmentation	Y	Two patients treated 8-methoxyypsoralen complained severe gastrointestinal disturbances. One patient had agranulocytosis with psoralen.

Mofy and Nada. <sup>47</sup> (1971)	Comparative study	Vitiligo, disease duration 2 months to 5 years	M/F (age range 8-50)	26	Non controlled	8-MOP, trisoralen and 8-MOP plus corticosteroids. 8-MOP dose 4-5 oral tablets of 10 mg twice a day (group I), trisoralen dose 2 oral tablets once a day (group II), 8-MOP 4 oral tablets in two unequal doses per day along with prednisolone dose 10-15 mg per day (group III). Sunlight from 05 minutes to level of tolerance. Trial duration up to 3 months.	Repigmentation	N	
-------------------------------------	-------------------	--	----------------------	----	----------------	---	----------------	---	--

**Notes:** Skin Phototypes (categories) as per Fitzpatrick classification of skin on the basis of unprotected response to the sun exposure (first 30-45 minutes). Type I= easily burn in the sun; never tans. Type II= usually burns easily; tans minimally. Type III= usually tans gradually; moderately burns. Type IV= always tans well; minimally burns. Type V= rarely burns; profusely tans (Asian skin). Type VI= never burns; pigmented deeply (Afro-Caribbean skin).

**Abbreviations:** AGE, Aloe vera leaf extract; BSA-V, body surface area with vitiligo.

**Table 3** Summary of Clinical Case Reports on Vitiligo and Melasma

Author (Year)	Patient Characteristics (Age, Sex)	Details of the Condition Treated	Details of Medicines Used	Suspected ADRs	Outcome
Peter et al <sup>48</sup> (2001)	48 years, female	Vitiligo for ten years	1 Khellin (100mg/oral) 2.5 hours before UVA (10 joules/cm <sup>2</sup> ) three times a week. 2) 2% khellin solution (topical)	A marked elevation in LFTs with oral and topical therapy. slight hepatomegaly	Liver functions returned to normal after the treatment stopped.
A Kreuter et al <sup>49</sup>	39 years, female	Cosmetically disturbing extensive exacerbated depigmented lesions on face.	Topical glucocorticoids, topical cream containing psoralen and UVA (0.5 J/cm <sup>2</sup> –4 J/cm <sup>2</sup> ).	No side effects	Complete repigmentation after 80 treatment sessions
Maurice and Cream <sup>50</sup> (1989)	30 years, male	Extensive vitiligo for twenty years, photosensitivity, itching of hands.	Herbal infusion containing powdered seeds of <i>Psoralea corylifolia</i> in a daily dose equivalent to 30 g of seeds.	Photosensitivity, itching, of hands, erythema, blistering.	Three month after stop of taking herbal infusion ADRs were reversed.
David et al <sup>51</sup> (1998)	9 years, female	Progressive vitiligo involving axillae, lower extremities and trunk BSA= 10%.	Bath PUVA, 8-MOP (0.0002%). Initial dose of UVA 0.25 J/cm <sup>2</sup> with increment of 0.25 J/cm <sup>2</sup> after every other treatment. Maximum UVA dose 3.0 J/cm <sup>2</sup>	No side effects	Nearly complete repigmentation of vitiliginous areas.
Zouhir Djerrou. <sup>52</sup> (2015)	34 years, male	Localized vitiligo on face and neck, diabetes and thyroid dysfunction.	History of using conventional drugs. natural remedy formed from honey bee, decoction of dry oat stems and red onion juice taken every evening daily. Exposure to sunlight for 15–20 minutes/day. Citrus lemon fruit juice (limited use).	No side effects	Complete repigmentation
Rigmor <sup>53</sup> (1976)	40 years, female	Vitiligo since 14 years of age, symmetrically localized vitiligo over trunk, back of feet and wrists. Achlorhydria, pernicious anemia diabetes mellitus and thyroid gland diseases.	Methoxsalen (20–30 mg/oral) and sunlight for 91 days. History of taking arsenic trioxide (1000 mg).	Moderate erythema of skin, multiple basal cell carcinomas.	Raised Risk of skin cancer with methoxsalen and sunlight in the patient with history of using carcinogenics.
Deborah and MacDonald <sup>54</sup> (2014)	52 years, female	Vitiligo	Oral use of seeds of <i>Psoralea corylifolia</i>	Cholestatic acute hepatitis, jaundice, abdominal pain, lethargy, vomiting, dark urine, pale stools.	Reversal of acute hepatitis on stoppage of using seeds of <i>Psoralea corylifolia</i> .
M.B. Abdel et al <sup>55</sup> (2004)	22 years, female	Generalized vitiligo	Systemic PUVA therapy (cumulative dose 1750 J/cm <sup>2</sup> )	PUVA induced lentiginos	Appearance of lentiginos in addition to pigmentation of skin.

Cream,<sup>50</sup> a case report concerning the use of herbal infusion containing powdered seeds of *Psoralea corylifolia*, mentioned the adverse effects of photosensitivity,

itching of hands, erythema, and blistering. The reversal of ADR after stoppage of the infusion it was related to the use of PC. Deborah and MacDonald<sup>54</sup> reported

**Table 4** Brief Summary of Adverse Events from VigiAccess<sup>56</sup>

Name of Medicinal Plants	Total No. of Reports	Skin + Subcutaneous Tissue Disorders (No. of Reports)	Reports Related to Pigmentation Disorders	Details (Where Applicable)
<i>Centella asiatica</i> Gotu kola	122	46	0	
<i>Artemisia capillaris</i>	1	0	0	
<i>Fallopia multiflora</i>	20	0	0	
<i>Eclipta prostrata</i>	5	0	0	
<i>Rehmannia glutinosa</i>	36	2	0	
<i>Hippophae rhamnoides</i> sea buckthorn	3	1	0	
<i>Cassia fistula</i>	1	0	0	
<i>Psoralea corylifolia</i> cullen corylifolium	16	3	0	
<i>Zingiber officinale</i> Gine	108	41	0	
<i>Piper nigrum</i>	2	0		
<i>Piper longum</i>	1	0	0	
<i>Petroselinum crispum</i> parsley	25	0	0	
<i>Ammi visnaga</i>	16	2	0	
Khellin	7	2	0	
<i>Ammi visnaga</i>	16	2		
<i>Ginkgo bilobo</i>	4016	66	7	Skin discoloration
<i>Morus alba</i>	7	0	0	
<i>Aloe vera</i>	204	29	1	Skin discoloration
<i>Withania somnifera</i> ashwagandha	54	7	0	
<i>Glechoma hederacea</i>	13	0	0	
<i>Achillea millefolium</i>	4	0	0	
<i>Ricinus communis</i>	147	24	0	
<i>Vitis vinifera</i>	1729	293	11	Skin discoloration
<i>Pinus pinaster</i>	7	5	0	
<i>Juglans regia</i>	11	2	0	
<i>Picrorhiza kurroa</i>	5	0	0	

a case of serious ADR with the oral use of PC seeds. The adverse effects were cholestatic acute hepatitis, jaundice, abdominal pain, lethargy, vomiting, dark

urine, and pale stools. Acute hepatitis was reversed after stopping the use of seeds of PC. Acute hepatitis was a potential ADR of PC and manufacturers of such

products should label a warning to highlight this harmful effect of hepatitis. A study recommending no significant side effects of PC did not include the biochemistry of liver function tests, thus hepatitis was unlikely to be observed in this research.<sup>57</sup> There is need for the proper recommendation of daily dosing of PC as current recommendations are referenced from customs instead of science.<sup>58</sup> The trials to establish formal dosing is needed. VigiAccess<sup>56</sup> reported 16 cases of total adverse events with PC including 3 reports on skin and subcutaneous tissue disorders of blister, pruritus and rash. PC is believed to have its local arterial pharmacological action on plexus of the capillaries, dilating them by stimulating melanoblasts to produce pigments. The pigment penetrates in the white vitiliginous patches on skin.<sup>59</sup> Orest et al,<sup>12</sup> Ahmed et al<sup>13</sup> and Parsad et al<sup>14</sup> studied *Ginkgo biloba* clinically in vitiligo patients. There were infrequent reports on side effects related to gastrointestinal problems. *Ginkgo biloba* has been widely used in many indications. VigiAccess<sup>56</sup> reported *Ginkgo biloba* 4016 cases of total adverse events including 66 reports on skin and subcutaneous reactions and 7 reports related to pigmentation disorders (skin discoloration). Interestingly the information of skin discoloration derived from VigiAccess is opposing the use of *Ginkgo biloba* in vitiligo for the purpose of acquiring skin coloration (pigmentation). Patients using *Ginkgo biloba* are prone to be more risk of increased bleeding.<sup>60</sup> Bedi et al<sup>16</sup> has not monitored the safety of *Picrorhiza kurroa* in self controlled trials on 30 patients. Some animals studies have reported the drug as potent liver protecting agent to counter the toxicities of poisons by improving the bile flow and rectifying the liver functions.<sup>61,62</sup> Eduardo<sup>20</sup> used *Polypodium leucotomos* (PL) orally adjuvant to PUVA to treat generalized vitiligo, on the other hand, Lucy et al<sup>19</sup> tried the same plant alone in the management of melasma. Adverse effects were not monitored by Lucy et al<sup>19</sup> while no side effects were reported by Eduardo et al.<sup>20</sup> Martiza et al<sup>21</sup> in an open trial conducted on 10 patients only reported PL plus PUVA as chemophotoprotective along with adverse effects of low grade erythema. Due to its pronounced antioxidative properties PL has protective effect against the UV and PUVA induced damage to skin. It thereby decreases sun burn cells when administered orally or topically to decrease phototoxicity and erythema of psoralens.<sup>63,64</sup> Colucci et al<sup>23</sup> in an adjunct therapy for non-segmental vitiligo reported no side effects for

*Phyllanthus emblica* when used orally while in another adjunct therapy for melasma reported by Adilson et al,<sup>24</sup> adverse effects of burning, erythema, and erythematous papules were observed with topical use of the herb. VigiAccess<sup>56</sup> reported one adverse event of rash erythematous related to skin and subcutaneous reactions. Khellin has been widely studied as adjunct therapy for its anti-vitiligo effects. Adverse effects reported with adjuvant topical therapy of khellin were erythema, burning sensation and perilesional hyperpigmentation as reported by Saraceno et al<sup>29</sup> in the study for vitiligo patients. Whilst no side effects of topical khellin treated patients in vitiligo is observed by Valkova et al<sup>30</sup> or Orecchia et al.<sup>31</sup> Subjects receiving a combination of topical and oral khellin were observed to have episodes of mild nausea, some orthostatic complaints and mild derangement of liver transaminases. A case reported by Dushet et al<sup>48</sup> regarding oral plus topical administration of khellin, showed that there was marked elevation of liver transaminases along with slight hepatomegaly. The liver functions were reversed to normal after the treatment was stopped thus confirming the khellin-related ADR. It has been reported previously that use of khellin can raise the transaminases in the first two months of treatment.<sup>65</sup> The dramatic increase in values of liver enzymes was not observed in a trial on 60 patients. It was surprising that the increase in liver transaminases was reported by Dushet et al<sup>48</sup> with topical application of the khellin although systematic absorption as well as serum level of the drug was not monitored. One cannot expect the systematic absorption of the drug merely due to its topical application on vitiliginous lesions.<sup>66</sup> No liver toxicity was reported with several years' use of Khellin with a daily dosage of up to 300 mg in treatment of cardio patients.<sup>67</sup> Although some later studies have mentioned the elevation of liver enzymes with the use of Khellin plus UVA.<sup>68</sup> The results of KUVA are comparable to the findings reported with the use of PUVA but the major advantages of khellin were no side effects of mutations and phototoxic skin erythema in contrast to PUVA.<sup>69</sup> VigiAccess<sup>56</sup> reported 7 adverse effects of khellein in general and 2 of these were related to skin and subcutaneous reactions, i.e., pruritis and 4 cases related to hepatobiliary disorders. The hepatotoxicity remains the potential concern with the use of khellin. In the current systematic review Psoralens have been observed as good choice alone or in combination with phototherapy in the management of vitiligo with

common adverse effects of pruritis, phototoxic reactions, erythema (mild-severe), itching, scaling, giddiness, nausea, depigmented macules, hyperpigmentation and gastrointestinal disturbances. Concerning the reports of adverse events of psoralens, VigiAccess<sup>56</sup> reported 34 cases of total adverse events including 6 cases of skin and subcutaneous reactions (macule, psoriasis, skin disorder, skin exfoliation, skin hyperpigmentation, skin lesion, skin toxicity and urticaria). Over the centuries it has been believed that medicinal plants containing psoralens when combined with phototherapy can successfully benefit vitiligo patients<sup>70</sup> However most of the observers came across the negative results of blisters, pruritis, itching, urticaria and erythema, etc., by adopting this therapeutic strategy.<sup>71</sup> Lentigines (little brown patches on skin) a side effect has been associated with extensive use of PUVA therapies in old males of skin type V and VI. Once appeared, these PUVA induced lentigines do not subside after the discontinuation of PUVA therapy although it has been believed to be reversed with cryotherapy (cold therapy with an instrument called cryoprobe using liquid nitrogen or nitrous oxide where abnormal tissues are frozen and destroyed with the therapy).<sup>72</sup> Dilute solution of PUVA in water is termed as bath PUVA having promising advantages over topicals and oral uses of PUVA. Its delivery to the skin is uniform thus avoidance of localized phototoxic reactions as well as uneven pigmentation.<sup>73</sup> Bath PUVA reduces the long term risk of squamous cell carcinoma by reducing cumulative doses of UVA, trade off is the incidence of more common phototoxic reactions.<sup>74</sup> There are some reports of inflammatory hyperpigmentation induced by Demodex mites (*Demodex folliculorum* and *Demodex brevis*) hence the researcher may also keep in mind the such hyperpigmentation when monitoring the clinical studies related to herbs.<sup>75</sup> Friction has been mentioned as a distinct aetiology of hyperpigmentation in Indian patients<sup>76</sup> and *Demodex* inflammation has been associated to induce the frictional melanosis in influencing the hyperpigmentation.<sup>77</sup> Herbal Taraxaci, Herba Agrimoniae and Cortex Phellodendri et al have remarkable anti-mites potential along with human skin safety versus the *Demodex folliculorum*.<sup>78,79</sup> Based on in vivo melanocyte proliferation potential of Piper nigrum extract (containing piperine)<sup>80</sup> there has been a clinical human study on few patients using the piperine extract, piperine alone or piperine extract associated with

prostaglandins. Pigmentation effects were reported with such therapies and latter combination speeded up the pigmentation with changed pigmentation pattern.<sup>81</sup> The results provide a clue of future benefits of such uses if the controlled clinical studies are carried out on larger batches of patients as the existing data involve few patients (3 patients only) and 1 patient of the 3 had withdrawn from the study due to intense burning sensations, irritation and local redness. The 2 remaining patients reported a slight burning sensation on first use under an occlusive dressing. The clinical study was not controlled and the application of ointment with rubbing can give false results due to frictional melanosis. Furthermore the formulation development and characterization of the ointment before loading the drug has not been mentioned in this study on two patients.

## Limitations of the Literature Search

It is possible that not all plants were identified (in Phase 1) and that not all relevant papers were found in the second phase literature search.

## Conclusion

Primarily the retrieved clinical studies were efficacy oriented and safety parameters were secondary in priority whilst the general protocol of clinical trials requires the screening of drugs/medicinal plants on the basis of safety studies before testing the clinical aspect of efficacy. Thereby it is recommended that efficacy studies may be followed once the safety has been established for a particular medicinal plant in treating vitiligo and hypermelanosis.

## Recommendations

The author recommends similar studies related to safety of medicinal plants and reports of harm for skin ailments other than vitiligo and hypermelanosis.

## Acknowledgment

Work was undertaken while author was a visiting scholar in the School of Pharmacy, University of Auckland, New Zealand from May 2017 to October 2017. The author is thankful to Professor Dr Zaheer-Ud-Din Babar for his reference and support in getting the guidance of relevant herbal medicine expert at the University of Auckland. Databases use expert Sue Fooggin is regarded for her help in the literature search. Higher Education Commission (HEC) Pakistan is acknowledged for supporting the research. .



## Disclosure

The author reports no conflicts of interest for this work. A part of this article was made available as pre-print on research gate and will be updated accordingly once published in the journal.

## References

- Khandalavala BN, Nirmalraj MC. Rapid partial repigmentation of vitiligo in a young female adult with a gluten-free diet. *Clin Dermatol.* 2014;6(3):283–287.
- Torok HM. A comprehensive review of the long-term and short-term treatment of melasma with a triple combination cream. *Am J Clin Dermatol.* 2006;7:223–230. doi:10.2165/00128071-200607040-00003
- Khushboo PS, Jadhav VM, Kadam VJ, et al. *Psoralea corylifolia* linn. – “kushtanashini”. *Pharmacogn Rev.* 2010;4(7):69–76. doi:10.4103/0973-7847.65331
- Szczurko O, Born HS. A systematic review of natural health product treatment for vitiligo. *BMC Dermatol.* 2008;8:2. doi:10.1186/1471-5945-8-2
- Fisk WA, Agbai O, Lev-Tov HA, Sivamani RK. The use of botanically derived agents for hyperpigmentation: a systematic review. *J Am Acad Dermatol.* 2014;70(2):352–365. doi:10.1016/j.jaad.2013.09.048
- Ekor M. The growing use of herbal medicines: issues relating to adverse reactions and challenges in monitoring safety. *Front Pharmacol.* 2013;4:177.
- Masoumeh G, Ali E. Clinical efficacy of liposome-encapsulated *Aloe vera* on melasma treatment during pregnancy. *J Cosmet Laser Ther.* 2017;19(3):181–187. doi:10.1080/14764172.2017.1279329
- Shahla K, Ali A, Hossein M, et al. The efficacy of topical use of *Petroselinum crispum* (parsley) versus hydroquinone cream for reduction of epidermal melasma: a randomized clinical trial. *AJP.* 2015;5(1):124–125.
- Debbie M, Palmer DO, Jennifer SK. A double blind, randomized, controlled clinical trial evaluating the efficacy and tolerance of a novel phenolic antioxidant skin care system containing *Coffea arabica* and concentrated fruit and vegetable extracts. *J Drugs Dermatol.* 2010;9(12):1480–1487.
- Buggiani G, Tsampau D, Hercogová J, et al. Clinical efficacy of a novel topical formulation for vitiligo: compared evaluation of different treatment modalities in 149 patients. *Dermatol Ther.* 2012;25(5):472–476. doi:10.1111/j.1529-8019.2012.01484.x
- Hussain I, Hussain I, Manan A, et al. Fabrication of anti-vitiligo ointment containing *Psoralea corylifolia*: in vitro and in vivo characterization. *Drug Des Devel Ther.* 2016;10:3805–3816. doi:10.2147/DDDT.S114328
- Orest S, Neill S, Anna T, et al. *Ginkgo Biloba* for the treatment of vitiligo Vulgaris: an open label pilot clinical trial. *BMC Complement Altern Med.* 2011;21:1–9.
- Ahmed R, Abu R, Noor MA, et al. Evaluation of standardized extract of *Ginkgo Biloba* in vitiligo remedy. *Asian J Pharm Clin Res.* 2013;6(5):127–130.
- Parasad P. Effectiveness of oral *Ginkgo biloba* in treating limited, slowly spreading vitiligo. *Clin Exp Dermatol.* 2003;28:285–287. doi:10.1046/j.1365-2230.2003.01207.x
- Jun Y, Atsushi S, Shoichi T, et al. Oral intake of proanthocyanidin-rich extract from grape seeds improves chloasma. *Phytother Res.* 2004;18:895–899. doi:10.1002/ptr.1537
- Beidi KL, Usha Z, Chopra CL. *Picrorrhiza kurroa*, an ayurvedic herb, may potentiate photochemotherapy in vitiligo. *J Ethnopharmacol.* 1989;27:347–352. doi:10.1016/0378-8741(89)90009-3
- Glen A, Nino C, Ailynne V, et al. Maria Jasmin Jamora MD. A comparative study of the safety and efficacy of 75% Mulberry (*Morus alba*) Extract oil versus placebo as a topical treatment for melasma: a randomized, single-blind, placebo-controlled Trial. *J Drugs Dermatol.* 2011;10(9):1025–1031.
- Ammar M, Ahmed M, Isha L, et al. randomized, double-blinded, placebo controlled trial of oral *Polypodium leucotomos* extract as an adjunct to sunscreen in the treatment of melasma. *JAMA Dermatol.* 2013;149(8):981–983. doi:10.1001/jamadermatol.2013.4294
- Lucy K, Martin M. A randomized double-blind placebo controlled study evaluating the effectiveness and tolerability of oral polypodium leucotomos in patients with melasma. *J Am Acad Dermatol.* 2012; Ab21:4630.
- Eduardo R, Pedro J, Elena H, et al. Systemic Immunomodulatory effects of *Polypodium leucotomos* as an adjuvant to PUVA therapy in generalized vitiligo: a pilot study. *J Dermatol Sci.* 2006;41:213–216. doi:10.1016/j.jdermsci.2005.12.006
- Martiza A, Middelkamp H, Madhu A, et al. Orally administered *Polypodium leucotomos* extract decreases psoralen UVA induced phototoxicity, pigmentation, and damage of human skin. *J Am Acad Dermatol.* 2004;50:41–49. doi:10.1016/S0190-9622(03)02732-4
- Mark S, Nestor BD, Nicole S. Safety and efficacy of oral *Polypodium leucotomos* extract in healthy adult subjects. *J Clin Aesthet Dermatol.* 2015;8(2):19–23.
- Colucci R, Dragoni F, Conti R. Evaluation of an oral supplement containing *Phyllanthus emblica* fruit extracts, vitamin E, and carotenoids in vitiligo treatment. *Dermatolog Treat.* 2015;28:17–21. doi:10.1111/dth.12172
- Adilson C, Tatiana C, Juliana M. Association of *emblica*, licorice and *belides* as an alternative to hydroquinone in the clinical treatment of melasma. *An Bras Dermatol.* 2010;85(5):613–620. doi:10.1590/S0365-05962010000500003
- Ni Z, Mu Y, Gulati O. Treatment of melasma with pycnogenol. *Phytother Res.* 2002;16:567–571. doi:10.1002/ptr.1085
- Mendoza CG. A randomized, double blind, placebo-controlled clinical trial on the efficacy of 3% *Rumex occidentalis* cream versus 4% hydroquinone cream in the treatment of melasma among Filipinos. *Int J Dermatol.* 2014;53:1412–1416. doi:10.1111/ijd.12690
- Morag M, Nawrot J, Siatkowski I, et al. A double-blind, placebo-controlled randomized trial of *Serratulae quinquefoliae folium*, a new source of  $\beta$ -arbutin, in selected skin hyperpigmentations. *J Cosmet Dermatol.* 2015;14(3):185–190. doi:10.1111/jocd.12147
- Leeuw JD, Assen YJ, Van N, et al. Treatment of vitiligo with khellin liposomes, ultraviolet light and blister roof transplantation. *J Eur Acad Dermatol Venereol.* 2011;25(1):74–81. doi:10.1111/j.1468-3083.2010.03701.x
- Saraceno R, Steven P. Nistico, monochromatic excimer light 308 nm in monotherapy and combined with topical khellin 4% in the treatment of vitiligo: a controlled study. *Dermatolog Treat.* 2009;25:391–394. doi:10.1111/j.1529-8019.2009.01252.x
- Valkova TC. Treatment of vitiligo with local Khellin and UVA: comparison with systemic PUVA. *Clin Exp Dermatol.* 2003;29:180–184. doi:10.1111/j.1365-2230.2004.01462.x
- Orecchia G, Sangalli M, Gazzaniga A, Giordano F. Topical photochemotherapy of vitiligo with a new Khellin formulation. *J Dermatolog Treat.* 1998;9(2):65–69. doi:10.3109/09546639809161375
- Procaccini E, Riccio G, Monfrecola G. Ineffectiveness of topical Khellin in photochemotherapy of vitiligo. *J Dermatolog Treat.* 1995;6(2):117–120. doi:10.3109/09546639509097164
- Bernhard O, Adrian T, Herbert H. Treatment of vitiligo with Khellin and Ultraviolet A. *J Am Acad Dermatol.* 1988;18:693–701. doi:10.1016/S0190-9622(88)70092-4
- Mofty M, Bosseila M, Mashaly HM, et al. Broadband ultraviolet A vs. psoralen ultraviolet A in the treatment of vitiligo: a randomized controlled trial. *Clin Exp Dermatol.* 2013;38(8):830–835. doi:10.1111/ced.12099



35. Shivani B, Bijaylaxmi S, Vijay G. Psoralen-narrowband UVB phototherapy for the treatment of vitiligo in comparison to narrowband UVB alone. *Photodermatol Photoimmunol Photomed*. 2013;29:311–317. doi:10.1111/phpp.12072
36. Ranjeeta S, Sudha A, Tapan K. Systemic PUVA vs narrowband UVB in the treatment of Vitiligo: a randomized controlled Study. *Int J Dermatol*. 2012;51:1107–1115. doi:10.1111/j.1365-4632.2011.05454.x
37. Yones SS, Palmer RA, Garibaldinos TM, Hawk JL. Randomized double-blind trial of treatment of Vitiligo: efficacy of psoralen–UV-A therapy vs narrowband–UV-B therapy. *Arch Dermatol*. 2007;143:578–584. doi:10.1001/archderm.143.5.578
38. Bhatnagar A, Kanwar AJ, Parsad D, De D. Psoralen and ultraviolet A and narrow-band ultraviolet B in inducing stability in vitiligo, assessed by vitiligo disease activity score: an open prospective comparative study. *J Eur Acad Dermatol Venereol*. 2007;21(10):1381–1385. doi:10.1111/j.1468-3083.2007.02283.x
39. Ermis A. Is the efficacy of Psoralen plus ultraviolet A therapy for vitiligo enhanced by concurrent topical calcipotriol? A placebo-controlled double-blind study. *Br J Dermatol*. 2001;145:472–475. doi:10.1046/j.1365-2133.2001.04286.x
40. Ameen E, Chu A. Topical calcipotriol as monotherapy and in combination with psoralen plus ultraviolet A in the treatment of vitiligo. *Br J Dermatol*. 2001;145:476–479. doi:10.1046/j.1365-2133.2001.04381.x
41. Parsad D, Saini R, Verma N. Combination of PUVA and topical calcipotriol in Vitiligo. *Dermatology*. 1998;197(2):167–170. doi:10.1159/000017991
42. Parasad D, Roma P, Sunil D, et al. Clinical study of repigmentation patterns with different treatment modalities and their correlation with speed and stability of repigmentation in 352 vitiliginous patches. *J Am Acad Dermatol*. 2004;50(1):63–67. doi:10.1016/S0190-9622(03)00786-2
43. Wiete W, Ludmila N. Treatment of vitiligo with UV-B radiation vs topical psoralen plus UV-A. *Arch Dermatol*. 1997;133:1525–1528. doi:10.1001/archderm.1997.03890480045006
44. Mofty A, Hussein E. Clinical study of a new preparation of 8-methoxypsoralen in photochemotherapy. *Int J Dermatol*. 1994;33(8):588–593. doi:10.1111/j.1365-4362.1994.tb02904.x
45. Africk J, Fulton J. Treatment of vitiligo with topical trimethylpsoralen and sunlight. *Br J Dermatol*. 1989;84:151–156. doi:10.1111/j.1365-2133.1971.tb06858.x
46. Sehgal. A comparative clinical evaluation of trimethylpsoralen, psoralen and 8-methoxypsoralen in treating vitiligo. *Int J Dermatol*. 1975;14:205–208. doi:10.1111/ijd.1975.14.3.205
47. Mofty AME, Nada MM. On the treatment of vitiligo. *Int J Dermatol*. 1971;10(4):262–266. doi:10.1111/j.1365-4362.1971.tb01709.x
48. Dushet P, Schwarz T, Pusch M, Gshnait F. Marked increase of liver transaminases after khellin and UVA therapy. *J Am Acad Dermatol*. 1989;21(3):592–593. doi:10.1016/S0190-9622(89)80248-8
49. Kreuter A, Gambichier AA, Jansen T. Localized vitiligo successfully treated with cream-psoralen + Ultraviolet A. *J Eur Acad Dermatol Venereol*. 2001;15:357–358.
50. Maurice CJ. The dangers of herbalism. *BMJ*. 1989;299:1204. doi:10.1136/bmj.299.6709.1204
51. David W, Mai CO. Childhood vitiligo successfully treated with Bath PUVA. *Pediatr Dermatol*. 1998;15(1):53–55. doi:10.1046/j.1525-1470.1998.1998015053.x
52. Zouhir D. Successful treatment of facial vitiligo with honey bee, *Allium cepa* and *Avena sativa* combined to sun light exposure: a case clinical trial. *Int J Pharm Clin Res*. 2015;7(1):9–14.
53. Rigmor M, Jette H. Methoxsalen and multiple basal cell carcinomas. *Arch Dermatol*. 1976;112:1613–1614. doi:10.1001/archderm.1976.01630350079027
54. Deborah AS, Stewart M. A rare case of acute hepatitis induced by use of Babchi seeds as an ayurvedic remedy for vitiligo. *BMJ Case Rep*. 2014;1–3. doi:10.1136/bcr-2013-200958
55. Abdel N, Okby WM. Psoralen plus ultraviolet A irradiation-induced lentiginous arising in vitiligo: involvement of vitiliginous and normal appearing skin. *Clinical Dermatol*. 2004;29:380–382.
56. World Health Organization. TM.VigiAccess Available from: [www.vigiaccess.org](http://www.vigiaccess.org). Accessed December 9, 2017.
57. Donata SR, Kesavan M, Austin KS, Rajagopalan K, Kuttan R. Clinical trial of certain ayurvedic medicines indicated in vitiligo. *Anc Sci Life*. 1990;9:202–206.
58. Psoralea corylifolia. Available from: <http://examine.com/supplements/Psoralea+Corylifolia/summary2-1>. Accessed 22 Jul 2013.
59. New WB. *Manual of Homeopathic Materia Medica and Repertory*. 9th ed. New Delhi: B. Jain Publishers Pvt. Ltd; 2002:11–29.
60. Stephen B, Harley G, Amy P, et al. Spontaneous bleeding associated with Ginkgo biloba. A case report and systematic review of the literature. *J Gen Intern Med*. 2005;20:657–661. doi:10.1007/s11606-005-0114-4
61. Ansari R, Aswal B, Chander R, et al. Hepatoprotective activity of kutin- the iridoid glycoside mixture of Picrorhiza Kurroa. *Indian J Med Res*. 1988;87:401–404.
62. Handa S, Sharma A, Chakraborty K. Natural products and plants as liver protecting drugs. *Fitoterapia*. 1986;58:307–351.
63. Middelkamp-Hup MA, Pathak MA, Parrado C, et al. Oral Polypodium leucotomos extract decreases ultraviolet-induced damage of human skin. *J Am Acad Dermatol*. 2004;51:910–918. doi:10.1016/j.jaad.2004.06.027
64. Gonzales S, Pathak MA, Cuevas J, Villarrubia VG, Fitzpatrick TB. Topical or oral administration with an extract of Polypodium leucotomos prevents acute sunburn and-psoralen induced phototoxic reactions as well as depletion of Langerhans cells in human skin. *Photodermatol Photoimmunol Photomed*. 1997;13:50–60. doi:10.1111/j.1600-0781.1997.tb00108.x
65. Anrep GV, Kenawy MR, Barsoum GS. The coronary vasodilator action of khellin. *Am Heart J*. 1949;37:531–542. doi:10.1016/0002-8703(49)91131-X
66. Herbert Hbnigsmann MD, Bernhard Ortel MD, Tanew A. Reply. *J Am Acad Dermatol*. 1989;21(3):593–594. doi:10.1016/S0190-9622(89)80249-X
67. Armbrust CA, Levine SA. The treatment of angina pectoris with a preparation of khellin. *Am J Med Sci*. 1950;220:127. doi:10.1097/0000441-195008000-00002
68. Hofer A, Karl H, Wolf P. Long-term results in the treatment of vitiligo with oral khellin plus UVA. *Eur J Dermatol*. 2001;11:225–229.
69. Morliere P, Honigsmann H, Averbeck D. Phototherapeutic, photobiologic and photosensitizing properties of Khellin. *J Invest Dermatol*. 1988;90:720–724. doi:10.1111/1523-1747.ep13083852
70. Ortonne J. Psoralen therapy in vitiligo. *Clin Dermatol*. 1989;7(2):120–135. doi:10.1016/0738-081X(89)90062-X
71. Said HM. *Hamdard pharmacographica. Indica*. 1972;XV(Special Issue):412–413.
72. Leroy D, Dompmartin A, Dubreuil A, et al. Cryotherapy of PUVA lentiginous. *Br J Dermatol*. 1996;135:988–990. doi:10.1046/j.1365-2133.1996.d01-1108.x
73. Collins P, Rogers S. Bath water compared with oral delivery of 8-methoxypsoralen PUVA for chronic plaque type psoriasis. *Br J Dermatol*. 1992;127:392–395. doi:10.1111/j.1365-2133.1992.tb00460.x
74. Ortel B, Perl S, Kinacian T, et al. Comparison of narrow-band (311 nm). UVB and broad band UVA after oral or bath water 8-methoxypsoralen in the treatment of Psoriasis. *J Am Acad Dermatol*. 1993;29:736–740. doi:10.1016/0190-9622(93)70239-P

75. Forton F, Germaux MA, Brasseur T, et al. Demodicosis and rosacea: epidemiology and significance in daily dermatologic practice. *J Am Acad Dermatol.* 2005;52:74–87. doi:10.1016/j.jaad.2004.05.034
76. mutalik SD, Pethe SV, Nikam BP, et al. Facial frictional melanosis in Indian patients: defining the entity. *Clin Dermatol Rev.* 2019;3(1):78–83. doi:10.4103/CDR.CDR\_6\_18
77. Shekhaar N, Radhakrishnan PK. Demodex induced facial frictional melanos. *Aust J Dermatol.* 2020;61(4):e490–e492.
78. Tian Y, Li CP, Deng Y. Anti-mite activity and skin safety of Herbal taraxaci extract for Demodex folliculorum. *Zhongguo Ji Sheng Chong Xue Yu Ji Sheng Chong Bing Za Zhi.* 2007;25(2):133–136.
79. Tian Y, Li CP. Anti-mite activities of 25 kinds of traditional Chinese medicines for Demodex folliculorum]. *Zhong Yao Cai.* 2006;10:1013–1015.
80. Faas L, Venkatasamy R, Hider RC, Young AR, Soumyanath A. In vivo evaluation of piperine and synthetic analogues as potential treatments for vitiligo using a sparsely pigmented mouse model. *Br J Dermatol.* 2008;158:941–950. doi:10.1111/j.1365-2133.2008.08464.x
81. Mihăilă B, Dinică RM, Tatu A, et al. New insights in vitiligo treatments using bioactive compounds from Piper nigrum. *Exp Ther Med.* 2019;17(2):1039–1044. doi:10.3892/etm.2018.6977

## Clinical, Cosmetic and Investigational Dermatology

Dovepress

### Publish your work in this journal

Clinical, Cosmetic and Investigational Dermatology is an international, peer-reviewed, open access, online journal that focuses on the latest clinical and experimental research in all aspects of skin disease and cosmetic interventions. This journal is indexed on CAS.

The manuscript management system is completely online and includes a very quick and fair peer-review system, which is all easy to use. Visit <http://www.dovepress.com/testimonials.php> to read real quotes from published authors.

Submit your manuscript here: <https://www.dovepress.com/clinical-cosmetic-and-investigational-dermatology-journal>