




# Ultrasound-Guided Cervical Intradiscal Injection with Platelet-Rich Plasma with Fluoroscopic Validation for the Treatment of Cervical Discogenic Pain: A Case Presentation and Technical Illustration

This article was published in the following Dove Press journal:  
*Journal of Pain Research*

King Hei Stanley Lam <sup>1</sup>  
Chen-Yu Hung <sup>2</sup>  
Tsung-Ju Wu <sup>3,4</sup>

<sup>1</sup>Department of Family Medicine, Faculty of Medicine, The Chinese University of Hong Kong, Hong Kong; <sup>2</sup>Department of Physical Medicine and Rehabilitation, National Taiwan University Hospital, Bei-Hu Branch, Taipei, Taiwan; <sup>3</sup>Graduate Institute of Basic Medical Science, China Medical University, Taichung, Taiwan; <sup>4</sup>Department of Physical Medicine and Rehabilitation, Yuanlin Christian Hospital, Changhua, Taiwan

**Abstract:** Chronic neck pain has a high incidence and prevalence in urban society. Cervical disc-related chronic neck pain with its referred pain is one of the most common causes. Traditionally, pain caused by a cervical disc is diagnosed by fluoroscopy-guided provocative discography. In this report, we presented a patient with chronic neck and shoulder pain and a technique of using ultrasound to guide the needle entry to the cervical discs which were suspected to be the cause of the patient's chronic neck and shoulder pain. The needle placement was then validated by contrast fluoroscopy. The patient's symptoms significantly improved three weeks after the procedure. In conclusion, US can serve as a good imaging guiding tool for cervical intradiscal injections.

**Keywords:** platelet-rich plasma, ultrasound, cervical, intradiscal injection, discogenic pain

## Introduction

Neck pain is a significant public health problem worldwide, with a lifetime prevalence rate of 66% and a 14% chance for progression to chronic neck pain.<sup>1,2</sup> Cervical discogenic pain is one of the most common causes of chronic neck pain, with a reported prevalence between 16% and 41%.<sup>3</sup> Its diagnosis is usually confirmed by provocative discography under fluoroscopy guidance to reproduce the concordant pain. Most of the pain can be managed with conservative treatments while anterior cervical fusion or artificial disc replacement may be required for refractory and severe patients.<sup>3</sup> Recently, platelet-rich plasma (PRP) has become an evolving therapy for various musculoskeletal conditions. Although specific evidence for cervical discogenic pain is still lacking, current studies have demonstrated the efficacy of intradiscal PRP injections for the treatment of discogenic lower back pain.<sup>4</sup>

In recent years, ultrasound (US) has merged as a tool utilized in the performance of chronic pain interventions owing to its several advantages such as portability, real-time guidance, and being free of radiation. Besides, US promptly depicts soft tissue structures and therefore is especially beneficial in cervical spine injections as multiple vulnerable nerves and vessels are compacted within the small region. Herein, we present a female patient who underwent US-guided cervical intradiscal PRP injection for the treatment of her chronic neck and shoulder pain, and

Correspondence: Chen-Yu Hung  
Department of Physical Medicine and Rehabilitation, National Taiwan University Hospital, Bei-Hu Branch, Taipei, Taiwan  
Email chenyu810@gmail.com

illustrated an US-guided injection technique. The research was performed according to the Declaration of Helsinki principles. Written informed consent has been provided by the patient to have the case details and any accompanying images published. The approval by the institutional review board was waived as there was no identifiable information in this case report.

## Case

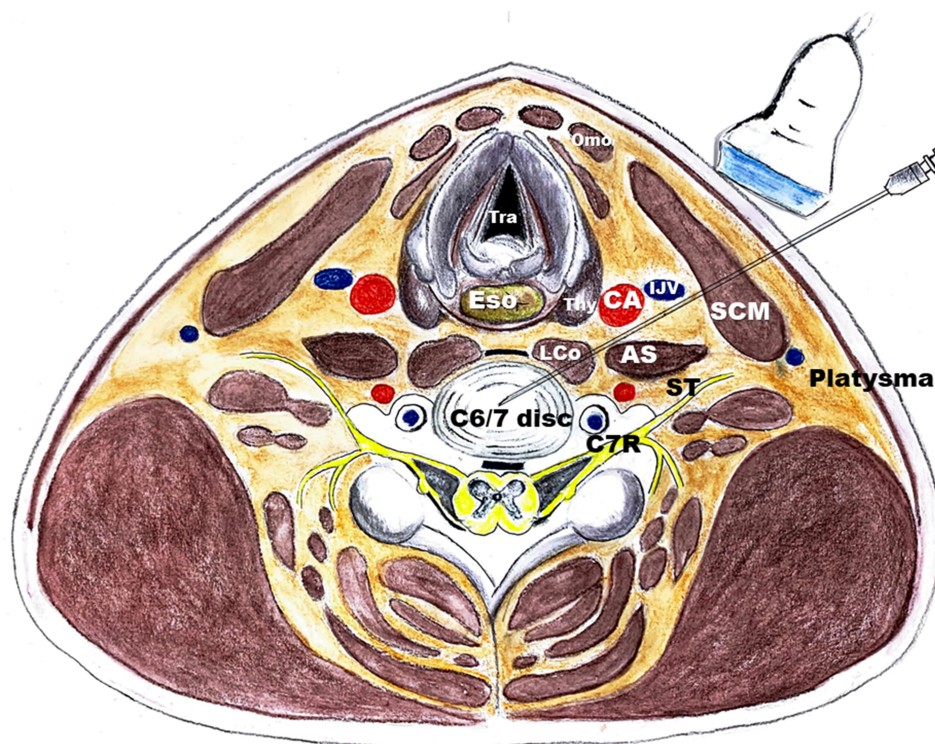
A 58-year-old woman complained of chronic neck pain (VAS 6–7) and tightness for several years. The neck pain was stronger on the left side and would radiate to the interscapular region. Six months before, she gradually developed left shoulder pain (VAS 6–7) which worsened (VAS 8–9) at night. She underwent 16 sessions of physical therapy with limited improvement. On physical examination, the range of motion (ROM) of the neck was 45 degrees for left rotation and for left side bending, 60 degrees for right rotation and for right side bending, 30 degrees for flexion, and 35 degrees for extension. Local tenderness over the left cervical paraspinal muscle, longus colli and longus capitis muscles were noted. The physical examination of the left shoulder was normal except mild snapping during repeated internal and external rotations. The neurological examination revealed slightly diminished pin-prick sensations over the left C6 and C7 dermatomes. The Neck Disability Index (NDI) was 40% (moderate disability) at the baseline and 50% (severe disability) at the most severe time. The Shoulder Pain and Disability Index (SPADI) was 55% at baseline and 70% when it was more painful during sleep. The magnetic resonance imaging (MRI) of the left shoulder was normal. The MRI of the cervical spine revealed C5/6 and C6/7 desiccated discs and a broad base posterior disc protrusion, slightly more prominent over the left side. When treatment options were discussed, the patient refused transforaminal epidural steroid injection for fear of the side effects of steroids. Instead, she opted to receive US-guided provocative discography in combination with a possible PRP intradiscal injection.

Provocative discography with contrast was performed to the C5/6 and C6/7 discs under US guidance with fluoroscopy confirmation. When the contrast was injected to the C5/6 and C6/7 discs, part of the shoulder pain was provoked, respectively, covering exactly all the shoulder pain areas the patient had complained of. Afterwards, PRP (Harvest, USA) mixed with 0.1% lidocaine was injected to each level and the injection eliminated the left shoulder pain of the patient. No procedure-related complications

were reported. Three weeks after the procedure, her neck pain had significantly improved (VAS 0–1). The ROM of the neck was 70 degrees for left rotation, 60 degrees for left side bending, almost 90 degrees for right rotation and 70 degrees for right side bending. The flexion was 45 degrees and the extension was 50 degrees. The NDI was 20% and the SPADI was also 20% after the injection into the desiccated cervical discs.

For performing the US-guided cervical intradiscal injection, the patient was placed in a supine position with a towel roll under the neck and a small pillow under the upper back to hyperextend the neck and open up the anterior intervertebral spaces. The physician was seated on the patient's symptomatic side for the needle entrance and the US device and monitor were placed opposite to the physician for better ergonomics. Antibiotics (Cefazolin 1 g) were injected intravenously 30 minutes before the procedure for infection prophylaxis. A scout scanning was first performed by placing a high-frequency linear transducer in the transverse plane on the lateral aspect of the neck. The C6 vertebra level was identified as the most caudal cervical vertebra that had both the anterior and posterior tubercles of the transverse process while the C7 vertebra only had the posterior tubercle. The prominent C6 anterior tubercle (also called the Chassaignac's tubercle) served as a landmark. Rotating the transducer in the long axis of the neck and sliding toward the midline, the intervertebral disc spaces were visualized as the gaps between each vertebral bony cortex. The intervertebral disc distal to the Chassaignac's tubercle level was the C6/7 disc and the disc proximal to that was the C5/6 disc. The physician then placed the center of the transducer at the targeted level of the intervertebral disc and marked a horizontal line for entry.

A complete aseptic technique was used throughout the procedure. The skin was prepped with chlorhexidine solution and the solution remained on the skin for at least two minutes to kill the skin bacteria that are usually implicated in deep tissue infections following skin puncture.<sup>5</sup> The injection was performed with a lateral-to-medial in-plane approach with the transducer placed transversely at the marked level. In order to pass the obstruction of the uncovertebral joint which was located at the posterolateral aspect of the intervertebral disc,<sup>6</sup> the needle should enter the disc as medial as possible. Therefore, the needle entry point was determined with the trajectory just passing the lateral edge of the internal jugular vein (IJV) to have enough angle to avoid the uncovertebral joint and enter the disc (Figure 1). The needle was advanced through the



**Figure 1** The cross-sectional anatomy and the needle trajectory of ultrasound-guided intradiscal injection using C6/7 level as an illustration.

**Abbreviations:** AS, anterior scalene; C7R, C7 root; CA, carotid artery; Eso, esophagus; LCo, longus colli; Omo, omohyoid; SCM, sternocleidomastoid muscle; ST, superior trunk of brachial plexus; Tra, trachea; Thy, thyroid.

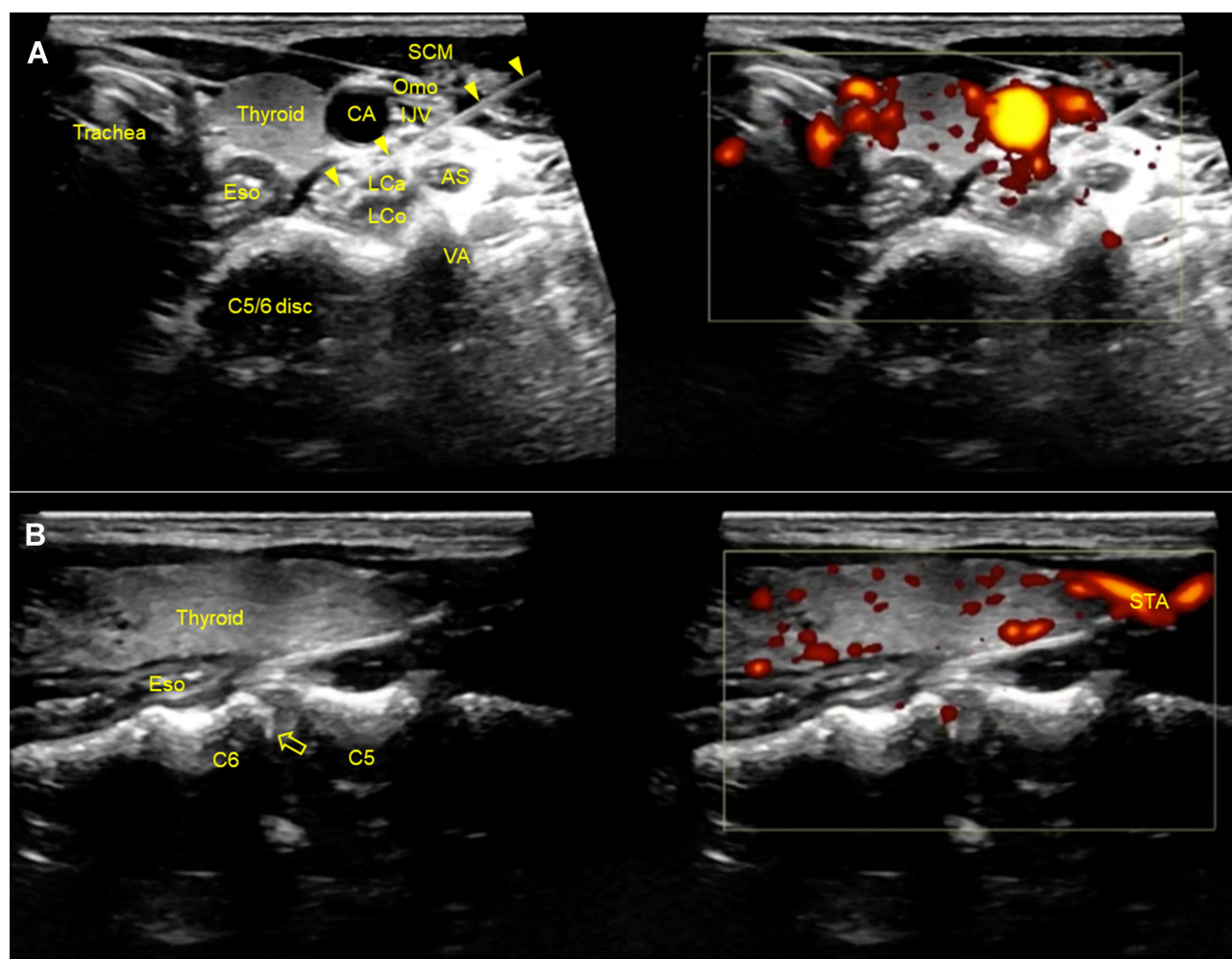
sternocleidomastoid (SCM), anterior scalene, longus capitis (if the targeted disc level was proximal to the C5/6), and longus colli muscles. The needle passage between the carotid artery and the IJV was sometimes utilized to ensure the trajectory was steep enough to skip the uncovertebral joint if the former needle entry point failed. A hydrodissection technique using 5% dextrose as injectate could be used to push away the IJV or other neural structures (such as the cervical nerve root, the phrenic nerve and the vagus nerve) encountered in the trajectory.<sup>7</sup> A dual-split display with one in power Doppler mode was used to visualize the critical vascular structures, with the attention especially focused on the vertebral artery. After the needle had reached the annulus fibrosus (Figure 2A), the transducer was rotated to the long axis of the neck to check the needle tip position out-of-plane and perform fine adjustment to enter the disc (Figure 2B). When the needle was inside the disc, the needle placement could be validated with the poking technique under in-plane and out-of-plane ultrasound imaging (Video 1). The video demonstrated the in-plane, lateral to medial approach of the ultrasound-guided intradiscal injection with the transducer placed in the short-axis of the

cervical spine. After the needle had reached at the annulus fibrosus, the transducer was rotated to the long-axis of the cervical spine to check the needle tip position out-of-plane. Further validation could be achieved by injecting the contrast and visualizing the spread of the contrast under fluoroscopy (Figure 3). The patient should feel the concordant pain during the injection. The PRP was then injected to the center of the disc (about 0.5 to 1 mL).

## Discussion

The cervical discography is traditionally performed under fluoroscopy guidance with two approaches: the midline approach and the lateral approach.<sup>8</sup> In the midline approach, firm but gentle pressure is applied with the index finger to the space between the medial border of the SCM and the trachea, and the needle entry point is medial to the medial border of the SCM. The major concern involved in this approach is the vasovagal reflex which may be caused due to the compression of the carotid artery during manual displacement. In the lateral approach, the needle entry point is over the lateral neck muscles and posterior to the great vessels, and the aimed insertion point is slightly anterior to the anterior margin of the uncinate process. The major concern here is the puncture



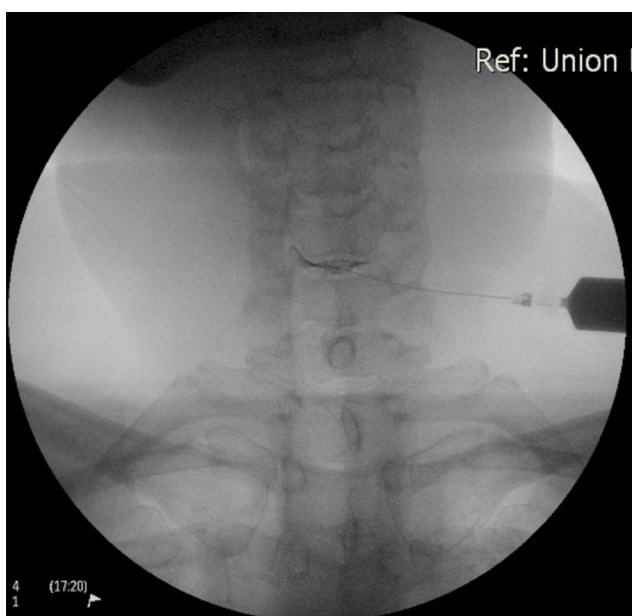


**Figure 2** Short- (A) and long-axis (B) ultrasound imagings of the cervical spine showing the in-plane and out-of-plane injection of the C5/6 intervertebral disc respectively. Dual-split display is used with B-mode on the left side and power Doppler mode on the right side. Arrowheads, needle shaft; void arrowhead, needle tip.

**Abbreviations:** AS, anterior scalene; CA, carotid artery; Eso, esophagus; IJV, internal jugular vein; LCa, longus capitis; LCo, longus colli; Omo, omohyoid; SCM, sternocleidomastoid muscle; STA, superior thyroid artery; VA, vertebral artery.

of the vertebral artery/vein which may be encountered at the trajectory with this approach. Samer Narouze had previously described US-assisted cervical discography which utilized a similar needle trajectory as the lateral approach of the fluoroscopy-guided discography.<sup>9</sup> Our US-guided procedure also utilized the same needle path. What we have elaborated in the technique is that we utilized the long-axis view to mark the needle insertion and to later confirm the needle tip position at the annulus. Also, the traditional cervical discography uses a right-sided approach as the esophagus is usually on the left side. Our technique demonstrated the feasibility and safety of the US-guided procedure performing from the left side without increasing the risk of esophagus injury as the needle shaft and tip were visualized at all times. This is sometimes necessary as the discogenic symptoms on the left side (like our patient) should come from a left-sided disc lesion.

Comparing with fluoroscopy-only discography, an US-guided procedure has several advantages. First, soft tissues including vessels and neural structures can not be visualized under fluoroscopy. Although the complication rate of cervical discography is rare, with the discitis being the most common problem, vascular and neural puncture injury are still potential complications.<sup>10,11</sup> With the familiarization of the cervical sonoanatomy and the use of Doppler mode, the needle path can be planned to avoid inadvertent injuries. Second, the needle trajectory can be determined as close to the IJV as possible, making it easier to pass the blockage of the uncovertebral joint. Last, US-guided injection can shorten the procedure time and decrease both the physical load and radiation exposure. To conclude, intradiscal PRP injection is a possibly effective treatment for



**Figure 3** The anteroposterior fluoroscopy view validating the needle placement and contrast spread during the injection of C5/6 intervertebral disc.

cervical discogenic pain, and US can serve as a good imaging tool to guide the procedure.

## Acknowledgment

The authors appreciate Dr. Dick Hui for drawing Figure 1 in this article.

## Funding

No funding was received.

## Disclosure

The authors declared no conflicts of interest existed.

## References

1. Bovim G, Schrader H, Sand T. Neck pain in the general population. *Spine*. 1994;19(12):1307–1309. doi:10.1097/00007632-199406000-00001
2. Cote P, Cassidy JD, Carroll L. The Saskatchewan health and back pain survey. The prevalence of neck pain and related disability in Saskatchewan adults. *Spine*. 1998;23(15):1689–1698. doi:10.1097/00007632-199808010-00015
3. Peng B, DePalma MJ. Cervical disc degeneration and neck pain. *J Pain Res*. 2018;11:2853–2857. doi:10.2147/JPR.S180018
4. Mohammed S, Yu J. Platelet-rich plasma injections: an emerging therapy for chronic discogenic low back pain. *Int J Spine Surg*. 2018;4:115–122. doi:10.21037/jss.2018.03.04
5. Singh V. The role of cervical discography in interventional pain management. *Pain Physician*. 2004;7:249–255.
6. Kocabiyyik N, Ercikti N, Tunali S. Morphometric analysis of the uncinate processes of the cervical vertebrae. *Folia Morphol*. 2017;76:440–445. doi:10.5603/FM.a2017.0010
7. Lam SKH, Reeves KD, Cheng AL. Transition from deep regional blocks toward deep nerve hydrodissection in the upper body and torso: method description and results from a retrospective chart review of the analgesic effect of 5% dextrose water as the primary hydrodissection injectate to enhance safety. *Biomed Res Int*. 2017;2017:7920438.
8. Deer TR, Leong MS, Ray AL. American Academy of Pain Medicine. *Treatment of Chronic Pain by Integrative Approaches: The American Academy of Pain Medicine Textbook on Patient Management*. xix, 2015:325.
9. Narouze S. *Atlas of Ultrasound-Guided Procedures in Interventional Pain Management*. cm; Springer: 2011.
10. Grubb SA, Kelly CK. Cervical discography: clinical implications from 12 years of experience. *Spine*. 2000;25(11):1382–1389. doi:10.1097/00007632-200006010-00010
11. Guyer RD, Ohnmeiss DD, Mason SL, Shelokov AP. Complications of cervical discography: findings in a large series. *J Spinal Disord*. 1997;10(2):95–101. doi:10.1097/00002517-199704000-00001

Journal of Pain Research

Publish your work in this journal

The Journal of Pain Research is an international, peer reviewed, open access, online journal that welcomes laboratory and clinical findings in the fields of pain research and the prevention and management of pain. Original research, reviews, symposium reports, hypothesis formation and commentaries are all considered for publication. The manuscript

Submit your manuscript here: <https://www.dovepress.com/journal-of-pain-research-journal>

Dovepress

management system is completely online and includes a very quick and fair peer-review system, which is all easy to use. Visit <http://www.dovepress.com/testimonials.php> to read real quotes from published authors.