

Post open prostatectomy bladder exteriorization mimicking “acquired bladder extrophy”

AO Takure¹
VC Onuora²
W Akerele³

¹Urology Division, Department of Surgery, University College Hospital, Ibadan, Nigeria; ²College of Health Sciences, Igbinedion University, Okada, Benin, Nigeria; ³Urology Unit, Department of Surgery, Irrua Specialist Teaching Hospital, Irrua, Nigeria

Abstract: A 58-year-old Nigerian male had open prostatectomy undertaken in a private hospital 3 months before presenting at our out-patient clinic with leakage of urine and a widening supra pubic defect of 10 weeks duration. Examination showed the posterior bladder wall and visible trigone. Subsequently the defect was closed and he remained continent at follow up.

Keywords: post open prostatectomy, bladder exteriorization, adult bladder extrophy

Background

Open prostatectomy is commonly done in rural Nigeria and similar areas in the African subcontinent. However, transurethral resection of the prostate (TURP), transvesical single port prostatectomy and recently holmium laser enucleation of the prostate (HoLEP) is increasingly performed in the United States, Europe and Asia. Whatever the surgical option of treatment, there are recognizable complications following each surgery. We present urinary bladder exteriorization following open transvesical prostatectomy in Nigeria.

Case presentation

A case report of a 58-year-old male laboratory chemical technician, nonhypertensive and nondiabetic (mellitus), presented at the out-patient clinic with a 10-week history of continuous leakage of urine from the suprapubic area and an increasing widening of defect. He was a nonsmoker and did not drink alcohol. He had open prostatectomy undertaken 2 weeks prior to the leakage of urine in a private hospital in a cosmopolitan city in Nigeria. Repeat surgery could not correct the defect. He had been changing his urethral catheter every 2 weeks.

Physical examination showed an anterior abdominal wall defect that measured 8 cm × 10 cm, with visualization of the urinary bladder trigone and hyperpigmented skin of the surrounding abdominal wall (Figure 1). His haematocrit and serum urea and electrolytes values were within normal limits. A urine culture yielded lactose forming coliform bacteria, sensitive to colistin but resistant to quinolone, amoxicillin, ceftriaxone, cotrimoxazole, nalidixic acid, amino glycoside and nitrofurantoin. He was thus treated for the urinary tract infection with colistin. He had closure of the extrophy (Figure 2) of the anterior abdominal defect that measured 8 cm × 10 cm. During the operation the following observations were made: there was complete exteriorization of the posterior bladder wall with both ureteric orifices visible, there was dense fibrosis around the wound edge and deficient bladder neck.

Correspondence: AO Takure
Urology Division, Department of Surgery,
University College Hospital, Ibadan,
Nigeria
Email aotakure@yahoo.com

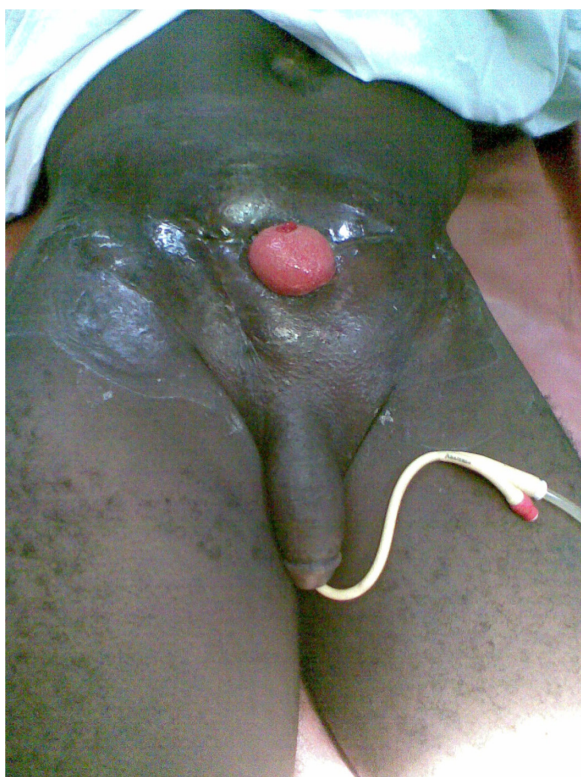


Figure 1 Post open prostatectomy bladder exteriorization (POP-BE).

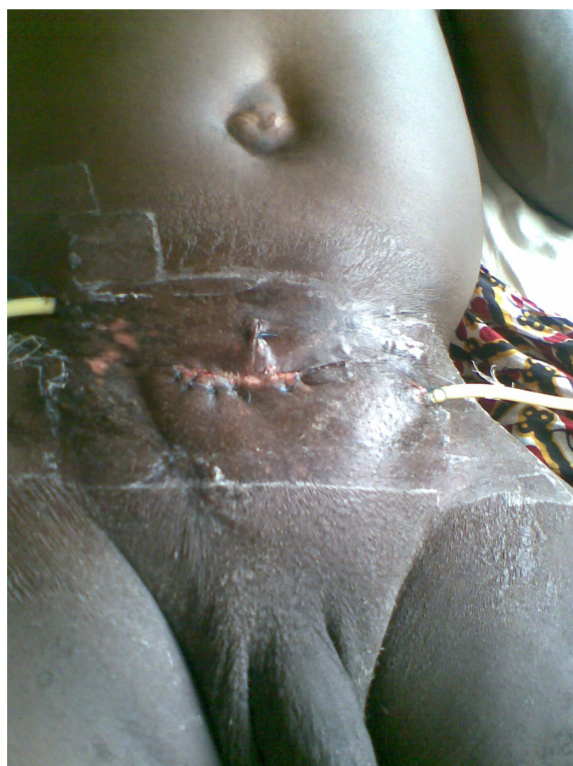

Figure 2 Postoperative closure of post open prostatectomy bladder exteriorization.

The bladder was mobilized, reconstructed and closed in two layers with absorbable 2/0 chromic catgut. A layered anterior abdominal wall closure was undertaken. The retro-pubic space was drained with a fenestrated Foley's catheter size 18 Fr, and the bladder drained through a separate stab wound. A urethral catheter was inserted. The patient had a cystogram performed 3 weeks post surgery that revealed no bladder leakage (Figure 3). He was discharged and has remained continent in the postoperative period.

Discussion

Benign prostatic enlargement (BPE) or benign prostatic hyperplasia (BPH) is the most common prostatic condition affecting middle-aged and elderly men.^{1,2} The prevalence of clinical BPH within an individual community of men aged between 55 to 75 years may vary from less than 5% to more than 30%.³

BPH is often indicated from filling and storage symptoms (irritative symptoms) and voiding symptoms (obstructive symptoms), also referred to as lower urinary tract symptoms (LUTS), together with acute urinary retention. Digital rectal examination often reveals a firm, smooth, enlarged prostate gland with a preserved median groove. Elongated verumontanum and occluding lateral lobes of the prostate seen in urethroscopy

and transrectal ultrasonographic investigation referred to as homogeneous prostatic architecture.¹⁻³

The American Urological Association symptom index or International Prostate Symptom Score (IPSS) categorized as minor (0–7), moderate (8–19), and severe (20–35) can assist in deciding the appropriate treatment option.³ These includes medical minimal invasive techniques,⁴ transurethral resection of the prostate (TURP), and open surgical enucleation.

TURP is the gold standard surgical treatment of BPE. The recognized complications include; retrograde ejaculation (75%), impotence (5%–10%), incontinence (<1%), and transurethral resection (TUR) syndrome that tends to occur; 90 minutes after resection, resection of a prostate gland greater than 75 g and intestinal obstruction.^{5,6}

Recently holmium laser enucleation of the prostate (HoLEP) is said to be cheaper and more effective, when compared to open prostatectomy, and has minimal side effects, some of which include capsular perforation (9.6%), superficial bladder mucosal injury (3.9%), ureteric orifice injury (2.1%), blood transfusion (1.4%), and cystoscopy with clot evacuation (0.7%). The commonest complication after HoLEP is transient urinary incontinence (10.7%). Other rare complications include the need for re-catheterization (3.9%), urinary tract infection (3.2%), epididymitis (0.7%),

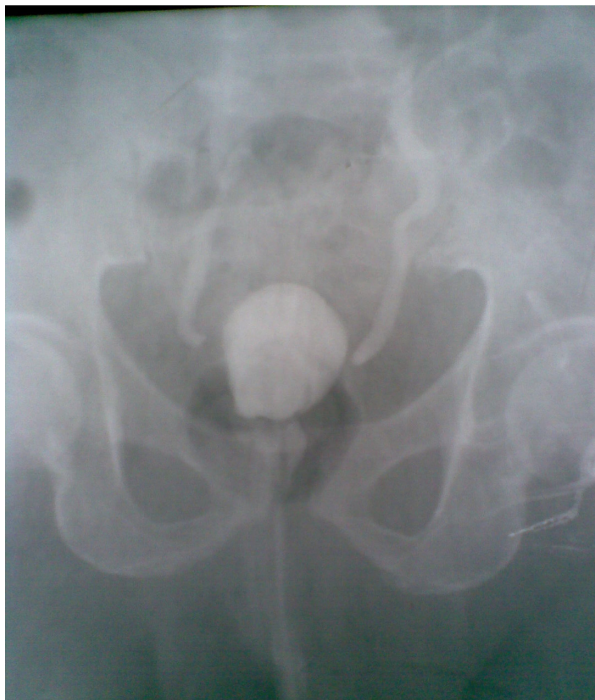

Figure 3 Postoperative bladder exteriorization cystogram.

meatal and submeatal stenosis (2.5%) and bladder neck contracture (0.35%).^{7,8}

Open prostatectomy, especially suprapubic transvesical prostatectomy, is associated with recognizable complications such as: bleeding (requiring blood transfusion),⁹ urinary retention, retrograde ejaculation, retrograde epididymo-orchitis, persistent vesicocutaneous fistula, transient or permanent urinary incontinence, osteitis pubis and bladder neck contracture.^{1,2,9}

Our patient had open transvesical prostatectomy complicated by complete anterior abdominal wall defects, absent anterior bladder wall, intact ureteric orifices, symptoms which are similar to those seen in congenital bladder extrophy or adult bladder extrophy, hence the title of this paper; post open prostatectomy bladder exteriorization mimicking “adult bladder extrophy”. This condition is different from that of congenital or adult bladder extrophy because of the presence of normal pubic symphysis and intact circumcised phallus.^{10,11} In the classic bladder extrophy, a spectrum of ectopia vesicae, pubic diastasis, and epispadias complex may be seen. There is a hereditary component to this condition and although it is more common in males the condition is also seen in females.

In our patient the urethral catheter was removed post prostatectomy and although the urinary stream was good the defect appeared soon after and progressed despite

repassing the urethral catheter. It is possible there was bladder outlet obstruction although this is difficult to justify since after repassing the urethral catheter the defect widened over a period of 10 weeks, until he presented at our clinic. There is also the possibility of a painless suprapubic mass (haematoma), present after the original surgery, that eventually ruptured and manifested as the focus of the urinary leakage. This complication must be differentiated from persistent vesicocutaneous fistula (PVCF), where urine leaks into the anterior abdominal wall through a small hole, without visualizing the posterior bladder wall. PVCF is commonly seen when the suprapubic drain exists in the abdominal incision wound, (rather than through a separate stab wound) or in the delayed removal of such a drain beyond 72 hours.

The presence of an ugly scar in the lower abdomen in our patient is suggestive of possible urinary tract and wound infection. It is possible that preoperatively, sterile urine was not obtained before performing the initial prostatic surgery. The previous right inguinal herniorrhaphy scar could have contributed to the intraoperative problems encountered during the prostatectomy, due to the presence of dense scar tissue on the lateral aspect of the pfannenstiell incision used. In addition excessive primary hemorrhage could have occurred.

A postoperative cystogram was undertaken and this excluded any objective evidence of urinary extravasations, although evidence of possible residual bilateral grade II, vesicoureteric reflux cannot be excluded, (we are not sure about the preoperative ultrasonography and micturating cystourethrography which may have shown this). The cystogram also confirmed the presence of a contracted bladder. The contracted bladder was due to continued urinary extravasation through the anterior abdomen and anterior bladder wall defect. We suggest that postoperative micturating cystogram evaluation be utilized to establish the efficacy of such repair in future patients.

It is mandatory that at a subsequent follow-up uroflowmetry should be undertaken to ascertain the adequacy of the urine stream. A micturating cystogram should also be repeated to assess the subsequent bladder volume and the extent of the bilateral vesico-ureteric reflux. Abdominal ultrasonography will establish the degree of improvement in the hydronephrosis and assist in deciding if any external or internal ureteric stenting is required.

Bladder extrophy has been reported in adulthood with similar findings as seen in their congenital counterparts although this is unlike that seen in our patient. The majority of these adult patients are treated with cystectomy and continent pouch creation. However, a few have reconstruction

of their bladder wall undertaken with improved self esteem and satisfactory social and sexual interaction.¹² Our patient had been distressed regarding the huge sum of money spent during that period, family disharmony and embarrassment of the urinary extravasation. He subsequently regained his self esteem and gave consent to this case report.

A literature review did not show that this complication has been reported in Nigeria (or elsewhere), hence our reporting this case to stress the future possibility of this complication and the need to strictly adhere to surgical principles in the management of patients with BPH.

In conclusion

Bladder exteriorization is a possible complication of post open prostatectomy and efforts to adhere to the need for preoperative sterile urine and the technical skills at closing the bladder will help prevent this problem in the future.

Acknowledgements

The patient and his relations gave their written consent for publication of this report.

Disclosures

The authors report no conflicts of interest in this research.

References

1. Neal DE, Kelly JD. The Prostate and Seminal vesicles. In: Russell RCG, Williams NS, Bulstrode CJK, editors. *Bailey and Love's Short Practice of Surgery*. 24th ed. New York: Edward Arnold; 2004. p. 1376–1380.
2. Roehrborn CG, McConnell JD. Benign Prostatic Hyperplasia. In: Wein AJ, Kavoussi, Novick, Pertin, Peters, editors. *Campbell Walsh Urology*. 8th ed. Philadelphia: WB Saunders; 2002. p. 1237–1433.
3. Barry MJ, Fowler FJ Jr, O'Leary MP; and the Measurement Committee of the AUA: The American Urological Association symptom index for benign prostatic hyperplasia. *J Urol*. 1992;148(5):1549–1557.
4. Oguike CT, Anele AA. Doxazocin in the management of Benign Prostatic obstruction in elderly Nigeria. *Nig J Surg Sci*. 2006;16(1):16–21.
5. Alhasan SU, Aji SA, Mohammed AZ, Malami S. Transurethral resection of the prostate in Northern Nigeria, problems and prospects. *BMC Urol*. 2008;8:18.
6. Popoola AA, Onawola KA, Adesina MD, Olaoye IO. Intestinal obstruction: a rare complication of channeling Transurethral Resection of the Prostate (TURP): a case report. *J Med Case Report*. 2008;2:30.
7. Salonia A, Suardi N, Naspro R, et al. Holmium laser enucleation versus open prostatectomy for benign hyperplasia: an inpatient cost analysis. *Urol*. 2006;68(2):302–306.
8. Shah HN, Mahaian AP, Hegde SS, Bansal MB. Peri-operative complications of holmium laser enucleation of the prostate: experience in the first 280 patients, and a review of literature. *BJU Int*. 2007;100(1):94–101.
9. Shittu OB, Kamara TB, Adebayo SA. Open prostatectomy at the UCH Ibadan: a ten year review. *Nigerian J G-U Med*. 2002;2(1):16–19.
10. Nelson CP, Dunn RL, Wei JT. Contemporary epidemiology of bladder extrophy in the United States. *J Urol*. 2005;173(5):1728–1731.
11. Gearhart JP. Exstrophy, Epispadias, and other bladder anomalies. In: Walsh PC, Retik AB, Vaughan ED, Wein AJ, editors. *Campbell's Urology*, 8th ed. Philadelphia: WB Saunders; 2002. p. 2136.
12. Nerli RB, Kamat GV, Alur SS, Koura A, Prabha V, et al. Bladder extrophy in adulthood. *Ind J Urol*. 2008;24(2):164–168.

Open Access Journal of Urology

Publish your work in this journal

The Open Access Journal of Urology is an international, peer-reviewed, open access journal publishing original research, reports, editorials, reviews and commentaries on all aspects of adult and pediatric urology in the clinic and laboratory including the following topics: Pathology, pathophysiology of urological disease; Investigation and treatment of

urological disease; Pharmacology of drugs used for the treatment of urological disease. The manuscript management system is completely online and includes a very quick and fair peer-review system, which is all easy to use. Visit <http://www.dovepress.com/testimonials.php> to read real quotes from published authors.

Submit your manuscript here: <http://www.dovepress.com/open-access-journal-of-urology-journal>

Dovepress