

CIP2A overexpression in Taiwanese oral cancer patients

This article was published in the following Dove Press journal:
Cancer Management and Research

Bharath Kumar Velmurugan¹
Hsin-Kai Wang^{2,3}
Chia-Min Chung^{4,5}
Chien-Hsun Lee⁶
Lan-Ru Huang⁷
Kun-Tu Yeh^{6,7*}
Shu-Hui Lin^{6,8*}

¹Faculty of Applied Sciences, Ton Duc Thang University, Ho Chi Minh City, Vietnam; ²Public Health Bureau, Tainan City Government, Tainan City, Taiwan;

³Jenteh Junior College of Medicine, Nursing and Management, Taiwan;

⁴Graduate Institute of BioMedical Sciences, China Medical University, Taichung, Taiwan; ⁵Environment-Omics-Diseases Research Center, China Medical University Hospital, Taichung, Taiwan;

⁶Department of Surgical Pathology, Changhua Christian Hospital, Changhua, Taiwan; ⁷School of Medicine, Chung Shan Medical University, Taichung, Taiwan;

⁸Department of Medical Laboratory Science and Biotechnology, Central Taiwan University of Science and Technology, Taichung, Taiwan

*These authors contributed equally to this work

Introduction: Oral cancer is a prevalent form of cancer worldwide, particularly in Taiwan, and mechanisms involved in oral squamous cell carcinoma (OSCC) progression remain relatively unknown. Cancerous inhibitor of protein phosphatase 2A (CIP2A), an oncoprotein, is aberrantly expressed in many human malignant tumors including oral cancer. However, the expression and role played by CIP2A in oral cancer pathogenesis remain obscure.

Methods: In this study, immunohistochemistry was used to analyze CIP2A expression between OSCC tissues and their adjacent noncancerous tissues. Furthermore, associations between CIP2A expression and histopathological parameters were investigated.

Results: In this study, we showed that CIP2A was overexpressed in most of the OSCC tissues. High CIP2A expression was significantly associated with moderate/poor tumor differentiation ($P=0.02$). No significant association was found between CIP2A expression and other clinical parameters. Kaplan–Meier analysis revealed that high CIP2A expression showed poorer survival rates than those with low CIP2A expression ($P=0.047$). Multivariate Cox regression analysis indicated that CIP2A expression, N stage, American Joint Committee on Cancer stage and clinical therapy were independent prognostic factors for survival.

Conclusion: Thus, our study suggests that CIP2A is an independent prognostic marker for OSCC and a novel target for OSCC treatment.

Keywords: CIP2A, OSCC: prognosis, survival, Taiwan

Introduction

Oral squamous cell carcinoma (OSCC), the most commonly occurring malignancy of the head and neck region, is a serious growing problem in many parts of the globe. This is the fourth most commonly occurring cancer affecting Taiwanese men. Despite so many advances in treatment and diagnostic aids, the 5-year survival rate in patients with OSCC remains ~50%.¹ Survival rates directly depend on the stage at which the disease is diagnosed.² Thus, survival and morbidity rates will be exceptionally improved if the disease is identified in initial stages. For that, we need a good prognostic marker to better understand the disease and its outcome.

Cancerous inhibitor of PP2A (CIP2A), also recognized as KIAA1524 and p90, is located in the 3q13.13 of chromosomes.³ CIP2A is abundantly expressed in various cancers like gastric cancer,⁴ breast cancer,⁵ lung cancer⁶ and head and neck carcinomas.⁷ Importantly, overexpression of CIP2A in head and neck squamous cell carcinoma (HNSCC) correlates with poor prognosis^{7,8} and is linked to poor overall 5-year survival in HNSCC.⁸ Bockelman et al studied CIP2A expression in 73 OSCC patients with stage T1N0M0 and T2N0M0 and identified CIP2A expression as an independent

Correspondence: Kun-Tu Yeh; Shu-Hui Lin
135 Nan-Hsiao St., Changhua 500-06, Taiwan
Tel +8 864 8595 Ext. 4830
Email 10159@cch.org.tw;
74630@cch.org.tw

prognostic marker in early-stage OSCC patients.⁷ Katz et al examined the expression of CIP2A in oral cancer cell lines and oral dysplasia and OSCC tissues.⁹ Thus, it is difficult to conclude the role of CIP2A in OSCC.

The aim of the present study was to address the significance of CIP2A expression in oral cancer. We examined protein expression levels of CIP2A in tissue samples by immunohistochemical staining and further analyzed the clinical significance of CIP2A in a cohort of OSCC patients. Our data support the perception that aberrant CIP2A expression is an important oncogenic event in OSCC.

Materials and methods

Participants and clinical tissues

Tissue samples of patients (from January 2000 to December 2008) with OSCC were obtained from the Department of Pathology at Changhua Christian Hospital, Taiwan, of which 133 OSCC specimens were used for immunohistochemistry (IHC) staining. Staging was classified according to the sixth edition of TNM staging system of AJCC (American Joint Committee on Cancer). The main treatment was tumor removal and radical neck dissection, including postoperation irradiation as well as selective patients treated with 5-fluorouracil (5-FU) and cisplatin chemotherapy. This study was approved by the Ethics Committees of Changhua Christian Hospital (Changhua, Taiwan) to use decoded tissue samples, and we adhered to the guidelines approved by (CCH IRB No. 170143).

Tissue microarray and immunohistochemical staining

Formalin-fixed, paraffin-embedded block of cancer tissues were used in this experiment. Tissue microarrays and immunohistochemical staining methods have been described previously.¹⁰ The sections were incubated CIP2A antibody in room temperature for 20 mins. After washing three times with PBS, the sections were incubated with appropriate peroxidase-labeled secondary antibodies for 30 mins at room temperature. The sections were washed three times with PBS and then labeled by diaminobenzidine and counterstained with Mayer's hematoxylin, dehydrated and mounted.

Two experienced pathologists (Kun-Tu Yeh and Chang Wei-Hsiang) independently assessed the results of immunohistochemical staining, and a final agreement was obtained for each score at a discussion microscope. The staining intensities were scored –, 1+ and 2+ for negative, low and high signals, respectively.

Statistical analysis

Results were expressed as the means \pm SD of at least three independent experiments. Statistical analysis was performed using version 9.4 of the SAS software package (SAS Institute, Inc.; Cary, NC, USA). Data comparisons were made using Student's *t* test between control and treated groups, when *P*-values <0.05 was considered statistically significant. The associations of clinicopathologic factor and CIP2A expression were examined by logistic regression with adjustment for age and gender.

Cox proportional hazards regression model was utilized for multivariate analyses to screen independent risk factors for prognosis of OSCC patients. HRs and CIs were subsequently calculated. Survival outcomes were summarized by the Kaplan–Meier method. *P*-values were obtained from log-rank tests for the homogeneity of Kaplan–Meier curves between high and low CIP2A expression.

Results

Patient characteristics

Table 1 summarizes the demographic and clinicopathologic characteristics for OSCC patients. A majority of cancer patients were men (94%), with the tumors mainly occurring at age of <60 years (66.6%). Fifty (37.6%) OSCC patients were diagnosed with III/IV tumor stage and 21 (15.8%) patients with N2/N3 lymph node metastasis, without distant nodal metastasis patients. Of those, 65 (59.4%) and 112 (84.3%) patients were, respectively, determined to be III/IV tumor stages and moderate/poor tumor differentiation.

CIP2A is overexpressed in OSCC tissues and correlated with survival of OSCC patients

First, CIP2A expression was evaluated in clinical samples including tumor part and non-tumor part using immunohistochemical staining, and the staining intensity was scored from – to 2+. In this experiment, we used nontumor part CIP2A expression as a standard to compare CIP2A expression in OSCC tissue. Based on CIP2A expression, OSCC patients were categorized into two groups: low expression group (– and 1+) if the staining intensity was lower than the staining intensity of the non-tumor tissues. The staining was scored as “2+” if the staining intensity in the tumor part is higher than the staining intensity of non-tumor tissues. Figure 1A shows that CIP2A protein was located in the cytoplasm of oral cancer tissues. Based on the IHC scoring, 58 (43.6%) cases showed low CIP2A

Table 1 Demographic and characteristics among oral cancer patients

Factors	n	%
Gender		
Female	8	6
Male	125	94
Age, years		
≤49	36	29.3
50–59	47	35.3
60–69	33	24.8
≥70	14	10.6
T (tumor size)		
I	38	28.6
II	45	33.8
III	10	7.5
IV	40	30.1
N (lymph node)		
N0	98	73.7
N1	14	10.5
N2	21	15.8
N3	0	0
M (metastasis)		
No	133	100
Yes	0	0
AJCC cancer stage		
I	34	19.8
II	34	20.9
III	14	11.6
IV	51	47.8
Histological grade		
Well	21	15.7
Moderate	111	81.3
Poor	1	3
Clinical therapy		
Surgery	58	43.6
Radiotherapy	64	48.1
Chemotherapy	11	8.2
Chemoradiotherapy	15	11.2

Abbreviation: AJCC, American Joint Committee on Cancer.

expression and 75 (56.3%) cases exhibited high expression. Overall, CIP2A was highly expressed in tumor cells compared with non-tumor tissues.

In order to understand the possible roles of CIP2A in the OSCC development, we examined the association between CIP2A expression and clinicopathological characteristics (Table 2). The results show that CIP2A expression was significantly associated with moderate/poor tumor differentiation

($P=0.02$). However, no significant association was found between CIP2A expression and other clinical parameters, such as TNM stage and AJCC cancer stage. Kaplan–Meier analysis was performed to evaluate the associations of CIP2A expression with survival of the patients. Results showed that patients with higher CIP2A expression had lower survival rate than those with lower CIP2A expression (Figure 1B, $P=0.047$).

Multivariate analysis to analyze prognostic value of CIP2A expression

The effects of clinicopathologic factors and CIP2A expression on mortality in the OSCC patient cohort are shown in Table 3. Adjusted for the effects of age and gender, nodal metastasis, AJCC stage and chemotherapy/radiotherapy were significantly associated with a higher mortality risk (adjusted HR [aHR], 2.5; 95% CI, 1.7–3.7; $P=0.0051$; aHR, 3.7; 95% CI, 2.2–6.0; $P=0.0127$; aHR, 2.9; 95% CI, 2.0–4.1; $P<0.0001$, respectively). To further understand whether CIP2A expression is an independent prognostic factor for OSCC patients, variables such as age, gender and histological grade were adjusted. Compared with high CIP2A expression, OSCC patients with low CIP2A expression had a 1.4-fold higher mortality risk (95% CI, 0.8–2.5; $P=0.0239$). These results clearly demonstrate that CIP2A expression is an independent predictor for OSCC patients.

Discussion

In this study, we demonstrated that CIP2A expression in oral cancer tissues was significantly increased compared with nontumoral tissues. Normal epithelium showed weak or partly moderate staining, whereas tumor cells showed variable distribution and intensity of CIP2A. As determined by IHC, a total of 58 cases showed low CIP2A expression (43.6%) and 75 cases showed high CIP2A expression (56.3%). This finding indicates that CIP2A was highly expressed in tumor tissues than non-tumor tissues, which is consistent with previous studies.^{4,5,7,9,11–15}

Increased CIP2A expression confers poor clinical outcome in several types of cancer. In this study, the relationship between CIP2A expression levels and certain clinicopathological parameters of oral cancer was evaluated. High CIP2A expression is associated with late pathologic stage and metastatic lymph node status

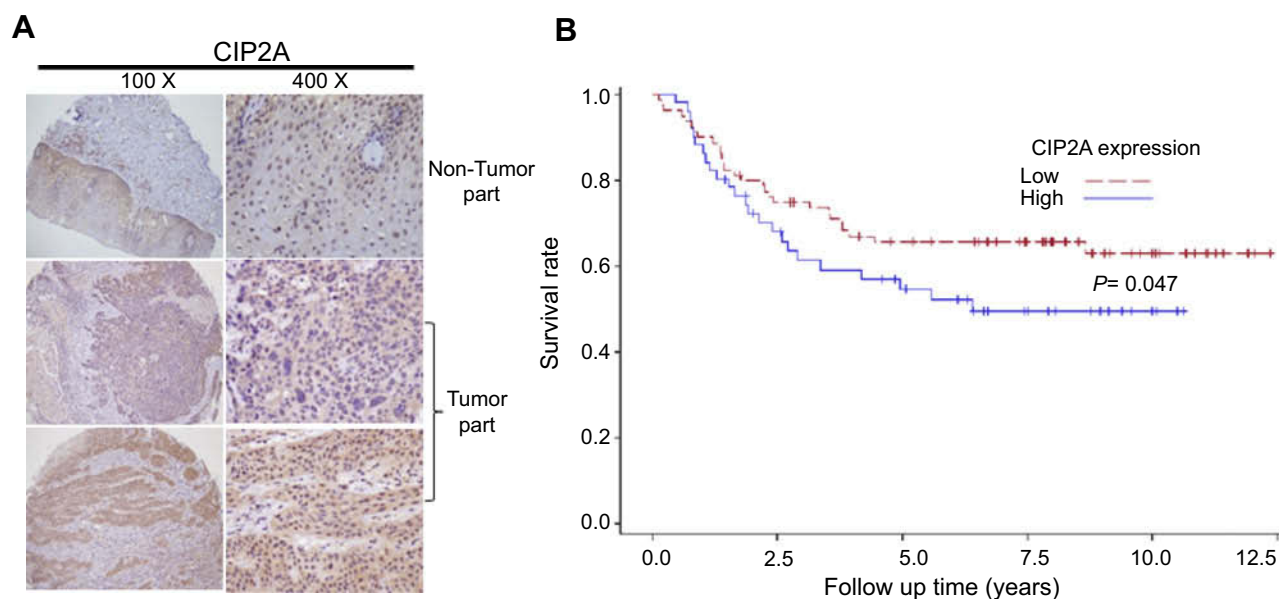


Figure 1 Higher expression levels of CIP2A in OSCCs. **(A)** Representative immunohistochemical expression patterns of CIP2A in nontumor tissues and OSCC specimens are shown. **(B)** Kaplan–Meier survival curves showing the difference of survival time between patients with low- and high-expression CIP2A on OSCC samples from 133 patients. **Abbreviations:** CIP2A, cancerous inhibitor of protein phosphatase 2A; OSCC, oral squamous cell carcinoma.

Table 2 Clinicopathologic factors associated with CIP2A expression

Factors	Cytoplasm			
	CIP2A			
	Low	High		
	Number	Number		
	(n = 58)	(n=75)	aOR ^a (95% CI)	P-value
Tumor size (SD)	3.16 (1.60)	2.81 (1.68)		
T classification				
I/II	31	52	I	
III/IV	27	23	0.49 (0.24–1.03)	0.058
N (lymph node)				
N0/N1	48	64	I	
N2/N3	10	11	0.77 (0.30–1.99)	0.591
M (metastasis)				
No	57	75	I	
Yes	1	0	ND	
AJCC cancer stage				
I/II	25	43	I	
III/IV	33	32	0.53 (0.26–1.07)	0.074
Histological grade				
Well	4	17	I	
Moderate/poor	54	58	0.25 (0.08–0.81)	0.020
Death				
No	23	36	I	
Yes	35	39	0.55 (0.27–1.15)	0.113

Notes: ^aAdjusted odds ratio (aOR) was controlled for gender and age.

Abbreviations: ND, not determined; CIP2A, cancerous inhibitor of protein phosphatase 2A; AJCC, American Joint Committee on Cancer.

Table 3 The effect of clinicopathologic factor and CIP2A expression on mortality density and adjusted hazard ratio (aHR) among OSCC patients

Factors	Number of patients	Follow-up	Number of death	Mortality density ^a	aHR ^b	(95% CI)	Interaction
		(person-year)					P-value
Overall mortality from primary malignancy to death							
T classification							
I/II	83	554.9	22	4.0	1		
III/IV	50	242	26	10.7	1.9	(1.4–2.8)	0.0707
N classification							
N0/N1	112	736.4	33	4.5	1		
N2/N3	21	60.5	15	24.8	2.9	(2.0–4.1)	<0.0001
AJCC tumor stage							
I/II	68	483.1	16	3.3	1		
III/IV	65	313.7	32	10.2	2.5	(1.7–3.7)	0.0051
Histological grade							
Well	21	160.1	0	0.0	1		
Moderate/poor	112	636.7	48	7.5	2.9	(1.4–5.6)	0.0682
CIP2A expression							
High	75	455.7	23	5.0	1		
Low	58	341.2	25	7.3	1.4	(0.82–2.53)	0.0239 ^c

Notes: ^aMortality density was displayed as per 100 people-years. ^baHR was adjusted for gender and age. ^caHR was adjusted for gender, age and histological grade.

Abbreviations: CIP2A, cancerous inhibitor of protein phosphatase 2A; OSCC, oral squamous cell carcinoma; AJCC, American Joint Committee on Cancer

in various cancers types.^{4,5,14,16–18} In this study, clinicopathological analyses revealed a significant association between CIP2A expression and histological grade; this result is consistent with Bockelman et al (2007) and our study.⁷ Dong et al (2011) found that non-small-cell lung carcinoma (NSCLC) patients with CIP2A-positive expression showed reduced survival rate when compared to CIP2A-negative NSCLC.¹² CIP2A overexpression is associated with shorter overall survival in patients with breast cancer, renal cancer^{5,17} and oral cancer and nasopharyngeal cancer.^{7,19} Similarly, in our study, high CIP2A expression was significantly correlated with poor prognosis in OSCC patients ($P=0.047$).

Dong et al (2010) have demonstrated that CIP2A expression was a significant prognostic factor for NSCLC patients.¹² Multivariate analysis indicated that CIP2A expression was an independent risk factor for T1N0M0 and T2N0M0 OSCC patients.⁷ Consistent with these findings, the present report showed that CIP2A is an independent prognostic factor in oral cancer. In conclusion, CIP2A is an oncogenic protein¹² in oral cancer and may serve as prognostic marker for overall survival.

Acknowledgment

This research did not receive any specific grant from funding agencies in the public, commercial or not-for-profit sectors.

Disclosure

The authors report no conflicts of interest in this work.

References

1. Warnakulasuriya S. Global epidemiology of oral and oropharyngeal cancer. *Oral Oncol.* 2009;45(4–5):309–316. doi:10.1016/j.oraloncology.2008.06.002
2. Lingen MW, Kalmar JR, Karrison T, Speight PM. Critical evaluation of diagnostic aids for the detection of oral cancer. *Oral Oncol.* 2008;44(1):10–22. doi:10.1016/j.oraloncology.2007.06.011
3. Xu ST, Wen WJ, Zhou J, Liu JX, Gu GJ. Clinicopathological significance of expression of CIP2A and c-myc in human gallbladder carcinoma. *Int J Clin Exp Pathol.* 2017;10(5):5868–5874.
4. Khanna A, Bockelman C, Hemmes A, et al. MYC-dependent regulation and prognostic role of CIP2A in gastric cancer. *J Natl Cancer Inst.* 2009;101(11):793–805. doi:10.1093/jnci/djp103
5. Come C, Laine A, Chanrion M, et al. CIP2A is associated with human breast cancer aggressivity. *Clin Cancer Res.* 2009;15(16):5092–5100. doi:10.1158/1078-0432.CCR-08-3283
6. Xu P, Xu XL, Huang Q, Zhang ZH, Zhang YB. CIP2A with survivin protein expressions in human non-small-cell lung cancer correlates with prognosis. *Med Oncol.* 2012;29(3):1643–1647. doi:10.1007/s12032-011-0053-3

7. Bockelman C, Hagstrom J, Makinen LK, et al. High CIP2A immunoreactivity is an independent prognostic indicator in early-stage tongue cancer. *Brit J Cancer*. 2011;104(12):1890–1895. doi:10.1038/bjc.2011.167
8. Ventela S, Sittig E, Mannermaa L, et al. CIP2A is an Oct4 target gene involved in head and neck squamous cell cancer oncogenicity and radioresistance. *Oncotarget*. 2015;6(1):144–158. doi:10.18632/oncotarget.2670
9. Katz J, Jakymiw A, Ducksworth MK, et al. CIP2A expression and localization in oral carcinoma and dysplasia. *Cancer Biol Ther*. 2010;10(7):694–699. doi:10.4161/cbt.10.7.12895
10. Hsu LS, Wu PR, Yeh KT, et al. Positive nuclear expression of KLF8 might be correlated with shorter survival in gastric adenocarcinoma. *Ann Diagn Pathol*. 2014;18(2):74–77. doi:10.1016/j.anndiagpath.2013.12.001
11. Rantanen T, Kauttu T, Akerla J, et al. CIP2A expression and prognostic role in patients with esophageal adenocarcinoma. *Med Oncol*. 2013;30:3. doi:10.1007/s12032-013-0684-7
12. Dong QZ, Wang Y, Dong XJ, et al. CIP2A is overexpressed in non-small cell lung cancer and correlates with poor prognosis. *Ann Surg Oncol*. 2011;18(3):857–865. doi:10.1245/s10434-010-1313-8
13. Junttila MR, Puustinen P, Niemela M, et al. CIP2A inhibits PP2A in human malignancies. *Cell*. 2007;130(1):51–62. doi:10.1016/j.cell.2007.04.044
14. Cha GQ, Xu JY, Xu XY, et al. High expression of CIP2A protein is associated with tumor aggressiveness in stage I-III NSCLC and correlates with poor prognosis. *Onco Targets Ther*. 2017;10:5907–5914. doi:10.2147/OTT.S148250
15. He H, Wu G, Li WJ, Cao YC, Liu YF. CIP2A is highly expressed in hepatocellular carcinoma and predicts poor prognosis. *Diagn Mol Pathol*. 2012;21(3):143–149. doi:10.1097/PDM.0b013e318249fd8b
16. Bockelman C, Lassus H, Hemmes A, et al. Prognostic role of CIP2A expression in serous ovarian cancer. *Brit J Cancer*. 2011;105(7):989–995. doi:10.1038/bjc.2011.346
17. Ren J, Li W, Yan L, et al. Expression of CIP2A in renal cell carcinomas correlates with tumour invasion, metastasis and patients' survival. *Brit J Cancer*. 2011;105(12):1905–1911. doi:10.1038/bjc.2011.492
18. Yu GZ, Liu GH, Dong J, Jin YY. Clinical implications of CIP2A protein expression in breast cancer. *Med Oncol*. 2013;30:2. doi:10.1007/s12032-013-0524-9
19. Liu N, He QM, Chen JW, et al. Overexpression of CIP2A is an independent prognostic indicator in nasopharyngeal carcinoma and its depletion suppresses cell proliferation and tumor growth. *Mol Cancer*. 2014;13:111.

Cancer Management and Research

Dovepress

Publish your work in this journal

Cancer Management and Research is an international, peer-reviewed open access journal focusing on cancer research and the optimal use of preventative and integrated treatment interventions to achieve improved outcomes, enhanced survival and quality of life for the cancer patient.

The manuscript management system is completely online and includes a very quick and fair peer-review system, which is all easy to use. Visit <http://www.dovepress.com/testimonials.php> to read real quotes from published authors.

Submit your manuscript here: <https://www.dovepress.com/cancer-management-and-research-journal>