

Biomaterial suture Vicryl Plus reduces wound-related complications

Qian Zhang
Chao Zhang
Xuanyu Fang
Xu Luo
Jiwei Guo

Southwest Hospital, The Third Military
Medical University (Army Medical
University), Chongqing, China

Objective: To compare the wound-related complications following craniotomy in patients with brain gliomas undergoing wound closure using either absorbable antibacterial Vicryl Plus suture or traditional braided silk suture.

Materials and methods: Two hundred and forty-five patients undergoing craniotomy for supratentorial gliomas from January 1, 2011 to December 31, 2013 were retrospectively analyzed. We divided the patients into two groups: the Vicryl Plus group (using absorbable antibacterial Vicryl Plus suture) and the control group (using traditional braided silk suture). The clinical data and wound-related complications after surgery between two groups have been summarized.

Results: Patients in the Vicryl Plus suture group had lower incidence of wound-related complications compared with traditional braided silk suture group ($P < 0.05$). No statistically significant difference was found between the two groups in terms of total medical expense.

Conclusion: Incision closure using absorbable antibacterial Vicryl Plus suture had less wound-related complications than using traditional braided silk suture, without increasing medical expense. Vicryl Plus suture could be a better choice for scalp closure in patients undergoing craniotomy surgery.

Keywords: biomaterial, Vicryl Plus, wound-related complications

Introduction

Absorbable antibacterial Vicryl Plus (Ethicon Inc, Somerville, NJ, USA) suture is a new type of biotechnological material, which is widely used in surgical incision suture. Because of the features of Vicryl Plus, such as the absorbability in the body, no irritation to tissues, and antibacterial properties, it can promote wound healing to some degree. In addition, they do not require suture removal, which may be painful or unpleasant for the patient and do not require an additional appointment at a suitable postoperative date for removal. Studies have reported that the use of the absorbable antibacterial Vicryl Plus suture in abdominal and orthopedic surgery can reduce the incidence of adverse reactions related to wounds.¹ However, fewer research focuses on its application in craniotomy surgery, especially in glioma surgery.

In resection of glioma surgery, the skull and dura mater are routinely opened, which causes an extremely high risk of infection and a wide range of complications related to the wound. Therefore, the suture of incision during operation is crucial for the success of glioma surgery. The aim of this study was to compare the incidence of wound-related complications after glioma surgery using Vicryl Plus suture with that of traditional suture.

Correspondence: Jiwei Guo
Southwest Hospital, The Third Military
Medical University (Army Medical
University), Chongqing 400038, China
Tel +86 23 6875 4000
Email gjw_1214@163.com

Materials and methods

Clinical data

This retrospective study was approved by our institutional review board (Ethics Committee of the First Affiliated Hospital of Third Military Medical University), and the requirement for informed consent was waived because this study used deidentified data, which is confidential for patient information. Data were collected retrospectively from 245 patients with supratentorial gliomas, who underwent craniotomy and tumor resection from January 1, 2011 to December 31, 2013 in the Southwest Hospital.

Inclusion criteria were elective surgery for a newly diagnosed and histologically confirmed supratentorial glioma and aged 18 to 70 years. Exclusion criteria were having undergone infratentorial or spinal intradural surgery, previous intracranial surgery or biopsy, previous brain radiation, and systemic or local infection or compromised immune system. According to the usage of different sutures, all of the patients were divided into the Vicryl Plus suture group and the control group (traditional braided silk suture). There were 129 cases in absorbable antibacterial Vicryl Plus suture group, including 71 males and 58 females, aged 20–79 years old, the average age was 45 ± 12 years. There were 116 cases in the control group, including 69 males and 47 females, aged 18–75 years old, the average age was 45 ± 13 years.

Methods

The procedures were performed under general endotracheal anesthesia and different approaches were utilized depending on the location of the glioma. Craniotomy was undertaken on patients using almost the same surgical techniques. After successful resection of glioma, the dura mater was tightly closed, and bone flap were fixed. Then, the incision, consisting of muscle, subcutaneous tissue and skin layers, was tightly closed with absorbable antibacterial Vicryl Plus suture (in the Vicryl Plus suture group) or with traditional braided silk suture (in the control group). After surgery, routinely managements were provided for every patient, especially wound close observation. Two groups of patients were given the same medicine and treatments postsurgery. Any complications occurred were recorded.

Outcome measurement and statistic analysis

The primary outcome was the wound-related complications, which include surgical site infection, wound swelling and exudation, subcutaneous bloody fluid collection, etc.^{2,3} SPSS 13.0 (SPSS Inc, Chicago, IL, USA) software was used for statistical analysis. The data were compared using unpaired Student's *t*-test or chi-squared test, depending on continuous

variables or categorical variables. A *P*-value < 0.05 was considered as statistically significant.

Results

A total of 245 patients were recruited to the study, of which 129 cases used the absorbable antibacterial Vicryl Plus suture (Figure 1), 116 cases used the traditional braided silk suture. The baselines of the two groups were comparable regarding the age, sex, epilepsy, and pathological grade (Table 1). The World Health Organization (WHO) grade is listed in Figure 2 for indication. No significant difference existed between two groups on admission.

Wound-related complications occurred in both groups (Table 2). In the Vicryl Plus group, eleven patients experienced wound-related complications, among whom five cases exhibited wound swelling and exudation, six cases presented subcutaneous bloody fluid collection. In the control group, 20 patients experienced wound-related complications. Wound swelling and exudation was found in nine cases, subcutaneous bloody fluid was appeared in eleven cases. Among them, two patients presented surgical site infection eventually resulting in intracranial infection, who were cured via lumbar drainage and antibiotics. The total medical expense was also analyzed. The data showed that no significant difference existed between two groups. These data demonstrate the occurrence of wound-related complications in the Vicryl Plus suture group was significantly lower than the traditional suture group (8.5% vs 17.2%, $P = 0.025$), without increasing the total medical expense of glioma patients.

Discussion

Biotechnology, which is the combination of life sciences and biotechnology, is changing many aspects of medical procedures. Among them, biological materials such as absorbable antibacterial suture with good biodegradability and antimicrobial activity have been widely used in many specialties. Absorbable suture decreases the discomfort due to postoperative suture removal and favor more rapid postoperative psychological recovery. Medical devices such as sutures are a vital part of nearly every surgical procedure. Although the incidence of infection associated with clean surgical procedures is typically low, those infections that do occur are ultimately complicated by the devices used in the procedure.^{5,6} Additionally, absorbable suture materials coated with antibacterial agents such as triclosan have been shown to decrease the incidence of incision infections. Vicryl Plus has been used clinically in the USA and Europe since 2003, and its efficacy in reducing wound infection has been demonstrated in general surgical and thoracic surgical fields.^{7,8} However, few studies have reported

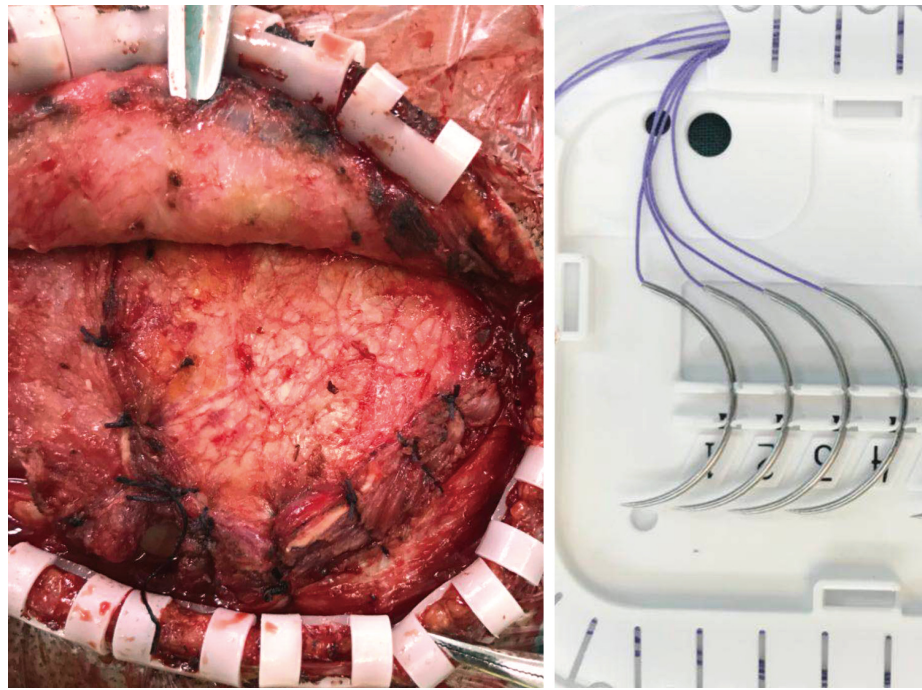


Figure 1 Vicryl Plus suture used in craniotomy surgery.

about its effects on wound-related complications in the field of neurosurgery, particularly in glioma surgery, which is associated with a high incidence of wound-related complications.⁹ Based on the common disease of neurosurgery (glioma), in this paper, we analyzed the impacts of the application of Vicryl Plus on the wound-related complications and hospital costs. Our data suggest that Vicryl Plus decreases the rate of wound-related complications after glioma surgery and does not increase the medical expense.

Table 1 Baseline patient characteristics of the two groups

Characteristic	Vicryl Plus n=129	Traditional n=116	X ² /t	P-value
Sex (male)	71 (55.0)	69 (59.5)	0.493	0.483
Age (<50 years)	83 (63.3)	80 (69.0)	0.587	0.444
Epilepsy	42 (32.6)	37 (31.9)	0.012	0.912
Extent of resection				
Subtotal	55 (42.6)	36 (31.0)	3.521	0.061
Total	74 (57.4)	80 (69.0)		
KPS on admission	75.9±11.4	73.3±11.6	1.774	0.077
Male	76.2±12.1	74.2±11.3	-1.007	0.316
Female	77.2±11.4	71.9±12.1	2.321	0.022
WHO grade				
I	3 (2.3)	1 (0.9)	7.111*	0.068
II	58 (45.0)	46 (39.7)		
III	41 (31.8)	28 (24.1)		
IV	27 (20.9)	41 (35.3)		

Notes: Data presented as mean±SD or number (%). *Corrected chi-square test.

Abbreviations: KPS, Karnofsky Performance Status; WHO, World Health Organization.

Successful wound healing is critical for glioma patients with high-grade pathological features because they need to receive radiotherapy and adjuvant chemotherapy postsurgery.¹⁰ Unsuccessful wound healing would delay the following treatment protocol, which increases the possibility of recurrence of glioma. Of note, irradiation usually interferes with the wound healing, even worse, sometimes leads to scalp incision dehiscence.¹¹ In the current study, the incidence of wound-related complications was 8.5% in the Vicryl Plus group compared with 17.2% in the control group using conventional suture. This indicates the use of suture made from biomaterials can significantly reduce the incidence of wound-related complications, which is beneficial for the postoperative recovery and following radiotherapy in glioma patients.

Although the present study, as well as other studies, demonstrates that Vicryl Plus provide advantages in preventing wound-related complications over traditional sutures. The efficacy of Vicryl Plus in the oral surgeries, cardiac surgeries, and breast surgeries has been reported to be slight, and no difference in efficacy was observed in the case of appendectomy or surgery for head and neck cancer.^{12,13} Further studies are needed to examine whether Vicryl Plus suture are effective at preventing wound-related complications in other surgeries.

Usually, the expense of Vicryl Plus suture is more than traditional sutures. However, once infections occur, they can bring a large economic burden. It is believed that the economic loss associated with the use of Vicryl Plus would be compensated

WHO grades of select CNS tumors**Diffuse astrocytic and oligodendroglial tumors**

Diffuse astrocytoma, IDH mutant	II
Anaplastic astrocytoma, IDH mutant	III
Glioblastoma, IDH wildtype	IV
Glioblastoma, IDH mutant	IV
Diffuse midline glioma, H3K27M mutant	IV
Oligodendroglioma, IDH mutant, and 1p/19q-codeleted	II
Anaplastic oligodendroglioma, IDH mutant, and 1p/19q-codeleted	III

Other astrocytic tumors

Pilocytic astrocytoma	I
Subependymal giant cell astrocytoma	I
Pleomorphic xanthoastrocytoma	II
Anaplastic pleomorphic xanthoastrocytoma	III

Ependymal tumors

Subependymoma	I
Myxopapillary ependymoma	I
Ependymoma	II
Ependymoma, <i>RELA</i> fusion-positive	II or III
Anaplastic ependymoma	III

Other gliomas

Angiocentric glioma	I
Chordoid glioma of third ventricle	II

Choroid plexus tumors

Choroid plexus papilloma	I
Atypical choroid plexus papilloma	II
Choroid plexus carcinoma	III

Neuronal and mixed neuronal-glia tumors

Dysembryoplastic neuroepithelial tumor	I
Gangliocytoma	I
Ganglioglioma	I
Anaplastic ganglioglioma	III
Dysplastic gangliocytoma of cerebellum (Lhermitte-Duclos)	I
Desmoplastic infantile astrocytoma and ganglioglioma	I

Desmoplastic infantile astrocytoma and ganglioglioma	I
Papillary glioneuronal tumor	I
Rosette-forming glioneuronal tumor	I
Central neurocytoma	II
Extraventricular neurocytoma	II
Cerebellar liponeurocytoma	II

Tumors of the pineal region

Pineocytoma	I
Pineal parenchymal tumor of intermediate differentiation	II or III
Pineoblastoma	IV
Papillary tumor of the pineal region	II or III

Embryonal tumors

Medulloblastoma (all subtypes)	IV
Embryonal tumor with multilayered rosettes, C19MC-altered	IV
Medulloepithelioma	IV
CNS embryonal tumor, NOS	IV
Atypical teratoid/rhabdoid tumor	IV
CNS embryonal tumor with rhabdoid features	IV

Tumors of the cranial and paraspinal nerves

Schwannoma	I
Neurofibroma	I
Perineurioma	I
MPNST	II, III, or IV

Meningiomas

Meningioma	I
Atypical meningioma	II
Anaplastic (malignant) meningioma	III

Mesenchymal, nonmeningothelial tumors

Solitary fibrous tumor/haemangiopericytoma	I, II or III
Haemangioblastoma	I

Tumors of the sellar region

Craniopharyngioma	I
Granular cell tumor	I
Pituicytoma	I
Spindle cell oncocyoma	I

Figure 2 Grading of selected CNS tumors according to the 2016 CNS WHO.

Note: Reprinted by permission from Springer Nature: Springer, *Acta Neuropathol*. The 2016 World Health Organization classification of tumors of the central nervous system: a summary. Louis DN, Perry A, Reifenberger G, et al. 2016;131(6):803–820.⁴

Abbreviations: CNS, central nervous system; MPNST, malignant peripheral nerve sheath tumor; WHO, World Health Organization.

even if one case of infection.⁷ On the basis of the data in the present study, we found that Vicryl Plus did not increase the overall expense of glioma patients compared with the control group.

Limitations

Our study was a retrospective study, it can give us some suggestive value. Second, our study only made the comparative analysis in supratentorial glioma patients. Further analyses

are still needed as regard to other diseases or lesions in other intracranial compartments. Another limitation was that we did not take into the account the differences in experience of surgeons, which could affect the outcomes to some extent. However, we believe this variation reflects the pragmatic design of the study and represents the wider surgical practice.

Conclusion

The data in this study suggest that the use of absorbable antibacterial sutures may decrease complications in wound healing after glioma surgery. Together with other studies,¹⁴ the usage of biomaterial sutures could be a better alternative for scalp closure in patients undergoing craniotomy surgery.

Disclosure

All the authors have no personal financial disclosures or commercial associations that might pose or create a conflict of interest with information presented in this paper.

Table 2 Wound-related complications and medical expenses of two groups

	Cases	Wound-related complications	Expenses (RMB)
Vicryl Plus	129	11 (8.5)	93,410.3±34,329.6
Traditional	116	20 (17.2)	86,279.9±38,261.3
χ^2		4.995	1.538
P-value		0.025	0.125

Note: Data presented as number (%) or mean±SD.

Abbreviation: RMB, renminbi.

References

1. Wang ZX, Jiang CP, Cao Y, Ding YT. Systematic review and meta-analysis of triclosan-coated sutures for the prevention of surgical-site infection. *Br J Surg*. 2013;100(4):465–473.
2. Sprowson AP, Jensen C, Parsons N, et al. The effect of triclosan-coated sutures on the rate of surgical site infection after hip and knee arthroplasty: a double-blind randomized controlled trial of 2546 patients. *Bone Joint J*. 2018;100-B(3):296–302.
3. Wilson J, Charlett A, Leong G, McDougall C, Duckworth G. Rates of surgical site infection after hip replacement as a hospital performance indicator: analysis of data from the English mandatory surveillance system. *Infect Control Hosp Epidemiol*. 2008;29:219–226.
4. Louis DN, Perry A, Reifemberger G, et al. The 2016 World Health Organization classification of tumors of the central nervous system: a summary. *Acta Neuropathol*. 2016;131(6):803–820.
5. Vadaux P, Francois P, Lew DP, et al. Host factors predisposing to and influencing therapy of foreign body infections. In: Waldvogel FA, Bisno AL, editors. *Infections Associated with Indwelling Medical Devices*. 3rd ed. Washington, DC: ASM Press, 2000.
6. Anderson JA, Marchant RE. Biomaterials: factors favoring colonization and infection. In: Waldvogel FA, Bisno AL, editors. *Infections Associated with Indwelling Medical Devices*. 3rd ed. Washington, DC: ASM Press, 2000.
7. Fleck T, Moidl R, Blacky A, Fleck M, Wolner E, Grabenwoger M, Wissner W. Triclosan-coated sutures for the reduction of sternal wound infections: economic considerations. *Ann Thorac Surg*. 2007;84(1):232–236.
8. Justinger C, Moussavian MR, Schlueter C, Kopp B, Kollmar O, Schilling MK. Antibacterial [corrected] coating of abdominal closure sutures and wound infection. *Surgery*. 2009;145(3):330–334.
9. Jackson C, Westphal M, Quiñones-Hinojosa A. Complications of glioma surgery. *Handb Clin Neurol*. 2016;134:201–218.
10. Stupp R, Mason WP, van den Bent MJ, et al. Radiotherapy plus concomitant and adjuvant temozolomide for glioblastoma. *N Engl J Med*. 2005;352(10):987–996.
11. Nair S, Giannakopoulos G, Granick M, Solomon M, McCormack T, Black P. Surgical management of radiated scalp in patients with recurrent glioma. *Neurosurgery*. 1994;34(1):103–106.
12. Mingmalairak C, Ungbhakorn P, Paucharoen V. Efficacy of antimicrobial coating suture coated polyglactin 910 with triclosan (Vicryl plus) compared with polyglactin 910 (Vicryl) in reduced surgical site infection of appendicitis, double blind randomized control trial, preliminary safety report. *J Med Assoc Thai*. 2009;92(6):770–775.
13. Chen SY, Chen TM, Dai NT, Fu JP, Chang SC, Deng SC, Chen SG. Do antibacterial-coated sutures reduce wound infection in head and neck cancer reconstruction? *Eur J Surg Oncol*. 2011;37(4):300–304.
14. Paolini S, Morace R, Lanzino G, Missori P, Nano G, Cantore G, Esposito V. Absorbable intradermal closure of elective craniotomy wounds. *Neurosurgery*. 2008;62(5 Suppl 2):ONS490–ONS492.

Therapeutics and Clinical Risk Management

Publish your work in this journal

Therapeutics and Clinical Risk Management is an international, peer-reviewed journal of clinical therapeutics and risk management, focusing on concise rapid reporting of clinical studies in all therapeutic areas, outcomes, safety, and programs for the effective, safe, and sustained use of medicines. This journal is indexed on PubMed Central, CAS,

Submit your manuscript here: <http://www.dovepress.com/therapeutics-and-clinical-risk-management-journal>

EMBASE, Scopus and the Elsevier Bibliographic databases. The manuscript management system is completely online and includes a very quick and fair peer-review system, which is all easy to use. Visit <http://www.dovepress.com/testimonials.php> to read real quotes from published authors.

Dovepress