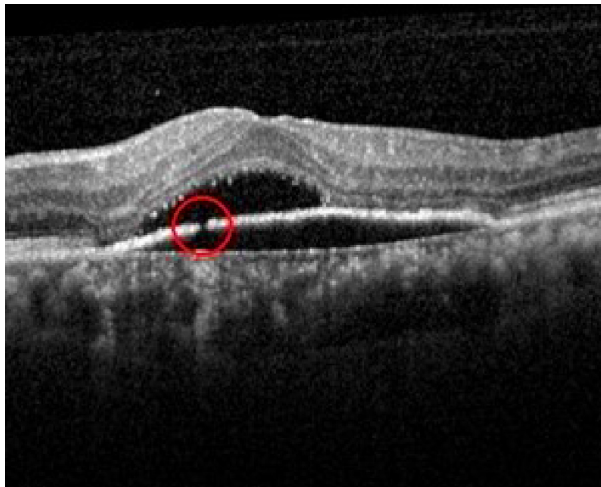


## Macular morphology and response to ranibizumab treatment in patients with wet age-related macular degeneration [Corrigendum]

Dervenis N, Younis S. *Clin Ophthalmol*. 2016;10:1117–1122.

On page 1119, Figure 2 was incorrectly presented. This should have read:



**Figure 2** RPE discontinuity and subretinal fluid.

**Notes:** Area of discontinuity shown in the red circle. This image was originally published in the Retina Image Bank. Avris Romario Diparaja Siahaan. Discontinuity RPE. Retina Image Bank. 2014; Image Number 20572. © the American Society of Retina Specialists.<sup>15</sup>

**Abbreviation:** RPE, retinal pigment epithelium.

On page 1122, References section, reference 15 should have been included along with the copyright information with Figure 2.

- Retina Image Bank. Discontinuity RPE. Available from: <http://imagebank.asrs.org/file/20572/discontinuity-rpe>. Accessed December 1, 2016.