

Laparoscopic bladder (Boari) flap ureteroneocystostomy

R B Nerli
M R Reddy
I R Ravish
S S Amarked

Department of Urology, KLES Kidney Foundation, KLES Hospital, Belgium

Abstract: Iatrogenic ureteric injuries in gynecologic surgery are quite common. The laparoscopic spectra of treatment gives a wide range of application. We present the case of a 40-year-old female who underwent total abdominal hysterectomy with bilateral salpingo-oophorectomy for dysfunctional uterine bleeding. Postoperatively, she had oliguria with raised creatinine and was found to have ureteric narrowing on magnetic resonance urogram. The patient was successfully managed by laparoscopic (Boari flap) ureteroneocystostomy.

Keywords: laparoscopy, Boari flap, ureteroneocystostomy

Iatrogenic ureteric injuries in gynecologic surgery are quite common. The laparoscopic spectra of treatment gives a wide range of application. We present the case of a 40-year-old female who underwent total abdominal hysterectomy with bilateral salpingo-oophorectomy for dysfunctional uterine bleeding (DUB). Postoperatively, she had oliguria with raised creatinine and was found to have ureteric obstruction on magnetic resonance urogram. The patient was successfully managed by laparoscopic (Boari flap) ureteroneocystostomy. Saline was released on the right and left side urinary Boari flap.

Case report

A 40-year-old female patient underwent total abdominal hysterectomy with bilateral salpingo-oophorectomy for DUB with right-side broad ligament fibroid. Serum creatinine was 0.9 mg% prior to surgery. Following surgery, 500 ml of urine was drained from the bladder. No urine output was noted for the next 48 hrs. Abdominal ultrasonography revealed bilateral minimal hydronephroureterosis. Serum creatinine rose to 7 mg%. An attempted retrograde bilateral *DJ* stenting failed. Magnetic resonance (MR) urogram revealed an urinary column up to the lower ureters. The patient was preoperatively dialyzed and biochemical parameters came down to near normal. Patient was taken up for diagnostic laparoscopy under general anesthesia. The patient was placed in a supine position four days after abdominal hysterectomy. A 10 mm infraumbilical port was placed along with two 5 mm ports, 4 cm below and lateral to the umbilicus. The lower ureters were identified at the level of crossing over iliac vessels. The ureters were traced downwards towards the bladder. The right lower ureter was found to be ligated with 2/0 vicryl. The ligature was cut and the ureter released. There was a 5 mm rent in the right ureter. A 6-Fr DJ stent (Bard, Karlsruhe, Germany) was introduced through cystoscopy and guided into the right renal pelvis under laparoscopic guidance. The rent in the ureter was sutured. The left lower ureter was found to be ligated and transected 5 cm above the vesicoureteric junction. The ligatures were cut and the proximal ureter was released. Approximation with the bladder was not possible in this situation. Boari flap was raised from

Correspondence: R B Nerli
Department of Urology, KLES Kidney Foundation, KLES Hospital and MRC, Nehru Nagar, Belgium – 590010
Email rbnerli@yahoo.com

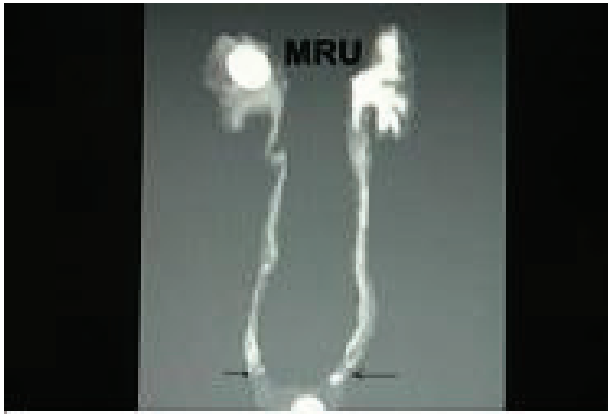


Figure 1 Magnetic resonance urogram (MRU) showing bilateral ureteric obstruction.

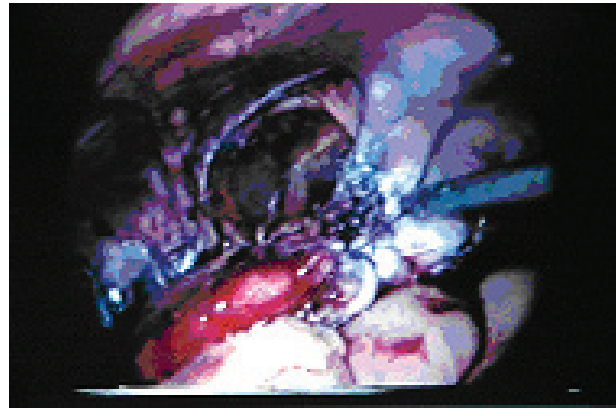

Figure 3 Tubularized Boari flap being anastomosed to the ureter.

the anterior surface of the bladder. The flap was converted into a tube and the lower end of the ureter was anastomosed to the end of the Boari flap tube. No attempt was made to create a submucosal tunnel antireflux technique. A 6-Fr DJ stent was placed and the bladder closed. Total operating time was 160 minutes. Urine output rose to 3400 cc in the first 24 hrs, serum creatinine came down to 0.9 mg% within 48 hrs, and ultrasound revealed no more hydronephrosis. No intra- or postoperative complications were noted. Postoperative paralytic ileus was noted for 96 hrs and conservatively managed.

Discussion

In gynecologic surgery, there is always the possibility that ureteral injuries will occur intraoperatively. Traditionally, these injuries were treated by laparotomy and ureteroneocystostomy. When the ureter is too short to reach the bladder without tension, bladder flap (Boari) technique is useful for ureteroneocystostomy.

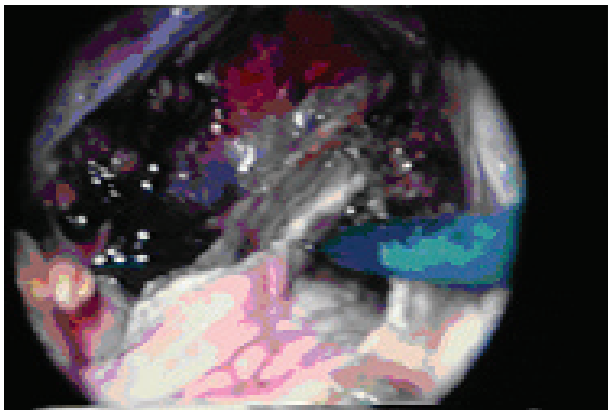


Figure 2 Creation of Boari flap.

The possible application of laparoscopic technique to different operations appears limitless. Attempts at laparoscopic ureteral reimplantation have involved the extravesical Lich-Gregoir technique with variable success. Ehrlich and colleagues (1994) and Reddy and Evans (1994) independently showed the safety and feasibility of this technique clinically. In a recent series, Lakshamanan and Fung (2000) reported 71 laparoscopic extravesical reimplantations, including 23 unilateral and 24 bilateral, with no persistent reflux or obstruction postoperatively. Fergany and colleagues (2001) reported their experience with laparoscopic bladder flap (Boari) ureteroneocystostomy in the porcine model. Six female farm pigs were used to perform a laparoscopic bladder flap ureteroneocystostomy. No intra- or postoperative complications were noted. We have successfully used bladder flap (Boari) ureteroneocystostomy to bridge the gap in lower ureter and maintain the continuity of the draining system. Laparoscopic ureteroneocystostomy using the bladder flap technique can be performed successfully. Robotics may make this procedure easier with better vision and dexterity during suturing.

References

- Ehrlich RM, Gershman A, Fuchs G. 1994. Laparoscopic vesicoureteroplasty children: initial case reports. *Urology*, 43:255–61.
- Fergany AF, Samee AA, Kaouk JH, et al. 2001. Laparoscopic porcine bladder flap (Boari) ureteric reimplantation. *J Urol*, 166:1920–3.
- Lakshamanan Y, Fung LC. 2000. Laparoscopic extravesicular ureteral reimplantation for vesicoureteral reflux: recent technical advances. *J Endourol*, 14:589–93.
- Reddy PK, Evans RM. 1994. Laparoscopic ureteroneocystostomy. *J Urol*, 152:2057–9.