

# Birdshot uveitis: current and emerging treatment options

Victor Menezo<sup>1,2</sup>  
Simon RJ Taylor<sup>3,4</sup>

<sup>1</sup>Institut Catala de Retina, Barcelona, Spain; <sup>2</sup>Department of Ophthalmology, Provincial Hospital Consortium Castellon, Castello, Spain; <sup>3</sup>Faculty of Medicine, Imperial College London, Hammersmith Hospital, London, UK; <sup>4</sup>Royal Surrey County Hospital NHS Foundation Trust, Guildford, UK

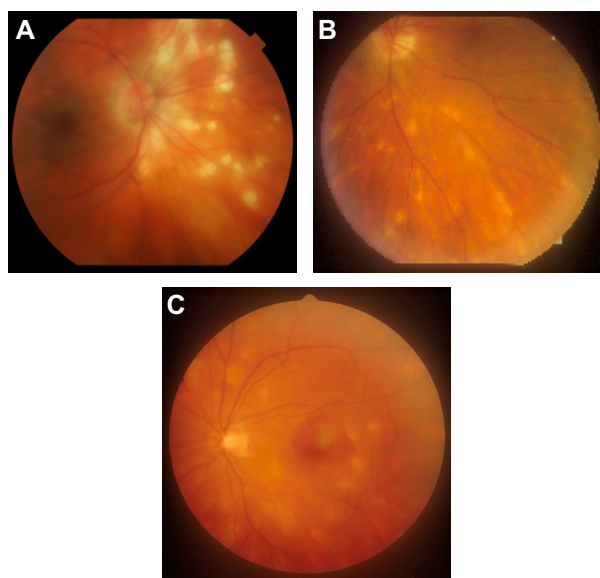
**Abstract:** Birdshot chorioretinopathy is a relatively uncommon subtype of idiopathic posterior uveitis with distinct clinical characteristics and a strong genetic association with the Human Leukocyte Antigen (HLA)-A29 allele. The diagnosis remains clinical and is based on the presence of typical clinical features, including multiple, distinctive, hypopigmented choroidal lesions throughout the fundus. The long-term visual prognosis of this disorder, however, remains guarded – central visual acuity can be preserved until late in the disease and it is not uncommon for patients to receive inadequate immunosuppressive treatment, leading to a poor long-term outcome in which peripheral retinal damage eventually leads to visual deterioration. Birdshot chorioretinopathy has proven a particularly attractive area of study within the field of uveitis, as it is a relatively easily defined disease with an associated human leukocyte antigen haplotype. Despite this, however, the immune mechanisms involved in its pathogenesis remain unclear, and some patients continue to lose retinal function despite therapy with corticosteroids and conventional immunosuppressive agents. Laboratory research continues to investigate the underlying mechanisms of disease, and clinical research is now being driven to improve the phenotyping and monitoring of this condition as, in the era of so-called personalized medicine, it is becoming increasingly important to identify patients at risk of visual loss early so that they can be treated more aggressively with targeted therapies such as the newer biological agents. This approach requires the formation of collaborative groups, as the relative rarity of the condition makes it difficult for one center to accumulate enough patients for worthwhile studies. Nevertheless, results obtained with newer therapies, such as biological agents directed against particular cytokines or cell-surface receptors, demonstrate ever improving control of the inflammation in refractory cases, providing hope that the outlook for visual function in this condition can only improve.

**Keywords:** birdshot chorioretinopathy, HLA-A29, retinal vasculitis, Th17 cells, monoclonal antibodies, interleukin antagonists

## Introduction

Birdshot chorioretinopathy (BSCR), also known as birdshot retinochoroiditis, is an uncommon type of idiopathic bilateral posterior uveitis that is typically seen in patients of Caucasian origin in their 6th decade of life and which has a strong genetic association with the human leukocyte antigen HLA-A29.<sup>1</sup> It is responsible for 6%–8% of cases of posterior uveitis, and the clinical presentation is usually one of a gradual deterioration of vision associated with the presence of floaters.<sup>2</sup> The condition has a distinct clinical phenotype consisting of mild anterior uveitis, but moderate vitritis and/or vitreous debris, retinal vasculitis, and characteristic multiple hypopigmented cream-colored, irregularly shaped choroidal lesions that are often clustered around the optic disc (Figure 1A–C).<sup>2</sup>

Correspondence: Simon RJ Taylor  
Imperial College London Faculty of  
Medicine, Hammersmith Hospital,  
Du Cane Road, London W12 0NN, UK  
Tel +44 20 8383 2394  
Fax +44 20 8383 2394  
Email s.r.taylor@imperial.ac.uk



**Figure 1** Fundus photographs (A-C) of patients with HLA-A29 positive birdshot chorioretinopathy demonstrating heterogeneity of fundal appearances.

BSCR is generally considered to be an isolated ocular disorder,<sup>3</sup> despite a few reports in the literature describing its possible association with systemic illnesses including essential hypertension, cerebrovascular accidents, hearing loss, and cutaneous immune-mediated conditions such as vitiligo and psoriasis.<sup>4-8</sup> Its pathogenesis, however, remains unclear, and this has contributed to a lack of optimal treatment protocols. The natural history of BSCR is of a chronic and progressive disorder – the majority of patients develop chronic disease with progressive retinal dysfunction, although a smaller proportion do have limited disease with spontaneous remission of their intraocular inflammation.<sup>1,2</sup> Central retinal function can be preserved until quite late in the disease, leading to a false impression of disease quiescence and thus inadequate immunosuppression being introduced, potentially prejudicing the long-term visual prognosis.

The diagnosis of BSCR is often reinforced by testing for the HLA-A29 haplotype, but it remains a clinical one: the positive predictive value of HLA-A29 testing is less than 50% in the posterior uveitis population, owing to some 8% of the general population being HLA-A29-positive.<sup>9</sup> Internationally accepted criteria for the diagnosis of BSCR are based on the presence of bilateral mild intraocular inflammation, “birdshot lesions,” and the absence of keratic precipitates and posterior synechiae.<sup>1</sup>

BSCR has proven particularly attractive to study within the field of uveitis, as it is a relatively easily defined disease with an associated human leukocyte antigen haplotype. The immune mechanisms involved in its pathogenesis remain

unclear, however, and laboratory research continues to investigate the underlying mechanisms of disease. The advent of therapeutic biological agents targeted at particular cytokines and molecular pathways has also exposed our lack of knowledge of both the pathogenetic mechanisms of disease as well as how to accurately assess disease activity and response to treatment. Accurate phenotyping is particularly important for early identification of patients at risk of visual loss, such that they can be treated more aggressively with targeted therapies, which may themselves carry an increased side effect profile that needs adequate justification for use. This is particularly key, as a significant proportion of patients continue to lose retinal function despite therapy with corticosteroids and conventional immunosuppressive agents.<sup>2</sup>

## Disease pathogenesis

Despite the strong association of HLA-A29 allele with BSCR, such that 85%–95% of affected patients carry the HLA-A29 haplotype,<sup>1,9</sup> the pathogenesis of BSCR remains largely unknown.<sup>10</sup> Evidence for the role of HLA-A29 in the development of BSCR originates from observations that transgenic mice either expressing HLA-A29 or injected with human HLA-A29.2-purified cDNA develop spontaneous bilateral posterior uveitis reminiscent of human BSCR.<sup>11,12</sup> Sequences from retinal soluble antigen also bind efficiently to HLA-A29,<sup>13</sup> and in vitro responsiveness to retinal soluble antigen can be demonstrated in a high proportion of BSCR patients;<sup>14</sup> however, nearly 8% of the Caucasian population is HLA-A29-positive, and the vast majority of these people do not develop BSCR.<sup>1,9</sup> It has therefore been theorized that molecular mimicry triggered by prior microbial infection could play a direct role in triggering the disease,<sup>15</sup> although there remains a lack of conclusive evidence for a direct association between any microbiological infection and BSCR.<sup>16</sup>

A role of T-cells in disease pathogenesis has been suggested by both histopathology<sup>17</sup> and the efficacy of anti-T-cell agents such as cyclosporine A,<sup>18</sup> and recent attention is now focusing on the more recently described Th17 system. Upregulated Th17 responses and increased interleukin (IL)-17 production from T-cells have previously been associated with chronic inflammation in gut disease<sup>19</sup> as well as other human leukocyte antigen class I-related diseases.<sup>20</sup>

Increased IL-17 levels have also been demonstrated in the aqueous humor of eyes with BSCR,<sup>21</sup> and increased serum IL-17, IL-23, and transforming growth factor-beta 1 levels have also been found to be raised in some treatment-naïve patients with BSCR.<sup>22</sup> Taken together, these findings are suggestive of an organ-specific Th17-driven

autoimmune process,<sup>22</sup> factors important in Th17 cell differential being found in the serum, and the effector cytokine of Th17 cells, IL-17, being found in intraocular fluid. This may help to direct treatment away from nonspecific T-cell blockade, although the IL-17 inhibitor secukinumab failed to demonstrate efficacy in uveitis in its initial clinical trials.<sup>23</sup> Further trials in more selected patient populations are, however, planned.<sup>23</sup>

## Monitoring disease activity and response to treatment

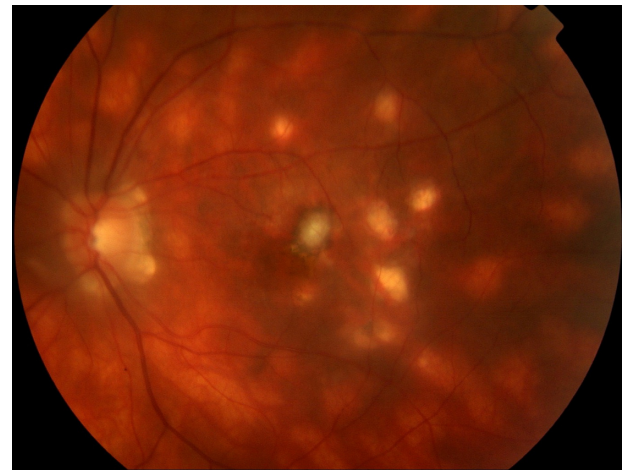As our knowledge of the pathogenesis of uveitis in general improves, this presents increasing opportunities for targeted treatment and early intervention.<sup>24</sup> One of the major goals of therapy has to be the early identification of patients at risk of a poor outcome, so that intervention can be targeted at this group in a more aggressive fashion. In order to achieve this, however, improved disease phenotyping, early detection of disease progression, and rapid assessment of any response to treatment are all required.

It is characteristic of patients with BSCR to complain of poor quality of vision despite often having good best-corrected distance visual acuity until late in the disease.<sup>25</sup> Symptoms including nyctalopia, loss of contrast sensitivity, and color vision defects are common,<sup>26</sup> and abnormalities in color discrimination, predominantly in the blue–yellow spectrum, are also very common complaints, occurring in almost two-thirds of patients.<sup>4</sup> These findings suggest that simply monitoring distance visual acuity is probably not sufficient to assess visual function or monitor disease progression in this disorder, even though retrospective studies suggest a significant association between visual acuity at the onset of the disease and long-term visual outcome.<sup>8,24</sup>

Biomicroscopically visible ocular features of disease severity or chronicity, such as hyperpigmentation of the birdshot lesions<sup>27</sup> or the development of choroidal neovascular membranes (Figure 2),<sup>2,8</sup> also tend to occur too late in the disease process to be useful markers of disease progression. Attention has therefore been directed for some time at other investigational modalities, to see whether these can detect disease progression earlier and more reliably, allowing for the early identification of at-risk patients.

## Imaging of the retinal and choroidal circulations

Fundus fluorescein angiography remains the gold-standard assessment of the integrity of the retinal vasculature, but it has relatively low specificity in characterizing birdshot lesions,



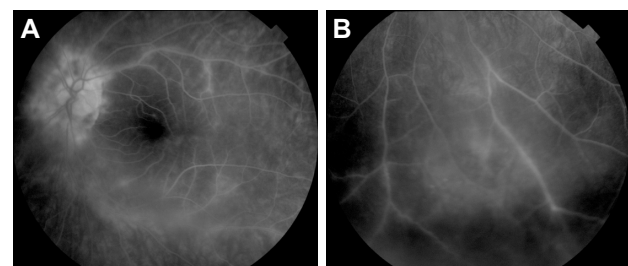
**Figure 2** A patient with long-standing birdshot chorioretinopathy who developed a central choroidal neovascular membrane associated with a dramatic drop in visual acuity.

especially in the early stages of the disease when the overlying retinal pigment epithelium is unaffected. Nevertheless, it remains a useful tool for the assessment of disease activity and its complications, including the presence of CMO and retinal vasculitis (Figure 3A and B).<sup>5,28,29</sup> Indocyanine green angiography is probably more sensitive,<sup>30</sup> and the fundus lesions tend to show different characteristics at different stages of the disease, making indocyanine green angiography one of the currently preferred methods of monitoring disease activity and response to treatment.<sup>30</sup>

While not directly imaging the retinal or choroidal circulation, autofluorescence provides a further camera-based imaging modality that is used in some centers to monitor patients with BSCR,<sup>31,32</sup> although there is as yet little evidence regarding its prognostic value.

## Optical coherence tomography scanning

Macular edema occurs in up to 50% of patients with BSCR (although there is considerable variability in its



**Figure 3** Fundus fluorescein angiograms demonstrating (A) central and (B) peripheral retinal vasculitis associated with birdshot chorioretinopathy.

reported prevalence), and it is the commonest cause of visual loss.<sup>29,33,34</sup> Optical coherence tomography (OCT) is the favored method by which to quantify retinal thickness and treatment response,<sup>33,35</sup> although there is still some controversy regarding the correlation between OCT and fundus fluorescein angiography findings.<sup>33,36</sup> However, more recent data suggests that retinal thinning is also an important association of visual deterioration, which may complicate analyses of central macular thickness. Gradual thinning of the outer retina occurs in the late stages of BSCR<sup>37</sup> and is associated with significantly lower visual acuities.<sup>40</sup> Subtle changes in the macular architecture, such as the loss of a linear band of high reflectivity corresponding to the photoreceptor layer, may also be related to abnormal visual function.<sup>33,36</sup>

Extramacular enhanced depth OCT scanning is a newer technique in which high resolution visualization of the choroidal anatomy is possible. Rather than focusing on the central retina, the analysis algorithms are adjusted to enable penetration into deeper layers of the choroidal anatomy, and the scanner can be directed at more peripheral retinal locations.<sup>39</sup> Recent evidence from patients with BSCR suggests that focal loss of the inner segment/outer segment junction can be detected, together with thinning of specific choroidal vascular layers.<sup>39</sup> This may prove useful in detecting extramacular disease progression and response to treatment, although data are currently limited and further studies are required.

## Electrodiagnostic testing

Abnormal electrophysiological retinal responses were described in some of the earliest reports of BSCR,<sup>40</sup> and electrodiagnostic testing has become one of the most important tools in the management of patients with BSCR. It allows for the early detection and objective monitoring of subtle functional retinal changes ahead of changes in clinical phenotype that herald irreversible loss of visual function.<sup>41,42</sup> Electroretinography typically reveals a disproportionate decrease in b-wave amplitude compared with a-wave amplitude in the early stages of the disease, suggesting neural retinal dysfunction with relative outer retinal sparing,<sup>41,42</sup> which has been suggested to be related to inner retinal dysfunction secondary to retinal vasculitis.<sup>43</sup>

Photoreceptor dysfunction usually occurs later in the disease, and rod dysfunction usually precedes cone dysfunction, detectable by relative changes in the scotopic and photopic b-waves.<sup>41</sup> Nevertheless, delayed 30 Hz cone flicker implicit time appears to be the most sensitive and consistently affected electrophysiological parameter.<sup>42,44</sup> It has been demonstrated to correlate well with disease activity and might be useful in predicting treatment failure.<sup>44,45</sup>

Electrophysiological testing is, however, time-consuming and requires experienced operators to obtain consistent results, limiting its repeatability and general applicability.

## Perimetry

A large range of different visual field defects have been described in the literature, including generalized diminished sensitivity, peripheral constriction, and/or small islands of paracentral scotomas, which appear not to be correlated with the birdshot lesion, as well as blind-spot enlargement.<sup>4</sup> Despite a lack of consistency in visual field assessment between different study groups, it is clear that extensive visual field deterioration can coexist with relatively well-preserved good central visual acuity, and that these changes may precede other clinical symptoms.<sup>46</sup> Furthermore, visual field assessment may also be useful in monitoring response to treatment in these patients.<sup>46,47</sup> This does suggest a role for perimetry as an adjunct to visual acuity testing alone in the detection of disease activity, but it may not be sensitive enough to detect early evidence of disease progression. Microperimetry has been thought to provide more sensitive assessments in some macular diseases, but there is again limited evidence for its use in BSCR.<sup>48</sup>

## Treatment

As with noninfectious uveitis in general, corticosteroids remain the mainstay of therapy in BSCR due to their strong and rapid anti-inflammatory and immunosuppressive effects.<sup>49</sup> As the disease is usually bilateral, these tend to be administered orally rather than locally, starting at a high dose followed by a slow taper. Owing, however, to the chronic nature of the disease and slow decline in visual and retinal function in the absence of adequate immunosuppression, early introduction of second-line immunosuppressive agents appears to be beneficial in preserving visual function and in minimizing side effects from higher doses of corticosteroids.<sup>45,50,51</sup>

## Conventional second-line immunosuppression

Although the pathogenesis of BSCR remains incompletely understood, evidence of T-cell-mediated responses has supported the use of cyclosporine in patients for whom low-dose prednisolone is insufficient to control their intraocular inflammation;<sup>47</sup> however, problems with renal impairment and hypertension limit the drug's usefulness.<sup>18,45,52</sup> Antimetabolite agents such as azathioprine, methotrexate, and mycophenolate mofetil have all been used as steroid-sparing agents to



treat patients with BSCR with varying degrees of success, either separately<sup>50</sup> or in combination.<sup>53</sup>

## Established biologic agents

In contrast to immunosuppressive agents, biologic agents modulate inflammation by targeting specific receptors or single molecules and thus offer a more specific targeted suppression of immune effector response and tissue damage. They have been shown to be a useful alternative in patients who failed to respond to conventional immunosuppressive therapy,<sup>54,55</sup> but there is also evidence that their use can reduce the risk of visual loss in severe forms of intraocular inflammation, such as uveitis related to Behcet's disease.<sup>56</sup>

The greatest volume of evidence for the biological agents exists for the tumor necrosis factor (TNF)-alpha inhibitors. This molecule has been detected in human eyes with a variety of inflammatory conditions and it plays a key role in the regulation of the inflammatory process seen in experimental autoimmune uveitis in rodents.<sup>57</sup> Inhibition of TNF- $\alpha$  results in a decrease in adhesion molecules and proinflammatory cytokines as well as in regulation of chemokine levels. The use of anti TNF- $\alpha$  antibodies can be effective in both short- and long-term management of patients with refractory posterior uveitis.<sup>58,59</sup>

Infliximab, a chimeric monoclonal antibody targeted against TNF- $\alpha$ , can be very effective in the treatment of patients with different types of refractory uveitis, including those with BSCR.<sup>60–62</sup> In the largest series to date of patients with BSCR treated with infliximab, nearly 90% of patients achieved complete control of inflammation after 1 year of treatment.<sup>63</sup> Furthermore, patients with inactive inflammation at the outset of treatment were able to maintain disease quiescence with an acceptable side effect profile.

Evidence is also beginning to support the use of adalimumab in uveitis. Adalimumab is a humanized monoclonal antibody against soluble and membrane-bound TNF, which has the advantage of being a subcutaneous injection that patients can perform at home, rather than requiring hospital admission for intravenous infusions.<sup>64</sup>

## Novel biologic agents

Daclizumab is a humanized immunoglobulin G monoclonal antibody directed against the CD25 subunit of the IL-2 receptor complex that has been shown to be effective in suppressing intraocular inflammation. IL-2 receptors are expressed on the cell membranes of activated T-cells, and significant increases in IL-2 levels have been detected in the aqueous humor of patients with BSCR.<sup>21</sup> A pilot study has demonstrated that twice-weekly treatments with daclizumab

are effective in controlling intraocular inflammation and stabilizing visual acuity in BSCR patients who were intolerant to conventional immunosuppressive therapy, although some patients still experienced ongoing deterioration of their ERG parameters.<sup>65</sup>

In terms of the IL-17 pathway, secukinumab is a human monoclonal antibody directed against IL-17 that failed to demonstrate efficacy in early trials in uveitis, but which may hold some promise for more targeted patient groups.<sup>23</sup> Ustekinumab targets the p40 subunit of IL-23 and IL-12, and IL-12, hence targeting the Th17 and Th1 pathways. This has been approved for psoriasis, but there is as yet no data for BSCR or other types of uveitis.<sup>22</sup> Nevertheless, this may be a promising therapeutic approach and provides hope for interrupting a mechanism that may be involved in the generation of tolerance.<sup>66</sup> Similarly, IL-6 is involved in the pathogenesis of experimental autoimmune uveitis and is necessary for the generation of local and systemic Th17 responses in animal models of disease.<sup>67</sup> IL-6 is blocked by tocilizumab, and several case reports have now demonstrated its efficacy in the treatment of uveitis refractory to anti-TNF, including cases of BSCR.<sup>68</sup>

Other novel systemic approaches include reducing antigen presentation by blocking lymph node efflux via the sphingosine-1-phosphate receptor (fingolimod)<sup>69</sup> and reducing inflammatory cell migration via  $\alpha$ 4-integrin (natalizumab).<sup>70</sup> There is as yet no evidence for either of these in BSCR.

## Other systemic immunomodulatory agents

Intravenous immunoglobulin is a therapeutic preparation of human immunoglobulin G obtained from the pooled plasma of healthy individuals that can be used to treat a number of autoimmune conditions, including uveitis. The mechanisms of action are complicated and include effects on both the innate and adaptive immune systems.<sup>71</sup> One study has shown efficacy in the treatment of refractory BSCR.<sup>72</sup>

Interferons (IFNs) possess antiviral, anti-proliferative, and immunomodulatory properties.<sup>73</sup> Interferon- $\alpha$ 2a is the type most commonly administered in uveitis, and is normally produced by dendritic cells in response to viral infection, stimulating the activity of NK and T cytotoxic cells and increasing the expression of Major Histocompatibility Complex (MHC) class I. It is administered subcutaneously and the majority of its use has been in uveitis associated with Behcet's disease, although it has also been used with some success in BSCR.<sup>74</sup> Unfortunately, it has many side effects, especially flu-like symptoms, which can be debilitating.

## Local therapy

In addition to oral treatment, local therapy can be useful in managing acute exacerbations of the disease, in particular these affecting only one eye or in cases of asymmetric involvement.<sup>75</sup> Both periocular and intravitreal corticosteroids have been used. Periocular corticosteroid injections are safe, with a low risk of complications,<sup>76–78</sup> but intravitreal therapy is more effective, and triamcinolone is the intravitreal corticosteroid of choice. However, raised intraocular pressure occurs in up to 50% of patients within a year,<sup>79</sup> and the rate of cataract progression is greatly increased, particularly after several injections.<sup>80</sup> More recent developments include sustained-release corticosteroid implants and non-corticosteroid intravitreal therapies.

## Intravitreal corticosteroid implants

The Ozurdex dexamethasone intravitreal implant (Allergan, Irvine, CA, USA) is licensed for the treatment of uveitis, and uses a biodegradable polymer delivery system to release dexamethasone over about 6 months.<sup>81</sup> It is reported to be effective in both adult<sup>82</sup> and pediatric<sup>83</sup> uveitis, but the side effect profile of multiple implants is not yet clear and further data are needed, including in BSCR.

Retisert (Bausch and Lomb, New Jersey, NY, USA) is an intravitreal implant that is surgically placed in the vitreous cavity and which releases fluocinolone acetonide to the posterior pole for approximately 2.5 years.<sup>84,85</sup> Its efficacy has been demonstrated in patients with BSCR,<sup>86</sup> but all patients require cataract surgery within 3 years<sup>87</sup> and up to 40% require trabeculectomy surgery.<sup>87</sup> Interestingly, BSCR patients are statistically more likely to require surgery earlier than other patients with uveitis.<sup>86</sup> There is currently no published evidence for the use in uveitis of either the Iluvien fluocinolone implant (Alimera Sciences, Alpharetta, GA, USA)<sup>88</sup> or the I-vation triamcinolone implant (SurModics, Eden Prairie, MN, USA).<sup>88,89</sup>

## Intravitreal non-corticosteroid therapy

In order to avoid the side effects of intraocular corticosteroids, the use of other agents has expanded in recent years. Intraocular methotrexate has been assessed recently in uveitis.<sup>90,91</sup> In one prospective clinical trial, it was found to be effective in reducing posterior segment inflammation,<sup>92</sup> and a larger collaborative series has suggested that it may induce longer-term remission in some patients,<sup>93</sup> but there is no direct evidence for its use in BSCR. Vascular endothelial growth factor inhibition has also been essayed as a therapeutic approach, but neither bevacizumab nor ranibizumab appear particularly effective.<sup>94–97</sup>

Local inhibition of TNF- $\alpha$  with intraocular infliximab appeared a more promising therapeutic direction, but clinical trials had mixed results and there has now been a call for a moratorium on its use outside of well-designed trials,<sup>98,99</sup> similar to the case of adalimumab.<sup>100,101</sup> However, recent preclinical studies of the TNF inhibitor ESBA105 indicate good bioavailability from topical administration,<sup>102</sup> and it may be that this antibody fragment can overcome the problems seen with full-size molecules.

Sirolimus, also known as rapamycin, is another potential non-corticosteroid therapy. It inhibits the mammalian target of rapamycin (mTOR) by binding to the immunophilin FK protein 12 (FKBP-12), and thus interrupts T-cell activation and proliferation; it also suppresses T-cell proliferation through the inhibition of IL-2, IL-4, and IL-15.<sup>103</sup> A Phase II study of intravitreal and subconjunctival administration of sirolimus proved encouraging,<sup>104</sup> and the results of Phase III trials are awaited.

## Future directions

Personalized medicine remains an important goal in the therapy of autoimmune conditions including BSCR. The variability of prognosis combined with the increasing array of treatment options, all with their own side effect profile, means that there is considerable value in being able to determine a patient's prognosis early in their disease process, and to direct their treatment regime accordingly. Similarly, the advent of the exquisitely targeted biological agents offers the opportunity to tailor therapeutic option to underlying immune dysregulation on an individual basis.

For this to be successful, however, patient profiling needs to improve. Disease phenotyping is important, as are the early detection of disease activity and accurate measurement of response to treatment, and advances have been made in these areas with the advent of improved ocular imaging.

In addition to systemic treatment, local administration of drugs remains an attractive option in conditions such as BSCR in which there are no systemic disease components. Locally delivered corticosteroids have a significant ocular side effect profile, so non-corticosteroid options are of particular interest, although it has proved difficult to match the efficacy that corticosteroids offer. The hope is that increased understanding of the pathophysiology of uveitis and the mechanisms of ocular damage will enable the generation of entirely novel therapeutic mechanisms.<sup>24,105</sup> For example, improved understanding of how inflammasomes potentiate the activation of caspase-1 to release IL-1 $\beta$  and IL-18<sup>106</sup> leads to the potential

for locally delivered anti-IL-1 or anti-caspase-1 therapies,<sup>107</sup> possibly via novel technologies such as antibody fragment or short interfering RNA approaches.<sup>102,108,109</sup>

This advent of novel therapies provides hope for improved outcomes in BSCR in the future, but also challenges clinicians in terms of directing these therapies appropriately to at-risk patients early enough to avoid visual loss, whilst minimizing any associated side effects in patients with less aggressive disease.

## Acknowledgment

ST is supported by the UK National Institute of Health Research. ST has received consultancy fees from Allergan, Novartis and Santen.

## Disclosure

The authors report no conflicts of interest in this work. The views and opinions expressed herein are those of the authors and do not necessarily reflect those of the UK Department of Health.

## References

- Levinson RD, Brezin A, Rothova A, Accorinti M, Holland GN. Research criteria for the diagnosis of birdshot chorioretinopathy: results of an International Consensus Conference. *Am J Ophthalmol*. 2006;141(1):185–187.
- Shah KH, Levinson RD, Yu F, et al. Birdshot chorioretinopathy. *Surv Ophthalmol*. 2005;50(6):519–541.
- Pagnoux C, Mahr A, Aouba A, et al. Extraocular manifestations of birdshot chorioretinopathy in 118 French patients. *Presse Med*. 2010;39(5):e97–e102.
- Gasch AT, Smith JA, Whitcup SM. Birdshot retinochoroidopathy. *Br J Ophthalmol*. 1999;83(2):241–249.
- Gass JD. Vitiliginous chorioretinitis. *Arch Ophthalmol*. 1981;99(10):1778–1787.
- Heaton JM, Mills RP. Sensorineural hearing loss associated with birdshot retinochoroidopathy. *Arch Otolaryngol Head Neck Surg*. Jun 1993;119(6):680–681.
- Priem HA, Oosterhuis JA. Birdshot chorioretinopathy: clinical characteristics and evolution. *Br J Ophthalmol*. 1988;72(9):646–659.
- Rothova A, Berendschot TT, Probst K, van Kooij B, Baarsma GS. Birdshot chorioretinopathy: long-term manifestations and visual prognosis. *Ophthalmology*. 2004;111(5):954–959.
- Zamecki KJ, Jabs DA. HLA typing in uveitis: use and misuse. *Am J Ophthalmol*. 2010;149(2):189–193. e2.
- Brézin AP, Monnet D, Cohen JH, Levinson RD. HLA-A29 and birdshot chorioretinopathy. *Ocul Immunol Inflamm*. 2011;19(6):397–400.
- Szpak Y, Vieville JC, Tabary T, et al. Spontaneous retinopathy in HLA-A29 transgenic mice. *Proc Natl Acad Sci U S A*. 2001;98(5):2572–2576.
- de Kozak Y, Camelo S, Pla M. Pathological aspects of spontaneous uveitis and retinopathy in HLA-A29 transgenic mice and in animal models of retinal autoimmunity: relevance to human pathologies. *Ophthalmic Res*. 2008;40(3–4):175–180.
- Boisgerault F, Khalil I, Tieng V, et al. Definition of the HLA-A29 peptide ligand motif allows prediction of potential T-cell epitopes from the retinal soluble antigen, a candidate autoantigen in birdshot retinopathy. *Proc Natl Acad Sci U S A*. 1996;93(8):3466–3470.
- Nussenblatt RB, Mittal KK, Ryan S, Green WR, Maumenee AE. Birdshot retinochoroidopathy associated with HLA-A29 antigen and immune responsiveness to retinal S-antigen. *Am J Ophthalmol*. 1982;94(2):147–158.
- Holak HM, Szymaniec S, Holak SA. The pathogenesis of birdshot chorioretinopathy. *Surv Ophthalmol*. 2006;51(4):446–447; author reply 447.
- Christen U, von Herrath MG. Initiation of autoimmunity. *Curr Opin Immunol*. 2004;16(6):759–767.
- Gaudio PA, Kaye DB, Crawford JB. Histopathology of birdshot retinochoroidopathy. *Br J Ophthalmol*. 2002;86(12):1439–1441.
- Vitale AT, Rodriguez A, Foster CS. Low-dose cyclosporine therapy in the treatment of birdshot retinochoroidopathy. *Ophthalmology*. 1994;101(5):822–831.
- Miossec P, Korn T, Kuchroo VK. Interleukin-17 and type 17 helper T cells. *N Engl J Med*. 2009;361(9):888–898.
- Brown MA. Genetics of ankylosing spondylitis. *Curr Opin Rheumatol*. 2010;22(2):126–132.
- Kuiper JJ, Mutis T, de Jager W, de Groot-Mijnes JD, Rothova A. Intraocular interleukin-17 and proinflammatory cytokines in HLA-A29-associated birdshot chorioretinopathy. *Am J Ophthalmol*. 2011;152(2):177–182. e1.
- Yang P, Foster CS. Interleukin 21, interleukin 23, and transforming growth factor beta 1 in HLA-A29-associated birdshot retinochoroidopathy. *Am J Ophthalmol*. 2013;156(2):400–406. e2.
- Dick AD, Tugal-Tutkun I, Foster S, et al. Secukinumab in the treatment of noninfectious uveitis: results of three randomized, controlled clinical trials. *Ophthalmology*. 2013;120(4):777–787.
- de Smet MD, Taylor SR, Bodaghi B, et al. Understanding uveitis: the impact of research on visual outcomes. *Prog Retin Eye Res*. 2011;30(6):452–470.
- Levinson RD, Monnet D, Yu F, Holland GN, Gutierrez P, Brezin AP. Longitudinal cohort study of patients with birdshot chorioretinopathy. V. Quality of life at baseline. *Am J Ophthalmol*. 2009;147(2):346–350. e2.
- Oh KT, Christmas NJ, Folk JC. Birdshot retinochoroiditis: long term follow-up of a chronically progressive disease. *Am J Ophthalmol*. 2002;133(5):622–629.
- Monnet D, Brezin AP, Holland GN, et al. Longitudinal cohort study of patients with birdshot chorioretinopathy. I. Baseline clinical characteristics. *Am J Ophthalmol*. 2006;141(1):135–142.
- Guex-Crosier Y, Herbort CP. Prolonged retinal arterio-venous circulation time by fluorescein but not by indocyanine green angiography in birdshot chorioretinopathy. *Ocul Immunol Inflamm*. 1997;5(3):203–206.
- Papadia M, Herbort CP. Reappraisal of birdshot retinochoroiditis (BRC): a global approach. *Graefes Arch Clin Exp Ophthalmol*. 2013;251(3):861–869.
- Fardeau C, Herbort CP, Kullmann N, Quentel G, LeHoang P. Indocyanine green angiography in birdshot chorioretinopathy. *Ophthalmology*. 1999;106(10):1928–1934.
- Koizumi H, Pozzoni MC, Spaide RF. Fundus autofluorescence in birdshot chorioretinopathy. *Ophthalmology*. 2008;115(5):e15–e20.
- Giuliari G, Hinkle DM, Foster CS. The spectrum of fundus autofluorescence findings in birdshot chorioretinopathy. *J Ophthalmol*. 2009;2009:567693.
- Monnet D, Levinson RD, Holland GN, Haddad L, Yu F, Brezin AP. Longitudinal cohort study of patients with birdshot chorioretinopathy. III. Macular imaging at baseline. *Am J Ophthalmol*. 2007;144(6):818–828.
- Taylor SR, Lightman SL, Sugar EA, et al. The impact of macular edema on visual function in intermediate, posterior, and panuveitis. *Ocul Immunol Inflamm*. 2012;20(3):171–181.
- Puliafito CA, Hee MR, Lin CP, et al. Imaging of macular diseases with optical coherence tomography. *Ophthalmology*. 1995;102(2):217–229.
- Kempner JH, Sugar EA, Jaffe GJ, et al; Multicenter Uveitis Steroid Treatment (MUST) Trial Research Group. Fluorescein angiography versus optical coherence tomography for diagnosis of uveitic macular edema. *Ophthalmology*. 2013;120(9):1852–1859.

37. Papadia M, Jeannin B, Herbort CP. OCT findings in birdshot chorioretinitis: a glimpse into retinal disease evolution. *Ophthalmic Surg Lasers Imaging*. 2012;43(Suppl 6):S25–S31.
38. Birch DG, Williams PD, Callanan D, Wang R, Locke KG, Hood DC. Macular atrophy in birdshot retinochoroidopathy: an optical coherence tomography and multifocal electroretinography analysis. *Retina*. 2010;30(6):930–937.
39. Keane PA, Allie M, Turner SJ, et al. Characterization of birdshot chorioretinopathy using extramacular enhanced depth optical coherence tomography. *JAMA Ophthalmol*. 2013;131(3):341–350.
40. Kaplan HJ, Aaberg TM. Birdshot retinochoroidopathy. *Am J Ophthalmol*. 1980;90(6):773–782.
41. Hirose T, Katsumi O, Pruett RC, Sakaue H, Mehta M. Retinal function in birdshot retinochoroidopathy. *Acta Ophthalmol (Copenh)*. 1991;69(3):327–337.
42. Holder GE, Robson AG, Pavesio C, Graham EM. Electrophysiological characterisation and monitoring in the management of birdshot chorioretinopathy. *Br J Ophthalmol*. 2005;89(6):709–718.
43. Monnet D, Brezin AP. Birdshot chorioretinopathy. *Curr Opin Ophthalmol*. 2006;17(6):545–550.
44. Sobrin L, Lam BL, Liu M, Feuer WJ, Davis JL. Electroretinographic monitoring in birdshot chorioretinopathy. *Am J Ophthalmol*. 2005;140(1):52–64.
45. Kiss S, Ahmed M, Letko E, Foster CS. Long-term follow-up of patients with birdshot retinochoroidopathy treated with corticosteroid-sparing systemic immunomodulatory therapy. *Ophthalmology*. 2005;112(6):1066–1071.
46. de Courten C, Herbort CP. Potential role of computerized visual field testing for the appraisal and follow-up of birdshot chorioretinopathy. *Arch Ophthalmol*. 1998;116(10):1389–1391.
47. Thorne JE, Jabs DA, Kedhar SR, Peters GB, Dunn JP. Loss of visual field among patients with birdshot chorioretinopathy. *Am J Ophthalmol*. 2008;145(1):23–28.
48. Giuliani GP, Pujari S, Shaikh M, Marvell D, Foster CS. Microperimetry findings in patients with birdshot chorioretinopathy. *Can J Ophthalmol*. 2010;45(4):399–403.
49. Stahn C, Buttgerit F. Genomic and nongenomic effects of glucocorticoids. *Nat Clin Pract Rheumatol*. 2008;4(10):525–533.
50. Becker MD, Wertheim MS, Smith JR, Rosenbaum JT. Long-term follow-up of patients with birdshot retinochoroidopathy treated with systemic immunosuppression. *Ocul Immunol Inflamm*. 2005;13(4):289–293.
51. Knecht PB, Papadia M, Herbort CP Jr. Early and sustained treatment modifies the phenotype of birdshot retinochoroiditis. *Int Ophthalmol*. Epub October 1, 2013.
52. Le Hoang P, Girard B, Deray G, et al. Cyclosporine in the treatment of birdshot retinochoroidopathy. *Transplant Proc*. 1988;20(3 Suppl 4):128–130.
53. Cervantes-Castañeda RA, Gonzalez-Gonzalez LA, Cordero-Coma M, Yilmaz T, Foster CS. Combined therapy of cyclosporine A and mycophenolate mofetil for the treatment of birdshot retinochoroidopathy: a 12-month follow-up. *Br J Ophthalmol*. 2013;97(5):637–643.
54. Imrie FR, Dick AD. Biologics in the treatment of uveitis. *Curr Opin Ophthalmol*. 2007;18(6):481–486.
55. Joshi L, Lightman SL, Salama AD, Shirodkar AL, Pusey CD, Taylor SR. Rituximab in refractory ophthalmic Wegener's granulomatosis: PR3 titers may predict relapse, but repeat treatment can be effective. *Ophthalmology*. 2011;118(12):2498–2503.
56. Taylor SR, Singh J, Menezo V, Wakefield D, McCluskey P, Lightman S. Behcet disease: visual prognosis and factors influencing the development of visual loss. *Am J Ophthalmol*. 2011;152(6):1059–1066.
57. Dick AD, Duncan L, Hale G, Waldmann H, Isaacs J. Neutralizing TNF- $\alpha$  activity modulates T-cell phenotype and function in experimental autoimmune uveoretinitis. *J Autoimmun*. 1998;11(3):255–264.
58. Benitez-del-Castillo JM, Martinez-de-la-Casa JM, Pato-Cour E, et al. Long-term treatment of refractory posterior uveitis with anti-TNF $\alpha$  (infliximab). *Eye (Lond)*. 2005;19(8):841–845.
59. Joseph A, Raj D, Dua HS, Powell PT, Lanyon PC, Powell RJ. Infliximab in the treatment of refractory posterior uveitis. *Ophthalmology*. 2003;110(7):1449–1453.
60. Baughman RP, Bradley DA, Lower EE. Infliximab in chronic ocular inflammation. *Int J Clin Pharmacol Ther*. 2005;43(1):7–11.
61. Lindstedt EW, Baarsma GS, Kuijpers RW, van Hagen PM. Anti-TNF- $\alpha$  therapy for sight threatening uveitis. *Br J Ophthalmol*. 2005;89(5):533–536.
62. Suhler EB, Smith JR, Wertheim MS, et al. A prospective trial of infliximab therapy for refractory uveitis: preliminary safety and efficacy outcomes. *Arch Ophthalmol*. 2005;123(7):903–912.
63. Artornombudh P, Gevorgyan O, Payal A, Siddique SS, Foster CS. Infliximab treatment of patients with birdshot retinochoroidopathy. *Ophthalmology*. 2013;120(3):588–592.
64. Díaz-Llopis M, Salom D, Garcia-de-Vicuña C, et al. Treatment of refractory uveitis with adalimumab: a prospective multicenter study of 131 patients. *Ophthalmology*. 2012;119(8):1575–1581.
65. Sobrin L, Huang JJ, Christen W, Kafkala C, Choopong P, Foster CS. Dacizumab for treatment of birdshot chorioretinopathy. *Arch Ophthalmol*. 2008;126(2):186–191.
66. Barbi J, Pardoll D, Pan F. Metabolic control of the Treg/Th17 axis. *Immunol Rev*. 2013;252(1):52–77.
67. Yoshimura T, Sonoda KH, Ohguro N, et al. Involvement of Th17 cells and the effect of anti-IL-6 therapy in autoimmune uveitis. *Rheumatology (Oxford)*. 2009;48(4):347–354.
68. Muselier A, Bielefeld P, Bidot S, Vinit J, Besancenot JF, Bron A. Efficacy of tocilizumab in two patients with anti-TNF- $\alpha$  refractory uveitis. *Ocul Immunol Inflamm*. 2011;19(5):382–383.
69. Raveney BJ, Copland DA, Nicholson LB, Dick AD. Fingolimod (FTY720) as an acute rescue therapy for intraocular inflammatory disease. *Arch Ophthalmol*. 2008;126(10):1390–1395.
70. Goodin DS, Cohen BA, O'Connor P, Kappos L, Stevens JC; Therapeutics and Technology Assessment Subcommittee of the American Academy of Neurology. Assessment: the use of natalizumab (Tysabri) for the treatment of multiple sclerosis (an evidence-based review): report of the Therapeutics and Technology Assessment Subcommittee of the American Academy of Neurology. *Neurology*. 2008;71(10):766–773.
71. Saadoun D, Bodaghi B, Bienvenu B, et al. Biotherapies in inflammatory ocular disorders: Interferons, immunoglobulins, monoclonal antibodies. *Autoimmun Rev*. 2013;12(7):774–783.
72. Cassoux N, Goichot-Bonnat L, Karmochkine M, et al. [Efficacy of intravenous immunoglobulin in the treatment of Birdshot retinochoroiditis]. *J Fr Ophtalmol*. 2002;25(1):23–30. French.
73. Yang DS, Taylor SR, Lightman SL. Interferon- $\alpha$  in the management of patients with Behcet's disease. *Br J Hosp Med (Lond)*. Oct 2008; 69(10):575–579.
74. Bodaghi B, Gendron G, Wechsler B, et al. Efficacy of interferon alpha in the treatment of refractory and sight threatening uveitis: a retrospective monocentric study of 45 patients. *Br J Ophthalmol*. 2007;91(3):335–339.
75. Tempest-Roe S, Joshi L, Dick AD, Taylor SR. Local therapies for inflammatory eye disease in translation: past, present and future. *BMC Ophthalmol*. 2013;13(1):39.
76. Roesel M, Gutfleisch M, Heinz C, Heimes B, Zurek-Imhoff B, Heiligenhaus A. Orbital floor triamcinolone acetonide injections for the management of active non-infectious uveitis. *Eye (Lond)*. 2009;23(4):910–914.
77. Byun YS, Park YH. Complications and safety profile of posterior sub-tenon injection of triamcinolone acetonide. *J Ocul Pharmacol Ther*. 2009;25(2):159–162.
78. Roesel M, Gutfleisch M, Heinz C, Heimes B, Zurek-Imhoff B, Heiligenhaus A. Intravitreal and orbital floor triamcinolone acetonide injections in noninfectious uveitis: a comparative study. *Ophthalmic Res*. 2009;42(2):81–86.
79. Kok H, Lau C, Maycock N, McCluskey P, Lightman S. Outcome of intravitreal triamcinolone in uveitis. *Ophthalmology*. 2005;112(11):1916.e1–e7.



80. Sallam A, Taylor SR, Habot-Wilner Z, et al. Repeat intravitreal triamcinolone acetonide injections in uveitic macular oedema. *Acta Ophthalmol.* 2012;90(4):e323–e325.
81. da Silva GR, da Silva Cunha A Jr, Ayres E, Oréfice RL. Effect of the macromolecular architecture of biodegradable polyurethanes on the controlled delivery of ocular drugs. *J Mater Sci Mater Med.* 2009;20(2):481–487.
82. Lowder C, Belfort R Jr, Lightman S, et al; Ozurdex HURON Study Group. Dexamethasone intravitreal implant for noninfectious intermediate or posterior uveitis. *Arch Ophthalmol.* 2011;129(5):545–553.
83. Taylor SR, Tomkins-Netzer O, Joshi L, Morarji J, McLoone E, Lightman S. Dexamethasone implant in pediatric uveitis. *Ophthalmology.* 2012;119(11):2412–2412. e2.
84. Driot JY, Novack GD, Rittenhouse KD, Milazzo C, Pearson PA. Ocular pharmacokinetics of fluocinolone acetonide after Retisert intravitreal implantation in rabbits over a 1-year period. *J Ocul Pharmacol Ther.* 2004;20(3):269–275.
85. Mruthyunjaya P, Khalatbari D, Yang P, et al. Efficacy of low-release-rate fluocinolone acetonide intravitreal implants to treat experimental uveitis. *Arch Ophthalmol.* 2006;124(7):1012–1018.
86. Burkholder BM, Wang J, Dunn JP, Nguyen QD, Thorne JE. Postoperative outcomes after fluocinolone acetonide implant surgery in patients with birdshot chorioretinitis and other types of posterior and panuveitis. *Retina.* 2013;33(8):1684–1693.
87. Jaffe GJ, Martin D, Callanan D, Pearson PA, Levy B, Comstock T. Fluocinolone acetonide implant (Retisert) for noninfectious posterior uveitis: thirty-four-week results of a multicenter randomized clinical study. *Ophthalmology.* 2006;113(6):1020–1027.
88. Kane FE, Burdan J, Cutino A, Green KE. Iluvien: a new sustained delivery technology for posterior eye disease. *Expert Opin Drug Deliv.* 2008;5(9):1039–1046.
89. Barnett PJ. Mathematical modeling of triamcinolone acetonide drug release from the I-vation intravitreal implant (a controlled release platform). *Conf Proc IEEE Eng Med Biol Soc.* 2009;2009:3087–3090.
90. Hardwig PW, Pulido JS, Erie JC, Baratz KH, Buettner H. Intraocular methotrexate in ocular diseases other than primary central nervous system lymphoma. *Am J Ophthalmol.* 2006;142(5):883–885.
91. Taylor SR, Habot-Wilner Z, Pacheco P, Lightman SL. Intraocular methotrexate in the treatment of uveitis and uveitic cystoid macular edema. *Ophthalmology.* 2009;116(4):797–801.
92. Taylor SR, Habot-Wilner Z, Pacheco P, Lightman S. Intravitreal methotrexate in uveitis. *Ophthalmology.* 2012;119(4):878–879.
93. Taylor SR, Banker AJ, Schlaen A, Joshi L, McCluskey P, Lightman S. Intravitreal methotrexate can induce long-term remission in some patients with non-infectious uveitis. *Retina.* 2013;33(10):2149–2154.
94. Cordero Coma M, Sobrin L, Onal S, Christen W, Foster CS. Intravitreal bevacizumab for treatment of uveitic macular edema. *Ophthalmology.* 2007;114(8):1574–1579. e1571.
95. Mackensen F, Heinz C, Becker MD, Heiligenhaus A. Intravitreal bevacizumab (avastin) as a treatment for refractory macular edema in patients with uveitis: a pilot study. *Retina.* 2008;28(1):41–45.
96. Weiss K, Steinbrugger I, Weger M, et al. Intravitreal VEGF levels in uveitis patients and treatment of uveitic macular oedema with intravitreal bevacizumab. *Eye (Lond).* 2009;23(9):1812–1818.
97. Acharya NR, Hong KC, Lee SM. Ranibizumab for refractory uveitis-related macular edema. *Am J Ophthalmol.* 2009;148(2):303–309. e302.
98. Farvardin M, Afarid M, Mehryar M, Hosseini H. Intravitreal infliximab for the treatment of sight-threatening chronic noninfectious uveitis. *Retina.* 2010;30(9):1530–1535.
99. Pulido JS, Pulido JE, Michet CJ, Vile RG. More questions than answers: a call for a moratorium on the use of intravitreal infliximab outside of a well-designed trial. *Retina.* 2010;30(1):1–5.
100. Tsilimbaris M, Diakonis VF, Naoumidi I, et al. Evaluation of potential retinal toxicity of adalimumab (Humira). *Graefes Arch Clin Exp Ophthalmol.* 2009;247(8):1119–1125.
101. Androudi S, Tsironi E, Kalogeropoulos C, Theodoridou A, Brazitikos P. Intravitreal adalimumab for refractory uveitis-related macular edema. *Ophthalmology.* 2010;117(8):1612–1616.
102. Furrer E, Berdugo M, Stella C, et al. Pharmacokinetics and posterior segment biodistribution of ESBA105, an anti-TNF-alpha single-chain antibody, upon topical administration to the rabbit eye. *Invest Ophthalmol Vis Sci.* 2009;50(2):771–778.
103. Sehgal SN. Rapamune (RAPA, rapamycin, sirolimus): mechanism of action immunosuppressive effect results from blockade of signal transduction and inhibition of cell cycle progression. *Clin Biochem.* 1998;31(5):335–340.
104. Nguyen QD, Ibrahim MA, Watters A, et al. Ocular tolerability and efficacy of intravitreal and subconjunctival injections of sirolimus in patients with non-infectious uveitis: primary 6-month results of the SAVE Study. *J Ophthalmic Inflamm Infect.* 2013;3(1):32.
105. Willermain F, Rosenbaum JT, Bodaghi B, et al. Interplay between innate and adaptive immunity in the development of non-infectious uveitis. *Prog Retin Eye Res.* 2012;31(2):182–194.
106. Schroder K, Zhou R, Tschopp J. The NLRP3 inflammasome: a sensor for metabolic danger? *Science.* 2010;327(5963):296–300.
107. Yu JR, Leslie KS. Cryopyrin-associated periodic syndrome: an update on diagnosis and treatment response. *Curr Allergy Asthma Rep.* 2011;11(1):12–20.
108. Ahmed Z, Kalinski H, Berry M, et al. Ocular neuroprotection by siRNA targeting caspase-2. *Cell Death Dis.* 2011;2:e173.
109. Dick AD. Road to fulfilment: taming the immune response to restore vision. *Ophthalmic Res.* 2012;48(1):43–49.

## Clinical Ophthalmology

### Publish your work in this journal

Clinical Ophthalmology is an international, peer-reviewed journal covering all subspecialties within ophthalmology. Key topics include: Optometry; Visual science; Pharmacology and drug therapy in eye diseases; Basic Sciences; Primary and Secondary eye care; Patient Safety and Quality of Care Improvements. This journal is indexed on

Submit your manuscript here: <http://www.dovepress.com/clinical-ophthalmology-journal>

Dovepress

PubMed Central and CAS, and is the official journal of The Society of Clinical Ophthalmology (SCO). The manuscript management system is completely online and includes a very quick and fair peer-review system, which is all easy to use. Visit <http://www.dovepress.com/testimonials.php> to read real quotes from published authors.