

Comparative diagnostic study of biomarkers using FibroMax™ and pathology for prediction of liver steatosis in patients with chronic hepatitis C virus infection: an Egyptian study

Ahmad Fouad^{1,*}

Dina Sabry²

Rasha Ahmed^{1,*}

Manal Kamal^{3,*}

Sayed Abd Allah^{4,*}

Samar Marzouk^{2,*}

Mona Amin^{4,*}

Rokaya Abd El Aziz^{4,*}

Ahmad El Badri⁴

Hany Khattab^{5,*}

Dina Helmy^{5,*}

¹Endemic Medicine Department,

²Medical Biochemistry and Molecular Biology Department, ³Clinical and Chemical Pathology Department,

⁴Internal Medicine Department,

⁵Pathology Department, Faculty of Medicine, Cairo University, Egypt

*These authors contributed equally to this work

Background: Steatosis is common in patients with hepatitis C virus (HCV) infection and may be a major determinant of progression of liver injury. This study evaluated FibroMax™ for noninvasive diagnosis of steatosis in patients with chronic HCV.

Methods: This cross-sectional study included 44 patients naïve to treatment who were referred to our hepatology clinic for assessment of fitness for antiviral therapy. Chronic HCV infection was diagnosed by viral markers. Investigations included assessment of abdominal ultrasonography, liver biopsy, calculation of body mass index, and biomarker parameters in serum using FibroMax.

Results: Histopathology of liver biopsies showed steatosis in 30 of 44 (68%) patients. FibroMax results were positively correlated with viral load by quantitative polymerase chain reaction and histopathological findings. Body mass index was significantly higher in steatotic patients ($P = 0.003$) and was significantly associated with the results on FibroMax ($P = 0.005$).

Conclusion: FibroMax was correlated with histopathology and body mass index in patients with HCV. Abdominal ultrasonography could not be used as a single tool to diagnose steatosis with HCV. Steatosis is correlated with viral load, which suggests a direct viral effect. We recommend FibroMax assessment in a larger number of patients to assess its applicability in patients with HCV and steatosis.

Keywords: steatosis, hepatitis C virus, histopathology, FibroMax™

Introduction

Hepatic steatosis has a high prevalence worldwide, and has been found to be associated with several features, including diabetes, hyperlipidemia, obesity, insulin resistance, and viral hepatitis.¹ Egypt has the largest epidemic of hepatitis C virus (HCV) in the world. The overall prevalence of people positive for antibodies to HCV in Egypt has been reported to be 14.7%.²

Steatosis is a frequent feature of HCV infection, and may be an important cofactor in both accelerating fibrosis and increasing liver necroinflammatory activity in chronic HCV infection. Several studies have suggested that steatosis induces resistance to combination treatment with interferon and ribavirin.³

One of the major clinical problems is how to evaluate steatosis in patients with HCV. Liver biopsy is still recommended by the current guidelines for management of the disorder.⁴ However, numerous studies have strongly suggested that liver biopsy has limitations, such as potential sampling error, the fact that it is invasive, costly,

Correspondence: Dina Sabry
Medical Biochemistry and Molecular
Biology Department, Faculty of
Medicine, Cairo University, Al Kasr
Al Aini Hospital, Al Kasr Al Aini
Street, Giza, Egypt
Tel +20 11 1120 0200
Fax +1 202 2363 2297
Email dinnasabry69@yahoo.com

and prone to potential complications, and the reluctance of patients to undergo an invasive procedure.⁵ Moreover, marked improvement has been achieved in the diagnostic accuracy of biochemical markers of fibrosis. Thus, liver biopsy should no longer be considered mandatory.⁶

Ultrasonography can be used for initial assessment of hepatic steatosis, because it has a number of advantages over other imaging methods, ie, low cost, safety, lack of need for intravenous contrast, wide availability, and widespread acceptance by patients.⁷ Hyperechogenicity is observed on ultrasound examination of the liver parenchyma in the presence of hepatic steatosis, and is associated with changes in echo texture, vascular blurring, and deep attenuation. This corresponds to steatotic infiltration greater than 30% in both liver lobes, with a sensitivity of 60%–95% and a specificity of 77%–100%.^{8,9}

Three simple blood tests were developed to provide an estimate of liver fibrosis and its aggravating factors of steatosis and nonalcoholic steatohepatitis, ie, the FibroTest™, SteatoTest™, and NashTest™, respectively. FibroMax™ (Biopredictive, Paris, France) combines these three tests on the same result sheet and provides physicians with simultaneous and complete estimation of the liver injury associated with nonalcoholic fatty liver disease.¹⁰ The aim of this study was to evaluate the group of noninvasive biomarkers known as FibroMax in the diagnosis of steatosis in patients with chronic HCV.

Materials and methods

Baseline demographic and clinical characteristics

This cross-sectional study was performed during the period from January to September 2011. It was approved by our institutional ethics review board for human studies, and patients signed their informed consent. We included 44 consecutive patients who were referred to the hepatology clinic at Cairo University for assessment of their fitness for antiviral therapy, and who had not received antiviral treatment for their disease before this test. All patients were middle-aged Egyptian Arabs, predominantly males, with HCV genotype 4, and a histological diagnosis of chronic HCV infection. Body mass index was calculated as weight (kg)/height (m²). Patients with poorly controlled diabetes mellitus, morbid obesity, and/or hypertension were excluded.

Liver histopathology

Percutaneous liver biopsies were available. Cores of at least 1–1.5 cm in length or encompassing a minimum of three

portal areas were considered suitable for interpretation. The pathologist was unaware of the corresponding clinical and biochemical data. The Metavir scoring system was used for assessment of necroinflammatory activity (Figure 1) and fibrosis stage (Table 1). Steatosis was graded based on the proportion of hepatocytes involved, ie, mild (<33%), moderate (33%–66%), and severe (>66%).^{11,12}

Abdominal ultrasound

Ultrasonographic examination was performed for all patients using commercially available equipment (Toshiba, Sequoia, Mountain View, CA, USA) with either a 4 mHz (n = 41) or an 8 mHz (n = 5) vector transducer. Multiple transverse and longitudinal gray-scale images of the abdomen were taken. Two independent sonologists with at least 15 years of abdominal ultrasound experience performed the sonogram and were unaware of the clinical features and pathological findings. The overall assessment of liver echogenicity was based on a combination of the echogenicity of the right renal cortex, beam attenuation with standard settings, visualization of the echogenicity of the walls surrounding the intrahepatic vessels, and the degree of reflectivity from the diaphragm. Normal liver echotexture was recorded in the absence of steatosis. Minimal steatosis was indicated by slightly increased liver echogenicity in relation to the right kidney, but echogenicity of the intrahepatic vessel walls and diaphragm was well visualized. Mild steatosis was defined by liver echogenicity moderately greater than that of the right kidney

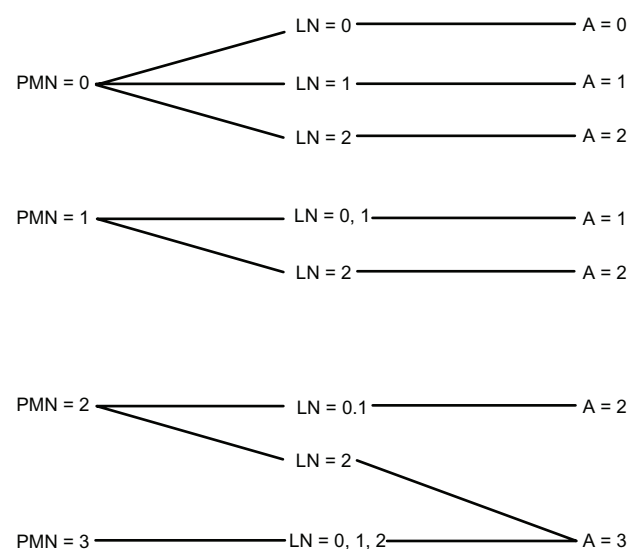


Figure 1 Metavir algorithm¹¹ for evaluation of histological activity.

Notes: PMN = 0, none; 1, mild; 2, moderate; 3, severe. LN = 0, no or mild; 1, moderate; 2, severe. A = 0, none; 1, mild; 2, moderate; 3, severe.

Abbreviations: A, histological activity score; LN, lobular necrosis; PMN, piecemeal necrosis.

Table 1 Metavir classification for staging of hepatitis C liver disease^{11,12}

No scarring	0
Minimal scarring	1
Scarring has occurred and extends outside areas in the liver containing blood vessels	2
Bridging fibrosis is spreading and connecting to other areas that contain fibrosis	3
Cirrhosis or advanced scarring of the liver	4

with slight decreased visibility of the intrahepatic vessel walls and decreased reflectivity of the hemidiaphragm. Moderate steatosis was defined by liver echogenicity moderately greater than that in the right kidney with poor visualization of the intrahepatic vessel walls and decreased reflectivity of the hemidiaphragm. Severe steatosis was determined by significantly increased echogenicity of the liver compared with that of the right kidney, lack of visualization of the intrahepatic vessel walls, and markedly decreased reflectivity of the hemidiaphragm. The liver was scored on the basis of the most affected area.

FibroMax scoring

Fasting blood samples were collected from all patients. The separated sera were stored at 2°C–8°C for a maximum of 4 days, then assayed for ten serum biomarkers included in the FibroMax score, which include the six components of the FibroTest-ActiTest (α 2-macroglobulin, apolipoprotein A1, haptoglobin, gamma glutamyltranspeptidase, total bilirubin, and alanine transaminase). In addition, aspartate transaminase, fasting glucose, total cholesterol, and triglycerides were measured. The results were adjusted for gender, age, weight, and height to calculate the FibroMax score. Measurements were performed using validated methods, and α 2-macroglobulin, apolipoprotein A1, and haptoglobin were measured using the BN Prospec autoanalyzer (Dade Behring Marburg GmbH, Marburg, Germany). The remaining parameters were assayed on a Hitachi 917 autoanalyzer (Roche Diagnostics GmbH, Mannheim, Germany).^{11–13}

Results of the measured components were introduced into the Biopredictive network, and the algorithms were computed. The results were used as input for the FibroTest-ActiTest. This is a patented artificial intelligence algorithm that generates a measure of liver fibrosis, and provides a numeric quantitative estimate of liver fibrosis ranging from 0.00 to 1.00. It is a continuous linear biochemical assessment of fibrosis stage, which corresponds with stages F0–4 of the Metavir scoring system and activity stages as grades A0–3 corresponding to the section of the Metavir scoring system

assessing viral necroinflammatory activity. The SteatoTest is a measure of the steatosis grade in hepatocytes in the range of S0–3 (Table 2).^{13–15}

RNA extraction

Centrifugation of blood samples for serum collection and storage at –20°C or –80°C was recommended until use. RNA extraction from the stored frozen samples was done using the QIAamp viral RNA Mini kit (Qiagen, Alameda, CA, USA) according to the manufacturer's instructions.

Primers and probe design

Primer Express software (Applied Biosystems, Foster City, CA, USA) was used to design an amplified 240 bp product of the HCV genome in a fluorescence detector (using FAM® dye). The VIC-labeled probe was detected in a fluorescence detector (using VIC® dye).

Real-time PCR assay

Real-time PCR was performed using the StepOne and the AgPath-ID™ one-step kits (Applied Biosystems) according to the manufacturer's instructions.¹⁶

Interpretation of ActiTest and FibroTest

Values used for interpretation of the ActiTest were A0 (0.00–0.24) = no histological activity; A1 (0.25–0.49) = minimal activity; A2 (0.50–0.60) = moderate activity; and A3 (>0.60) = severe activity. Values used for interpretation of the FibroTest were F0 (0.00–0.21) = no fibrosis; F0–F1 (0.22–0.27); F1 (0.28–0.31) portal fibrosis without septa; F1–F2 (0.32–0.48); F2 (0.49–0.58) = portal fibrosis with septa; F3 (0.59–0.72) = numerous septa; F3–F4 (0.73–0.74); and F4 (\geq 0.75) = cirrhosis.

Statistical analysis

Quantitative analysis was done using the mean \pm standard deviation for parametric data unless otherwise indicated. For nonparametric data, the analysis was performed using the median and 25th–75th percentile. For qualitative data, the analysis was done by frequency and percentage. Data

Table 2 Estimation of steatosis grade and percentage from FibroMax™ (SteatoTest) in hepatocytes with steatosis

SteatoTest	Estimate of steatosis percentage
0.00–0.37	S0, 0%, no steatosis
0.38–0.56	S1, 1%–5%, mild steatosis
0.57–0.68	S2, 6%–32%, moderate steatosis
0.69–1.00	S3, >32%, severe steatosis

from patients with and without steatosis were compared using the Chi-square test or the Student's *t*-test. The correlation was assessed by the Pearson coefficient of correlation. Multiple receiver operating characteristic curves were constructed to get the best area under the curve and the best cutoff for FibroMax to verify those with no steatosis. A *P* value < 0.05 was considered to be statistically significant.

Results

Patient characterization

Patient characteristics and viral load are shown in Table 3. The patients were divided into two groups according to the presence or absence of steatosis based on histopathology and abdominal ultrasound (Table 4). The statistical difference (*P* value) between these two groups is shown. Thirteen (29.5%) patients had diabetes, and all had good blood sugar control at baseline. There was a trend towards a higher viral load in the steatotic group.

Ultrasound and histopathology results

Liver biopsies showed histopathologically different degrees of steatosis (Figure 2). There was a positive significant correlation between percentage of steatosis by the SteatoTest and steatosis percentage by histopathology and by viral load (Figures 3 and 4, respectively). There was a significant correlation between steatosis by pathology and sonography (*P* = 0.005). Four of 14 cases (29%) with steatosis by pathol-

ogy showed no steatosis on sonography and six of 16 (38%) with no steatosis on sonography showed mild to moderate steatosis by pathology. Of the 30 patients with histopathologically proven steatosis, five had a body mass index of <25 and their score on FibroMax was S1–2. The frequency of degrees of steatosis by FibroMax (SteatoTest) in steatotic and nonsteatotic patients according to histopathology and sonography is shown in Table 4 (*P* = 0.016 and *P* = 0.002, respectively).

Effect of steatosis on serum HCV RNA quantitation

The HCV RNA level in patients with steatosis was increased (151,458 IU/mL), but not significantly compared with patients without steatosis (92,945 IU/mL, *P* = 0.08).

Fibromax results

The results of the FibroMax (FibroTest, ActiTest, and SteatoTest) are shown in Table 5. Analysis of the receiver operating characteristic curves showed that FibroMax (SteatoTest) had the highest area under the curve for diagnosis of steatosis (88%, *P* = 0.000). Gamma-glutamyl transferase and alanine transaminase showed lower values (68% and 59%, respectively, see Figure 5). There was a significant association between FibroMax (SteatoTest) levels and body mass index (Table 6). The optimal cutoff of FibroMax (SteatoTest) in predicting steatosis was 0.67, with a sensitivity of 100%

Table 3 Patient characteristics and viral load

	All cases (n = 44)	No steatosis (n = 14)	Steatosis (n = 30)	P value
Men	31 (70.5)	11 (78.6)	20 (66.7)	0.9
Women*	13 (29.5)	3 (21.4)	10 (33.3)	
Age, years	40.4 ± 10.9	38.2 ± 10.2	41.2 ± 11.6	0.39
BMI, kg/m ²	27.2 ± 3.6	24.8 ± 3.4	28.5 ± 3.2	0.003 [†]
ALT, U/L	40.7 ± 15.7	36.1 ± 10.4	42 ± 17.5	0.18
AST, U/L	40.7 ± 13.0	36.6 ± 10.9	42.6 ± 13.9	0.13
Bilirubin total, μmol/L	10.8 ± 4.2	9.5 ± 3.6	11.2 ± 4	0.16
GGT, U/L	40.5 ± 21.3	34.2 ± 22.3	43.6 ± 18.2	0.19
Glucose, mmol/L	5.6 ± 2.6	4.4 ± 0.6	6.1 ± 2.8	0.007 [†]
Triglycerides, mmol/L	1.4 ± 0.6	1.2 ± 0.4	1.4 ± 0.6	0.16
Cholesterol, mmol/L	4.1 ± 0.8	3.7 ± 0.3	4.3 ± 0.9	0.01 [†]
Haptoglobin, g/L	1.9 ± 0.6	1.9 ± 0.7	2 ± 0.6	0.64
Apo A1, g/L	1.7 ± 0.5	1.5 ± 0.3	1.8 ± 0.5	0.016 [†]
Alpha2-macroglobulin, g/L	2.5 ± 0.6	2.2 ± 0.7	2.7 ± 0.5	0.06
qPCR** (IU/mL)	140279.5 (18521.75–676026.5)	92945 (29237–492979.5)	151458 (19041–732108.5)	0.08

Notes: Data are represented as the mean ± standard deviation unless otherwise indicated. *Frequency (%); **median (25th–75th percentile). [†]*P* < 0.05 is considered statistically significant between steatotic and nonsteatotic patients.

Abbreviations: Apo, apolipoprotein; ALT, alanine transaminase; AST, aspartate transaminase; BMI, body mass index; GGT, gamma-glutamyl transferase; qPCR, quantitative polymerase chain reaction.

Table 4 Steatosis grade by SteatoTest™ in steatotic and nonsteatotic patients

	Steatosis grade (SteatoTest)			
	S0 (n = 1)	S1 (n = 20)	S2 (n = 12)	S3–S4 (n = 11)
Steatosis*				
0 (n = 14)	1 (100)	12 (60)	1 (8.3)	0
Mild (n = 25)	0	7 (35)	9 (75)	9 (81.8)
Moderate (n = 4)	0	1 (5)	2 (16.7)	1 (9.1)
Severe (n = 1)	0	0	0	1 (9.1)
Steatosis**				
Normal (n = 16)	0	13 (65)	3 (25)	0
Steatosis (n = 28)	1 (100)	7 (35)	9 (75)	11 (100)

Notes: *Defined by histopathology; **defined by sonography.

and a specificity of 94%. For the diagnosis of moderate and severe steatosis, the sensitivity of the SteatoTest was 100% at the cutoff of 0.38, and the specificity at the 0.71 cutoff was 99.8%.

Correlation between histopathology and Fibromax

The stages of fibrosis and activity score proven by histopathology were significantly associated with the ActiTest and

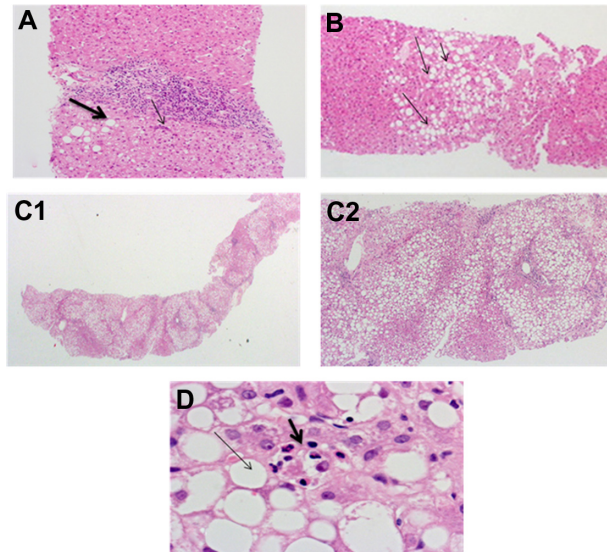


Figure 2 Steatosis assessment in liver histopathology. (A) Liver case with a Metavir activity score I, showing focal interface activity (thin arrow) and mild macrovesicular steatosis (thick arrow). Note the moderate portal tract chronic inflammatory infiltrate (hematoxylin and eosin stain, 200×). (B) Moderate macrovesicular steatosis (arrows) involving about half of the hepatocytes in this section (hematoxylin and eosin, 100×). (C) Marked diffuse macrovesicular steatosis involving most of the hepatocytes in a case having a Metavir activity score of I and a fibrosis stage of I [hematoxylin and eosin stain, 40 × (C1), and 200× (C2)]. (D) High power view of macrovesicular steatosis showing large fat globules inside hepatocytes pushing the nucleus to one side. Note also the focus of lobular necroinflammation (thick arrow) with evident polymorphs denoting steatohepatitis (hematoxylin and eosin stain, 400×).

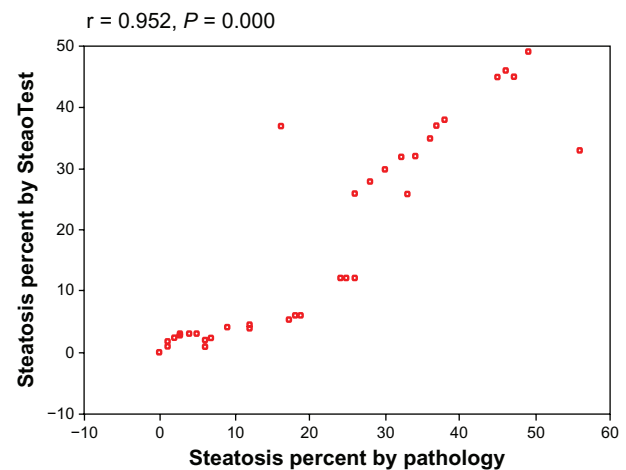


Figure 3 Significant positive correlation between percentage of steatosis by SteatoTest and by pathology.

FibroTest results ($P = 0.000$). There was a significant association between the SteatoTest and FibroTest ($P = 0.012$), but there was no association between the SteatoTest and ActiTest ($P = 0.09$). The frequency of activity and fibrosis stages in relation to the grade of steatosis by FibroMax ($P = 0.06$ and $P = 0.03$, respectively) is shown in Table 7. Table 8 reveals a significant association between different degrees of fibrosis by the FibroTest and steatosis by biopsy ($P < 0.001$).

Discussion

Both nonalcoholic fatty liver disease and HCV infection are common in Egypt, and their coexistence initiates a vicious circle, ie, they interact with each other.¹⁷ Hepatic steatosis is common in patients with the HCV genotype 4 and has been related to disease progression and suggested as a predictor of response to treatment in chronic HCV.¹⁸ Hepatic steatosis has been described in 31%–72% of chronic HCV liver biopsies.^{19,20} Similarly, in our study, we found steatosis (by liver biopsy) in 68% of our patients infected with HCV. We also found that body mass index was significantly higher in the group with steatosis than in the group without steatosis by histopathology. These findings are inconsistent with the finding of other studies in our country.^{21–23} Due to the increased incidence of HCV, limitations of biopsy, and development of reliable noninvasive blood tests, liver biopsy should no longer be considered mandatory for screening of liver lesions in the first instance.

In this study, FibroMax was tested as a noninvasive tool in the diagnosis of steatosis. The values of the SteatoTest by FibroMax were significantly higher in patients with steatosis and there was a significant association between the grade of steatosis by SteatoTest and both biopsy and sonographic imaging. Body mass index was a good predictor of steatosis

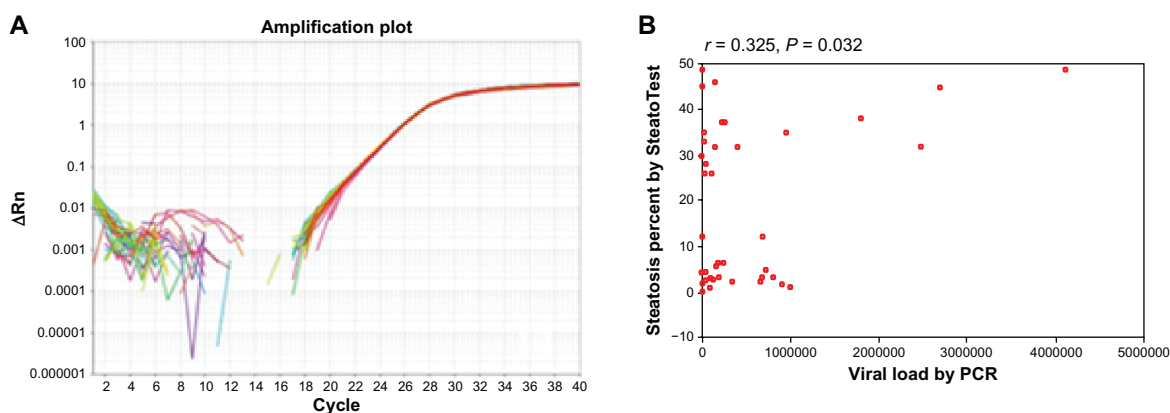


Figure 4 Shows the quantitative HCV PCR and its correlation with liver steatosis (A) Fluorescence (Rn) is plotted versus PCR cycle number for reaction and each sample is indicated. Quantitative real-time PCR curves measuring HCV-RNA concentration through the standard curve (IU/mL). (B) Correlation between percentage of steatosis by SteatoTest and viral load by quantitative PCR.

Abbreviations: HCV, hepatitis C virus; PCR, polymerase chain reaction.

in our study, in which there was a significant positive association between body mass index and SteatoTest by FibroMax. Of the 30 patients with steatosis by histopathology, five (16%) had a body mass index < 25 and their liver biopsies showed mild steatosis. In these patients, the FibroMax showed S1, denoting high specificity and sensitivity. It also denotes a good positive predictive value and suggests that it can detect steatosis in patients with normal body mass index. The importance of higher body mass index with steatosis was evidenced by its improvement, which was significantly associated with degree of weight loss as reported by Esmat et al, who suggested that steatosis may be related to obesity.²¹

Table 5 Results of FibroMax™ test

	All cases (n = 44)	No steatosis (n = 14)	Steatosis (n = 30)	P value
SteatoTest	0.6 ± 0.15	0.46 ± 0.1	0.64 ± 0.1	0.000†
Steatosis percentage*	6 (2.8–32.7)	2.6 (1.9–2.8)	28 (5.6–36.5)	0.000†
Steatosis grade**				
S0, no	1–2.3	1–7.1	0–0	0.004†
S1, mild	20–45.4	11–78.6	9–30	
S2, moderate	12–27.3	2–14.3	10–33.3	
S3–S4, severe	11–25	0–0	11–36.7	
FibroTest**				
F0	4–9	4–28.6	0–0	0.006†
F1	28–63.6	10–71.4	18–60	
F2	2–4.6	0–0	2–6.6	
F3	5–11.4	0–0	5–16.7	
F4	5–11.4	0–0	5–16.7	
ActiTest**				
A1	29–65.9	14–100	15–50	0.005†
A2	8–18.2	0–0	8–26.7	
A3	7–15.9	0–0	7–23.3	

Notes: Data are shown as the mean ± standard deviation unless otherwise indicated. **Frequency (%); *median (25th to 75th percentile). †P < 0.05, statistically significant between steatotic and nonsteatotic patients.

The optimal cutoff using the receiver operating characteristic curves for the SteatoTest in diagnosing steatosis was 0.67, for which the sensitivity was 100% and the specificity was 99%. Fibromax showed the highest area under the curve when compared with the parameter used in other studies for the prediction of steatosis. FibroMax showed a high positive predictive value, but the negative predictive value was only 48.3%, which indicates that the test was not able to diagnose the absence of steatosis accurately.

It has been assumed by other authors that viral load may be involved in the pathogenesis of steatosis in HCV-infected patients.²¹ accordingly, in our study, there was

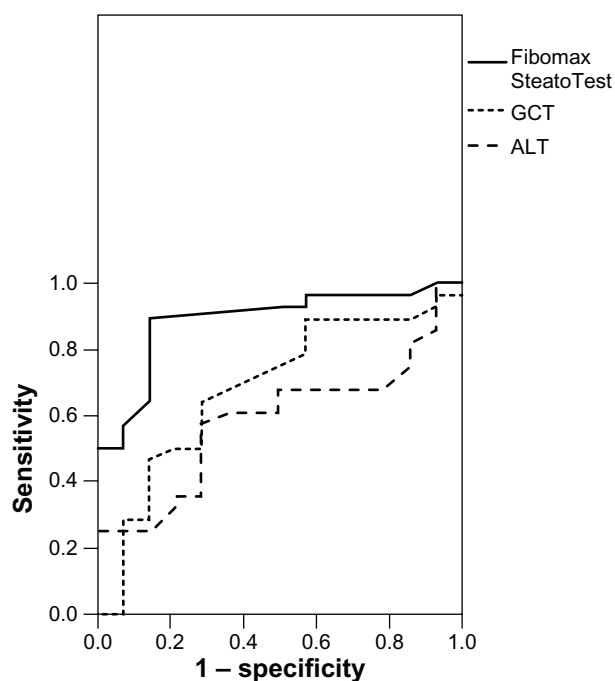


Figure 5 Multiple receiver operating characteristic curves to discriminate between steatosis and nonsteatosis.

Abbreviations: ALT, alanine transaminase; GCT, gamma-glutamyl transferase.

Table 6 FibroMax™ (SteatoTest) in obese and nonobese patients

BMI, kg/m ²	FibroMax (SteatoTest)		P value
	Mean	SD	
<25 (n = 13)	0.49	0.14	0.005
≥25 (n = 31)	0.62	0.13	

Abbreviations: BMI, body mass index; SD, standard deviation.

a trend towards higher viral load in patients with steatosis as detected by liver biopsy, and there was a significant positive correlation between viral load and steatosis by FibroMax.

Although cholesterol levels were significantly higher in the group with steatosis, all our patients had a normal lipid profile. Other researchers have reported that there is a direct effect of HCV on the pathogenesis on lipid accumulation in genotype 3, and that probably the interaction of HCV core protein with the lipoprotein secretion pathway causes the characteristic alterations in lipid metabolism observed in HCV-related steatosis.^{24,25} The difference in our results may be attributed to the HCV genotype in the Egyptian population. From this, we surmise that steatosis is independent of hyperlipidemia in chronic active HCV infection.

Fibrosis is the most important end point because it is directly related to mortality. A higher prevalence of advanced fibrosis has been observed in patients with steatosis (6%),²⁶ and several studies have reported an association between fibrosis and steatosis in patients with chronic HCV infection,^{27,28} while some studies have failed to find such an association.^{29–31} Accordingly, in our study, we found a significant association between the Fibrotest and steatosis by histopathology and a significant association between steatosis and the FibroTest by FibroMax. However, there was no association between the SteatoTest

Table 7 Degrees of frequency of fibrosis and activity in relation to steatosis grade by FibroMax™

	Steatosis grade (FibroMax)			
	S0 (n = 1)	S1 (n = 20)	S2 (n = 12)	S3–S4 (n = 11)
Activity stage				
A1	1	18	6	4
A2	0	1	4	3
A3	0	1	2	4
Fibrosis stage*				
F0 (no fibrosis)	0	6	1	0
F1–F2 (mild to moderate)	1	13	6	6
F3–F4 (severe to advanced)	0	1	6	4

Note: *According to Metavir scoring system.

Table 8 Frequency of fibrosis in relation to steatosis by pathology

	Steatosis*		
	No (n = 14)	Mild-moderate (n = 29)	Severe (n = 1)
Fibrosis**			
No, F0	1 (7.1)	3 (10.3)	0
Mild-moderate, F1–2	12 (85.8)	21 (72.4)	1 (100)
Severe-advanced, F3–4	1 (7.1)	5 (17.3)	0

Notes: Data are presented as no (%); *histopathology; **FibroTest.

and the Actitest. This supports the hypothesis that steatosis has a profound effect on the degree of fibrosis in chronic HCV, but has no influence on the degree of inflammatory activity.

FibroMax has several advantages over other diagnostic tools, including being cheaper than biopsy or magnetic resonance imaging. In addition, many authors have reported that ultrasound is a nonspecific test for the presence and degree of steatosis in patients with chronic HCV, but the imaging findings together with appropriate clinical information may provide the most likely diagnosis.³² This was demonstrated in our study because we found that about 29% of cases of steatosis were missed by sonography and about 38% of the cases were falsely negative on pathology. We recommend that, to improve the treatment outcome, patients be assessed by Fibromax if they have steatosis, encouraged to reduce their weight, and confirm improvement of the liver by another Fibromax, which is not as invasive as liver biopsy.

Conclusion

Our preliminary results show that FibroMax was correlated with histopathology and body mass index in patients with HCV. Abdominal ultrasonography could not be used as a single tool to diagnose steatosis with HCV. We recommend that FibroMax assessment be done in a larger number patient population to assess its applicability in patients with HCV.

Disclosure

The authors report no conflict of interests in this work.

References

- Santos LF, Hernandez G, Puerta AV, Beltran O, Botero RC, Mejia G. Non alcoholic fatty liver disease. The new millennium Pandemia. *Rev Col Gastroenterol*. 2010;25:373–391.
- El-Zanaty F, Way A. Egypt Demographic and Health Survey 2008. Cairo, Egypt: Ministry of Health; 2009. Available from: <http://www.measuredhs.com/pubs/pdf/FR220/FR220.pdf>. Accessed December 12, 2012.
- Szanto P, Grigorescu M, Dumitru I, Serban A. Steatosis in hepatitis C virus infection. Response to anti-viral therapy. *J Gastrointest Liver Dis*. 2006;15:117–124.

4. Crax A, Pawlotsky JM, Wedemeyer H, et al. EASL clinical practice guidelines: management of hepatitis C virus infection. *J Hepatol*. 2011;55:245–264.
5. Chiano TD, Azeem S, Bodian CA, et al. Importance of specimen size in accurate needle liver biopsy evaluation of patients with chronic hepatitis C. *Clin Gastroenterol Hepatol*. 2005;3:930–935.
6. Castéra L, Vergniol J, Foucher J, et al. Prospective comparison of transient elastography, Fibrotest, APRI, and liver biopsy for the assessment of fibrosis in chronic hepatitis C. *Gastroenterology*. 2005;128:343–345.
7. Saadeh S, Younossi ZM, Remer EM, et al. The utility of radiological imaging in nonalcoholic fatty liver disease. *Gastroenterology*. 2002;123:745–750.
8. Narciso-Schiavon JL, Schiavon Lde L, Carvalho-Filho RJ, et al. Clinical characteristics associated with hepatic steatosis on ultrasonography in patients with elevated alanine aminotransferase. *Sao Paulo Med J*. 2010;128:342–347.
9. Charatcharoenwitthaya P, Lindor KD. Role of radiologic modalities in the management of non-alcoholic steatohepatitis. *Clin Liver Dis*. 2007;11:37–54.
10. Poynard T, Ratziu V, Naveau S, et al. The diagnostic value of biomarkers (SteatoTest) for the prediction of liver steatosis. *Comp Hepatol*. 2005;1:187–191.
11. [No authors listed]. Inter- and intra-observer variation in the assessment of liver biopsy of chronic hepatitis C. The French METAVIR Cooperative Study Group. *Hepatology*. 1994;20:15–20.
12. Chalasani N, Wilson L, Kleiner DE, Cummings OW, Brunt EM, Unalp A; NASH Clinical Research Network. Relationship of steatosis grade and zonal location to histological features of steatohepatitis in adult patients with non-alcoholic fatty liver disease. *J Hepatol*. 2008;48:829–834.
13. Colletta C, Smirne C, Fabris C, et al. Value of two noninvasive methods to detect progression of fibrosis among HCV carriers with normal aminotransferases. *Hepatology*. 2005;42:838–845.
14. Blanc JF, Bioulac-Sage P, Balabaud C, Desmouliere A. Investigation of liver fibrosis in clinical practice. *Hepatol Res*. 2005;27:1–8.
15. Morra R, Munteanu M, Imbert-Bismut F, Messous D, Ratziu V, Poynard T. FibroMax: towards a new universal biomarker of liver disease? *Expert Rev Mol Diagn*. 2007;7:481–490.
16. Radonić A, Thulke S, Mackay IM, Landt O, Siegert W, Nitsche A. Guideline to reference gene selection for quantitative real-time PCR. *Biochem Biophys Res Commun*. 2004;313:856–862.
17. Rafiq N, Younossi ZM. Interaction of metabolic syndrome, nonalcoholic fatty liver disease and chronic hepatitis C. *Expert Rev Gastroenterol Hepatol*. 2008;2:207–215.
18. Khattab MA, Abdel-Fattah ME, Eslam M, et al. Hepatic steatosis in genotype 4 chronic hepatitis C patients: implication for therapy. *J Clin Gastroenterol*. 2010;44:707–712.
19. Rubbia-Brandt L, Quadri R, Abid K, et al. Hepatocyte steatosis is a cytopathic effect of hepatitis C virus genotype 3. *J Hepatol*. 2000;33:106–115.
20. Gordon A, McLean CA, Pedersen JS, Bailey MJ, Roberts SK. Hepatic steatosis in chronic hepatitis B and C: predictors, distribution and effect on fibrosis. *J Hepatol*. 2005;43:38–44.
21. Esmat G, El Akel W, Metwally M, et al. Improvement of steatosis after interferon therapy in HCV genotype 4 is related to weight loss. *Indian J Gastroenterol*. 2009;28:45–48.
22. Ahmed AM, Hassan MS, Abd-Elseyed A, Hassan H, Hasanain AF, Helmy A. Insulin resistance, steatosis, and fibrosis in Egyptian patients with chronic hepatitis C virus infection. *Saudi J Gastroenterol*. 2011;17:245–251.
23. El-Zayadi AR, Attia M, Barakat EMF, et al. Hepatic steatosis in hepatitis C genotype 4 infected patients. *Arab J Gastroenterol*. 2007;8:104–108.
24. Patel JH, Cobbald JFL, Thomas HC, Taylor-Robinson SD. Hepatitis C and hepatic steatosis. *QJM*. 2010;103:293–303.
25. Shiha G, Seif S, Zalata K. Hepatic steatosis in chronic hepatitis C virus infection genotype 4: prevalence and clinical correlations. *Liver Int*. 2006;26:80.
26. Wyatt J, Baker H, Prasad P, Gong YY, Millson C. Steatosis and fibrosis in patients with chronic hepatitis C. *J Clin Pathol*. 2004;57:402–406.
27. Ratziu V, Saboury M, Poynard T. Worsening of steatosis and fibrosis progression. *Gut*. 2003;52:1386–1387.
28. Fartoux L, Poujol-Robert A, Guechot J, Wendum D, Poupon R, Serfaty L. Insulin resistance is a cause of steatosis and fibrosis progression in chronic hepatitis C. *Gut*. 2005;54:1003–1008.
29. Rubbia-Brandt L, Leandro G, Spahr L, et al. Liver steatosis in chronic hepatitis C: a morphological sign suggesting infection with HCV genotype 3. *Histopathology*. 2001;39:119–124.
30. Sharma P, Balan V, Hernandez J, et al. Hepatic steatosis in hepatitis C virus genotype 3 infection: does it correlate with body mass index, fibrosis, and HCV risk factors? *Dig Dis Sci*. 2004;49:25–29.
31. Jármy K, Karácsony G, Nagy A, Schaff Z. Changes in lipid metabolism in chronic hepatitis C. *World J Gastroenterol*. 2005;11:6422–6428.
32. Strickland GT, Elhefni H, Salman T, et al. Role of hepatitis C infection in chronic liver disease in Egypt. *Am J Trop Med Hyg*. 2002;67:436–442.

International Journal of General Medicine

Publish your work in this journal

The International Journal of General Medicine is an international, peer-reviewed open-access journal that focuses on general and internal medicine, pathogenesis, epidemiology, diagnosis, monitoring and treatment protocols. The journal is characterized by the rapid reporting of reviews, original research and clinical studies across all disease areas.

Submit your manuscript here: <http://www.dovepress.com/international-journal-of-general-medicine-journal>

Dovepress

A key focus is the elucidation of disease processes and management protocols resulting in improved outcomes for the patient. The manuscript management system is completely online and includes a very quick and fair peer-review system. Visit <http://www.dovepress.com/testimonials.php> to read real quotes from published authors.