

# Superior subconjunctival anesthesia versus retrobulbar anesthesia for manual small-incision cataract surgery in a residency training program: a randomized controlled trial

Pipat Kongsap

Department of Ophthalmology,  
Prapokklao Hospital, Chanthaburi,  
Thailand; Faculty of Medicine,  
Chulalongkorn University, Bangkok,  
Thailand

**Purpose:** To evaluate the effectiveness of subconjunctival anesthesia as compared to retrobulbar anesthesia for pain control during manual small-incision cataract surgery (MSICS) performed by third-year residents.

**Design:** A randomized, controlled trial.

**Patients and methods:** A total of 150 patients undergoing routine cataract surgery were randomly assigned to receive either subconjunctival anesthesia (group 1,  $n = 75$ ) or retrobulbar anesthesia (group 2,  $n = 75$ ). Third-year residents performed MSICS using the modified Blumenthal technique. Subconjunctival anesthesia was administered by injecting 2% xylocaine with adrenalin into the superior conjunctiva, and retrobulbar anesthesia by injecting 2 mL of 2% xylocaine with adrenalin into the retrobulbar space. We studied the following variables: intraoperative pain score rated on a 100-point visual analog scale (VAS), operative time, and injection and operative complications.

**Results:** A mean age of 69 vs 70 years, an operative time of 47.1 (SD, 9.9) min vs 47.7 (10.9) min, and a median (interquartile range) pain score of 40 (range, 20–70) vs 40 (range, 20–50) were observed in the subconjunctival and the retrobulbar groups, respectively. The injection complication of subconjunctival hemorrhage was significantly higher in the subconjunctival group (25.3%) compared to the retrobulbar group (1.3%). The operative complication rate between groups was not different ( $P > 0.05$ ).

**Conclusion:** Both, superior subconjunctival anesthesia and retrobulbar anesthesia were effective during MSICS when used in a residency training program.

**Keywords:** subconjunctival anesthesia, retrobulbar anesthesia, cataract surgery, small-incision cataract surgery, visual analog scale, pain score

## Introduction

Topical anesthesia is becoming increasingly widely accepted and has become a well-established technique for use in phacoemulsification.<sup>1</sup> A number of previous studies that have evaluated topical versus needle block anesthesia have shown no significant difference in patient satisfaction.<sup>2,3</sup> Unlike phacoemulsification, conjunctival excision has to be performed in manual small-incision cataract surgery (MSICS), which is not well tolerated under topical anesthesia. Several methods of local anesthesia are routinely used in conventional extracapsular cataract extraction (ECCE) or MSICS. Of these, retrobulbar and peribulbar anesthesia are associated with globe perforation, retrobulbar hemorrhage, optic nerve injury, brain-stem anesthesia, and other

Correspondence: Pipat Kongsap  
Department of Ophthalmology,  
Prapokklao Hospital and Medical Center,  
Chanthaburi 22000, Thailand  
Tel +663 932 4975  
ext 1450; or +668 1863 2668  
Fax +663 932 4861  
Email pkongsap@gmail.com

serious complications.<sup>4-6</sup> Superior subconjunctival anesthesia produces adequate analgesia, but not adequate akinesia. Its use has been reported in conventional extracapsular cataract surgery to avoid serious complications associated with other methods of anesthesia.<sup>7</sup> We propose that MSICS can be performed under subconjunctival anesthesia. However, there are no reports of its use in MSICS, especially during residency training. We believe that it may also be effective for pain control in MSICS. We hypothesized that both subconjunctival anesthesia and retrobulbar block have similar levels of pain control in MSICS, and that subconjunctival anesthesia may have a lower pain score during injection than a retrobulbar block.

To verify the effectiveness and safety of subconjunctival anesthesia in a residency training program, we conducted a clinical trial and compared pain control during MSICS with intraocular lens (IOL) implantation achieved by superior subconjunctival anesthesia versus retrobulbar anesthesia.

## Materials and methods

A hospital-based, randomized, controlled clinical trial was conducted at Prapokklao Hospital, Chanthaburi, Thailand. This trial adhered to the tenets of the Declaration of Helsinki, and was approved by the Prapokklao Hospital Ethics Committee for Human Research. Written informed consent was obtained from each subject.

## Participants

Patients with cataracts who visited our center and planned to have cataract surgery performed by third-year residents between January 1, 2011, and December 31, 2011, were recruited. Eligibility criteria included age > 40 years, and a visually significant cataract that was indicated for cataract surgery with IOL implantation. Patients with immature, mature, and intumescent cataracts were included in this study. Patients with uveitis, glaucoma, or previous ocular trauma/surgery, or those who were unable to co-operate and communicate during surgery (due to dementia, hearing impairment, etc) were excluded.

## Study design

Study participants were assigned randomly to receive superior subconjunctival anesthesia (study group) or retrobulbar anesthesia (control group). Stratified blocked randomization was used to reduce the variation in outcome due to chance disproportions in important baseline variables such as sex and second eye operation. The randomization code was allocated inside the operating room just before the surgery in a sealed

envelope drawn by a nurse not involved in patient treatment. Pain assessment was performed by a single skilled observer, blinded to the type of anesthesia. The patients and the operating surgeon were aware of the treatment being given.

## Outcome measures

The primary outcome measure was pain scores during the operation, and during the injection. The secondary outcome measures were postoperative pain scores, operative time, anesthetic complications, and operative complications. Pain visual analog scale (VAS) scores (0 = no pain, and 100 = the worst imaginable pain) were recorded by a well-trained research assistant after the patient was administered the anesthetic agent, and upon completion of the operation. The patients also graded the level of pain felt 2 hours after their surgery.

Operative time was measured as the time between eyelid speculum insertion and removal. Operative and anesthetic complications were recorded by the operating surgeon.

## Treatment procedure

Surgical standardization and consistency was maintained throughout the study by ensuring that each surgeon carried out all the surgical procedures and anesthetic techniques accurately. All patients underwent MSICS using the modified Blumenthal technique (further described below).<sup>8</sup> Third-year residents from the university hospital in Thailand performed the cataract surgeries under close supervision during the 2-week MSICS training course.<sup>9</sup> Each resident was required to have previous experience of having performed cataract surgery using ECCE with IOL implantation in at least 30 of the cases and of having performed cataract surgery using phacoemulsification in at least 10 cases, to ensure that they could perform capsulorhexis before they participated in this study. The 14 participating residents had performed retrobulbar anesthesia during their 2 years of residency training and had also received training in MSICS using the modified Blumenthal technique for at least 1 week prior to operating on the patients enrolled in this study.

Patients in group one received superior subconjunctival anesthesia. Within 5 minutes before surgery, a drop of 0.5% tetracaine hydrochloride was instilled into the lower conjunctival sac, followed by the administration of subconjunctival anesthesia consisting of 0.2 mL of xylocaine 2% with adrenalin 1:100,000 (Drocanil-A®; M and H Manufacturing Co, Ltd, Samutprakarn, Thailand), injected under the superior bulbar conjunctiva. Patients in group two received retrobulbar anesthesia. A drop of 0.5% tetracaine

hydrochloride was instilled into the lower conjunctival sac, and a retrobulbar block with 2.0 mL of xylocaine 2% with adrenalin 1:100,000 (Drocanil-A®) was performed using the standard procedure.

Patients' heart rate, respiratory rate, blood pressure, and oxygen saturation were monitored using a Philips monitor (MP40 Model, Philips Healthcare, Andover, MA). Patients were advised to ask for supplemental anesthesia if they were unable to tolerate the procedure. They were also interviewed regarding the tolerance of the procedure 30 minutes after the surgery, by a trained interviewer blinded to the type of anesthesia received by the patients. Patients who could not tolerate the procedure received an additional retrobulbar block or subconjunctival anesthesia as appropriate. Successful anesthesia was defined as completion of the operation without requiring supplemental anesthesia.

For the modified Blumenthal technique,<sup>8</sup> an anterior chamber maintainer was inserted through the 6 o'clock side port. A 6–6.5 mm scleral tunnel incision was performed at the 12 o'clock position and a one-side port was created at the 3 or 9 o'clock position. A continuous circular capsulorhexis (or capsulotomy) was performed, followed by hydrodissection and nuclear dislocation into the anterior chamber. Anterior cortical debris was removed. The nucleus was dislocated into the anterior chamber, and the lens glide was inserted below the nucleus. Gentle pressure was applied on the lens glide. The hydrostatic pressure pushed the nucleus through the scleral tunnel incision. The cortex was removed, and then the IOL was placed in the capsular bag. The wound was sutured with one stitch if wound leakage occurred.

## Sample size calculation

The main outcome measure was pain scores during the operation and during the injection. The pain scores during the operation were used to calculate the sample size. We used the data from a pilot study of 20 patients (10 patients in each group) to determine the sample size. The intraoperative pain scores were 49 (SD, 30) in the subconjunctival anesthesia group and 41 (SD, 25) in the retrobulbar group. With a statistical power of 80% and the level of statistical significance set at  $P < 0.05$ , we estimated that a minimum of 74 patients would be required in each group (Sample Size calculator; DSS Research, Fort Worth, TX).

## Data analysis

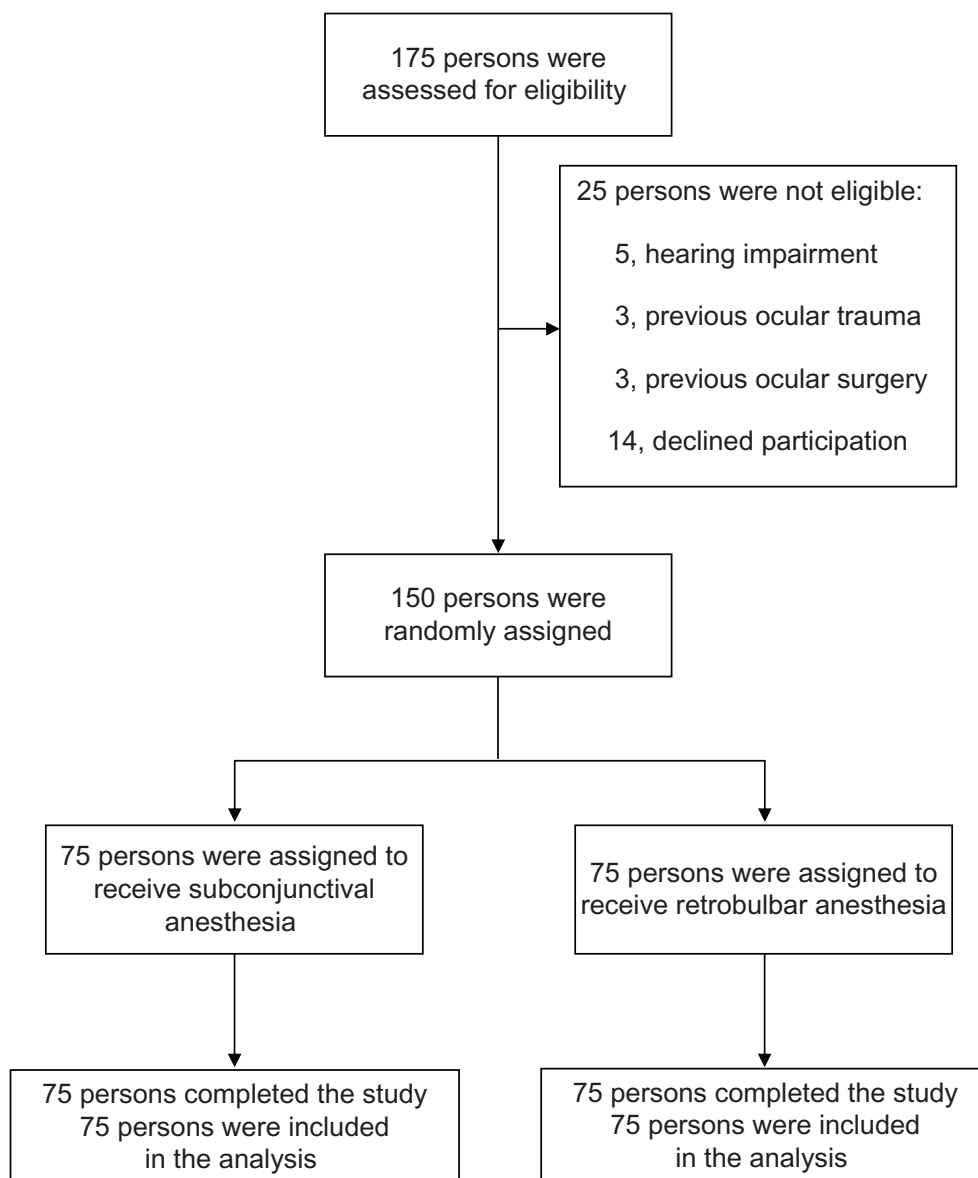
Statistical analysis was performed using SPSS for Windows (version 11.5; IBM, Armonk, NY). Data were tested for normal distribution using the Kolmogorov–Smirnov test.

Baseline demographic data and procedure complications were compared using the Chi-square test. Comparisons of operation time, pain scores, and requirement of supplemental anesthesia in the two groups were performed using the independent Student's *t*-test, Mann–Whitney *U* test, and Fisher's exact test, respectively. A  $P$  value  $< 0.05$  was considered statistically significant.

## Results

We recruited 150 patients with all types of cataracts for the trial (Figure 1). Seventy-five patients were allocated to the subconjunctival anesthesia group (Group 1) and 75 patients to the retrobulbar anesthesia group (Group 2). Their demographic data, including age and sex, as well as their associated conditions were similar at the time of recruitment (Table 1). A total of 150 patients completed the study. The mean operative time was 47.1 (9.9) min and 47.7 (10.9) min in Groups 1 and 2, respectively, which was not significantly different ( $P = 0.74$ ). The VAS-intraoperative pain (VAS-OP), VAS-postoperative pain (VAS-PO), and VAS-injection pain (VAS-IN) scores were rated on a 100-point VAS. The distribution of pain scores was not normal in either group. The median VAS-IN, VAS-OP, and VAS-PO scores are shown in Table 2. During the operation, a median (interquartile range) pain score of 40 (range, 20–70) vs 40 (range, 20–50) was seen in the subconjunctival group and the retrobulbar group, respectively. After the operation, a median (interquartile range) pain score of 20 (range, 0–30) vs 10 (range, 0–20) was observed in the subconjunctival group and the retrobulbar group, respectively. The pain score difference (intraoperative and postoperative pain) between the groups was not statistically significant (Figure 2). The median injection pain score was significantly lower in group 1 as compared to group 2 ( $P < 0.001$ ). Supplemental anesthesia was required in nine of the 75 eyes (12%) in the retrobulbar anesthesia group, but in only three of the 75 eyes (4%) in the subconjunctival anesthesia group. The operation was successfully performed with supplemental anesthesia where required, without complications, in all patients.

There was no difference in the operative complications, but the incidence of injection complications differed significantly (Table 2). Localized subconjunctival hemorrhage was observed in 19 of 75 eyes (25.3%) in the subconjunctival group and in one of 75 eyes (1.3%) in the retrobulbar group. Iris prolapse tended to be more common in the retrobulbar group and was possibly related to the positive vitreous pressure, but the difference between the two groups was not statistically significant ( $P = 0.209$ ).



**Figure 1** Flowchart of study design.

**Table 1** Baseline demographic data of the participants

	Group 1 subconjunctival anesthesia (n = 75)	Group 2 retrobulbar anesthesia (n = 75)
Age (years)		
Mean	69	70
Range	50–86	44–86
Sex (n)		
Female	46	47
Male	29	28
Laterality (n)		
Right	41	40
Left	34	35
Operation		
First eye	55	54
Second eye	20	21

## Discussion

The operations were successful in all 150 patients. Seventy-two of the 75 patients (96%) in the subconjunctival group and 66 of the 75 patients (88%) in the retrobulbar group tolerated the operation well. Supplemental anesthesia was required in only three of the 75 patients (4%) in the subconjunctival group and in nine of the 75 patients (12%) in the retrobulbar group. However, there were only two levels of assessment (yes/no). For more accuracy, the need for additional anesthesia should be evaluated in the questionnaire. The operative time was prolonged (>47 minutes in both groups) because it was performed by residents in training. The pain scores during the operation (VAS-OP) were not

**Table 2** Results and complications in the participants

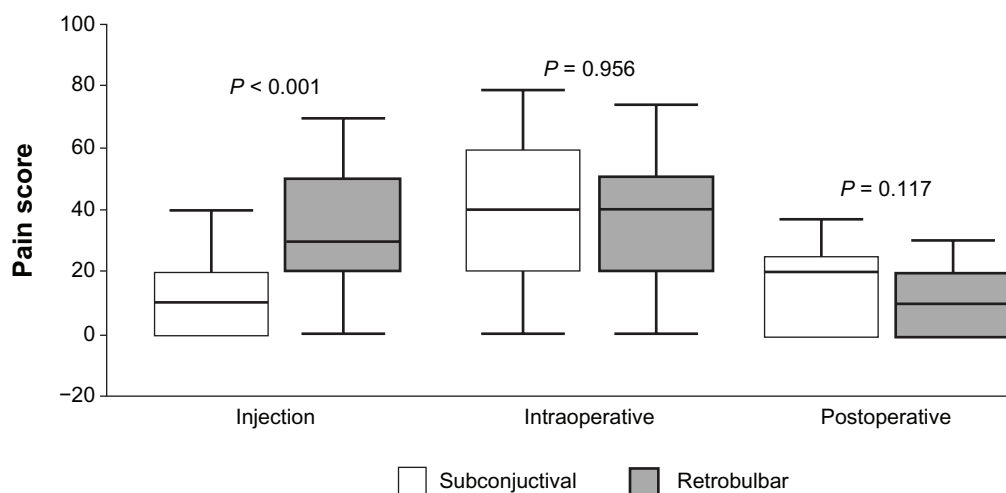
	Group 1 subconjunctival anesthesia (n = 75)	Group 2 retrobulbar anesthesia (n = 75)	P
Supplementary anesthesia	3 patients (4.0%)	9 patients (12.0%)	0.13 <sup>F</sup>
Operative time, min	47.1 ± 9.9	47.7 ± 10.9	0.74 <sup>†</sup>
VAS-IN	10 [0, 20]	30 [20, 50]	
VAS-OP	40 [20, 70]	40 [20, 50]	
VAS-PO	20 [0, 30]	10 [0, 20]	
Injection complications			<0.001 <sup>‡</sup>
None	56	74	
Retrobulbar hemorrhage	0	0	
Localized subconjunctival hemorrhage	19	1	
Operative complications			0.262 <sup>‡</sup>
None	70	66	
Vitreous loss	3	4	
Iris prolapse	1	5	
Zonular tear	1	0	

**Notes:** Values are mean ± SD, median [interquartile range], or n (%); <sup>F</sup>Fisher's exact test; <sup>†</sup>Student's t-test; <sup>‡</sup>Chi-square test.

**Abbreviations:** VAS, visual analog scale; IN, injection pain; OP, intraoperative pain; PO, postoperative pain.

significantly different between the two groups, suggesting that subconjunctival anesthesia provides equal pain control as retrobulbar anesthesia during MSICS. The median injection pain score (VAS-IN) was significantly lower in Group 1 than in Group 2, indicating that the administration of subconjunctival anesthesia causes less pain as compared to the retrobulbar block. Unlike peribulbar or retrobulbar anesthesia, subconjunctival anesthesia eliminates the risk of globe perforation, retrobulbar hemorrhage, and optic-nerve trauma, and is associated with minimal discomfort.<sup>10</sup> No serious intraoperative complications occurred in our study. Posterior capsular tear with vitreous loss occurred in three of 75 patients (5.3%) in the subconjunctival group, which is similar to the 5.01% rate reported previously.<sup>9</sup>

Anesthetic complications such as localized subconjunctival hemorrhage are also more common when using this technique, which is in agreement with the results of Tulvatana et al.<sup>7</sup> The successful use of circumcorneal perilimbal anesthesia in extracapsular cataract surgery, and circumferential subconjunctival anesthesia and superior subconjunctival anesthesia with deep topical anesthesia has been reported.<sup>7,11,12</sup> We used superior subconjunctival anesthesia, which permits the surgeon to perform procedures such as bridle suturing, subconjunctival peritomy, cautery, and wound construction. In addition, it allows the surgeon to manage a prolapsed iris or nucleus, enlarge the pupil, break the capsule, and perform a vitrectomy in the same manner as when injection anesthesia is used.

**Figure 2** Comparison of the visual analog scale between the groups.

Residents in our 2-week training course of MSICS are wary about performing capsulorhexis, because, if the patients move their eyes during the capsulorhexis, while under subconjunctival anesthesia, an anterior capsular tear can occur. Therefore, we suggest that the retrobulbar block is routinely utilized for anesthesia by residents in the first week of training, and the subconjunctival anesthesia later in the second week, by which time they have developed good surgical skills. Patient selection is also important for successful operations in the training course. Patients with poor cooperation or communication during surgery (because of hearing impairment, dementia, etc) should not be selected for cataract surgery under subconjunctival anesthesia.

The anesthesia was administered by different surgeons in both groups. However, this limitation could not be controlled because these residents from the university campus were on 2-week rotations for MSICS training. Patient satisfaction as well as surgeon stress levels were not reported herein, and should be recorded in future studies.

## Conclusion

Superior subconjunctival anesthesia provided similar pain control in MSICS as retrobulbar anesthesia. Both methods can provide effective anesthesia for cataract surgery in residency training programs.

## Disclosure

The authors have no financial or proprietary interest in any material or method mentioned. The authors wish to

thank Sommai Khotchanam (PhD) for his assistance in the statistical analysis.

## References

1. Zehetmayer M, Radax U, Skorpik C, et al. Topical versus peribulbar anesthesia in clear corneal cataract surgery. *J Cataract Refract Surg*. 1996;22:480–484.
2. Unal M, Yücel I, Altin M. Pain induced by phacoemulsification performed by residents using topical anesthesia. *Ophthalmic Surg Lasers Imaging*. 2007;38:386–391.
3. Mathew MR, Webb LA, Hill R. Surgeon experience and patient comfort during clear corneal phacoemulsification under topical local anesthesia. *J Cataract Refract Surg*. 2002;28:1977–1981.
4. Edge R, Navon S. Scleral perforation during retrobulbar and peribulbar anesthesia: risk factors and outcome in 50,000 consecutive injections. *J Cataract Refract Surg*. 1999;25:1237–1244.
5. Pautler SE, Grizzard WS, Thompson LN, et al. Blindness from retrobulbar injection into the optic nerve. *Ophthalmic Surg*. 1986;17:334–337.
6. Javitt JC, Addiego R, Friedberg HL, et al. Brain stem anesthesia after retrobulbar block. *Ophthalmology*. 1987;94:718–724.
7. Tulvatana W, Kulvichit K, Tinnungwattana U. Circumferential subconjunctival anesthesia versus retrobulbar anesthesia for extracapsular cataract extraction. *Anesth Analg*. 2006;102:1900.
8. Kongsap P. Visual outcome of manual small-incision cataract surgery: comparison of modified Blumenthal and Ruit techniques. *Int J Ophthalmol*. 2011;4:62–65.
9. Kongsap P. Visual outcomes and incidence of vitreous loss among third-year ophthalmology residents performing manual small incision cataract surgery. *Int J Ophthalmol*. 2009;9:2057–2059.
10. Hamilton RC, Gimbel HV, Javitt JC. The prevention of complications of regional anesthesia for ophthalmology. *Ophthalmol Clin North Am*. 1990;3:111–125.
11. Makuloluwa CA, Dharmarathna L. Circumcorneal perilimbal anesthesia in extracapsular cataract extraction with intraocular lens implantation. *J Cataract Refract Surg*. 2000;26:1647–1649.
12. Tinnungwattana U, Gorvanich S, Kulvichit K, et al. Combined deep topical and superior subconjunctival anesthesia for extracapsular cataract extraction in a rural eye camp. *Anesth Analg*. 2009;109:2025–2027.

### Clinical Ophthalmology

### Publish your work in this journal

Clinical Ophthalmology is an international, peer-reviewed journal covering all subspecialties within ophthalmology. Key topics include: Optometry; Visual science; Pharmacology and drug therapy in eye diseases; Basic Sciences; Primary and Secondary eye care; Patient Safety and Quality of Care Improvements. This journal is indexed on

Submit your manuscript here: <http://www.dovepress.com/clinical-ophthalmology-journal>

### Dovepress

PubMed Central and CAS, and is the official journal of The Society of Clinical Ophthalmology (SCO). The manuscript management system is completely online and includes a very quick and fair peer-review system, which is all easy to use. Visit <http://www.dovepress.com/testimonials.php> to read real quotes from published authors.