

CHONGQING UNIVERSITY CANCER HOSPITAL

Pathological Report

● General Information

Name: -	Gender: Female	Age: 49 years old	ID: -
Department: Department of Breast Center		Clinical diagnosis: tumor	
Submitting surgeon's name: -		Date: 01/25/2013	

● Gross Appearance

A piece of gray-red skin and muscular tissue, about 7 x 4 x 1.5 cm in size. A gray mass is found near the muscular tissue about 5 cm from the skin. The mass has medium texture, unclear boundary, and no capsule. The cut surface is in gray.

● Pathological Diagnosis

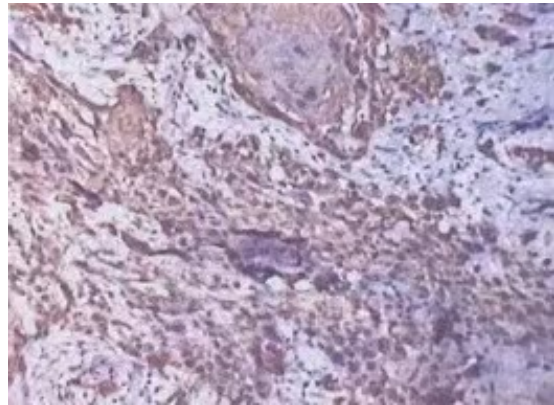
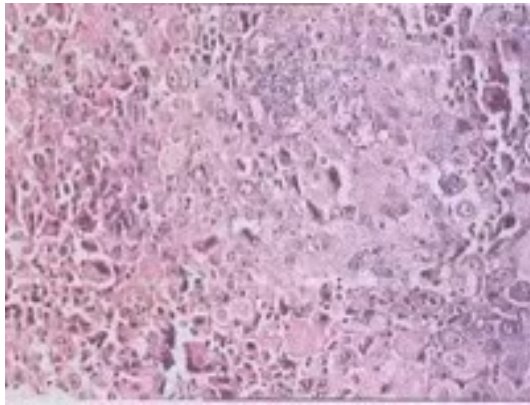
Right chest wall: Squamous cell carcinoma.

According to the analysis of H&E and IHC images, the pathological diagnosis is considered as breast squamous cell carcinoma with metastasis to the right chest wall.

● IHC Results

CK-HMW: (-). CK5/6: (+). P63: (+). P16: (-). TTF1: (-). Ki67: (+), 80%. PCNA: (+), 80%. TOPO II: (+), 40%. MDR1: (-). GST- π : (+). ER: (-). PR: (-). C-erbB-2: (-).

- Images



Date of diagnosis: 01/29/2013.

The first pathologist: -

The second pathologist: -