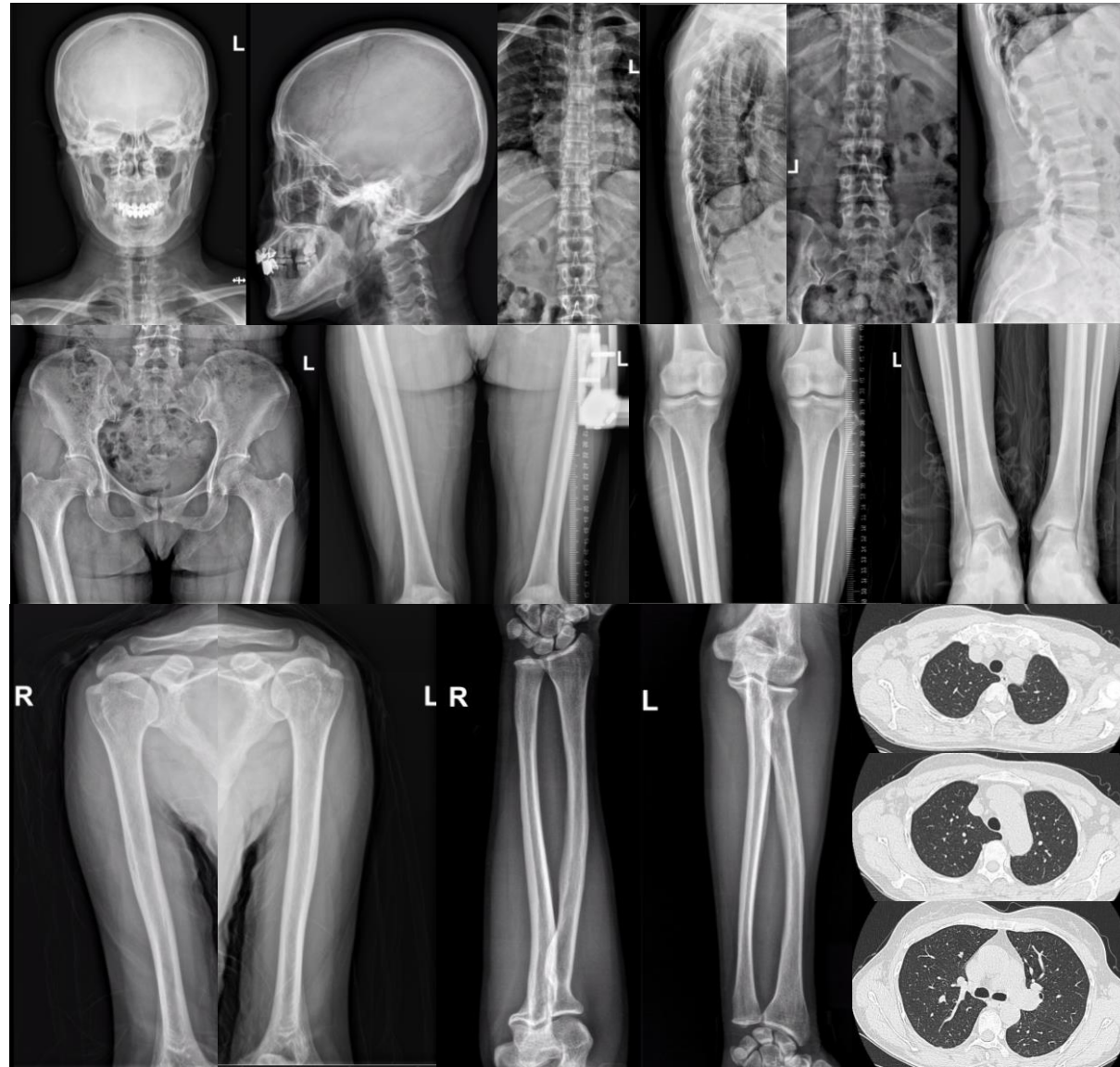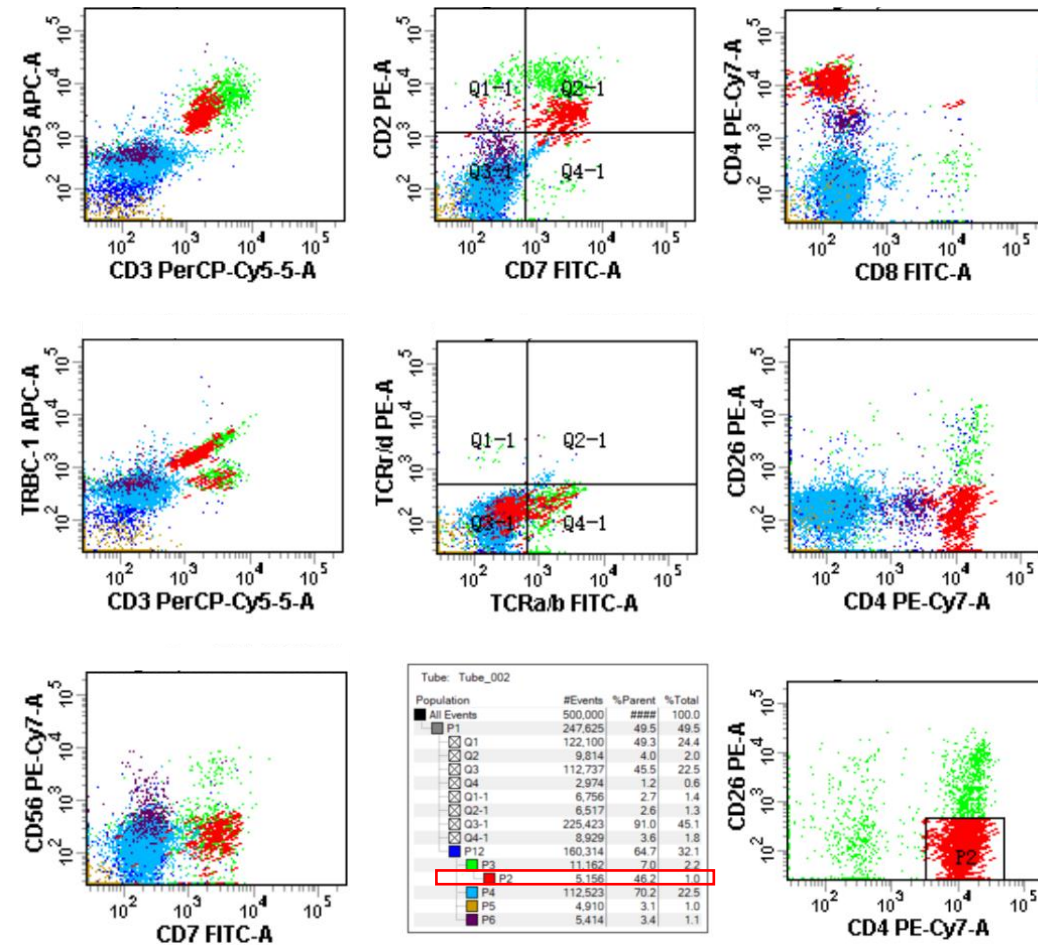
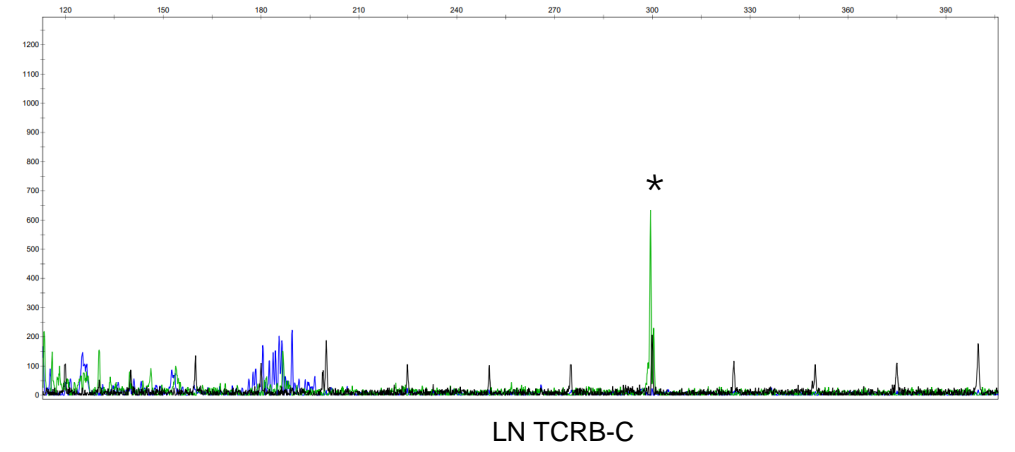
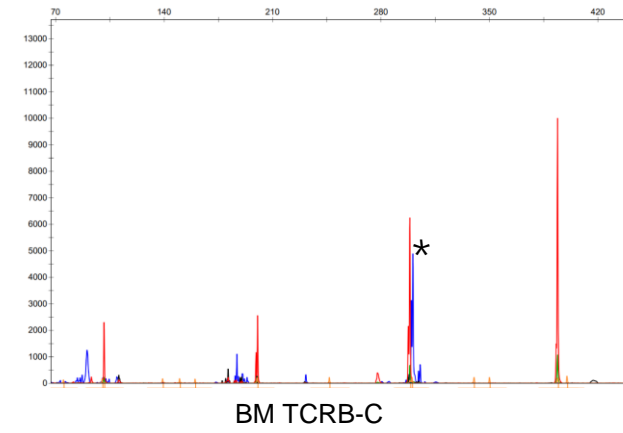
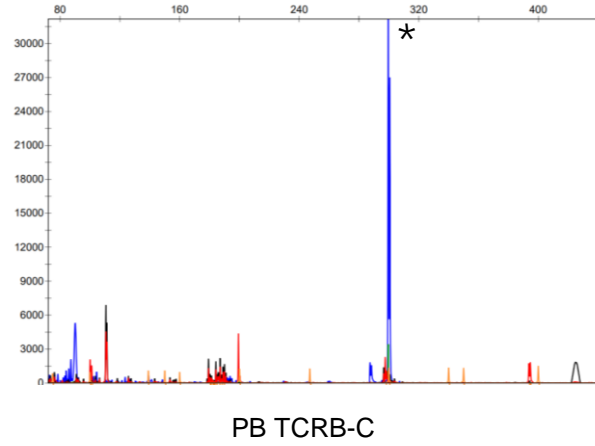
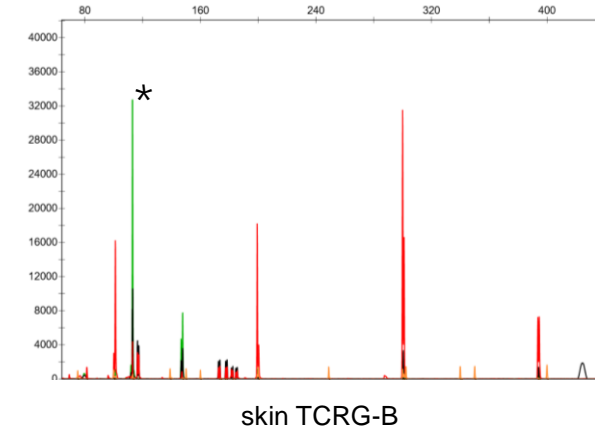
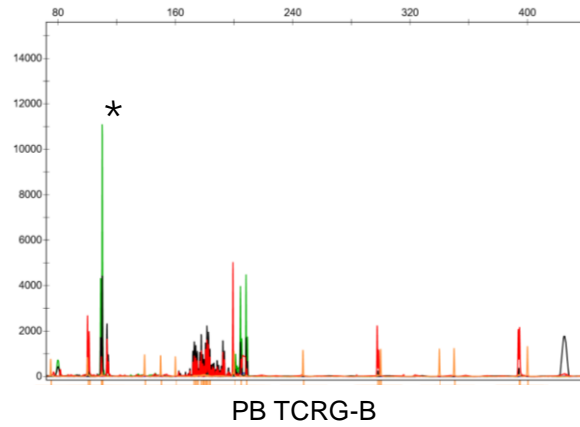


Supplementary Figure 1: Bone imaging of the skull, thoracolumbar spine, pelvis, and limbs did not reveal any bone lesions and the lung computed tomography (CT) scan was normal.



Supplementary Figure 2: Representative images of flow cytometric immunophenotyping of PB and CD4+CD26- cells accounting for 46.2% of total lymphocytes.

a**b**

Supplementary Figure 3: Molecular analysis for TCR gene rearrangement. **a.** TCRB peaks of identical sizes in the PB, BM, and LN. **b.** TCRG peaks of identical sizes in the PB and skin.