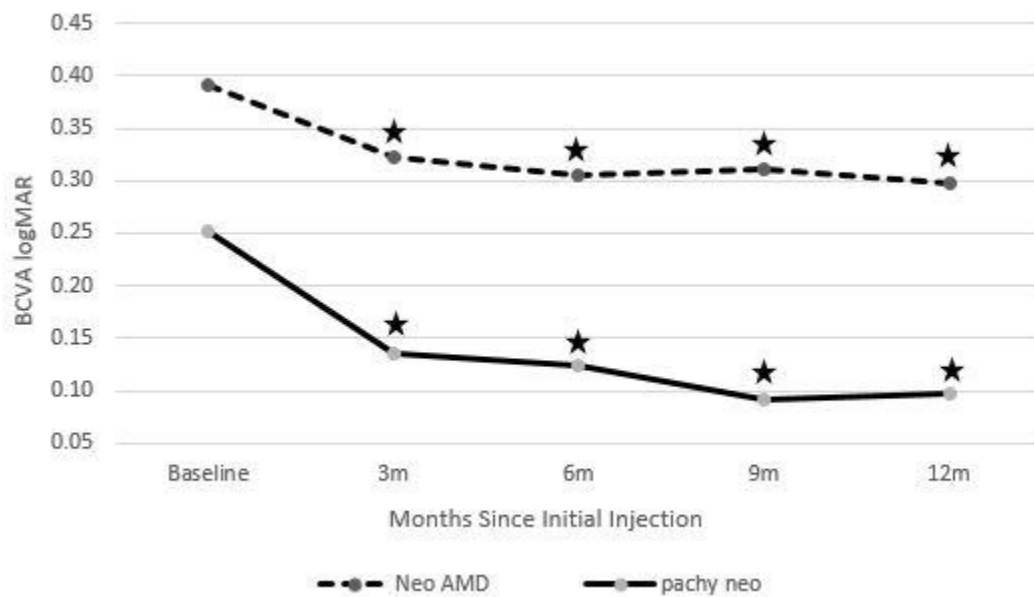


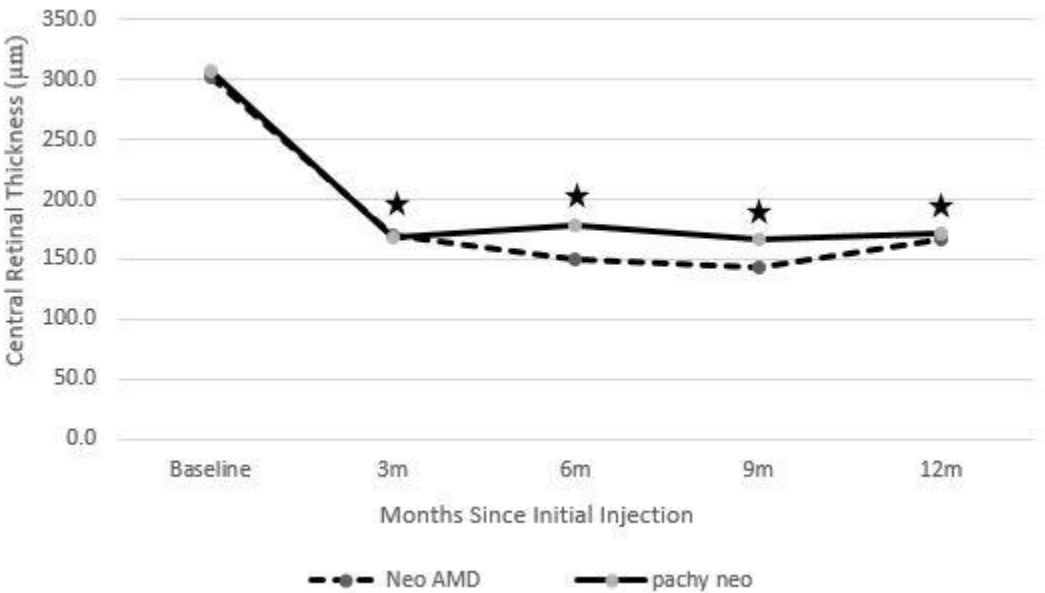
Supplementary Figure 1. Changes in mean BCVA in eyes with neovascular AMD and pachychoroid neovascularopathy treated with intravitreal aflibercept injection.



Star: significant difference from baseline.

BCVA = best-corrected visual acuity; AMD = age-related macular degeneration; logMAR = logarithm of minimal angle of resolution.

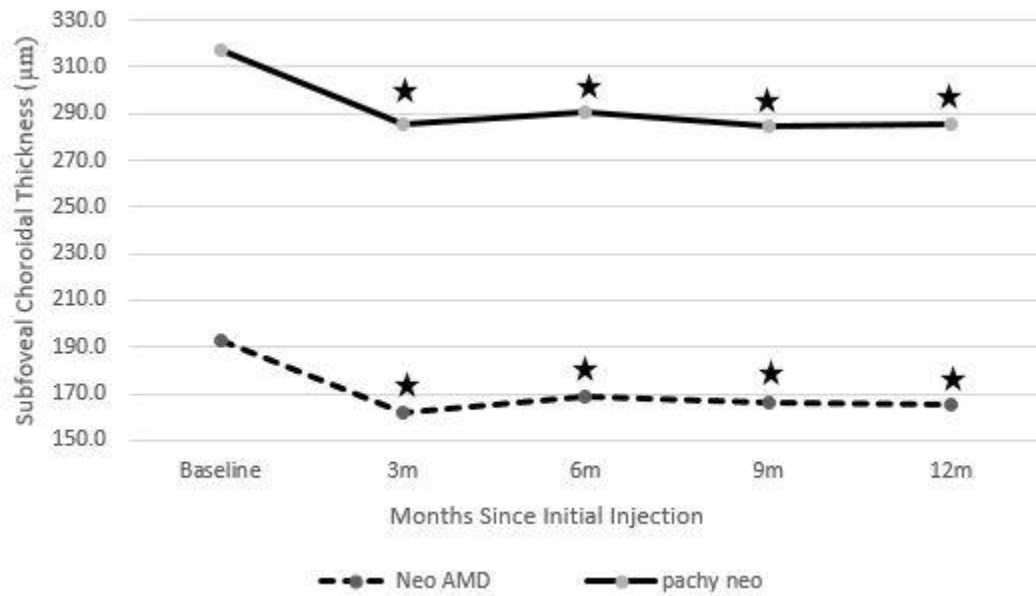
Supplementary Figure 2. Changes in mean central retinal thickness in eyes with neovascular AMD and pachychoroid neovascularopathy treated with intravitreal aflibercept injection.



Star: significant difference from baseline.

AMD = age-related macular degeneration.

Supplementary Figure 3. Changes in mean subfoveal choroidal thickness in eyes with neovascular AMD and pachychoroid neovascularopathy treated with intravitreal aflibercept injection.



Star: significant difference from baseline.

AMD = age-related macular degeneration.