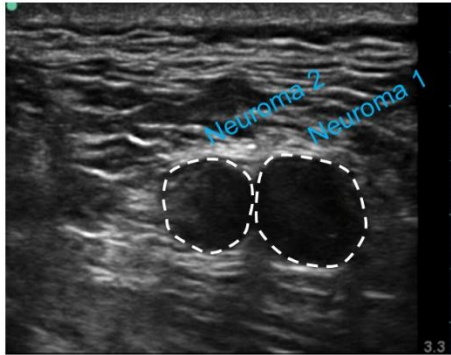
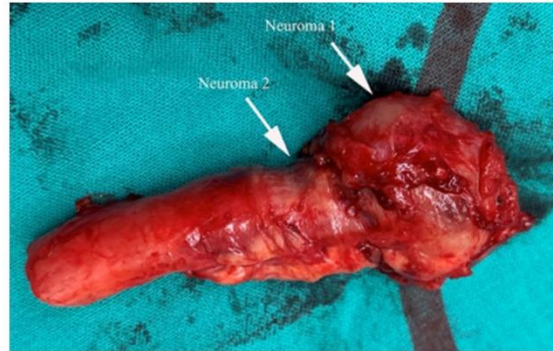


A



B



Supplementary Figure 1. Characteristics of painful neuroma in an amputee. A: Preoperative ultrasound showed two neuromas on one nerve. B: The results of postoperative specimen were consistent with preoperative ultrasonography.