



# Panitumumab-Induced Periorbital Dermatitis: A Case Report

Napat Pongbangpho, Kumutnart Chanprapaph , Wimolsiri Iamsumang 

Division of Dermatology, Department of Medicine, Faculty of Medicine Ramathibodi Hospital, Mahidol University, Bangkok, Thailand

Correspondence: Wimolsiri Iamsumang, Division of Dermatology, Faculty of Medicine Ramathibodi Hospital, Mahidol University, 270 Rama VI Road, Rajthevi, Bangkok, 10400, Thailand, Tel +662-201-1141, Fax +662-201-1211, Email i.wimolsiri@hotmail.com

**Abstract:** Panitumumab is a recombinant, fully humanized immunoglobulin G<sub>2</sub> monoclonal antibody targeting the epidermal growth factor receptor (EGFR). It is approved for the first- and second-line treatment of advanced wild-type KRAS colorectal cancer. Although common cutaneous side effects include acneiform dermatitis, folliculitis, and xerosis, ocular toxicities have occasionally been reported. Herein, we report the case of an 81-year-old Thai female with chemorefractory advanced stage sigmoid colon cancer who developed isolated periorbital dermatitis following treatment with panitumumab plus modified FOLFOX6. The cutaneous adverse reaction occurred after subsequent infusions; however, it was alleviated by topical therapy. To our knowledge, panitumumab-induced periorbital dermatitis is exceptionally rare. To raise awareness of potential periocular cutaneous side effects in patients taking EGFR inhibitors, the published literature regarding periorbital dermatitis induced by these agents has also been reviewed in this article. Periorbital dermatitis should be considered as a potential cutaneous reaction following panitumumab administration, and should be promptly treated.

**Keywords:** colorectal cancer, cutaneous adverse drug reaction, epidermal growth factor receptor inhibitors, panitumumab, periorbital rash

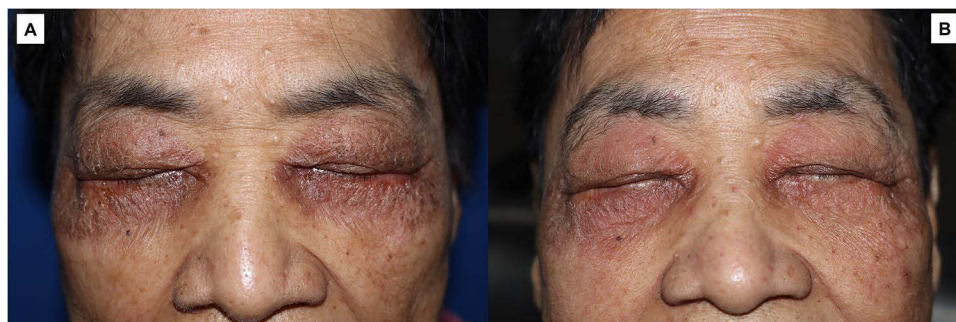## Introduction

Panitumumab is a recombinant, fully humanized immunoglobulin G<sub>2</sub> (IgG<sub>2</sub>) monoclonal antibody targeting the epidermal growth factor receptor (EGFR). It is approved for the treatment of refractory metastatic wild-type Kirsten rat sarcoma virus (KRAS) colorectal cancer.<sup>1</sup> Panitumumab binds to the EGFR and interferes with downstream cell signaling, leading to the inhibition of cell growth and angiogenesis, and induces apoptosis.<sup>2</sup> Since EGFR is present on both normal epithelial cells and tumor cells, dermatological side effects, such as papulopustular eruptions, xerosis, and pruritus, are generally anticipated.<sup>3</sup> Similarly to other EGFR inhibitors, cutaneous toxicities are the most frequent adverse effect of panitumumab administration.<sup>4,5</sup> However, cases of panitumumab-induced periocular toxicity have scarcely been reported. We hereby present a rare case of panitumumab-induced periorbital dermatitis in a patient with advanced stage colorectal cancer. A literature review of periorbital dermatitis related to EGFR inhibitors is performed to emphasize this potential drug-related side effect.

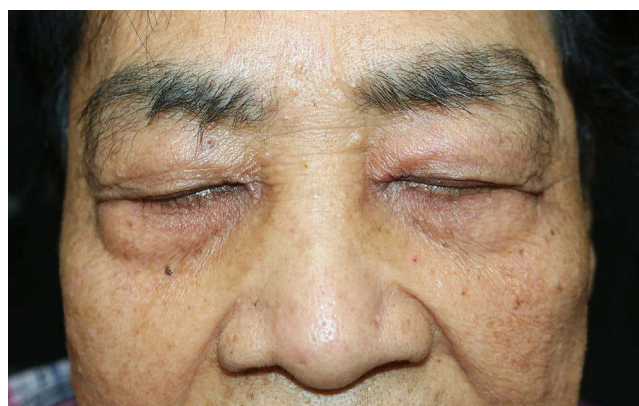
## Case Presentation

An 81-year-old female presented with significant weight loss and changes in bowel habit. Robot-assisted sigmoidectomy was carried out in April 2022 and the pathology report showed moderately differentiated adenocarcinoma with an absence of KRAS and v-Raf murine sarcoma viral oncogene homolog B (BRAF) mutation. Clinical staging was performed and the diagnosis of sigmoid colon cancer stage IIIB (T4aN1M0) was established. She subsequently received eight cycles of capecitabine 3500 mg/day from June to November 2022. Unfortunately, she had progressive disease, with liver metastasis being detected on a computed tomography scan. In March 2023, the first cycle of modified FOLFOX6 (oxaliplatin 70 mg/m<sup>2</sup>, leucovorin 520 mg/m<sup>2</sup>, and fluorouracil 1200 mg/m<sup>2</sup>) was commenced. Because of the disease progression, panitumumab 6 mg/kg had

been added since the second cycle of chemotherapy, which was scheduled for administration every 2 weeks. In April 2023, after a week following the second cycle of the combination regimen, the patient developed periorbital skin erythema and pruritus, which spontaneously resolved within 1 week without treatment. Later on, after 10 days following the third cycle of panitumumab infusion, a similar periorbital rash occurred. She underwent a dermatological consultation and the physical examination revealed ill-defined scaly erythematous plaques with marked pruritus involving both periorbital areas (Figure 1A). She reported a history of using lubricant eye drops, which contained only hydroxypropyl methylcellulose, for several years, but denied the application of other ophthalmic medications or new facial skin care products. On ophthalmic evaluation, her corrected visual acuity was 20/30 and 20/50 in the right eye and the left eye, respectively. No papillary or follicular reactions were observed. Corneal examination showed minimal punctate epithelial erosions without epithelial defects. The slit-lamp examination revealed flat maculae, normal cup-to-disc ratio, and no retinal detachments. An overall evaluation indicated no ophthalmic involvement. Initially, allergic contact dermatitis due to artificial tears and cutaneous side effects from panitumumab were suspected. Nevertheless, a repeated open application test with the ophthalmic preparation was performed and showed negative results, making the first differential diagnosis less likely. On the other hand, the temporal relationship between panitumumab administration and the onset of the rash suggested the diagnosis of the latter. Hence, the diagnosis of panitumumab-induced periorbital dermatitis with grade 1 skin toxicity, according to the Common Terminology Criteria for Adverse Events (CTCAE) version 5.0,<sup>6</sup> was established. The ophthalmologist suggested that panitumumab could be readministered, with the regular use of artificial tears and ophthalmological monitoring. Her periorbital rash was treated with 0.25% prednicarbate cream twice daily and improved within 7 days. However, at 10–14 days following her next infusions, she repeatedly developed a similar periorbital rash, which was alleviated by an application of 0.03% tacrolimus ointment twice daily (Figure 1B). The recurring cutaneous symptoms upon medication re-exposure helped to confirm the diagnosis of panitumumab-related periorbital dermatitis. Fortunately, she was able to finish the course of therapy and then the rash completely resolved (Figure 2). In September 2023, on the follow-up computed tomography scan, although an improvement in an old metastatic lesion was noted, new surgically unresectable lesions of liver metastasis were



**Figure 1** (A) Bilateral ill-defined pruritic scaly erythematous plaques with minimal crusts on the periorbital area after the third cycle of modified FOLFOX6 plus panitumumab therapy. (B) Recurrence of similar periorbital lesions after the fifth cycle of therapy.



**Figure 2** Complete resolution of the periorbital rash after 4 months of topical treatment.

also detected. Therefore, two treatment options, including the treatment with fluorouracil–panitumumab infusion as a maintenance therapy, and the best palliative care, were offered to the patient.

## Discussion

EGFR, also known as human epidermal growth factor receptor 1 (HER1) or ErbB1, is a member of the ErbB family of receptor tyrosine kinases. EGFR is widely expressed in normal human skin tissues, including epidermal basal cells, outer root sheath cells of the hair follicle, sebaceous glands, eccrine glands, and vascular smooth muscle cells.<sup>7</sup> EGFR stimulation promotes epidermal proliferation and angiogenesis, and inhibits keratinocyte apoptosis.<sup>2</sup> The inhibition of EGFR activity causes damage to the epidermal layer and hair follicles, resulting in an imbalance of skin homeostasis.<sup>7</sup> As EGFR is abundant in normal keratinocytes in the basal and suprabasal layers of the epidermis, EGFR inhibitors are frequently associated with cutaneous side effects, with papulopustular eruption being the most common. Other cutaneous side effects include xerosis, telangiectasia, paronychia, brittle and curly scalp hair, and hypertrichosis on the face and lip. Cutaneous adverse effects are dose dependent, as shown for gefitinib and panitumumab.<sup>3</sup> Likewise, EGFR is also located at the corneal, limbal, and conjunctival epithelium, and therefore ocular side effects have sometimes been reported following EGFR inhibition.<sup>8–15</sup> Common adverse effects include dysfunctional tear syndrome, followed by blepharitis and eyelash changes (trichomegaly and trichiasis). The most common culprits appear to be erlotinib and cetuximab, among others.<sup>8</sup>

Panitumumab is a fully human monoclonal antibody against EGFR, which is currently prescribed as a monotherapy or a combined agent with chemotherapy to treat metastatic colorectal cancer.<sup>16,17</sup> Regarding panitumumab, the reported cutaneous toxicities are similar to those reported for other EGFR inhibitors, including acneiform eruption, papulopustular rash, and pruritus.<sup>3,18</sup> Ophthalmic toxicities linked to panitumumab, such as trichomegaly, cicatricial ectropion, corneal melting with perforation, and keratoconjunctivitis, have also been occasionally reported.<sup>10,13,19–22</sup>

Periorbital dermatitis is characterized by an inflammation of the periorbital area. It is frequently associated with eyelid dermatitis.<sup>23</sup> There have been reports of periorbital dermatitis with or without ocular toxicities, mainly relating to the older generation anti-EGFR agents, such as cetuximab and erlotinib.<sup>9,11,12,14,15</sup> These side effects developed in a time frame varying from 1 week to 12 months after anti-EGFR administration. To the best of our knowledge, a periorbital rash due to panitumumab has rarely been reported in the literature.<sup>10,13</sup> Scofield-Kaplan et al noted a man with periorbital rash and bilateral cicatricial ectropion of the lower eyelids secondary to anterior lamellar contraction, and bilateral exposure keratoconjunctivitis after the fifth cycle of panitumumab. The symptoms improved with neomycin–polymyxin B-dexamethasone ophthalmic ointment, oral doxycycline, and temporary panitumumab cessation. Fortunately, the patient was able to carry on with four more cycles of panitumumab without side effects.<sup>13</sup> In 2020, another case was reported, with eyelid dermatitis as well as cicatricial ectropion and madarosis, after receiving panitumumab for 8 weeks. The rash improved after panitumumab cessation and responded well to lubricants and topical ophthalmic steroid/antibiotic ointment.<sup>10</sup> The mechanism of EGFR inhibitor-induced periocular side effects has not been well elucidated. Nonetheless, this could be explained by the high concentration of sebaceous glands, hair follicles, and basal epidermal cells in the eyelids, which makes the periorbital area susceptible.<sup>15</sup> The similarities in the ocular and periocular events linked to agents in different generations of anti-EGFR medication imply that these toxicities could be a class effect.<sup>14</sup> In addition, periorbital skin in those with atopic dermatitis is vulnerable as a consequence of a defective barrier and is easily sensitized by contact irritants and other allergens.<sup>24</sup> Most biological agents can also cause immune dysregulation, which may exacerbate the disease. We propose that periorbital dermatitis related to panitumumab may share an overlapping pathophysiology with atopic eyelid dermatitis. However, our patient denied a personal or family history of atopy.

In the present case, the more common causes of periorbital and eyelid dermatitis, including allergic contact dermatitis, atopic dermatitis, irritant contact dermatitis, and seborrheic dermatitis, were also considered in the differential diagnosis.<sup>23</sup> However, with regard to the disease onset and the clinical course, allergic contact dermatitis and, although rare, panitumumab-induced periorbital dermatitis were clinically compatible. Skin tests such as the patch test and repeated open application test often show false-negative results to ophthalmic solutions, with only approximately 35% of patients with suspected allergy to topical ophthalmic medications showing positive patch tests in one large study.<sup>25</sup> Although the negative repeated open application test to artificial tears in our patient could not completely exclude allergic

contact dermatitis, the recurrence of the rash after repeated exposure to panitumumab supported the diagnosis of panitumumab-induced periorbital dermatitis.

In terms of management for periorbital dermatitis induced by anti-EGFR therapy, local therapy with topical corticosteroids and topical calcineurin inhibitors for acute and chronic eyelid reactions, respectively, is usually effective.<sup>8,12</sup> Once the diagnosis has been made, early ophthalmic consultation is necessary to exclude ocular involvement. Cessation or dose adjustment of anti-EGFR agents, along with more aggressive medical management such as doxycycline and other ophthalmic preparations, may be required when ocular side effects are present.<sup>13</sup> In our case, since ophthalmic assessment revealed no serious ocular side effects and her periocular rash responded promptly to topical corticosteroid treatment, the same regimen of panitumumab infusion was continued. Although periorbital dermatitis due to EGFR inhibitors is generally reversible with temporary medication discontinuation or regimen modification,<sup>9–11,13</sup> some patients show persistent periorbital side effects even after dose modification.<sup>14,15</sup> It has been suggested that the occurrence of cutaneous side effects during therapy with panitumumab is a significant predictive factor for better disease outcome and favorable anti-cancer efficacy of the drug.<sup>26</sup> However, to date, there are no specific data showing an association between periorbital rash and therapeutic response regarding panitumumab therapy.

## Conclusion

Periorbital dermatitis can present as a rare cutaneous adverse effect of panitumumab administration. It can be an unpleasant symptom, affecting the patient's quality of life, including their social activity and their vision, and may lead to poor compliance with therapy. For that reason, it is necessary to monitor and inform patients about possible side effects, as well as to provide a prevention plan and promptly manage cutaneous symptoms when needed.

## Abbreviations

BRAF, v-Raf murine sarcoma viral oncogene homolog B; CTCAE, Common Terminology Criteria for Adverse Events; EGFR, epidermal growth factor receptor; FOLFOX6, oxaliplatin, leucovorin, and fluorouracil; HER1, human epidermal growth factor 1; IgG<sub>2</sub>, immunoglobulin G<sub>2</sub>; KRAS, Kirsten rat sarcoma virus.

## Ethics Approval and Informed Consent

The patient has given written informed consent for the publication of her clinical details and accompanying images. Institutional approval is not required for this case study.

## Funding

The authors received no financial support for this research.

## Disclosure

The authors declare that this manuscript was prepared in the absence of any commercial or financial relationships that could be construed as a potential conflict of interest.

## References

1. Hocking CM, Townsend AR, Price TJ. Panitumumab in metastatic colorectal cancer. *Expert Rev Anticancer Ther*. 2013;13(7):781–793. doi:10.1586/14737140.2013.811064
2. Toffoli G, De Mattia E, Cecchin E, Bion P, Masier S, Corona G. Pharmacology of epidermal growth factor inhibitors. *Int J Biol Markers*. 2007;22 (1 Suppl 4):S24–S39. doi:10.1177/17246008070221s404
3. Segal S, Van Cutsem E. Clinical signs, pathophysiology and management of skin toxicity during therapy with epidermal growth factor receptor inhibitors. *Ann Oncol*. 2005;16(9):1425–1433. doi:10.1093/annonc/mdi279
4. Chanprapaph K, Pongcharoen P, Vachiramon V. Cutaneous adverse events of epidermal growth factor receptor inhibitors: a retrospective review of 99 cases. *Indian J Dermatol Venereol Leprol*. 2015;81(5):547. doi:10.4103/0378-6323.157448
5. Chanprapaph K, Vachiramon V, Rattanakaemakorn P. Epidermal growth factor receptor inhibitors: a review of cutaneous adverse events and management. *Dermatol Res Pract*. 2014;2014:734249. doi:10.1155/2014/734249
6. National Cancer Institute Database. Rockville: Common Terminology Criteria for Adverse Events (CTCAE) Version 5.0; 2017. Available from: <https://www.cancer.gov>. Accessed March 3, 2024



7. Li Y, Fu R, Jiang T, et al. Mechanism of lethal skin toxicities induced by epidermal growth factor receptor inhibitors and related treatment strategies. *Front Oncol*. 2022;12:804212. doi:10.3389/fonc.2022.804212
8. Borkar DS, Lacouture ME, Basti S. Spectrum of ocular toxicities from epidermal growth factor receptor inhibitors and their intermediate-term follow-up: a five-year review. *Support Care Cancer*. 2013;21(4):1167–1174. doi:10.1007/s00520-012-1645-y
9. Chan JYY, Kwok TYT, Yuen HKL. Eyelash trichomegaly induced by erlotinib for metastatic lung cancer. *Hong Kong Med J*. 2021;27(1):60.e1–60.e3. doi:10.12809/hkmj208506
10. Jin HD, Blessing NW. Cicatricial ectropion and madarosis associated with panitumumab treatment of metastatic colorectal cancer. *Am J Ophthalmol Case Rep*. 2020;19:100810. doi:10.1016/j.ajoc.2020.100810
11. Manthri S, Chakraborty K. Blepharitis: a rare side effect related to cetuximab in patient with colorectal cancer. *BMJ Case Rep*. 2019;12(8):e231774. doi:10.1136/bcr-2019-231774
12. Melichar B, Nemcová I. Eye complications of cetuximab therapy. *Eur J Cancer Care*. 2007;16(5):439–443. doi:10.1111/j.1365-2354.2006.00763.x
13. Scofield-Kaplan S, Todaro J, Winn BJ. Reversible cicatricial ectropion associated with EGFR inhibitors. *Orbit*. 2018;37(5):364–367. doi:10.1080/01676830.2017.1423342
14. Frankfort BJ, Garibaldi DC. Periocular cutaneous toxicity and cicatricial ectropion: a potential class effect of antineoplastic agents that inhibit EGFR signaling. *Ophthalmic Plast Reconstr Surg*. 2007;23(6):496–497. doi:10.1097/IOP.0b013e31815a124b
15. Methvin AB, Gausas RE. Newly recognized ocular side effects of erlotinib. *Ophthalmic Plast Reconstr Surg*. 2007;23(1):63–65. doi:10.1097/IOP.0b013e31802d97f0
16. Lee MS, Kopetz S. Current and future approaches to target the epidermal growth factor receptor and its downstream signaling in metastatic colorectal cancer. *Clin Colorectal Cancer*. 2015;14(4):203–218. doi:10.1016/j.clcc.2015.05.006
17. Battaglin F, Dadduzio V, Bergamo F, et al. Anti-EGFR monoclonal antibody panitumumab for the treatment of patients with metastatic colorectal cancer: an overview of current practice and future perspectives. *Expert Opin Biol Ther*. 2017;17(10):1297–1308. doi:10.1080/14712598.2017.1356815
18. Mitchell EP, Piperdi B, Lacouture ME, et al. The efficacy and safety of panitumumab administered concomitantly with FOLFIRI or irinotecan in second-line therapy for metastatic colorectal cancer: the secondary analysis from STEPP (Skin Toxicity Evaluation Protocol With Panitumumab) by KRAS status. *Clin Colorectal Cancer*. 2011;10(4):333–339. doi:10.1016/j.clcc.2011.06.004
19. Goyal A, Blaes A. Trichomegaly associated with panitumumab. *N Engl J Med*. 2020;383(16):e94. doi:10.1056/NEJMicm2003622
20. Goyal S, Uwaydat SH. Epidermal growth factor receptor inhibitor induced trichomegaly and poliosis. *Ophthalmology*. 2018;125(2):294. doi:10.1016/j.ophtha.2017.11.004
21. Sarzi Sartori D, Lorangeira de Almeida A, Santana Pereira de Oliveira G, de Almeida HL. Scanning electron microscopy of panitumumab-induced eyelash and hair alterations - Pili canaliculi. *An Bras Dermatol*. 2022;97(2):240–242. doi:10.1016/j.abd.2021.03.011
22. Saint-Jean A, Sainz de la Maza M, Morral M, et al. Ocular adverse events of systemic inhibitors of the epidermal growth factor receptor: report of 5 cases. *Ophthalmology*. 2012;119(9):1798–1802. doi:10.1016/j.ophtha.2012.03.002
23. Wolf R, Orion E, Tüzün Y. Periorbital (eyelid) dermatides. *Clin Dermatol*. 2014;32(1):131–140. doi:10.1016/j.clindermatol.2013.05.035
24. Mughal AA, Kalavala M. Contact dermatitis to ophthalmic solutions. *Clin Exp Dermatol*. 2012;37(6):593–597. doi:10.1111/j.1365-2230.2012.04398.x
25. Landeck L, John SM, Geier J. Periorbital dermatitis in 4779 patients - patch test results during a 10-year period. *Contact Dermatitis*. 2014;70(4):205–212. doi:10.1111/cod.12157
26. Petrelli F, Borgonovo K, Barni S. The predictive role of skin rash with cetuximab and panitumumab in colorectal cancer patients: a systematic review and meta-analysis of published trials. *Target Oncol*. 2013;8(3):173–181. doi:10.1007/s11523-013-0257-x

## Clinical, Cosmetic and Investigational Dermatology

Dovepress

### Publish your work in this journal

Clinical, Cosmetic and Investigational Dermatology is an international, peer-reviewed, open access, online journal that focuses on the latest clinical and experimental research in all aspects of skin disease and cosmetic interventions. This journal is indexed on CAS. The manuscript management system is completely online and includes a very quick and fair peer-review system, which is all easy to use. Visit <http://www.dovepress.com/testimonials.php> to read real quotes from published authors.

Submit your manuscript here: <https://www.dovepress.com/clinical-cosmetic-and-investigational-dermatology-journal>