

# Cogan's Syndrome Combined with Hypertrophic Pachymeningitis: A Case Report

Ci Lu<sup>1,\*</sup>, Panpan Lv<sup>2,\*</sup>, Xiaoying Zhu<sup>1</sup>, Yongmei Han<sup>1</sup>

<sup>1</sup>Department of Rheumatology, Sir Run Run Shaw Hospital, Zhejiang University School of Medicine, Hangzhou, People's Republic of China;

<sup>2</sup>Department of Ultrasound, Sir Run Run Shaw Hospital, Zhejiang University School of Medicine, Hangzhou, People's Republic of China

\*These authors contributed equally to this work

Correspondence: Xiaoying Zhu; Yongmei Han, Department of Rheumatology, Sir Run Run Shaw Hospital, Zhejiang University School of Medicine, 3# Qingchun East Road, Hangzhou, 310016, People's Republic of China, Email 3202091@zju.edu.cn; 3408235@zju.edu.cn

**Abstract:** Cogan's syndrome (CS) is a rare chronic inflammatory disease, characterized by interstitial keratitis and vestibular auditory dysfunction. Hypertrophic pachymeningitis (HP) is a rare chronic aseptic inflammatory disease of the central nervous system. This article reports a patient with CS coexisting with HP. The patient was a 66-year-old male with fever, headache, red eyes, hearing loss, and significantly elevated inflammatory markers. Cerebrospinal fluid examination, blood culture, and tests for autoantibodies such as antinuclear antibodies were negative. Pure tone audiology (PTA) indicated bilateral sensorineural deafness. Both Positron emission tomography-computed tomography (PET/CT) and vascular color Doppler ultrasound suggest the presence of vasculitis. Considering Cogan's syndrome, the patient received 40 mg of methylprednisolone intravenously once daily. The brain's magnetic resonance imaging (MRI) revealed slightly thickened and enhanced dura mater, suggesting HP. The dose of methylprednisolone was increased to 40 mg intravenously every 8 hours, leading to the patient's improved symptoms and decreased inflammatory markers. Both CS and HP are rare chronic inflammatory diseases, and their coexistence is even rarer, with only two reported cases in literature up to date. The coexistence of CS and HP should be considered when the CS patients with headaches do not respond well to treatment.

**Keywords:** Cogan's syndrome, hypertrophic pachymeningitis, vasculitis

## Introduction

Cogan's syndrome (CS) is a rare chronic inflammatory disease characterized by eye and vestibuloauditory dysfunction. The most common ocular manifestation of CS is interstitial keratitis. But it may also present itself with conjunctivitis, iridocyclitis, scleritis, retinal vasculitis, etc. Vestibuloauditory dysfunction mainly manifests as Ménière's-like attacks, including dizziness, ataxia, and hearing loss. CS may also involve systemic vasculitis, among which aortic inflammation is the most common.<sup>1</sup> It can be divided into typical CS (the interval between the onset of ocular and audiovestibular manifestations is less than 2 years) and atypical CS (the interval between the onset of typical ocular and audiovestibular manifestations is more than 2 years).

Hypertrophic pachymeningitis (HP) is a chronic non-infectious inflammatory disease characterized by thickening of the dura mater. It is divided into two major categories: idiopathic and secondary. Secondary HP can occur in various diseases, such as infections (such as neurosyphilis or fungal meningitis), inflammatory diseases (IgG4-related diseases, ANCA-associated vasculitis), and tumors (such as dural metastases and meningiomas).<sup>2</sup>

The incidence of CS or HP is low, and their simultaneous occurrence is even rarer. So far, only two case reports have been published.<sup>3,4</sup>

## Case Report

The 66-year-old male patient was admitted to the hospital in January 2022 with a chief complaint of "recurrent fever and headache for more than a month". One month before admission, the patient experienced headaches, nasal congestion, and fatigue. After that, he developed a fever with a temperature of around 38.5°C, accompanied by mild cough with a small

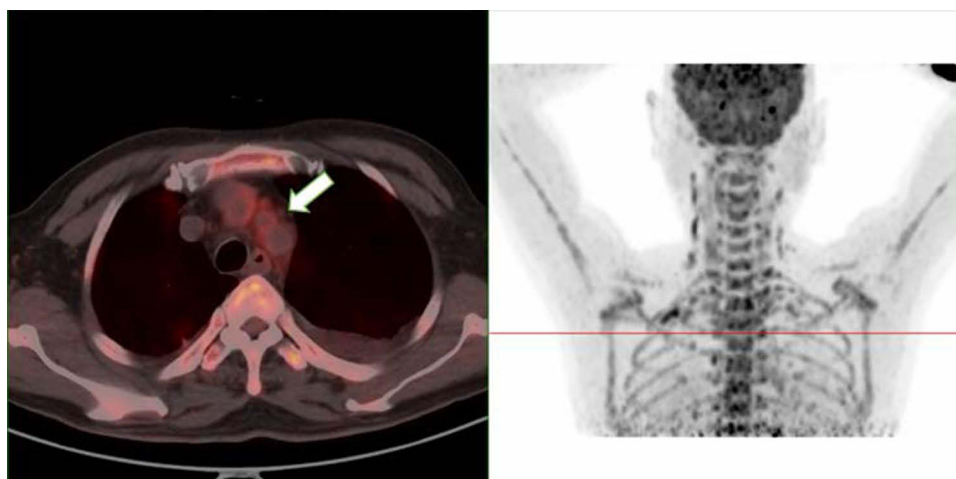
amount of white sticky phlegm. Additionally, the patient had bilateral eyelid edema, redness, and blurry vision. About a week later, tinnitus with hearing loss was worse than before. The patient's C-reactive protein (CRP) level increased progressively (46–63.4–141–146mg/L). In the meanwhile, blood culture, sputum culture, and cerebrospinal fluid tests were all normal. The patient was treated with levofloxacin, moxifloxacin, piperacillin/tazobactam, and imipenem/cilastatin without improvement. The patient had a history of stroke 5 years ago, hypertension for 2 years, and diabetes for 1 month. No family or genetic history.

Physical examination showed conjunctival congestion and swelling in both eyes. Several enlarged lymph nodes with slightly hard textures were palpable on both sides of the neck, which were mobile and non-tender. No other enlarged superficial lymph nodes were found. The heart and lungs were normal, and no abnormalities were detected in the abdomen or joints.

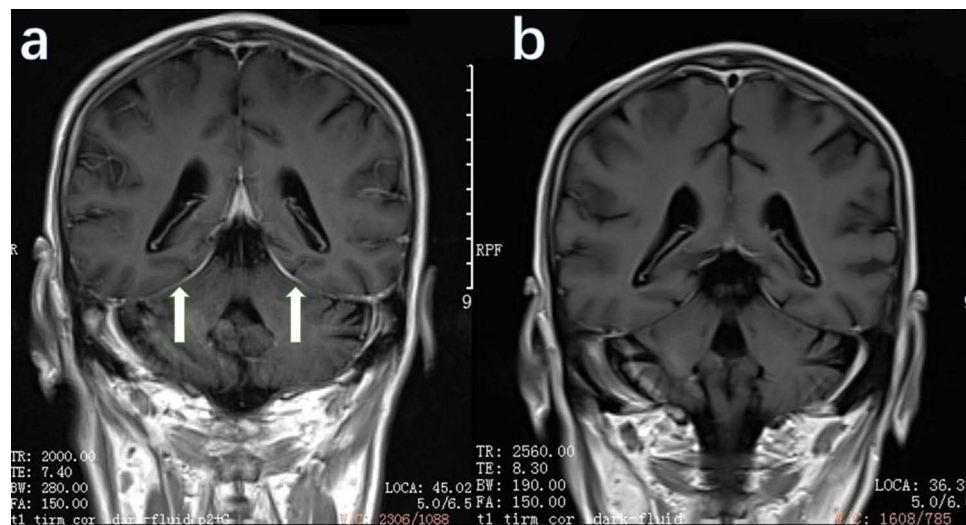
Laboratory examination showed a white blood cell count of  $16.9 \times 10^9/L$ , red blood cell count of  $3.49 \times 10^{12}/L$ , hemoglobin 96g/L, platelet count  $440 \times 10^9/L$ , hematocrit 28.8%, neutrophil percentage 78.6%, C-reactive protein 159.3mg/L, procalcitonin 0.92ng/mL, erythrocyte sedimentation rate (ESR) 111mm/hr, ferritin  $>2000 \mu g/L$ . G test, Phosphatidyl ethanolamine, T.SPOT-TB, Brucella antibody, as well as hepatitis B, hepatitis C, syphilis, and HIV antibodies were all negative. The blood culture in both bottles showed no bacterial growth. CA125, CA19-9, AFP, and CEA were normal. Rheumatoid factors, ANA, ANCA, ACE, immunoglobulins, and complement, were all negative.

Imaging examinations showed slight thickening and enhancement of the dura mater in the MRI of head. PET/CT revealed mild heterogeneous FDG uptake with increased metabolism in the wall of the aortic arch, right brachiocephalic trunk, left common carotid artery, and the starting segment of the left subclavian artery, suggesting vasculitis (Figure 1). Vascular ultrasound demonstrated local thickening of the walls of both common carotid arteries and superior thyroid arteries, indicating arterial inflammation. Pure tone audiometry (PTA) showed sensorineural hearing loss in both ears.

The patient was admitted to the department of rheumatology on January 13, 2022. From these findings, he was diagnosed as CS. Treatment with intravenous methylprednisolone 40mg once a day was initiated, along with gastric protection and calcium supplementation. The patient's body temperature, headache, and hearing were improved, but on the night of January 16, 2022, the headache reoccurred at 12:00 AM and was unbearable, with no fever or chills. Hearing loss accompanied with headache, but without apparent visual blurring. On the afternoon of January 18, 2022, the patient had a body temperature of  $38^\circ C$  which improved after receiving one dose of intravenous methylprednisolone 40mg. The patient began to experience continuous headache at 5:00 AM on January 19, 2022. MRI-enhanced scanning of the patient's head indicated thickening and enhancement of the dura mater, suggesting the possibility of HP (Figure 2a). The methylprednisolone dose was increased to 40mg every 8 hours. The patient's headache, and body temperature significantly improved. Re-examination of ESR and CRP showed a significant decrease. The methylprednisolone was gradually reduced, and immunosuppressive therapy with methotrexate 15mg orally once a week was added.



**Figure 1** PET/CT showing FDG metabolism is mildly increased with uneven distribution in the walls of the right head and arm, left common carotid artery, and the starting segment of the left subclavian artery.



**Figure 2** Gadolinium-enhanced coronal T1-weighted MRI of the brain. (a) Pre-treatment MRI showing pachymeningial thickening and enhancement along the cerebellar tentorium (arrows). (b) Post-treatment MRI showing improvement of thickness and reduced enhancement along the cerebellar tentorium.

## Discussion

CS is a rare autoimmune disease, characterized by non-syphilitic interstitial keratitis and vestibuloauditory dysfunction. In 1934, Morgan and Baumgartner first described the disease as interstitial keratitis associated with vestibuloauditory dysfunction. In 1945, Cogan described four cases of interstitial keratitis with vestibuloauditory dysfunction, naming the disease Cogan's syndrome.<sup>5</sup> Two extensive case series studies have shown that the median age of onset for CS is 22 years (5–63 years).<sup>6</sup> It can also occur in children and elderly people, without gender or racial differences observed.

CS syndrome mainly affects the eyes, causing non-syphilitic interstitial keratitis characterized by redness, pain, photophobia, and blurred vision. Other ocular inflammations, such as iridocyclitis, conjunctivitis, superficial keratitis, anterior uveitis, posterior uveitis, or retinal vasculitis, can also occur. The vestibuloauditory impairment in CS mainly manifests as Meniere's-like attacks, including dizziness, ataxia, nausea, vomiting, tinnitus, and hearing loss, which may also cause oscillopsia. Audiometry results show sensorineural hearing loss, with predominant low and high-frequency hearing loss. Poor speech recognition may also occur. About 70% of CS patients have non-specific systemic manifestations such as fever, fatigue, and weight loss, while 10% may experience vasculitis.<sup>7</sup> CS is classified as variable-vessel vasculitis in the 2012 International Chapel Hill classification of vasculitis,<sup>8</sup> presenting as large, medium, or small vessel vasculitis or aortitis. The patient, in this case, was affected by large vessel vasculitis involving the aortic arch, the right brachiocephalic trunk, the left common carotid artery, and the left subclavian artery.

The etiology of CS is still unclear. Although there are no specific laboratory tests, CS is usually accompanied with an increase in ESR and CRP. Multiple studies have found antibodies against corneal antigens or inner ear components in patients with CS.<sup>9</sup> Hsp-70 antibodies have been found in some CS patients.<sup>10</sup> Very few of patients may have positive rheumatoid factor, anti-neutrophil cytoplasmic antibodies, and anti-nuclear antibody spectra.<sup>11</sup> Currently, there are only 300 literatures related to CS, most of which are case reports or case series. The diagnosis of CS mainly relies on its characteristic clinical manifestations and the exclusion of other diseases, such as viral infection, tuberculosis, Wegener's granulomatosis with polyangiitis, Behçet, Vogt–Koyanagi–Harada and malignant disease.<sup>7,12</sup> The patient had conjunctival congestion in both eyes, bilateral sensorineural hearing loss, and large vessel vasculitis, with no evidence of infection and malignancy. Therefore, the diagnosis of CS was established.

8–10% of patients with CS have other autoimmune diseases, such as sarcoidosis, giant cell arteritis, takayasu arteritis, and granulomatosis with polyangiitis.<sup>9</sup> Among them, there were only two case reports of CS coexisting with HP. The first case was reported by Togashi et al.<sup>4</sup> The patient was a 63-year-old male who presented with chronic headache, bilateral hearing loss, and bilateral conjunctivitis. The patient tested positive for anti-Cogan's peptide antibodies and was diagnosed with CS. During the steroid tapering process, the patient developed headache, and cranial MRI showed

thickening and enhancement of the tentorium cerebelli, indicating of HP. After receiving steroid pulse therapy, patient's symptom relieved. The second case was reported by Kawamura et al.<sup>3</sup> The patient was a 55-year-old female with a history of *Listeria* meningitis and HP. She later developed bilateral sensorineural hearing loss, vertigo, uveitis, and aortic arteritis, and was diagnosed with CS. Despite of receiving treatment with corticosteroids and methotrexate, the patient developed severe hearing loss in both ears within one year and eventually received a left cochlear implant.

HP can be divided into secondary and idiopathic types. The secondary HP is more commonly associated with ANCA-associated vasculitis and IgG4-related disease. In this case, the diagnosis of CS was confirmed. However, the patient's symptoms worsened after several days of steroid treatment. Enhanced cranial MRI showed enhancement of the dura mater, which is consistent with HP. The patient's symptoms improved after increasing the steroid dosage. Followed cranial MRI also showed improvement compared to the previous exam (Figure 2b), further supporting the diagnosis of HP in this patient.

The main treatment for CS is a combination of glucocorticoids and immunosuppressive agents, with a typical dose of prednisone at 1mg/(kg·d). Cyclophosphamide, methotrexate, cyclosporine, mycophenolate mofetil, and azathioprine are the available immunosuppressive agents. Studies have signified that TNF antagonists, IL-6 antagonists and Janus kinase inhibitor are effective for some patients.<sup>9,13,14</sup>

HP associated with autoimmune diseases can be treated with glucocorticoids and immunosuppressive agents, often requiring glucocorticoid pulse therapy.<sup>15</sup> The doses and duration of glucocorticoid therapy are highly empirical.<sup>2</sup> Immunosuppressants, such as cyclophosphamide, methotrexate, azathioprine, and mycophenolate mofetil have been used. This also explains why the patient's condition worsened during treatment and improved after an increase in steroid dose.

## Conclusion

CS and HP are both rare chronic inflammatory diseases, and their coexistence is even rarer. This case reports is the third case of their coexistence. When Cogan's syndrome patients present with headaches have poor treatment outcomes, the possibility of coexisting HP should be considered.

## Data Sharing Statement

The data and materials used and/or analyzed during the current study are available from the corresponding author on reasonable request.

## Ethics Approval and Consent to Participate

Ethical approval is not necessary because this is a case report based on the clinical data during the patient's hospitalization other than research and/or experiment. The patient has given his consent and authorized his clinical data in our report and signed the Patient Consent Form.

## Consent for Publication

The patient has given his consent and authorized his clinical data in our report to be published.

## Acknowledgments

The authors thank the patient for their commitment to this research.

## Author Contributions

All authors made a significant contribution to the work reported, whether that is in the conception, study design, execution, acquisition of data, analysis and interpretation, or in all these areas; took part in drafting, revising or critically reviewing the article; gave final approval of the version to be published; have agreed on the journal to which the article has been submitted; and agree to be accountable for all aspects of the work.

## Funding

This work was supported by Grants from the Educational Commission of Zhejiang Province (No. Y201941232).

## Disclosure

The authors declare that there is no conflict of interest.

## References

1. Espinoza GM, Wheeler J, Temprano KK, Keller AP. Cogan's syndrome: clinical presentations and update on treatment. *Curr Allergy Asthma Rep.* 2020;20(9). doi:10.1007/s11882-020-00945-1
2. Kupersmith MJ, Martin V, Heller G, Shah A, Mitnick HJ. Idiopathic hypertrophic pachymeningitis. *Neurology.* 2004;62(5):686–694. PubMed PMID: 15007115. doi:10.1212/01.wnl.0000113748.53023.b7
3. Kawamura S, Sakamoto T, Kashio A, et al. Cochlear implantation in a patient with atypical Cogan's syndrome complicated with hypertrophic cranial pachymeningitis. *Auris Nasus Larynx.* 2010;37(6):737–741. PubMed PMID: 20576375. doi:10.1016/j.anl.2010.04.005
4. Togashi M, Komatsuda A, Masai R, et al. Hypertrophic cranial pachymeningitis in a patient with Cogan's syndrome. *Clin Rheumatol.* 2008;27 (Suppl 1):S33–S35. PubMed PMID: 18219435. doi:10.1007/s10067-008-0841-0
5. Cogan DG. Syndrome of nonsyphilitic interstitial keratitis and vestibuloauditory symptoms. *Arch Ophthalmol.* 1945;33(2):144–149. doi:10.1001/archophth.1945.00890140064007
6. Haynes BF, Kaiser-Kupfer MI, Mason P, Fauci AS. Cogan syndrome: studies in thirteen patients, long-term follow-up, and a review of the literature. *Medicine.* 1980;59(6):426–441. PubMed PMID: 6969345. doi:10.1097/00005792-198011000-00003
7. Gluth MB, Baratz KH, Matteson EL, Driscoll CL. Cogan syndrome: a retrospective review of 60 patients throughout a half century. *Mayo Clin Proc.* 2006;81(4):483–488. PubMed PMID: 16610568. doi:10.4065/81.4.483
8. Jennette JC. Overview of the 2012 revised International Chapel Hill Consensus Conference nomenclature of vasculitides. *Clin Exp Nephrol.* 2013;17(5):603–606. PubMed PMID: 24072416; PubMed Central PMCID: PMC4029362. doi:10.1007/s10157-013-0869-6
9. Garcia Berrocal JR, Vargas JA, Vaquero M, Ramon Y, Cajal S, Ramirez-Camacho RA. Cogan's syndrome: an oculo-audiovestibular disease. *Postgrad Med J.* 1999;75(883):262–264. PubMed PMID: 10533627; PubMed Central PMCID: PMC1741234. doi:10.1136/pgmj.75.883.262
10. Bonaguri C, Orsoni JG, Zavota L, et al. Anti-68 kDa antibodies in autoimmune sensorineural hearing loss: are these autoantibodies really a diagnostic tool? *Autoimmunity.* 2007;40(1):73–78. PubMed PMID: 17364500. doi:10.1080/08916930601119377
11. Vollertsen RS. Vasculitis and Cogan's syndrome. *Rheum Dis Clin North Am.* 1990;16(2):433–439. PubMed PMID: 2189159. doi:10.1016/S0889-857X(21)01068-1
12. Durtette C, Hachulla E, Resche-Rigon M, et al. Cogan syndrome: characteristics, outcome and treatment in a French nationwide retrospective study and literature review. *Autoimmun Rev.* 2017;16(12):1219–1223. PubMed PMID: 29037902. doi:10.1016/j.autrev.2017.10.005
13. Higashida-Konishi M, Akiyama M, Tabata H, et al. Atypical Cogan's syndrome with large-vessel vasculitis successfully treated with tocilizumab. *Intern Med.* 2023;62(22):3413–3417. PubMed PMID: 37032081. doi:10.2169/internalmedicine.1561-23
14. Wang Y, Tang S, Shao C, Liu Y. Cogan's syndrome is more than just keratitis: a case-based literature review. *BMC Ophthalmol.* 2023;23(1):212. PubMed PMID: 37173630; PubMed Central PMCID: PMC10176949. doi:10.1186/s12886-023-02966-6
15. Yao Y, Xu Y, Li X, et al. Clinical, imaging features and treatment response of idiopathic hypertrophic pachymeningitis. *Mult Scler Relat Disord.* 2022;66:104026. PubMed PMID: 35868153. doi:10.1016/j.msard.2022.104026

Journal of Inflammation Research

Dovepress

### Publish your work in this journal

The Journal of Inflammation Research is an international, peer-reviewed open-access journal that welcomes laboratory and clinical findings on the molecular basis, cell biology and pharmacology of inflammation including original research, reviews, symposium reports, hypothesis formation and commentaries on: acute/chronic inflammation; mediators of inflammation; cellular processes; molecular mechanisms; pharmacology and novel anti-inflammatory drugs; clinical conditions involving inflammation. The manuscript management system is completely online and includes a very quick and fair peer-review system. Visit <http://www.dovepress.com/testimonials.php> to read real quotes from published authors.

Submit your manuscript here: <https://www.dovepress.com/journal-of-inflammation-research-journal>