

The Anatomical Layering Assessment: The Construction of Beauty

Carla de Sanctis Pecora 

Dermatologie Private Practice, São Paulo, Brazil

Correspondence: Carla de Sanctis Pecora, Dermatologie Private Practice, Avenida Dr. Cardoso de Melo, 1308, conj 121, São Paulo, 04548-004, Brazil, Tel +5511 99621-9162, Email carla@dermatologie.com.br

Abstract: Restructuring an aging face from bone structure to the surface of the skin can be metaphorically compared to building and renovating a house. While each anatomical layer of the face undergoes an aging process of its own, there is also an interdependency of superficial structures on deeper layers, so that a change in one layer may lead to changes to the adjacent layers. This interaction among the structures deep into the skin, along with the skin's ability to envelope them is what determine the aspect of the aging face. Thus, a careful assessment of all the layers is imperative and we describe herein a step-by-step facial layering assessment and facial restructuring approach from bone structure to the surface of the skin to implement a treatment plan able to deliver a harmonious rejuvenating outcome.

Keywords: layers, assessment, anatomy, aging process, combined treatment

Introduction

From superficial to deep tissues, aging is observed in all facial structures: Reduction of collagen and elastin content of the skin is attributable to a decrease in synthesis and excessive breakdown by up-regulated matrix metalloproteinases (MMPs).¹ Some superficial fat pads, such as the nasolabial superficial fat pad, tend to suffer repositioning or hypertrophy,²⁻⁴ while deep fat pockets undergo atrophy. Some muscles may become stronger due to a lifetime of over-activation (eg procerus),⁵ so that the muscle contraction that has folded the skin along the same area repetitively, lead a temporary wrinkle to convert to a persistent wrinkle.⁶ Moreover, for some muscles, the resting tone increases, and therefore the amplitude between contracted and relaxed muscle decreases,⁷ while muscle tone may decrease for other muscles.⁴ Ligaments may present altered mechanical function secondary to changes in structures where they are inserted (eg, bone, skin).^{4,5,8-10} Bone may suffer either remodeling (eg, expansion of the supraorbital ridges) or resorption; the latter observed for instance in the anterior and inferior aspects of the maxilla, leading to retrusion of the face.^{8,11,12} Moreover, the onset, degree of involvement and the speed of onset of age-related changes differ depending not only on each layer but also individual characteristics (eg, genetic, ethnical background).⁴

While each anatomical layer of the face undergoes an aging process of its own, there is also an interdependency of superficial structures on deeper layers, so that a change in one layer may lead to changes to the adjacent layers.^{2,8} For instance, the bony components of the face impact the overall facial 3D contour because they provide the framework upon which the soft-tissue envelope rests.¹² Individuals with strong skeletal structure—bony features that provide good support to the overlying soft tissues age better than others with poor facial skeletal support.⁹ This interplay of the structures deep into the skin along with skin's ability to envelope them is what determine the aspect of the aging face. Thus, a careful assessment of all the layers is imperative and we describe herein a step-by-step facial layering assessment and facial restructuring approach from bone structure to the surface of the skin to implement a treatment plan able to deliver a harmonious rejuvenating outcome.

Materials and Methods

All procedures performed in this report involving human patients were in accordance with the ethical standards of the institutional and/or national research committee and with the 1964 Helsinki declaration and its later amendments.

Ethics Approval

The report was approved by a centralized institutional review board (Hospital e Centro de Reabilitação da Associação de Assistência à criança Deficiente (AACD) number: 73,808,223.5.0000.0085, approval date: September 26th 2023). Written informed consent has been provided by all the patients to have the case details and any accompanying images published.

We report 5 cases of facial layering assessment and approach with hyaluronic acid (CPM-HA; Belotero[®] range; Cohesive poly-densified matrix hyaluronic acid; Merz Pharmaceuticals GmbH, Frankfurt, Germany), Microfocused ultrasound with visualization (MFU-V; Ultherapy[®] (Merz North America, Inc., Raleigh, North Carolina)), undiluted calcium hydroxylapatite with 0.3% powdered lidocaine hydrochloride (CaHA (+); Radiesse Plus[®]; Merz Pharmaceuticals GmbH, Frankfurt, Germany), diluted calcium hydroxylapatite (CaHA; Radiesse[®]; Merz Pharmaceuticals GmbH, Frankfurt, Germany), and Incobotulinum toxin (INCO; Xeomin[®], Merz Pharmaceuticals GmbH, Frankfurt, Germany). Eligible patients were men or women, between 18 and 65 years of age, with normal Body Mass Index (BMI: 18.5–24.9), mild facial laxity, who sought facial rejuvenation and agreed to participate in the study. Exclusion criteria included previous facial surgery, use of fillers or biostimulators within the last 12 months, presence of acne scars and/or use of hormonal therapy.

Photographs were taken at baseline, 1 month after INCO injection, and after a follow-up interval of at least 90 days after the procedure. Three-dimensional photographs (3D) were also taken with a digital camera (Vectra Software, Canfield, NJ, USA).

Clinical efficacy was evaluated by the investigator and an independent evaluator comparing pre and 90-day post treatment images using the Global Aesthetic Improvement Scale (GAIS). The 5-point scale ranging from 0 (much worse) to 4 (much improved) rates global aesthetic improvement in post-treatment appearance compared with pre-treatment. Moreover, a more detailed analysis of the results was performed by 2 independent blinded physicians comparing pre and 90-day post-treatment images with the following 5-point scales (0-no, 1-mild, 2-moderate, 3-severe, and 4-very severe): Scientific Assessment Scale of Skin Quality (SASSQ), a global photonumeric scale for aged skin to evaluate skin laxity and wrinkles at rest,¹³ Merz Aesthetic Scale for Upper Cheek and Lower Cheek Fullness,¹⁴ to evaluate upper cheek and lower cheek fullness and Validated assessment scales for the lower face for Jawline evaluation.¹⁵

Baseline and post 30-day images were evaluated for dynamic wrinkles, using the previously validated Merz Aesthetic Scale for Forehead,¹⁶ Glabellar,¹⁷ Crow's Feet Dynamic Lines.¹⁸

Facial Assessment Protocol

Restructuring an aging face from bone structure to the surface of the skin can be metaphorically compared to renovating a house. A solid construction requires a well-structured and strong foundation (bone-structure), as well as an adequate framing (ligaments and muscles) to guarantee stability.

Step I: Foundation and Support (Bone and Retaining Ligaments)

Since bone structure provides the underlying support for the face, when the bone density decreases secondary to aging, changes in facial contours, such as sagging, or loss of contour are observed. Strong skeletal features provide good support to the overlying soft tissue, being related to delayed clinical manifestation of age-related bone loss, whereas subjects with poor facial skeletal support are more prone to premature manifestations of aging.⁹ The process of bone remodeling occurs throughout life, being the equilibrium dynamic according to the period of life and in response to demand.¹² When the bone is submitted to traction (eg, a hypertrophic muscle or subcutaneous fat distension of the ligaments), a local demand is generated, and bone is produced in that area. On the other hand, continuous pressure on the bone (eg, due to silicon prosthesis) or lack of mechanical stress (eg, secondary to intense muscle atrophy, ligament or skin laxity) may lead to bone resorption.^{19,20} Sites identified as areas prone to bone resorption in the facial skeleton correspond to the more

mobile part of the face during animation. It was speculated that since the mobility required for the function of these regions needs to be structurally associated with a less ligamentous fixation of the soft tissues to the bone, these areas would be attended by less stress.¹¹ Restoring this foundation is like repairing the structural integrity of a house. Thus, the first step would be to recognize each area that requires replacement of bone support. Once the areas are marked, if the objective is to create structural support with projection, injection with a filler with high modulus E' (elastic module in compression; ability to resist dynamic compression), high G' prime (Elastic module in shear stress; ability to recover shape after shear deformation) and high Force normal (F_n ; ability to maintain tissue projection) is indicated to mimic the bone support (HAI; Belotero Intense[®]; Cohesive poly-densified matrix hyaluronic acid; Merz Pharmaceuticals GmbH, Frankfurt, Germany).²¹ Both high elastic moduli G' and E' reflect the capability of a filler to withstand mechanical stress, while the higher the F_n , the higher the ability to project skin tissues.²¹ When the goal is to create support with focal biostimulation, CaHA (+) (Radiesse Plus[®]; Merz Pharmaceuticals GmbH, Frankfurt, Germany), a product with high G' prime can be used instead.

Depending on the area where structural support is needed, the injection can be performed in bolus with needle or cannula (eg, zygomatic arch), or as linear retrograde injection with cannula (eg, supraorbital; Figure 1).

The retaining ligaments of the face are strong and deep fibrous attachments which originate from the periosteum or deep fascia and act as anchor points to stabilize the superficial soft tissues (skin and SMAS) to the underlying deep tissues (ie, fascia and facial skeleton).

As in any construction, foundation and structure are closely related. An example of interdependency between bone and ligaments, the reduced muscle tension results in less stress to the bone structure contributing to the acceleration of its resorption,⁹ while the retrusion of the periosteum of the reabsorbed bone areas leads to altered location of the attachments of facial ligaments, thus modifying the mechanics of these latter.¹¹ Therefore, it is of paramount importance to maintain the integrity of the deep fibrous structures (eg, the retaining ligaments), akin to reinforcing the framework of a house to ensure stability, preventing, or reducing bone remodeling.

With aging, these tissues can weaken, leading to a change in soft-tissue positioning, clinically translated as the appearance of sulci. As part of the first step, identification of static grooves/sulci indicating the reduction or lack of support of the retaining ligaments should be performed. Injections of 0.2mL boluses of high elasticity and high G' prime HAI deep below the ligaments, in the supraperiosteal plane, can provide further support for the retaining ligaments (Figure 1).

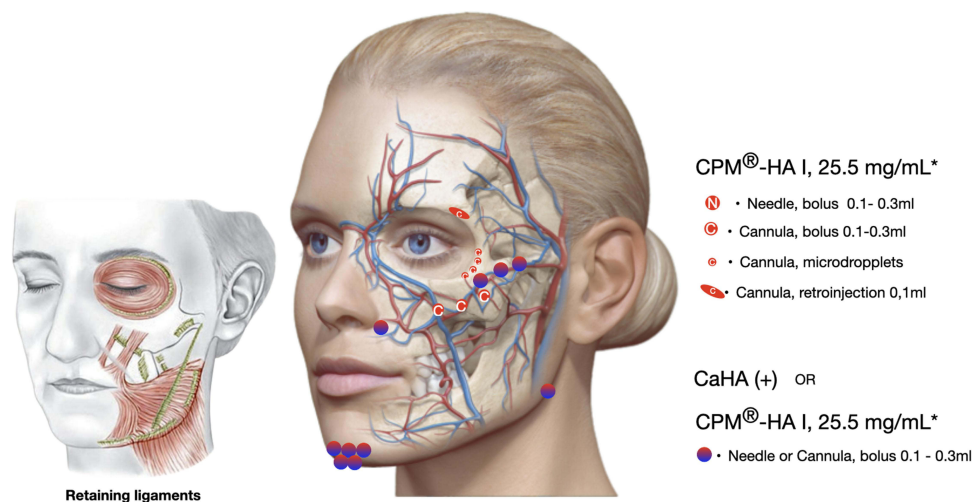


Figure 1 Step 1: Foundation and support: Supraperiosteal injection points, volumes, and technique. *The use of CPM®-HA I, 25.5 mg/mL or CaHA (+) following the figure scheme for bone support and structuring is the author's choice. While injecting CaHA (+), patient's capacity to respond to biostimulation must be taken into consideration. (Image partially reproduced from Merz Institute Advanced Aesthetics platform-www.merz-institute.com).

Step 2: Structure and Framing (Muscles, Ligaments, and Superficial Muscular Aponeurotic System (SMAS))

Like the framing of a house, muscles, ligaments, and superficial muscular aponeurotic system (SMAS) give support to the face, maintaining it balanced and cohesive. Each retaining ligament originates from the periosteum or deep facial fascia, rooted in a tree-like distribution, travel through the facial layers, branching as it approaches the SMAS and insert into the dermis. This branched network is known as retinacular cutis.²² Retaining ligaments and the subcutaneous fibrous septa (including reticular cutis) create zones of adhesion that divide the face into superficial and deep fat compartments. Facial mimetic muscles also insert into the dermis, thus playing an important role in both the suspension and structural integrity of the soft tissue envelope, thereby affecting the volume and contour of the region.

Therefore, reinforcement of the SMAS and the reticular dermis' fibrous structures, as well as increased collagen content of the deep dermis are paramount to provide support to the facial structure. This can be performed with Microfocused ultrasound with visualization (MFU-V; Ultherapy® (Merz North America, Inc., Raleigh, North Carolina; Figure 2). MFU-V delivers energy (0.4–1.2 J/mm²) to three different depths (1.5mm, 3.0mm, and 4.5mm), to heat target tissues from the superficial skin to the SMAS, creating inverted cone-shaped microthermal 1 mm³ lesions in the dermis and subdermis, without damaging the overlying papillary dermal and subdermal layers. A distinctive feature of MFU-V is its real-time viewing capability up to 8.0mm as it incorporates a high-resolution ultrasound imager, which allows users to simultaneously “see and treat” different tissue layers including SMAS, subcutaneous fat, dermis, and epidermis. The patented DeepSEE® technology enables users to noninvasively “see” through the skin to ensure treatment precision and enhance safety.

A recent consensus recommends tailoring MFU-V treatments to each patient (“See-Plan-Treat”), developing a personalized tissue targeting strategy for MFU delivery (treatment areas, energy, plane of treatment, number of lines).²³ Moreover, dual-depth treatments, targeting the superficial fascial/SMAS and deep dermal layers produce superior results. If possible, schedule each procedure 1–2 weeks apart to allow for resolution of local side effects and/or to assess the results, but if performed on the same day, MFU-V should be performed before injectable agents.²⁴

Step 3: Walls (Fat)

On top of a strong and structured foundation, the walls (fat pads) give shape to the house and support the roof (dermis). The subcutaneous fat act as the walls and insulation of the face. Fat pad repositioning tends to occur due to bony remodeling, weakening of the supporting ligaments and gravity, leading to an infero-medial displacement of the overlying skin envelope, clinically translated into increased hollowing in the cheeks and temple, as well as flattening of the angles of the face.^{2,8,9}

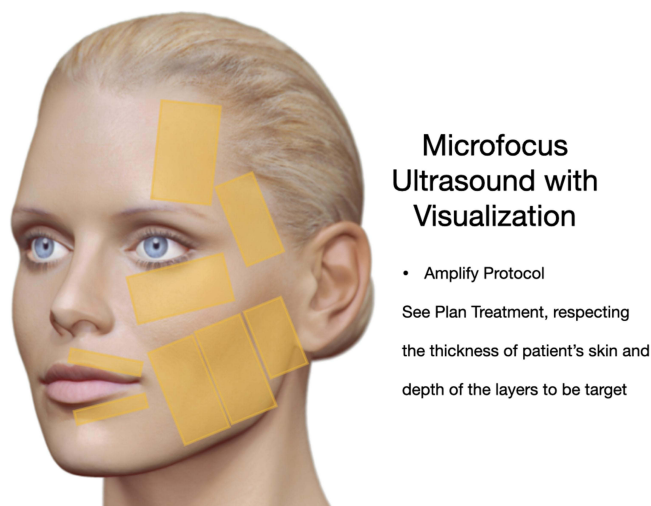


Figure 2 Step 2: Structure and framing (reinforcement of the SMAS and the reticular dermis' fibrous structures). MFU-V treatment areas. Treatment should be tailored to patient's needs. (Image partially reproduced from Merz Institute Advanced Aesthetics platform-www.merz-institute.com).

Deep fat is immobile because it is firmly anchored to the underlying bone and helps to provide contour, support of overlying fat compartments, and a gliding plane for muscle movement.^{2,8} The superficial fat compartments are more mobile and are subject to both the resting and dynamic tension of the mimetic muscles.

The third step in the layering process would be identification of all areas with volume loss, establishing which ones are secondary to tissue displacement and/or deflation, and if the change occurred within the superficial or the deep fat compartments. Restoring volume to the superficial fat compartment causes the cheek skin and cutaneous ligaments to plump up, whereas supraperiosteal injections of volumizing fillers placed in the deep fat pads enhance structural support, acting like a pole that lifts a tent, stretching the ligaments and lowering the continuous bone remodeling. Moreover, deeper injections increase anterior projection, spare the amount of filler needed for superficial injection and help reestablishing a youthful facial contour.^{8,9} Thus, since structure should be secured to achieve a good construction, deep compartments should be approached first, with linear retrograde injection in the deep medial cheek fat pad with 22G-25G cannula, using the fanning technique of a HA that has a balance between elasticity, G prime and cohesivity, integrating homogeneously in the tissue (HAV; Belotero Volume[®]; Cohesive poly-densified matrix hyaluronic acid; Merz Pharmaceuticals GmbH, Frankfurt, Germany; Step 3A; Figure 3A). If needed, superficial fat compartment injection can be performed thereafter with linear retrograde injection with cannula in the temporal part of the latero-temporal cheek compartment with HAV or HAB, being the choice related to the degree of the atrophy, and bolus injection with cannula with HAI in the lateral cheek fat to further improve soft-tissue repositioning (Step 3B; Figure 3B).

Step 4: Exterior of the House (Dermis / Scaffold)

Restoring the skin's health and appearance is like renovating the exterior of a house. After all the structural part is concluded, the improvement of the surface (skin surface) is put into practice. Just as the roof and the exterior of the house, the skin act as an envelope protecting inner structures from environmental damage. The resilience of the skin resides primarily in the dermis, since this layer is composed of collagen that contributes to the bulk and strength of the skin, elastin that fosters elasticity, and glycosaminoglycans that play a key role in skin hydration. In healthy, youthful skin, elastic bundles bound to a core create a network in the extracellular matrix that allows skin to stretch and spring back when relaxed.^{2,9} With the aging process, not only the rate of collagen breakdown increases and rate of synthesis decreases, but also the collagen fibers in aged skin become disorganized, which further impairs the structural integrity of the dermis. Elastin biosynthesis declines steeply, the elastic fiber network disintegrates, and therefore, the skin loses elasticity and resilience and succumbs to the underlying pull of the mimetic muscles, manifesting as both static wrinkles and dynamic folds.² Water is lost as the hydroscopic glycosaminoglycans degrade.

Step 4A and B

In this setting, it makes sense to aim for regenerative biostimulation by fostering neocollagenesis and repair of the extracellular matrix,^{25,26} which can be achieved by either focal (undiluted CaHA; Step 4A; Figure 4A) stimulus for improvement of the facial frame or diffuse stimulus with CaHA to create a scaffold within the dermis (diluted; Step 4B; Figure 4B).

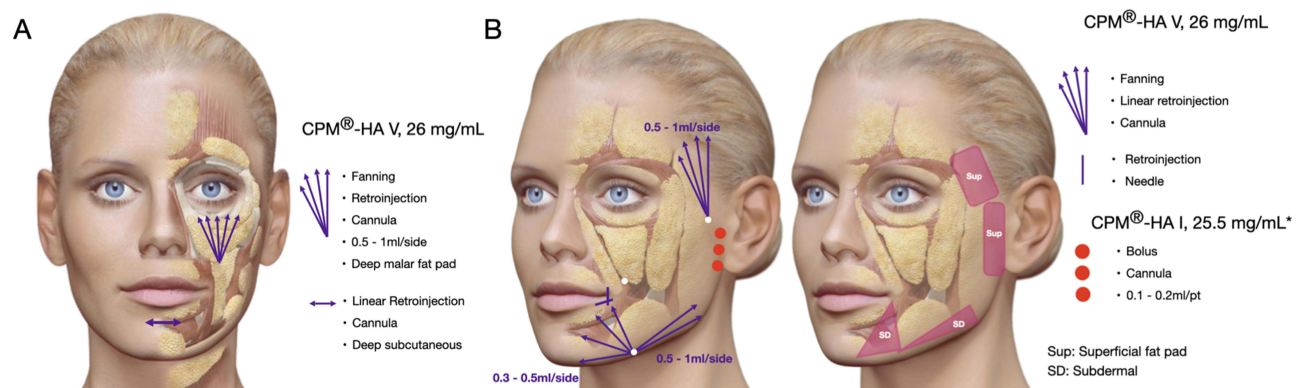


Figure 3 Step 3: Walls (Fat pad repositioning). Deep and superficial fat pad treatment: entry points, products, volumes, and technique. **(A)** Step 3A; Deep compartments should be approached first; **(B)** Step 3B; if needed, superficial fat compartment injection can be performed thereafter. *The use of CPM[®]-HA I, 25.5 mg/mL is the author's choice due to its projection capacity. The injection, instead, of CPM[®]-HA V, 26 mg/mL is also a good option. (Image partially reproduced from Merz Institute Advanced Aesthetics platform-www.merz-institute.com).

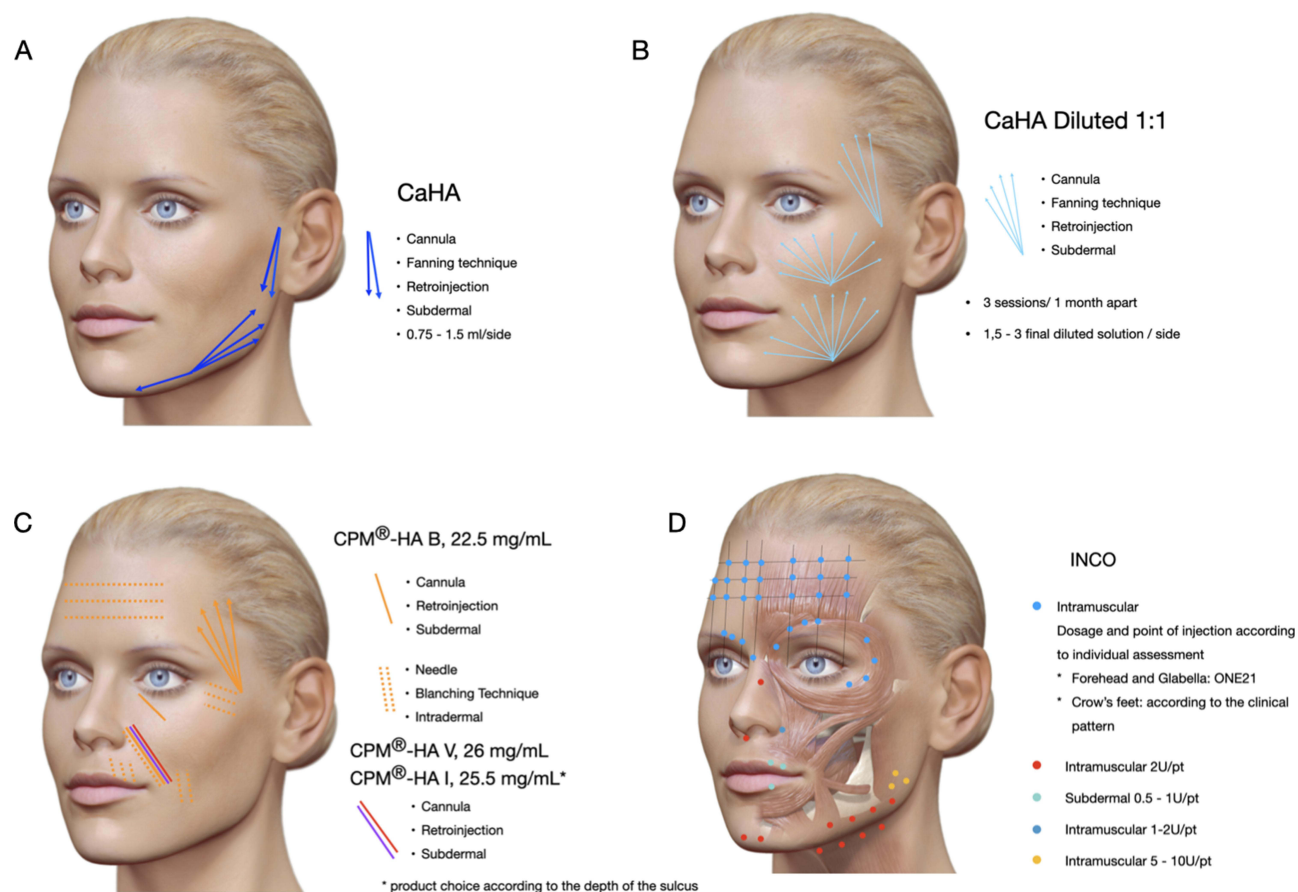


Figure 4 Step 4: Exterior of the house (Improvement of Dermis): entry points, products, volumes, and technique. **(A)** Step 4A; Focal dermal stimulus with undiluted stimulus for improvement of the facial frame. **(B)** Step 4B; Diffuse stimulus with diluted CaHA to create a scaffold within the dermis. **(C)** Step 4C; Targeted correction of a specific sulcus or groove. If the target is a superficial wrinkle, intradermal injection with HAB is indicated, whereas for a deeper sulcus HAI or HAV are indicated due to their high normal forces of compression to procure an optimal capacity of tissues projection. **(D)** Step 4D; Treatment of wrinkles related to unbalance of facial muscle expression. On the upper face, an assessment grid of 21 possible injection points can be delimited by the crossing of vertical lines (mid-pupillary lines, inner and outer canthus, and medial facial line) and functionally defined horizontal lines (lowest frown line, upmost line, intermediate line (ONE21 Technique)). *Product choice according to the depth of the sulcus. (Image partially reproduced from Merz Institute Advanced Aesthetics platform-www.merz-institute.com).

The CaHA injected in this study (CaHA; Radiesse®; Merz Pharmaceuticals GmbH, Frankfurt, Germany) contains 30% synthetic CaHA, in the form of uniform microspheres of 25 to 45 µm suspended in an aqueous matrix of 70% sodium carboxymethyl cellulose gel. Its gel component allows immediate and linear correction (1:1) of volume deficits after injection and is eventually reabsorbed. In its formulation without lidocaine, CaHA is used for diffuse biostimulation, and should be injected diluted in a saline solution and lidocaine in a 1:1 ratio.

A recent variant, CaHA(+) (CaHA (+); Radiesse Plus®; Merz Pharmaceuticals GmbH, Frankfurt, Germany) contains 0.3% whole lidocaine hydrochloride to improve pain control and is used for facial definition, contouring and focal biostimulation.²⁷ Upon injection, the particles induce a histiocytic and fibroblastic response, acting as a scaffold for new tissue formation and stimulating the synthesis of collagen and elastin around the implant for sustained aesthetic improvements. CaHA fosters dermal remodeling consistent with the physiological 2-step process of neocollagenesis, in which Type I collagen gradually replaces Type III collagen. The collagen synthesis starts 4 weeks after injection, with a peak approximately 4 months after injection, reaching stability in 9 months and observed up to 12–18 months.²⁸

Steps 4C and D

If after renovating the house, specific grooves, sulci and/or fine wrinkles remain, the targeted correction of a specific sulcus can be performed with the appropriate presentation of HA, according to the region and depth of the wrinkle (Steps 4C and 4D; Figure 4C and D).

If the target is a superficial wrinkle, dermal injection (ie, superficial administration) is indicated and thus a product with lower viscosities and optimal Fn to deliver intradermal projection such as HAB, (Figure 4C) enables optimal HA distribution/integration in this skin layer to treat fine lines or medium to deep-sized depressions of the skin. CPM technology enables intradermal injection with the blanching technique without Tyndall effect and nodule formation.²⁹ On the other hand, if a deeper sulcus, such as the nasolabial fold should be approached, HAI or HAV are indicated due to their high normal forces of compression to procure an optimal capacity of tissues projection. Moreover, for mobile areas, it is important to choose fillers with both high elastic moduli G' and E' , which translate into a powerful capacity to withstand the mechanical stress, and high viscosity with the essential purpose for the filler to move as one with the skin tissues and thus to provide more natural clinical outcomes, especially during dynamic expression of the face.²¹

Nonetheless, if wrinkles are related to unbalance of facial muscle expression, neurotoxin can be injected according to patient's need and expectation. Also in this step, it is important to consider the "dynamic discordance with aging", a new concept related to the relationship between mimetic facial muscles and the overlying deteriorating skin envelope characterized by an unbalance among muscles of facial expression, resulting in miscommunication of emotions.²

To date, neurotoxin injection remains the gold standard treatment for dynamic wrinkles. The severity of wrinkles and the age at which they become clinically visible is extremely variable, being affected by individual muscle structure, skin quality, musculature use and several external factors. Careful assessment of patients' facial expression, clinical anatomical patterns, mass and muscle strength, and presence of dynamic discordance are crucial for a better outcome (Figure 4D). The ONE21 technique is a customizable injection protocol that allows for individualized assessment and treatment of the upper third of the face with neurotoxin (Figure 4D).³⁰ The protocol can be customized according to the aesthetic demands of each patient and their anatomical particularities.³¹

When used to correct the imbalance between the activity of the elevators and depressor muscles of the face, INCO is injected into the mentalis, DAO and in the facial platysma (the depressors), pending the muscle balance in favor of the elevator facial muscles and thus, resulting in a chemical facial lifting.^{32,33}

Step 5 Décor (Improvement of Skin Surface)

And as a finishing touch intradermal INCO injection can be performed, according to the patient's need (Step 5A) and/or injection of a polydensified filler containing a single phase of continuously cross-linked HA and manufactured using CPM technology, containing glycerol (Step 5B; HA20G; CPM-HA; Belotero Revive®; Cohesive poly-densified matrix hyaluronic acid; Merz Pharmaceuticals GmbH, Frankfurt, Germany).

Off-label intradermal injection of INCO improves skin quality, with studies demonstrating benefit in treating sagging facial skin, excessive sebum production and enlarged facial pores.³² While the mechanism of action of BTX-A on sebum production has not been fully elucidated, it is known that sebocyte differentiation and sebum production can be disturbed by inhibiting the release of acetylcholine with intradermal neurotoxin injection. Moreover, the effect of intradermal injection of BTX-A into facial pores may be indirectly related to the reduction in sebum production and secondary to the action of the neurotoxin that relaxes the arrector pili muscle.

The use of a pure neurotoxin, free from complexing protein, is indicated, to reduce the possibility of activating the immune system, through dendritic cells located in the dermis.³¹

Intradermal injection of 0.5U of INCO (100U vial reconstituted in 2mL of saline solution) using 31G needle and fixed pre-determined doses may be performed in the anterior malar area, forehead, glabella, and chin (Step 5A; Figure 5A).

HA's ability to rejuvenate the skin, improve skin turgor and hydration, increase the production of collagen fibers and promote the release of cell growth factors has already been demonstrated.³⁴ HA20G markedly improved skin viscoelastic properties (skin elasticity, skin firmness and skin fatigue), skin's roughness, tone, radiance and hydration for up to 36 weeks. Micropuncture Injections of 50 μ L should be delivered in the deep dermis, into up to 20 injection points on the lower cheek. Sessions should be performed over three consecutive visits, 4 weeks apart (Step 5B; Figure 5B).

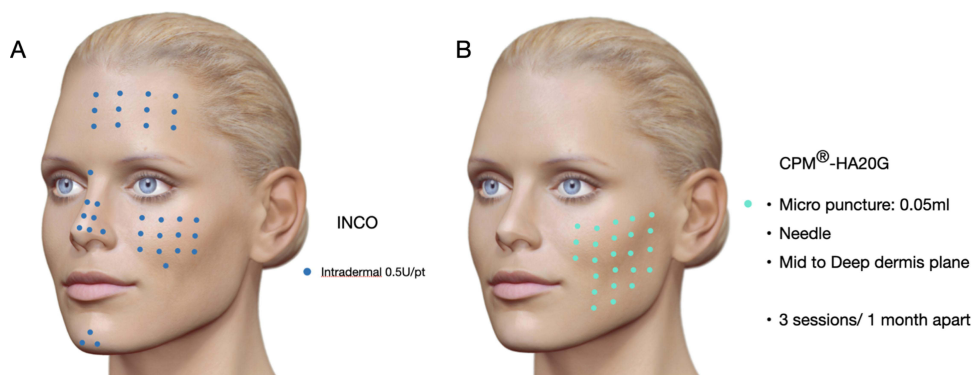


Figure 5 Step 5 Décor (improvement of skin surface). (A) Step 5A; Injection points and units of INCO: to improve skin quality. (B) Step 5B; Injection points, plane, technique of HA20G to improve skin viscoelastic properties. (Image partially reproduced from Merz Institute Advanced Aesthetics platform-www.merz-institute.com).

Results

Median age of the patients included was 43 years (Figures 6–10). As per investigator's and the independent evaluator's assessments, all patients were at least improved at the 3-month evaluation (Figure 11). Both blinded evaluators deemed at




Figure 6 32-yr-old female submitted to Step 2 reinforcement of SMAS and reticular cutis with MFU-V in the mid and lower thirds (7MHz - 3.0mm (190 lines and 10MHz - 1.5mm (190 lines), Step 4B diffuse biostimulation with CaHA in 1:1 dilution in the mid and lower thirds of the face., and Step 4D with INCO for upper third and platysma. (A, C, E, G, I, K) correspond to pre-treatment images. In (B, D and F) (3 months after treatment) soft tissue repositioning can be observed, with improvement of the fullness of the upper and lower cheek and definition of the jawline. (H, J, L) present outcome 30 days after Botulinum toxin treatment of the upper third and facial contouring, achieving grade 0 (no wrinkles) in the MAS for dynamic wrinkles in all three regions (forehead, glabella and crow's feet).



Figure 7 26-yr-old female submitted to Step 2: reinforcement of SMAS with MFU-V in the mid and lower thirds with 7MHz - 3.0mm transducer (190 lines) and 4MHz - 4.5mm transducer (120 lines), based on the see-plan treatment. Step 3: Injection of deep malar fat pads for fat pad repositioning (1mL/side of HAV using a 25-G cannula in fanning technique). In pre-treatment images (**A, C, E, G**) sagging of the medial and inferior third of the face is visible, as a consequence of the skin laxity and a reduction of the deep medial cheek fat compartment. In the post-treatment images (**B, D, F, H**) a reduction of the skin laxity and sagging can be observed as a consequence of the skin tightening achieved after the MFU-V treatment and replacement of the volume by the injection of HA in the anterior malar area.

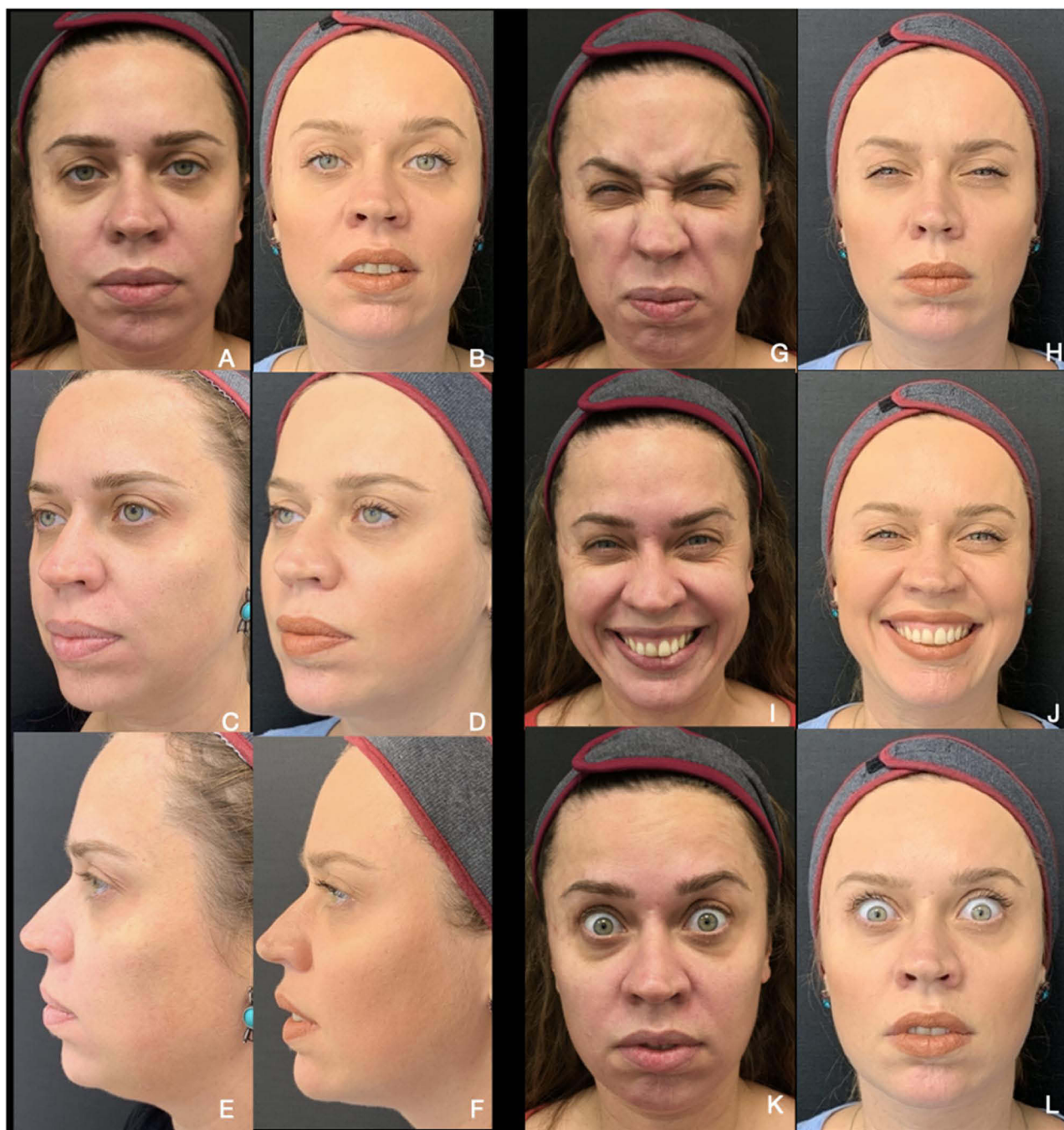

Figure 8 43-yr-old female, submitted to Step 1: Using a 22–25G cannula, HAI was injected in the lateral and medial cheek, in the supraperiosteal plane, below the zygomatic cutaneous and zygomatic retaining ligaments to reposition them more horizontally (0.2–0.2 – 0.1mL/ side). Five boluses of 0.2mL were injected with a 27-G needle in the supraperiosteal plane of the chin, being 3 bolus in the pogonium for anterior projection and 2 central bolus close to the inferior border of the chin, aiming for vertical projection (total volume of 1mL of HAI); Step 3: Injection of 0.5mL/side of HAV in the deep malar fat pads using fanning technique for soft tissue repositioning; Step 4A: Using a 25–22G cannula, injection of 0.75mL per side of undiluted CaHA(+) for pre-auricular soft tissue repositioning and in the subdermal plane slightly below the mandibular border for improvement of mandibular contour; 4B Diffuse stimulus with 1 syringe of diluted CaHA (1:1; 1,5mL of the final solution per side) using fanning technique in the medial and inferior thirds of the face to create a scaffold within the dermis, and Step 4C and D injection of 0.5mL/side of HAV for correction of nasolabial and mental-labial folds and injection of INCO for upper face wrinkles, correction of facial asymmetry and improvement of facial contour. The changes observed in the face of this patient are a consequence of a multifactorial process affecting each component of the facial anatomy, in particular bone support in the anterior maxilla, chin and mandibular contour decrease of ligaments support, soft tissue descent and volumetric deflation in the anterior malar area (**A, C, E, G, I, K**). By restructuring the face from bone to surface (3-month post-treatment; **B, D, F**), it was possible to establish the balance among the ligaments and the surrounding structures and correct the facial asymmetry (as a consequence of INCO injection; **H, J, L**) 30-day after INCO), creating a more harmonious profile, an inverted triangle facial shape and enhancement of the Ogee curve.

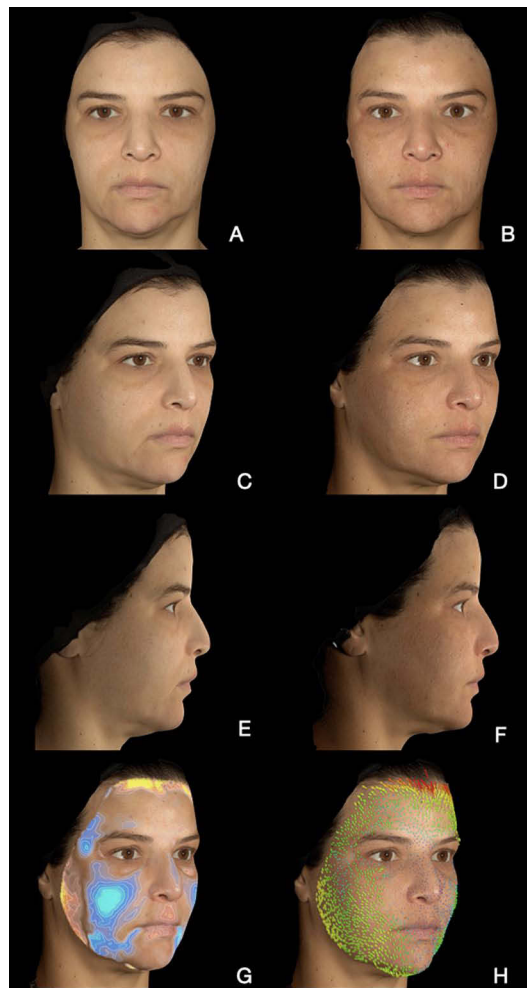


Figure 9 42-yr-old female treated according to the following scheme: Step 1: One syringe of HAI was injected in the lateral and medial cheek, in the supraperiosteal plane below the zygomatic cutaneous and zygomatic-retaining ligaments to reposition these latter more horizontally (3 bolus of 0.2–0.2–0.1 mL/side from medial to lateral). In the palpebro-malar hollow 0.3mL/side of HAI was placed inferior to the orbicularis retaining ligament along the orbital rim, and 0.1mL/side below the ROOF. HAI was injected posteriorly to the mandible angle in the supraperiosteal plane using 27G needle (0.2mL /side) and in the pogonion for anterior projection of the chin (3 bolus of 0.2mL; supraperiosteal). Step 2: MFU-V protocol including different depth transducers (1.5mm, 3.0mm; 4.5mm). Step 3: The following volumes and products were injected using a 25G cannula: HAV in the superficial temporal fat pad (0.5mL/side; subdermal plane); HAI (3 bolus of 0.2–0.2–0.1 mL/side) in the lateral cheek fat to improve soft-tissue repositioning; 1 syringe of HAV (0.5mL/side; fanning technique) in the deep medial cheek and 1 syringe of HAV (0.5mL/side) in the pre-jowl sulcus. Step 4A and B: 1 syringe of undiluted CaHa (+) (0.75mL/side) was injected in the subdermal plane, slightly below and along the mandibular border; 1 syringe of CaHa (1:1 dilution) was distributed in the medial and inferior thirds of the face, in the subdermal plane using the fanning technique. Step 4C: 1 syringe of HAB was injected in the subdermal plane of the nasolabial fold using a 30G needle. Step 4D: INCO was used for the treatment of dynamic lines of the upper face and to improve facial contouring. (A, C, E) correspond to pre-treatment. In (B, D, F) to 3-month post treatment images, improvement in all 3 thirds of the face can be observed: Upper third: improvement of the temporal and infra-orbital hollowness, increase in inferior lateral support of the eyes, lifting of the eyebrows can be observed; Mid-third: the ogee curve was naturally recreated, decrease of the naso-jugal groove; Inferior third: rectification of the corner of the mouth, decrease of the marionette lines, and better definition of the mandibular contour. In the Vectra system volume analysis (G): improvement in volume in all areas in blue, while there is a reduction in volume in the lateral part of the face (yellow areas). The Vectra system vector displacement assessment (H) illustrates the lifting effect: green arrows directed laterally and upwards in the three thirds of the face, red arrows in the upper forehead, place with the greatest lifting degree.

least 1-point improvement for all patients compared to baseline for the following parameters: skin laxity and wrinkles at rest as per SASSQ, dynamic wrinkles (forehead, glabella, and crow's feet) as per respective validated scales, and upper cheek and lower cheek fullness as per Merz Aesthetic Scale for Upper and Lower Cheek Fullness (Figure 12). For the jawline, 3 patients were graded 0 in the MAS in the pre-treatment image by the independent evaluators, with no room for improvement, while the remaining patients presented at least 1 point of improvement compared to baseline. One subject was treated with INCO for skin quality and in erythema evaluation there was at least 1-point improvement in erythema evaluation as per 2 blinded evaluators.

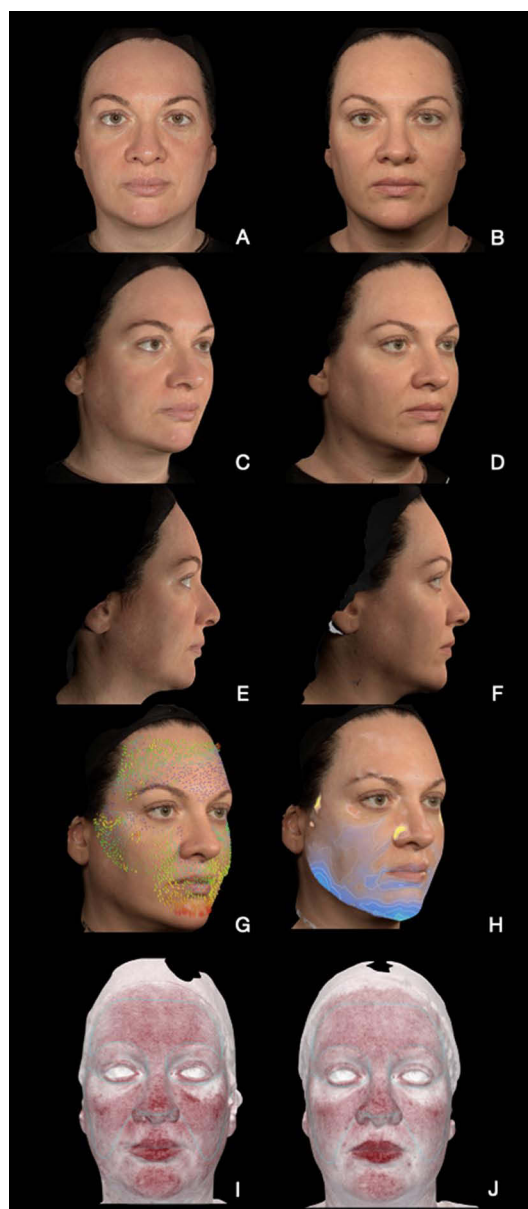


Figure 10 45-yr-old female treated according to the following scheme: Step 1: 1 syringe of HAI injected in the lateral and medial cheek, in the supraperiosteal plane, below the zygomatic cutaneous and zygomatic-retaining ligaments to reposition these latter more horizontally (3 bolus of 0.2 - 0.2 - 0.1mL/side from medial to lateral). Step 3: The following volumes and products were injected using a 25G cannula: 0.5mL/side of HAV in the superficial temporal fat pad, in the subdermal plane; 1 syringe of HAI (3 bolus of 0.2 - 0.2 - 0.1mL/side) in the lateral cheek fat to improve soft-tissue repositioning; 2 syringes of HAV (1mL/side; fanning technique) in the deep medial cheek. Step 4C: 1 syringe of HAB was injected in the subdermal plane of the nasolabial fold using a 30G needle. Step 4D and 5A: INCO was used for the treatment of dynamic lines of the upper face, improve facial contouring and skin quality. Comparing pre-treatment (A, C, E) images with 3-month post treatment images (B, D, F), an improvement of the palpebro-malar hollow and tear trough, volumetric replacement in the anterior malar area recreating the ogee curve, improvement of the naso-jugal groove, and better definition of the mandibular contour can be observed. In Vectra system analysis, the vector displacement assessment (G) illustrates the lifting effect showing arrows directed laterally and upwards in the entire face, and the volumetric analysis (H) highlights the improvement of the contour of the face and malar area. (J and I) represent the before and after treatment with intradermal botulinum toxin injection for skin quality, respectively, with a reduction of erythema after treatment, graded as at least 1-point improvement as assessed by the independent blinded evaluators.

Discussion

Facial aging has been deemed as a predictable process. The topographic changes observed on the face are influenced by a multifactorial process underlying each component of the facial anatomy.³ This results from a combination of decrease of bone structural support, laxity of the ligaments, changes in muscles tone and dynamic discordance, volumetric deflation, soft tissue descent and skin resilience reduction.⁹ Nonetheless, it is important to point out that facial aging

Global Aesthetic Improvement Scale - independent observer

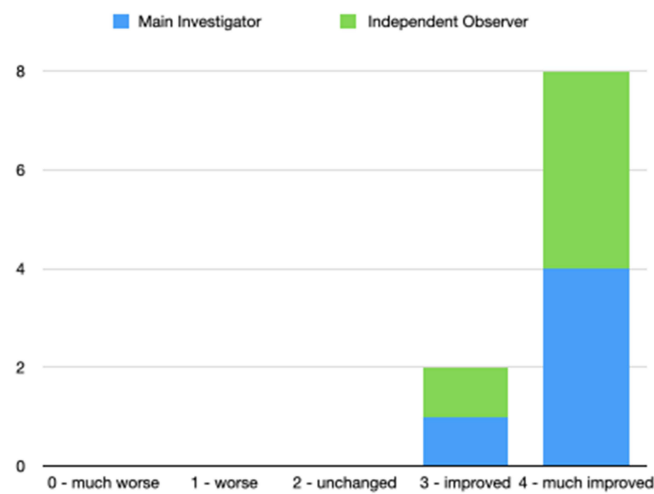


Figure 11 Improvement as assessed by the Global Aesthetic Improvement Scale at 3 months. Proportion of subjects graded by the main investigator as improved (3) or much improved (4), and proportion of subjects graded by the independent evaluator as improved (3) or much improved (4).

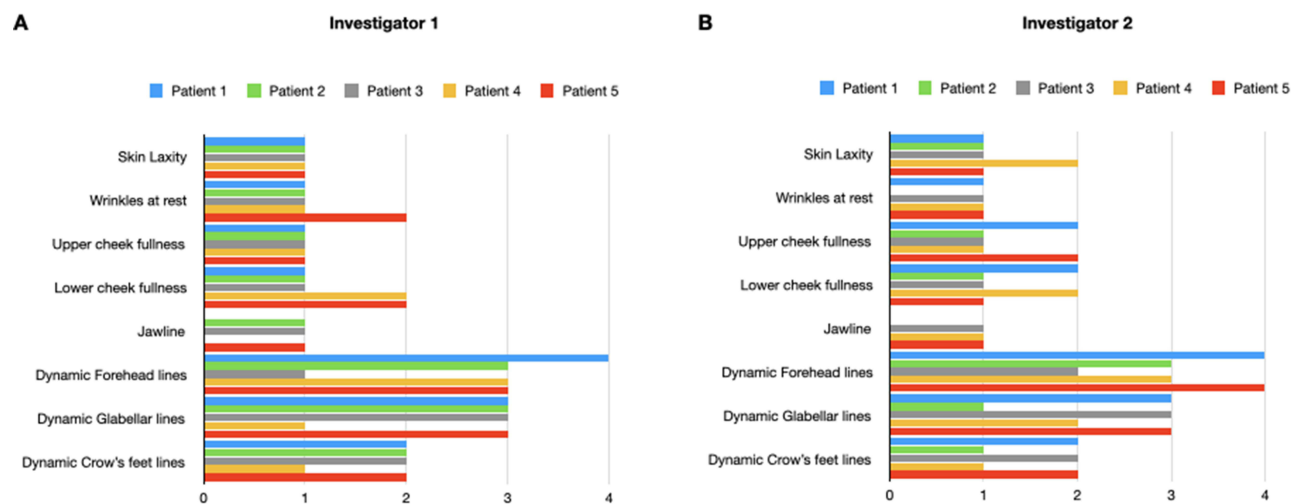


Figure 12 A and B: Independent blinded evaluators analysis (degree of improvement). For Skin quality and Upper and Lower Cheek Fullness, pre- and 3-month post-treatment images were evaluated using the Scientific Assessment Scale of Skin Quality (SASSQ) and Merz Aesthetic Scale (MAS) respectively. For the Jawline, 3 patients were graded 0 in the MAS in the pre-treatment image by independent evaluators, with no room for improvement, while patient 4 presented no improvement in the post-treatment image as per independent evaluator 1. Dynamic wrinkles were evaluated using Forehead, Glabellar and Crow's Feet dynamic wrinkles MAS validated scales, comparing baseline images with 30-day post-botulinum injection treatment: Both independent blinded evaluators considered at least 1-point improvement of the upper face dynamic wrinkles for all patients, with 72% of the patients achieving at least 2-point improvement.

does not occur homogeneously throughout each component of facial anatomy, also there exists a variation among the components. Furthermore, there is an interplay among the facial structures. For instance, skeletal changes in the orbit, maxilla, and mandible may influence the relative prominence and position of facial soft tissues of the mid-face, while volumetric changes to both facial bones and fat compartments also impact the facial mimetic muscles with changes in laxity and muscle tension. Muscles of facial expression in young people, are convex thanks to the deep, underlying fatty volume. Thus, the muscle is longer and its amplitude of movement is greater, resulting in a broader and more expressive facial expression, whereas in the elderly, the resting tone increases, the muscle becomes shorter, leading to a more contracted face.⁷ The restructuring of bone support as well as the restoration of the volume of the fat compartments

positively interfere with the restoration of tone and amplitude of muscle contraction, corroborating the importance of restoring the foundation (bone and ligaments) and walls (fat) before addressing the musculature.

Even though we didactically separate assessment in layers, all facial layers are interconnected, like a spider web so that the changes that occur in one of the layers of the face will interfere positively or negatively in all other layers. By following this systematized assessment and treatment plan, considering individual anatomical deficiencies layer by layer from deep to the surface, it was possible to observe that structuring the face starting from the deepest structures, interferes positively in the adjacent and most superficial layers (Figures 6–10), since part of the changes observed in the latter is a consequence of structural changes in the deeper layers. In this way, once we first restructure the deeper layers, many of the changes observed in the more superficial layers will be resolved, and thus the therapeutic intervention in the latter will be focused only on the remaining changes.

The rationale behind restructuring an aging face from the bone structure to the surface of the skin is to restore its functionality, like renovating a house to improve its structure, appearance, and longevity. By planning a treatment starting from the foundation to the surface, based on the etiology and progression of facial aging, the layering restructuring presented herein respects the original anatomy of the face, with restoration of the balance among the structures, providing not only more rationale use of the injectable treatments, but also a more natural outcome. For instance, a crack in the wall may be fixed briefly by using paint or wallpaper, but if the underlying cause is lack of structure, if the latter has not been addressed, the repair will require later more effort and investments. A deep nasolabial fold may be secondary to loss of malar bone support and/or deep malar fat pad atrophy.² Starting treatment by injecting the nasolabial fold (NLF) will require more product volume and will not address the root cause, and thus may not achieve a satisfactory overall result, since the malar retrusion would still be left untreated. Moreover, to compensate the malar retrusion, injection of excessive volume may be needed in the midfacial fat compartments, since the latter are overlapped by so many layers that larger volumes are needed to have a projection effect.³⁵ This may lead to the “overfilled syndrome” when the patient smiles, which due to the presence of the transverse facial septum, the volume of the midfacial fat compartments together with the injected product are projected anteriorly and the midface appears overfilled.³⁶ On the other hand, if tackled as per layering approach, from bone support to the skin, supraperiosteal injections would mimic the bone support and stretch the ligaments, and if necessary, less volume would need to be injected in the midfacial fat compartments and NLF to achieve a more natural and holistic result, minimizing harmful stigma associated with bad cosmetic practice. Thus, despite the small sample, all patients presented at least 1-point improvement in skin laxity and wrinkles at rest, dynamic wrinkles (forehead, glabella, and crow’s feet), and upper cheek and lower cheek fullness in the full assessment performed by the independent blinded evaluators, regardless of the individualized treatment scheme adopted for each of the 5 patients, demonstrating that by interfering on structural individual changes, enhancement can be observed in adjacent areas as a consequence of the improvement of the facial balance.

Also, it is important to highlight that there is no one-size-fits-all recipe for rejuvenation and not all patients need to be treated with all 5 steps (Figures 6–10). The author recommends a customized treatment plan able to deliver a harmonious rejuvenating and beautification outcome, adapted to the patient’s needs considering not only the individual’s original anatomy, but also changes resulting from the aging process. In this way, decrease of bone structural support, laxity of the ligaments, changes in muscles tone and dynamic discordance, volumetric deflation, soft tissue descent and skin resilience reduction should be considered, regardless of the approach being classified as prevention (for younger patients in the second and third decade (Figure 6) or restoration (for patients who have already presented atrophy of the fat compartment and loss of structural bone tissue secondary to the aging process; Figures 7 and 8).

A limitation of this retrospective investigation is the small sample size. Nonetheless, this study highlights the aesthetic improvement in the layering approach. Whether these results are applicable to a larger population with different ethnicities and other characteristics than the sample retrospectively investigated remains elusive and should be subject to further clarification.

Conclusion

Having in mind that with the aging process changes may happen in all facial layers, sometimes in different degrees according to the original anatomical structure, a careful assessment of all the layers is imperative to set up a treatment

plan able to deliver a harmonious outcome. By planning a treatment starting from the foundation to the surface, the layering restructuring respects the original anatomy of the face, and aging process, restoring the balance among the structures, providing not only more rationale use of the injectable treatments but also a more natural outcome.

Acknowledgment

This research received no specific grant from any funding agency in the public, commercial, or not-for-profit sectors. Medical writing and editorial assistance were provided by Dr Danielle Shitara, (Private Practice) and were supported by Medical Affairs of Merz Aesthetics LATAM, through its affiliate Merz Farmaceutica Comercial Ltda, in accordance with Good Publication Practice guidelines.

Funding

Merz Aesthetics LATAM funded medical writing assistance and provided products to this study through its affiliate in Brazil – Merz Farmacêutica Comercial Ltda. Despite this support, this study was conducted with autonomy and independence by the medical authors, and Merz Farmacêutica Comercial, Ltda. had any participation or influence on design, conduct, collect, assess and evaluate the presented data.

Disclosure

Dr Pecora has been speaker for Merz Pharmaceuticals and personal fees from Merz Aesthetics, outside the submitted work. The author reports no other conflicts of interest in this work.

References

1. Helfrich YR, DI S, Voorhees JJ. Overview of skin aging and photoaging. *Dermatol Nurs*. 2008;20(3):177–183.
2. Swift A, Liew S, Weinkle S, Garcia JK, Silberberg MB. The Facial Aging Process From the “Inside Out”. *Aesthet Surg J*. 2021;41(10):1107–1119. doi:10.1093/asj/sjaa339
3. Rohrich RJ, Avashia YJ, Savetsky IL. Prediction of Facial Aging Using the Facial Fat Compartments. *Plast Reconstr Surg*. 2021;147(1S–2):38S–42S. doi:10.1097/PRS.00000000000007624
4. Cotofana S, Fratila AA, Schenck TL, Redka-Swoboda W, Zilinsky I, Pavicic T. The Anatomy of the Aging Face: a Review. *Facial Plast Surg*. 2016;32(3):253–260. doi:10.1055/s-0036-1582234
5. McKee D, Remington K, Swift A, Lambros V, Comstock J, Lalonde D. Effective Rejuvenation with Hyaluronic Acid Fillers: current Advanced Concepts. *Plast Reconstr Surg*. 2019;143(6):1277e–1289e. doi:10.1097/PRS.0000000000005607
6. Hillebrand GG, Liang Z, Yan X, Yoshii T. New wrinkles on wrinkling: an 8-year longitudinal study on the progression of expression lines into persistent wrinkles. *Br J Dermatol*. 2010;162(6):1233–1241. doi:10.1111/j.1365-2133.2010.09709.x
7. Le Louam C. [Muscular aging and its involvement in facial aging: the Face Recurve concept]. Vieillesse musculaire et son implication dans le vieillissement facial: le concept du Face Recurve. *Annales de dermatologie et de venerologie*. 2009;136(4):S67–72. doi:10.1016/S0151-9638(09)74530-2
8. Trevidic P, Kaufman-Janette J, Weinkle S, et al. Injection Guidelines for Treating Midface Volume Deficiency With Hyaluronic Acid Fillers: the ATP Approach (Anatomy, Techniques, Products). *Aesthet Surg J*. 2022;42(8):920–934. doi:10.1093/asj/sjac007
9. Landau M, Anand CV, Besins T, et al. First Consensus on Primary Prevention and Early Intervention in Aesthetic Medicine. *J Dru Dermatol*. 2017;16(9):846–854.
10. Suwanchinda A, Webb KL, Rudolph C, et al. The posterior temporal supraSMAS minimally invasive lifting technique using soft-tissue fillers. *J Cosmet Dermatol*. 2018;17(4):617–624. doi:10.1111/jocd.12722
11. Mendelson B, Wong CH. Changes in the facial skeleton with aging: implications and clinical applications in facial rejuvenation. *Aesthetic Plast Surg*. 2012;36(4):753–760. doi:10.1007/s00266-012-9904-3
12. Toledo Avelar LE, Cardoso MA, Santos Bordoni L, de Miranda Avelar L, de Miranda Avelar JV. Aging and Sexual Differences of the Human Skull. *Plast Reconstr Surg Glob Open*. 2017;5(4):e1297. doi:10.1097/GOX.0000000000001297
13. Eiben-Nielson C, Kerscher M. Development and validation of a global photonic scale for evaluating skin quality of aged female facial skin. *J Cosmet Dermatol*. 2021;20(12):4032–4039. doi:10.1111/jocd.14058
14. Carruthers J, Flynn TC, Geister TL, et al. Validated assessment scales for the mid face. *Dermatol Surg*. 2012;38(2):320–332. doi:10.1111/j.1524-4725.2011.02251.x
15. Narins RS, Carruthers J, Flynn TC, et al. Validated assessment scales for the lower face. *Dermatol Surg*. 2012;38(2):333–342. doi:10.1111/j.1524-4725.2011.02247.x
16. Carruthers A, Carruthers J, Hardas B, et al. A validated grading scale for forehead lines. *Dermatol Surg*. 2008;34(Suppl 2):S155–60. doi:10.1111/j.1524-4725.2008.34364.x
17. Flynn TC, Carruthers A, Carruthers J, et al. Validated assessment scales for the upper face. *Dermatol Surg*. 2012;38(2):309–319. doi:10.1111/j.1524-4725.2011.02248.x
18. Carruthers A, Carruthers J, Hardas B, et al. A validated grading scale for crow’s feet. *Dermatol Surg*. 2008;34(2):S173–8. doi:10.1111/j.1524-4725.2008.34367.x
19. Enlow DH, Hans MG. *Noções Básicas sobre crescimento facial*. Santos; 2012:536.

20. Enlow DH, Moyers RE. Growth and architecture of the face. *J Am Dent Assoc*. 1971;82(4):763–774. doi:10.14219/jada.archive.1971.0144
21. Molliard SG, Bétemps JB, Hadjab B, Topchian D, Micheels P, Salomon D. Key rheological properties of hyaluronic acid fillers: from tissue integration to product degradation. *Plast Aesthet Res*. 2018;5:657.
22. Alghoul M, Codner MA. Retaining ligaments of the face: review of anatomy and clinical applications. *Aesthet Surg J*. 2013;33(6):769–782. doi:10.1177/1090820X13495405
23. Park JY, Lin F, Suwanchinda A, et al. Customized Treatment Using Microfocused Ultrasound with Visualization for Optimized Patient Outcomes: a Review of Skin-tightening Energy Technologies and a Pan-Asian Adaptation of the Expert Panel's Gold Standard Consensus. *J Clin Aesth Dermatol*. 2021;14(5):E70–E79.
24. Carruthers J, Burgess C, Day D, et al. Consensus Recommendations for Combined Aesthetic Interventions in the Face Using Botulinum Toxin, Fillers, and Energy-Based Devices. *Dermatol Surg*. 2016;42(5):586–597. doi:10.1097/DSS.0000000000000754
25. Corduff N. Introducing aesthetic regenerative scaffolds: an immunological perspective. *J Cosmet Dermatol*. 2023;22(1):8–14. doi:10.1111/jocd.15702
26. Goldie K. The evolving field of regenerative aesthetics. *J Cosmet Dermatol*. 2023;22(1):1–7. doi:10.1111/jocd.15556
27. Corduff N, Chen JF, Chen YH, et al. Pan-Asian Consensus on Calcium Hydroxyapatite for Skin Biostimulation, Contouring, and Combination Treatments. *J Clin Aesth Dermatol*. 2021;14(8).
28. Goldie K, Peeters W, Alghoul M, et al. Global Consensus Guidelines for the Injection of Diluted and Hyperdiluted Calcium Hydroxylapatite for Skin Tightening. *Dermatol Surg*. 2018;44:S32–S41. doi:10.1097/DSS.0000000000001685
29. Micheels P, Sarazin D, Besse S, Sundaram H, Flynn TC. A blanching technique for intradermal injection of the hyaluronic acid Belotero. *Plast Reconstr Surg*. 2013;132(4):59S–68S. doi:10.1097/PRS.0b013e31829a02fb
30. de Sanctis Pecora C, Ventura Ferreira K, Amante Miot H. ONE21 technique for an individualized assessment and treatment of upper face wrinkles in five pairs of identical twins with IncobotulinumtoxinA. *J Cosmet Dermatol*. 2022;21(5):1940–1947. doi:10.1111/jocd.14879
31. de Sanctis Pecora C. One21: a Novel, Customizable Injection Protocol for Treatment of the Forehead with IncobotulinumtoxinA. *Clin Cosmet Invest Dermatol*. 2020;13:127–136. doi:10.2147/CCID.S237519
32. Park JY, Cho SI, Hur K, Lee DH. Intradermal Microdroplet Injection of Diluted Incobotulinumtoxin-A for Sebum Control, Face Lifting, and Pore Size Improvement. *J Dru Dermatol*. 2021;20(1):49–54. doi:10.36849/JDD.5616
33. de Almeida ART, Romiti A, Carruthers JDA. The Facial Platysma and Its Underappreciated Role in Lower Face Dynamics and Contour. *Dermatol Surg*. 2017;43(8):1042–1049. doi:10.1097/DSS.0000000000001135
34. Hertz-Kleptow D, Hanschmann A, Hofmann M, Reuther T, Kerscher M. Facial skin revitalization with CPM((R))-HA20G: an effective and safe early intervention treatment. *Clin Cosmet Invest Dermatol*. 2019;12:563–572. doi:10.2147/CCID.S209256
35. Cotofana S, Koban KC, Konstantin F, et al. The Surface-Volume Coefficient of the Superficial and Deep Facial Fat Compartments: a Cadaveric Three-Dimensional Volumetric Analysis. *Plast Reconstr Surg*. 2019;143(6):1605–1613. doi:10.1097/PRS.0000000000005524
36. Cotofana S, Gotkin RH, Frank K, Lachman N, Schenck TL. Anatomy Behind the Facial Overfilled Syndrome: the Transverse Facial Septum. *Dermatol Surg*. 2020;46(8):e16–e22. doi:10.1097/DSS.0000000000002236

Clinical, Cosmetic and Investigational Dermatology

Dovepress

Publish your work in this journal

Clinical, Cosmetic and Investigational Dermatology is an international, peer-reviewed, open access, online journal that focuses on the latest clinical and experimental research in all aspects of skin disease and cosmetic interventions. This journal is indexed on CAS. The manuscript management system is completely online and includes a very quick and fair peer-review system, which is all easy to use. Visit <http://www.dovepress.com/testimonials.php> to read real quotes from published authors.

Submit your manuscript here: <https://www.dovepress.com/clinical-cosmetic-and-investigational-dermatology-journal>