

Uterine Burkitt Lymphoma with Rare Extranodal Deposits in the Bone, Breast, and Sacral Canal: A Case Report

Xu-Sheng Liu¹, Chao Liu², Yi-Jia Chen¹, Dao-Bing Zeng¹, Ya-Lan Wang¹, Zhi-Jun Pei¹

¹Department of Nuclear Medicine, Taihe Hospital, Hubei University of Medicine, Shiyan, People's Republic of China; ²Medical Imaging Center, Taihe Hospital, Hubei University of Medicine, Shiyan, People's Republic of China

Correspondence: Zhi-Jun Pei, Department of Nuclear Medicine, Taihe Hospital, Hubei University of Medicine, Shiyan, People's Republic of China, Email pzjml1980@taihehospital.com

Abstract: Burkitt lymphoma is a highly invasive non-Hodgkin lymphoma. Sporadic Burkitt's lymphoma is commonly found in the abdomen. However, Burkitt lymphoma infiltrating the uterus is uncommon in occurrence. We report the results of ¹⁸F-FDG PET/CT examination of a 36-year-old woman. The report indicates that in addition to the strong uptake of FDG imaging agent in the uterus, bilateral cervical and abdominal lymph nodes also have strong activity. At the same time, it was also found that bilateral small breast nodules, sacral canal and multiple bones in the whole body showed a radiation uptake pattern similar to that of the uterus. ¹⁸F-FDG PET/CT imaging can help determine the extent of the disease and the affected body area, which is helpful to guide the treatment decision. This case report shows the application of ¹⁸F-FDG PET/CT imaging in the diagnosis, staging and post-treatment evaluation of Burkitt lymphoma of the uterus. It provides very useful information for clinicians and helps to improve the accuracy of diagnosis and treatment effect.

Keywords: uterine, Burkitt lymphoma, case report, PET/CT, bone involvement

Introduction

Burkitt lymphoma is a highly invasive non-Hodgkin lymphoma, known for its rapid growth and invasion of the body's lymphatic system.^{1,2} Sporadic Burkitt's lymphoma is commonly found in the abdomen.³ However, there have been few reported cases of Burkitt lymphoma involving the uterus. Uterine Burkitt lymphoma is a rare and challenging diagnosis, as it can present with non-specific symptoms and can often be confused with other gynecological malignancies.^{4,5} The use of imaging modalities such as ¹⁸F-FDG PET/CT has greatly improved the detection and staging of this disease, particularly in cases with multi-focal disease.⁶⁻⁸ Early diagnosis and active treatment are crucial to improve the prognosis of patients. However, there are few reports on PET/CT imaging of uterine Burkitt lymphoma.

Case Presentation

In January 2013, Shiyan Taihe Hospital accepted a 36-year-old female referral patient. The patient had abnormal uterine bleeding a month prior to presentation, which was characterized by increased menstrual volume, prolonged menstrual period and occasional dizziness. After the onset of the disease, the patient was treated in an external hospital and underwent hysteroscopy and uterine tissue aspiration. The examination suggested the likelihood of: (uterine) Burkitt lymphoma. Immunohistochemical results showed LCA (+++), CD38 (+++), CD138 (-), CKpan (-), EMA (-), Vimentin (+), CD10 (+), CD3 (+), CD5 (+), CD20 (+++), CD79α (+++), Ki-67 (positive rate 95%), MUM-1 (+), CyclinD1 (-), SOX-10 (-), CD23 (-), Pax-5 (+++), Bcl-2 (-), Bcl-6 (+), TdT (-), κ (+), λ (-), CD43 (+), SMA (-), h-Caldesmon (-), Desmin (-), ER (-), PR (-). In order to further evaluate the situation and determine the hidden metastasis, she was referred to the PET center for ¹⁸F-FDG PET/CT lymphoma staging.

^{18}F -FDG PET/CT results showed that there was abnormal imaging agent concentration in the uterine body and cervix of the patient (Figure 1), suggesting that the possibility of malignant tumor was high, which supported the diagnosis of immunohistochemistry.

At the same time, PET/CT scan also found abnormal uptake of imaging agents in multiple lymph nodes, including left cervical lymph nodes and abdominal lymph nodes. In addition, several extranodal parts of the body, including breast, sacral canal and bone, have metabolic abnormalities of different degrees. These findings support the diagnosis of Burkitt lymphoma and suggest that the case has widespread invasion. Based on the PET/CT scan results, the clinician diagnosed the patient as stage IIIa of Burkitt lymphoma and had lost the opportunity for surgery. The patient received CD20 monoclonal antibodies combined with chemotherapy.

The patient underwent a PET/CT scan after the completion of the fourth round of chemotherapy. The post-treatment PET/CT scan revealed a restored uterine morphology (decreased size and disappearance of hypermetabolic lesions). The size and metabolism of the lymph nodes in the left neck and abdominal cavity, and the small nodules scattered on both sides of the breast glands decreased compared with before. The bone density of many bones in the whole body was uneven and the uptake of imaging agents was lower than before. After the above consideration, the activity of tumor cells was significantly suppressed after comprehensive treatment (Figure 2).

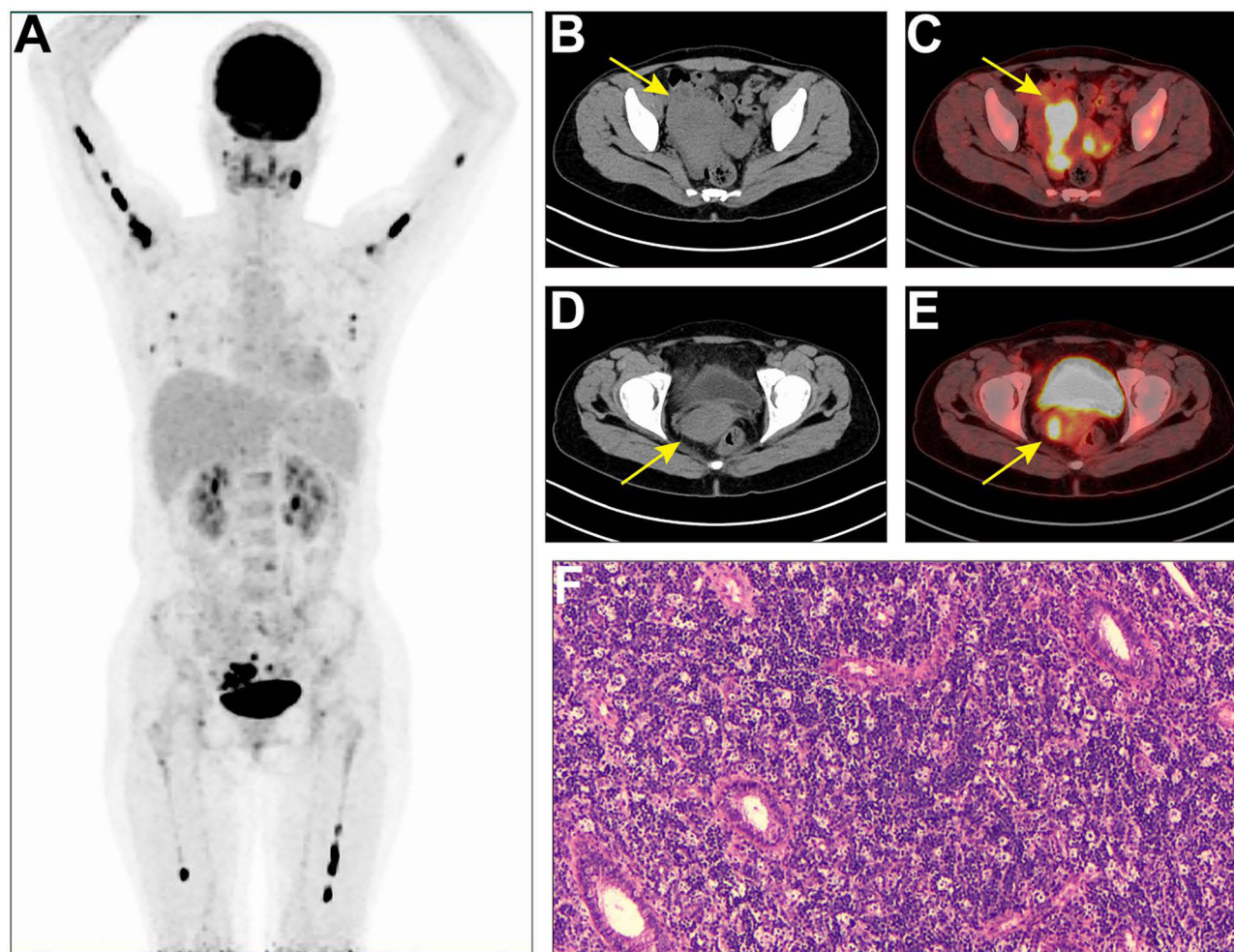


Figure 1 MIP on ^{18}F -FDG scan (A) showed hypermetabolic lesions in the whole body. Increased tracer uptake occurred in the pelvic area, and the most significant abnormal activity of the uterine body was located in the axial image (B), CT; (C), PET/CT fusion image; (arrow, SUVmax, 19.5). The most significant abnormal activity of the cervix is located in the axial image (D), CT; (E), PET/CT fusion image; (arrow, SUVmax, 9.5). (F) Hematoxylin-eosin stain, original magnification $\times 40$. Histopathological reports support Burkitt's lymphoma.

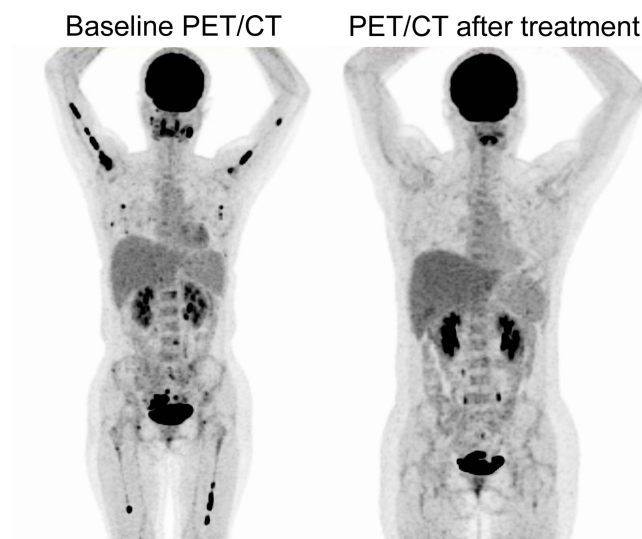

Figure 2 ^{18}F -FDG PET/CT imaging after and before treatment.

Discussion

Burkitt lymphoma is a dangerous malignant lymphoma, which usually occurs in children and young people. It is characterized by rapid tumor growth and rapidly deteriorating symptoms. Although the treatment of Burkitt lymphoma has made significant progress in the past decades, the treatment of advanced or recurrent cases still faces challenges.^{1,2} ^{18}F -FDG PET/CT imaging has very high diagnostic accuracy, can provide systemic metabolic information, and help guide treatment and monitor the efficacy.^{9,10}

In previous reports, Burkitt lymphoma often involved lymph nodes and extranodal sites, such as peritoneal lymph nodes, spleen and bone. Wang et al⁶ reported that a 7-year-old boy had peritoneal Burkitt lymphoma. PET/CT showed peritoneal, mesenteric and omental masses, accompanied by obvious ascites, mesenteric nodules and kidney involvement. Wen et al⁷ reported the results of FDG PET/CT examination of a 21-year-old man. His Burkitt lymphoma involved not only lymph nodes, spleen, brain and bone, but also four organs of the endocrine system, including thyroid gland, right adrenal gland, pancreas and right testicle. Previous studies reported the first well-documented case of Burkitt lymphoma in the uterus. A 40-year-old woman presented with vaginal bleeding. Endometrial scrapes revealed diffuse infiltration of medium-sized lymphocytes with the characteristic morphological and immunophenotypic characteristics of Burkitt lymphoma. There was no evidence of extrauterine disease.¹¹ However, there are few reports of PET/CT scan involving uterine Burkitt lymphoma. In the treatment of Burkitt lymphoma, chemotherapy and immunotherapy are the main treatment methods.^{1,2} For Burkitt lymphoma of the uterus, depending on the patient's age, condition and range of disease, other treatment methods such as surgery or chemotherapy may be required.^{4,5} In our report, not only lymph node diseases are involved, but also a large number of extranodal sites, including breast, bone and sacral canal. In particular, the appearance of lesions involving bones throughout the body is a manifestation of its deterioration, which usually occurs in patients with advanced disease. There are relatively few clinical studies on Burkitt lymphoma with bone involvement throughout the body, and no standard treatment scheme has been established for this subtype. Burkitt lymphoma with bone involvement throughout the body is a rare and challenging disease. Clinicians need to consider multiple treatment methods according to the patient's condition to improve the treatment effect. However, ^{18}F -FDG PET/CT imaging can help determine the extent of the disease and the affected body area, which is helpful to guide the treatment decision.⁹

Conclusion

In conclusion, this case report shows the application of ^{18}F -FDG PET/CT imaging in the diagnosis, staging and post-treatment evaluation of Burkitt lymphoma of the uterus. It provides very useful information for clinicians and helps to improve the accuracy of diagnosis and treatment effect.

Ethics Approval and Informed Consent

The studies involving human participants were reviewed and approved by The Ethics Committee of Taihe Hospital Affiliated of Hubei University of Medicine. Written informed consent was obtained from the patient for publication of this report.

Acknowledgments

This work was supported by the Shiyan Taihe Hospital hospital-level project (2022JJXM007) and the Key Discipline Project of Hubei University of Medicine.

Disclosure

The authors report no conflicts of interest in this work.

Reference

1. López C, Burkhardt B, Chan JKC, et al. Burkitt lymphoma. *Nat Rev Dis Primers*. 2022;8(1):78. doi:10.1038/s41572-022-00404-3
2. Roschewski M, Staudt LM, Wilson WH. Burkitt's Lymphoma. *N Engl J Med*. 2022;387(12):1111–1122. doi:10.1056/NEJMra2025746
3. Zeng W, Lechowicz MJ, Winton E, Cho SM, Galt JR, Halkar R. Spectrum of FDG PET/CT findings in Burkitt lymphoma. *Clin Nucl Med*. 2009;34(6):355–358. doi:10.1097/RLU.0b013e3181a34552
4. Horowitz NA, Benyamini N, Wohlfart K, Brenner B, Avivi I. Reproductive organ involvement in non-Hodgkin lymphoma during pregnancy: a systematic review. *Lancet Oncol*. 2013;14(7):e275–e282. doi:10.1016/S1470-2045(12)70589-2
5. Khan WA, Deshpande KA, Kurdukar M, Patil P, Mahure H, Pawar V. Primary Burkitt's lymphoma of endometrium and bilateral ovaries in a 6-year-old female: report of a rare entity and review of the published work. *J Obstet Gynaecol Res*. 2013;39(10):1484–1487. doi:10.1111/jog.12085
6. Wang X, Chen Z, Tang G, Zhang X, Child With A. Burkitt lymphoma with pleural, peritoneal, mesenteric, omental, and renal involvement. *Clin Nucl Med*. 2011;36(7):612–615. doi:10.1097/RLU.0b013e318217af84
7. Wen Z, Zhuang H. Burkitt's lymphoma involving multiple hormone-producing organs on FDG PET/CT. *Clin Nucl Med*. 2019;44(12):995–997. doi:10.1097/RLU.0000000000002807
8. Chen Z, Xue Q, Huang C, Yao S, Miao W. Burkitt lymphoma/ leukemia presented on 68Ga-Pentixafor and 18F-FDG PET/CT. *Clin Nucl Med*. 2022;47(1):98–100. doi:10.1097/RLU.0000000000003750
9. Milgrom SA, Rechner L, Berthelsen A. The optimal use of PET/CT in the management of lymphoma patients. *Br J Radiol*. 2021;94(1127):20210470. doi:10.1259/bjr.20210470
10. Juweid ME, Mueller M, Alhouiri A, A-Risheq MZ, Mottaghy FM. Positron emission tomography/computed tomography in the management of Hodgkin and B-cell non-Hodgkin lymphoma: an update. *Cancer*. 2021;127(20):3727–3741. doi:10.1002/cncr.33772
11. Keller C, Savage DG, Rusta-Villa M, Bhagat G, Alobeid B. Primary Burkitt lymphoma of the uterine corpus. *Leuk Lymphoma*. 2006;47(1):141–145. doi:10.1080/10428190500144821

OncoTargets and Therapy

Dovepress

Publish your work in this journal

OncoTargets and Therapy is an international, peer-reviewed, open access journal focusing on the pathological basis of all cancers, potential targets for therapy and treatment protocols employed to improve the management of cancer patients. The journal also focuses on the impact of management programs and new therapeutic agents and protocols on patient perspectives such as quality of life, adherence and satisfaction. The manuscript management system is completely online and includes a very quick and fair peer-review system, which is all easy to use. Visit <http://www.dovepress.com/testimonials.php> to read real quotes from published authors.

Submit your manuscript here: <https://www.dovepress.com/oncotargets-and-therapy-journal>