

Challenges in Surgical Intervention for a Rare Case of Anterior Segment Dysgenesis: A Case Report

Amirah Aldawood¹, Sultan Bakri¹, Batool Alotaibi²

¹Ophthalmology Department, Dhahran Eye Specialist Hospital, Dhahran, Saudi Arabia; ²Ophthalmology Department, Imam Abdulrahman Bin Faisal University, Dammam, Saudi Arabia

Correspondence: Sultan Bakri, Ophthalmology Department, Dhahran Eye Specialist Hospital, Dhahran, Saudi Arabia, Tel +966 553324350, Email soltan.bakri@hotmail.com

Abstract: Anterior Segment Dysgenesis (ASD) represents a spectrum of rare, congenital disorders that pose significant challenges to ophthalmological management due to their complex and heterogeneous nature. The management of ASD becomes particularly complex when associated with other serious ocular conditions. This report discusses the case of a 4-year-old girl diagnosed with ASD exhibiting a combination of sclerocornea, aphakia, aniridia, and secondary glaucoma. Owing to the complexity of such condition, a multi-disciplinary approach is required. Despite successful initial surgical interventions on the left eye, eye was lost due to subsequent endophthalmitis and retinal detachment, resulting in a decision to adopt a conservative, non-surgical approach for the right eye. Although a series of therapeutic interventions have been performed, the final visual outcome was poor, demonstrating the complexity and seriousness of such cases. This case serves as a reminder of the need for regular follow-up, prompt recognition, and management of potential complications. Further research is necessary to optimize the outcomes in patients with similar presentations.

Keywords: congenital aniridia, aphakia, secondary glaucoma, sclerocornea, case report

Introduction

Anterior Segment Dysgenesis (ASD) is a complex, heterogeneous group of disorders characterized by malformations of the anterior chamber of the eye, leading to significant visual impairments and often associated with secondary complications such as glaucoma.¹ These abnormalities include a wide spectrum of conditions, including aniridia, aphakia, and sclerocornea, which may appear concurrently or independently, contributing to the diagnostic complexity.²

Aniridia, a condition characterized by the partial or complete absence of the iris, is one of the more commonly observed features of ASD.³ Genetically, it is a hereditary disorder with an established autosomal dominant inheritance linked to the paired box six (PAX6) gene carried on chromosome 11 (part 13), the so-called “WAGR-region” deletions.^{4–6} This congenital disorder is typically bilateral and frequently results in a variety of complications, including reduced visual acuity, nystagmus, and amblyopia.^{3,7}

Aphakia, or the absence of the lens of the eye, is another crucial clinical manifestation of ASD, often leading to complications such as secondary glaucoma and cataracts.⁸ Congenital aphakia is linked to FOXE3 gene mutations, and occurs between 1 to 5/10,000 live births.^{9,10} While glasses or contact lenses can offer temporary correction, secondary implantation of an intraocular lens (IOL) has shown improved visual results.^{11,12} Numerous IOL secondary implantation methods have been suggested over time, with options like scleral-fixated or iris-sutured posterior chamber IOL (PCIOLs),¹³ but the best surgical approach remains uncertain. Notably, anterior chamber IOLs have led to complications like corneal cell loss and glaucoma, and thus are discouraged in pediatric patients.¹⁴

Secondary glaucoma, a serious consequence of the aforementioned conditions, occurs due to impaired aqueous humor outflow, often as a result of structural anomalies of the anterior chamber angle.¹⁵ Glaucoma, in turn, can further damage the optic nerve, aggravating vision loss.¹⁶ Lastly, sclerocornea, a rare and severe congenital anomaly, features a non-transparent, white cornea that merges with the sclera, often leading to profound visual impairment.¹⁷

The surgical management of ASD is challenging, primarily due to the presence of multiple co-existing anterior segment abnormalities, the need for individualized treatment plans, and the inherent risks associated with pediatric eye surgery. Each component of ASD demands a unique surgical approach, and their simultaneous occurrence complicates the intervention plan.¹⁸ The surgical intervention may include lens replacement, glaucoma drainage devices, or corneal transplantation, among others.^{18,19} However, the outcomes of these surgeries can be unpredictable and carry a high risk of complications, especially in children under the age of 5 years.¹⁹ Moreover, the success rate of glaucoma surgeries tends to be lower in pediatric patients compared to adults.¹⁸ Therefore, the decision to perform surgery must be carefully weighed against the potential risks and benefits.²⁰ In this report, we aimed to describe a rare case of a 4-year-old girl who presented with aniridia, aphakia, secondary glaucoma, and sclerocornea. In addition, we aimed to highlight the challenges associated with the surgical management of such case.

Case Presentation

In this report, we describe the case of a 4-year-old female patient who demonstrated distinctive ocular manifestations at birth, namely a large and opaque cornea (Figure 1). The pregnancy was uneventful, and there was no family history of any significant congenital anomaly. Upon her first ophthalmologic examination at the age of two weeks, she exhibited markedly elevated intraocular pressure (IOP) (34 mmHg in the left eye and 24 mmHg in the right eye) that was confirmed by doing complete examination under anaesthesia and several measurements were taken with a Tono-Pen and pneumotonometer that showed elevated IOP bilaterally. The axial length measured by A scan and found to be 18.25 mm in the right eye and 18.42 in the left eye. Additionally, B-scan showed evidence of aphakia and optic nerve cupping (Figure 2).

The diagnosis of bilateral sclerocornea, aniridia, aphakia, and secondary glaucoma was established clinically. Beyond the clinical diagnosis of sclerocornea, the extracted cornea was sent to a histopathologist to confirm the diagnosis. Despite our inability to directly visualize the fundus, B-scan ultrasonography provided evidence of a flat retina in both eyes. Visually Evoked Potential (VEP) was performed and resulted in a very poor vision. Primary medical management failed to control IOP. Hence, the cyclophotocoagulation (CPC) procedure was performed in both eyes because it is considered the least invasive procedure to reduce high IOP and Transillumination was used to locate the ciliary body. The ultrasound biomicroscopy (UBM) was used to detect the anatomical limbus.

At six months of age, the assessment of visual acuity proved challenging. As an alternative, a visual-evoked potential test was conducted, confirming the limited potential for vision. The family was consulted regarding the option of performing a penetrating keratoplasty to address the sclerocornea. During this discussion, the guarded prognosis associated with the procedure was thoroughly communicated to them.

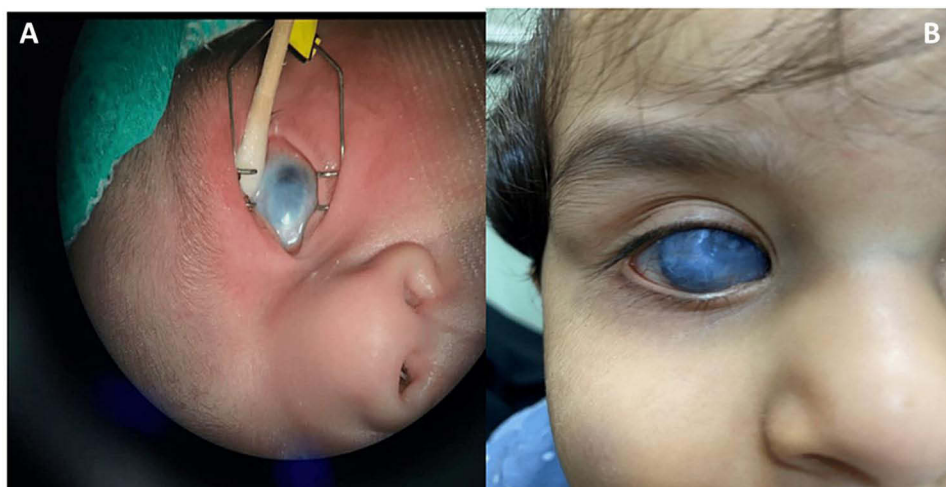


Figure 1 (A) Examination under anaesthesia of the patient showing evidence of sclerocornea, aniridia, and aphakia (age 2 weeks old). (B) Presentation of the patient with sclerocornea, aniridia, and aphakia (age 4 years old).

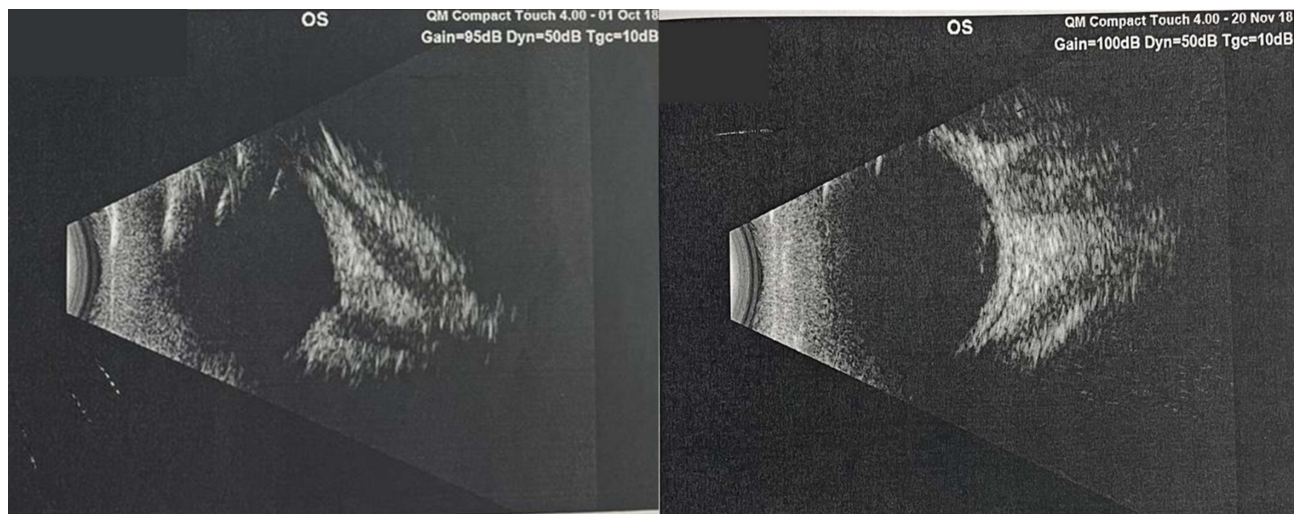


Figure 2 B-scan image to confirm the diagnosis of aphakia in the presence of sclerocornea.

A penetrating keratoplasty procedure was conducted when the patient reached six months of age, and she responded well to the intervention. Despite this, elevated IOP persisted, recording at 28 mmHg in the left eye and 24 mmHg in the right eye. The family was then consulted regarding the potential implementation of an Ahmed Valve Implant (AVI) to manage this issue. The MODEL FP7 plate with 184mm² size was placed in the superior-temporal quadrant, and the tube was placed in the anterior chamber. Six weeks post-AVI insertion, the patient developed AVI-related endophthalmitis, which was controlled using intravitreal antibiotics, necessitating the removal of the AVI. Regrettably, this was followed by the onset of total retinal detachment, resulting in no light perception in the patient's vision. Due to this outcome, evisceration was performed, and a scleral shell prosthesis was inserted in the patient's left eye for aesthetic purposes.

Prior to initiating the surgical procedure, it was clear that the risk of complications in the left eye was significantly high. This led to the decision to withhold surgical intervention in the right eye. Consequently, the level of vision in the right eye remained at light perception. The raised IOP was effectively managed through a medical approach utilizing a combination of dorzolamide and timolol, along with apraclonidine and latanoprost eye drops. B-scan ultrasonography revealed a flat retina and detected optic disc cupping. The VEP assessment further underscored the poor visual prognosis.

Discussion

This case presents a unique constellation of ocular anomalies, including sclerocornea, aniridia, aphakia, and secondary glaucoma in a four-year-old female patient, requiring the complex, multidisciplinary approach that ensued. The rarity of the co-occurrence of such congenital deformities poses substantial challenges in terms of the choice of intervention and poor prognosis of this comorbidity.

Congenital aniridia is a rare condition associated with severe comorbidities, and the outcome of surgical intervention remains uncertain.²¹ Furthermore, in infants, the condition creates a complex clinical dilemma with the involvement of parents in decision-making. One case report described the presence of congenital aniridia, in conjunction with aphakia and glaucoma, in an adult patient.²² One previous single case report described the condition in a 3-year-old infant,²³ but none, to the best of our knowledge, has reported an association with sclerocornea. In adult patients, it is difficult to treat congenital aniridia and its associated ocular comorbidities because it carries a significant risk of adverse events.¹⁰ The outcomes and prognostic factors in congenital aniridia have been well described in several studies. According to a retrospective case series by Jacobson et al, the majority of aniridic patients underwent at least one intraocular surgery, with cataract, glaucoma, and keratopathy identified as key factors associated with worse visual acuity (VA). Aphakic eyes, as seen in our case, were associated with poorer VA compared to phakic or pseudophakic eyes. Interestingly, they found that glaucoma drainage devices exhibited the highest success rate (71%) in controlling IOP over a long-term follow-up.²⁴ Chang et al also identified nystagmus and ocular hypertension as important

prognostic factors for poor visual outcome in aniridia. Notably, they found a high rate of secondary ocular hypertension following cataract surgery, emphasizing the need for careful management.²⁵ These findings reiterate the complexity of managing aniridia, particularly in combination with other ocular conditions such as sclerocornea and aphakia, as in our patient. Therefore, comprehensive and individualized treatment strategies are critical for the optimal management of these patients.

The decision to use CPC as the primary surgical intervention to control IOP is supported by the literature.²⁶ It has been shown to be a relatively safe and moderately effective procedure for reducing IOP in paediatric glaucoma when medical management has failed.^{27,28} However, the failure of CPC in our patient could be attributed to several factors. First, the unique co-morbidity of sclerocornea, aniridia, and aphakia may have contributed to the complex anatomical situation and hence to the failure of CPC. These ocular conditions often cause alteration of anterior chamber anatomy which may affect the success of CPC.²⁹ Second, the paediatric population can exhibit a higher degree of resistance to the effects of CPC. This is attributed to the higher degree of inflammation and wound healing response seen in children compared to adults.^{30,31} Lastly, the procedure was performed at a very young age (six months), which, according to some studies, might be associated with a higher rate of failure due to the immaturity of ocular tissues.³²

Despite occasional reports of successful penetrating Keratoplasty in the management of sclerocornea among very small babies, it is considered a risky procedure, with a high failure rate and significant post-operative ocular complications.^{19,33,34} Penetrating Keratoplasty has shown particular success in the treatment of sclerocornea in the context of posterior fossa malformations, hemangioma-arterial anomalies, cardiac defects, eye abnormalities, sternal cleft, and supraumbilical raphe (PHACES) syndrome,³⁵ which was not the case in our patient.

Despite the successful keratoplasty, the subsequent development of AVI-related endophthalmitis, and the decision to perform evisceration, underline the serious challenges that can accompany these complex cases. Literature reports an incidence of endophthalmitis following AVI of around 0.8% to 6.3%.³⁶ Our patient unfortunately fell within this minority, leading to a total retinal detachment. This was an unfortunate event, and it was clear that further surgical intervention in the right eye was not prudent. Following the removal of the AVI, our patient sustained retinal detachment, and her visual abilities were substantially affected, making it impossible to see the light via her left eye.

In terms of visual prognosis, the decision to perform a VEP test was crucial. VEPs provide a measure of the functional integrity of the visual pathway and are particularly useful in pre-verbal children or non-communicative patients.³⁷ Despite the poor prognosis, interventions were aimed at preserving the anatomical integrity and maximizing the visual potential. Managing IOP medically in the right eye using a combination of dorzolamide, timolol, apraclonidine, and latanoprost eye drops is a well-documented approach. Studies show that these medications, alone or in combination, can be effective in reducing IOP.^{38,39}

One important limitation of our case report is our inability to provide advice on underpinning the genetic or pathological abnormalities that lead to the combination of congenital ocular abnormalities. Furthermore, case reports have inherent difficulties in terms of external generalization. However, we believe that this case provides important information regarding potential surgical complications in the treatment of congenital aniridia. The benefits would rarely outweigh the risks among small children with this condition, and surgery should be attempted with extreme caution. Future research should attempt to longitudinally follow up patients with congenital aniridia for long periods with only conservative treatment and evaluate the risks associated with non-surgical intervention.

Conclusion

This case describes a rare combination of sclerocornea, aphakia, secondary glaucoma, and aniridia in a 4-year-old girl, highlighting the importance of a multi-disciplinary approach in managing such case. Despite a series of therapeutic interventions, the final visual outcome was poor, demonstrating the complexity and seriousness of such cases. This case serves as a reminder of the need for regular follow-up, prompt recognition, and management of potential complications. Further research is necessary to optimize the outcomes in patients with similar presentations.

Ethical Considerations

The case procedures and publication were approved by the local ethical committee of the Dhahran Eye Specialist Hospital (IRB: DESH1101). A written informed consent was obtained from the patient's parents, and they approved the publication of the patient's data and any accompanying images.

Funding

There is no funding to report.

Disclosure

The authors report no conflicts of interest in this work.

References

- Gould DB, John SWM. Anterior segment dysgenesis and the developmental glaucomas are complex traits. *Hum Mol Genet.* 2002;11(10):1185–1193. doi:10.1093/hmg/11.10.1185
- Harissi-Dagher M, Colby K. Anterior segment dysgenesis: peters anomaly and sclerocornea. *Int Ophthalmol Clin.* 2008;48:35–42. doi:10.1097/IIO.0b013e318169526c
- Hingorani M, Hanson I, van Heyningen V. Aniridia. *Eur J Hum Genet.* 2012;20(10):1011–1017. doi:10.1038/ejhg.2012.100
- Cheng F, Song W, Kang Y, Yu S, Yuan H. A 556 kb deletion in the downstream region of the PAX6 gene causes familial aniridia and other eye anomalies in a Chinese family. *Mol Vis.* 2011;17:448–455.
- Chang MS, Han JC, Lee J, et al. A novel splice site mutation in the PAX6 gene in a Korean family with isolated aniridia. *Ann Clin Lab Sci.* 2015;45(1):90–93.
- Kim W, Kim J, Cho N. Newly identified paired box 6 mutation of variant familial aniridia: congenital iris ectropion with foveal hypoplasia. *Indian J Ophthalmol.* 2017;65(1):55. doi:10.4103/0301-4738.202305
- Ivanov I, Shuper A, Shohat M, Snir M, Weitz R. Aniridia: recent achievements in paediatric practice. *Eur J Pediatr.* 1995;154(10):795–800. doi:10.1007/BF01959784
- Lambert SR, Lynn MJ, Hartmann EE, et al. Comparison of contact lens and intraocular lens correction of monocular aphakia during infancy: a randomized clinical trial of HOTV optotype acuity at age 4.5 years and clinical findings at age 5 years. *JAMA Ophthalmol.* 2014;132(6):676–682. doi:10.1001/jamaophthalmol.2014.531
- Manschot WA. [Congenital primary aphakia from the genetic point of view]. *Klin Monbl Augenheilkd.* 1969;154(1):1–11. German.
- Moreker M, Parikh R, Parikh SR, Thomas R. Aniridia associated with congenital aphakia and secondary glaucoma. *Indian J Ophthalmol.* 2009;57(4):313–314. doi:10.4103/0301-4738.53061
- Cheung CSY, VanderVeen DK. Intraocular lens techniques in pediatric eyes with insufficient capsular support: complications and outcomes. In: *Seminars in Ophthalmology*. Taylor & Francis; 2019:293–302.
- Epley KD, Shainberg MJ, Lueder GT, Tychsen L. Pediatric secondary lens implantation in the absence of capsular support. *J Am Assoc Pediatr Ophthalmol Strabismus.* 2001;5(5):301–306. doi:10.1067/mpa.2001.117567
- Karasavvidou E-M, Wilde C, Zaman A, Orr G, Kumudhan D, Panos GD. Surgical management of paediatric aphakia in the absence of sufficient capsular support. *J Ophthalmol.* 2021;2021:2253486. doi:10.1155/2021/2253486
- Numa A, Nakamura J, Takashima M, Kani K. Long-term corneal endothelial changes after intraocular lens implantation. Anterior vs posterior chamber lenses. *Jpn J Ophthalmol.* 1993;37(1):78–87.
- Kaushik S, Dubey S, Choudhary S, Ratna R, Pandav SS, Khan AO. Anterior segment dysgenesis: insights into the genetics and pathogenesis. *Indian J Ophthalmol.* 2022;70(7):2293–2303. doi:10.4103/ijo.IJO_3223_21
- Baudouin C, Kolko M, Melik-Parsadaniantz S, Messmer EM. Inflammation in glaucoma: from the back to the front of the eye, and beyond. *Prog Retin Eye Res.* 2021;83:100916. doi:10.1016/j.preteyeres.2020.100916
- Mahdavi Fard A, Pourafkari L, Nader ND. Sclerocornea. *QJM.* 2015;108(11):917. doi:10.1093/qjmed/hcv110
- Landsend ECS, Lagali N, Utheim TP. Congenital aniridia – a comprehensive review of clinical features and therapeutic approaches. *Surv Ophthalmol.* 2021;66(6):1031–1050. doi:10.1016/j.survophthal.2021.02.011
- Elhefney EM, Mokbel TH, Hagraas SM, et al. Micropulsed diode laser cyclophotocoagulation in recurrent pediatric glaucoma. *Eur J Ophthalmol.* 2020;30(5):1149–1155. doi:10.1177/1120672119858226
- Ahmed MR, Sethna S, Krueger LA, Yang MB, Hufnagel RB. Variable anterior segment dysgenesis and cardiac anomalies caused by a novel truncating variant of FOXC1. *Genes.* 2022;13(3). doi:10.3390/genes13030411
- Calvão-Pires P, Santos-Silva R, Falcão-Reis F, Rocha-Sousa A. Congenital aniridia: clinic, genetics, therapeutics, and prognosis. *Int Sch Res Not.* 2014;2014:305350.
- Bajwa A, Burstein E, Grainger RM, Netland PA. Anterior chamber angle in aniridia with and without glaucoma. *Clin Ophthalmol.* 2019;13:1469–1473. doi:10.2147/OPTH.S217930
- Aljazzaf AM, Abdelmoaty SMA, Behbehani AH, Abdulmuez AA, Aljazzaf HA. The outcome of the Ahmad Glaucoma Valve implantation for refractory glaucoma in Kuwait. *Saudi J Ophthalmol.* 2013;27(1):15–18. doi:10.1016/j.sjopt.2012.10.001
- Jacobson A, Mian SI, Bohnsack BL. Clinical outcomes and visual prognostic factors in congenital aniridia. *BMC Ophthalmol.* 2022;22(1):235. doi:10.1186/s12886-022-02460-5
- Chang JW, Kim JH, Kim S-J, Yu YS. Congenital aniridia: long-term clinical course, visual outcome, and prognostic factors. *Korean J Ophthalmol.* 2014;28(6):479–485. doi:10.3341/kjo.2014.28.6.479

26. Al Owaifeer AM, Almutairi AT, Schargel K. The outcomes of trans-scleral cyclophotocoagulation in pediatric glaucoma secondary to Sturge-Weber syndrome. *J AAPOS off Publ Am Assoc Pediatr Ophthalmol Strabismus*. 2022;26(2):78.e1–78.e5.
27. Mohammedsleh A, Raffa LH, Almarzouki N, et al. Surgical outcomes in children with primary congenital glaucoma: an eight-year experience. *Cureus*. 2020;12(8):e9602. doi:10.7759/cureus.9602
28. Kraus CL, Tychsen L, Lueder GT, Culican SM. Comparison of the effectiveness and safety of transscleral cyclophotocoagulation and endoscopic cyclophotocoagulation in pediatric glaucoma. *J Pediatr Ophthalmol Strabismus*. 2014;51(2):120–127. doi:10.3928/01913913-20140211-01
29. Bhasin P, Panday M, Dhanapal P. Globe rupture with aphakia, aniridia, secondary glaucoma and late corneal decompensation: a multi-staged approach to management. *Indian J Ophthalmol*. 2023;71(5):2263–2266. doi:10.4103/IJO.IJO_3068_22
30. Lee JH, Shi Y, Amoozgar B, et al. Outcome of micropulse laser transscleral cyclophotocoagulation on pediatric versus adult glaucoma patients. *J Glaucoma*. 2017;26(10):936–939. doi:10.1097/IJG.0000000000000757
31. Kuchar S, Moster MR, Reamer CB, Waisbourd M. Treatment outcomes of micropulse transscleral cyclophotocoagulation in advanced glaucoma. *Lasers Med Sci*. 2016;31(2):393–396. doi:10.1007/s10103-015-1856-9
32. Kirwan JF, Shah P, Khaw PT. Diode laser cyclophotocoagulation: role in the management of refractory pediatric glaucomas. *Ophthalmology*. 2002;109(2):316–323. doi:10.1016/S0161-6420(01)00898-3
33. Doane JF, Sajjadi H, Richardson WP. Bilateral penetrating keratoplasty for sclerocornea in an infant with monosomy 21. *Cornea*. 1994;13(5):454–458. doi:10.1097/00003226-199409000-00014
34. Sbordon S, Romano V, Savastano A, Piccirillo V, Savastano MC, Bifani M. Aniridia associated with lens coloboma and secondary glaucoma treated with transcorneal argon laser ciliary body photocoagulation: a case report. *Case Rep Ophthalmol*. 2013;4:44–47. doi:10.1159/000353356
35. Pohlmann D, Rossel M, Salchow DJ, Bertelmann E. Outcome of a penetrating keratoplasty in a 3-month-old child with sclerocornea. *GMS Ophthalmol Cases*. 2020;10:Doc35. doi:10.3205/oc000162
36. Al-Torbak AA, Al-Shahwan S, Al-Jadaan I, Al-Hommadi A, Edward DP. Endophthalmitis associated with the Ahmed glaucoma valve implant. *Br J Ophthalmol*. 2005;89(4):454–458. doi:10.1136/bjo.2004.049015
37. Zheng X, Xu G, Zhang K, et al. Assessment of human visual acuity using visual evoked potential: a review. *Sensors*. 2020;20(19):5542. doi:10.3390/s20195542
38. Konstas AG, Schmetterer L, Katsanos A, et al. Dorzolamide/timolol fixed combination: learning from the past and looking toward the future. *Adv Ther*. 2021;38(1):24–51. doi:10.1007/s12325-020-01525-5
39. Erdogan H, Ozec AV, Caner C, Toker MI, Arici MK, Topalkara A. Effect of latanoprost/timolol and dorzolamide/tiomolol on intraocular pressure after phacoemulsification surgery. *Int J Ophthalmol*. 2011;4(2):190–194. doi:10.3980/j.issn.2222-3959.2011.02.17

International Medical Case Reports Journal

Dovepress

Publish your work in this journal

The International Medical Case Reports Journal is an international, peer-reviewed open-access journal publishing original case reports from all medical specialties. Previously unpublished medical posters are also accepted relating to any area of clinical or preclinical science. Submissions should not normally exceed 2,000 words or 4 published pages including figures, diagrams and references. The manuscript management system is completely online and includes a very quick and fair peer-review system, which is all easy to use. Visit <http://www.dovepress.com/testimonials.php> to read real quotes from published authors.

Submit your manuscript here: <https://www.dovepress.com/international-medical-case-reports-journal-journal>