


Gallbladder Perforation with Choledochogastric Fistula Due to *Ascaris* Infestation, a Case Report

Ashenafi Amsalu, Yohannis Molla 

Department of Surgery, University of Gondar, College of Medicine and Health Sciences, Gondar, Ethiopia

Correspondence: Yohannis Molla, Email yderbew73@gmail.com

Abstract: We present a case of a 35-year-old Ethiopian female patient presented with right upper quadrant abdominal pain. Studies suspected gallbladder disease, for which she operated. Intraoperatively, gallbladder perforation with choledochogastric fistula was identified, with *Ascaris lumbricoides* (AL) worm in the common bile duct. Cholecystectomy was performed; common bile was repaired with T-tube and gastric repair. Patient was discharged 11 days after. On subsequent follow-up at the surgical referral clinic, the patient had no complaints.

Keywords: gallbladder perforation, fistulous communication, *Ascaris lumbricoides*, case report

Introduction

Given that it affects a quarter of the world's population, ascariasis is regarded as the most common helminthic infection.¹ *Ascaris lumbricoides* (AL), largest of human helminthic infections, is the parasite that causes ascariasis. It is a worldwide parasite. The jejunum is the adult worm's typical habitat. The larvae undergo a pulmonary migration phase during their maturity, and the route of transmission is ingestion of embryonized eggs.² The worm may cause symptoms twice during its life cycle: once while it is in its larval stage and causes symptoms owing to the deposition and inflammation of the alveoli, and once when it is an adult stage and is trapped in the small intestine, where it may release toxins and cause a systemic reaction. If the mature worms are present in large enough numbers, obstruction of the bowel, common bile duct or other hollow viscera, may result.³

In impoverished nations like Ethiopia, where the majority of the population lives in unhygienic conditions and lacks basic sanitation, ascariasis and other intestinal parasitosis are common. The consequences are therefore more common and pose a significant medical, social, and economic cost for these countries.^{1,4} According to one study conducted in Ethiopia, 6.2% of school-age children had AL.⁵ Appendicitis, gastrointestinal bleeding, hepatobiliary diseases including cholangitis or obstructive jaundice, pancreatitis, gallbladder perforation, intussusception, and bowel obstruction are just a few of the complications that patients with AL can develop.^{1,6,7} Even in endemic areas, hepatobiliary infestation is rare, although it can occasionally result in mechanical blockage, cholangitis or cholecystitis.⁸ However, gangrene and gallbladder perforation are incredibly rare, even at the highest levels of infestation.⁹ Here, we present a case of gallbladder perforation with choledochogastric fistula due to *Ascaris* infestation in a 35-year-old woman who was diagnosed intraoperatively.

Clinical Presentation

She is a 35-year-old Ethiopian female patient who presented with abdominal pain for 02 days which was initially epigastric and the right upper quadrant area but it became generalized one day later. Associated with the above symptoms, she has multiple episodes of vomiting and mild abdominal distension but no diarrhea or failure to pass feces or flatus. History revealed that the patient had had intermittent, moderately severe, epigastric burning pain for two

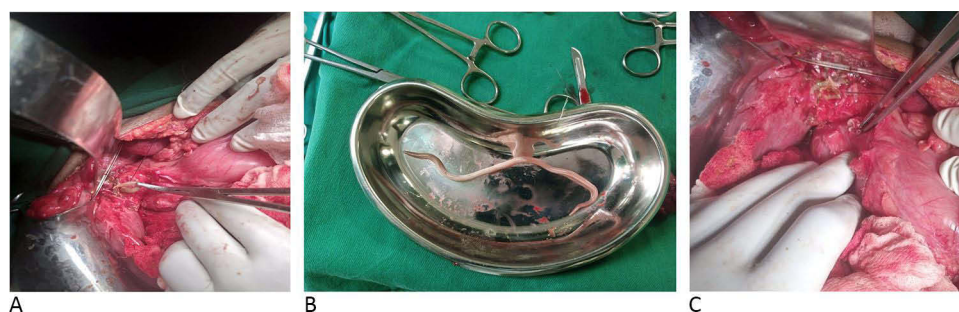

Figure 1 Intraoperative pictures showing (A) ascaris worm in the CBD, (B) ascaris worm after extraction, and (C) gastric and CBD perforations after release of the fistula (black arrow) shows the CBD fistula communication site and rose arrow shows gastric communications site.

years which was relieved with milk, and had a history of *Ascaris* passage via feces. Otherwise, she had unremarkable past medical and surgical histories.

On examination, she was acutely sick looking with a pulse rate of 138 beats per minute, respiratory rate of 32 breaths per minute, a temperature of 38.9°C, and blood pressure of 100/60mmHg. On abdominal examination, she had a mildly distended abdomen with diffuse guarding, and direct and rebound tenderness. On investigation, complete blood count (CBC) showed leukocytosis of 12,700 with 89% granulocytes. Liver function test results were within the normal limits except for low albumin of 2.2g/dl. Alkaline phosphatase was not determined. The erect plain abdominal x-ray did not show any air under the diaphragm or sign of obstruction.

With the preoperative diagnosis of generalized peritonitis secondary to likely perforated peptic ulcer disease, she was resuscitated with normal saline, a nasogastric tube inserted, and broad-spectrum antibiotics started (ceftriaxone 1gm IV and metronidazole 500mg IV), and, laparotomy was done. Intraoperatively, there was 600mL thick offensive pus all over the peritoneal cavity, there was mild interloop adhesion between the bowel loops. There was a 2*2 cm gallbladder perforation on the anterior part of the body with gastric content coming out through the perforation. There was adhesion between the posterior wall of the gallbladder, common bile duct (CBD), and distal antrum of the stomach (2 cm from the pylorus), and there was fistulous communication between the CBD and stomach where the gastric content was passing through. After the release of the fistulous tract, there was one large live ascaris inside the CBD (Figure 1A–C) and (Video 1). Therefore, for the above intraoperative findings: pus sucked out, cholecystectomy done, CBD repaired after placing catell type T-tube. Distal patency of the CBD was checked using a 10fr NG tube, stomach edges were refreshed and repaired and a drain was left in the subhepatic space. The abdomen was thoroughly washed with warm normal saline and abdomen was closed in layers and the skin was left open for wound care. Postoperatively, the patient was put on ceftriaxone 1gm IV twice a day, metronidazole 500mg IV three times a day, and diclofenac 50mg IV twice a day. She was also kept NPO and was put on MF for 72 hours. The patient had had 4 episodes of vomiting ascaris in the first two postop days. Later the patient started feeding and she tolerated it well. The T-tube was clamped starting from the fifth day. A T-tube cholangiogram was done on the 10th postop day and the CBD was patent and the T-tube removed. The patient had had a rough recovery in the early postoperative days complicated by hypokalemia but later she improved significantly, the potassium level normalized and was discharged improved after 11 days of hospital admission. The patient and the family members were dewormed with albendazole 400mg at discharge and advised on hygiene. On subsequent follow-up at the surgical referral clinic, the patient had no complaints. The histopathologic examination of the gallbladder showed signs of cholecystitis but no signs of malignancy.

Discussion

Gallstones frequently exacerbate gallbladder disease, a common condition that is susceptible to complications. These complications include the rare spontaneous (non-traumatic) gallbladder perforation (GBP), which has a mortality rate of 12 to 16% and an incidence of 0.8 to 15.0%.¹⁰ According to Neimeier, there are three different types of GBP: type I, which is chronic perforation with fistulous communication; type II, which is subacute perforation with a surrounding abscess that is contained by adhesions; and type III, which is acute perforation and spillage to the cavity with generalized biliary peritonitis.¹¹

According to Niemeier classification, our patient had type III perforation. Although ascaris is primarily found in the jejunum, it can also cause perforations in the terminal ileum, cecum, appendix, Meckel's diverticulum and very rarely the duodenum,¹² or stomach,¹³ gallbladder.⁹ Untreated sewage pollution, which is frequently associated with farming, poor hygiene, and malnutrition are risk factors for contracting this helminth infection. These elements contribute to higher infection rates in tropical nations like Ethiopia.¹⁴ The route of transmission involves ingesting raw vegetables or water containing embryonated eggs. Since adults do not multiply in humans, the symptoms depend on the amount of worms present in the intestine.¹⁵ The adult worm is a sizable, pink, cylindrical, elongated that tapers at both ends as depicted in the image. Due to its muscular activity, the adults worm keeps itself in the intestinal lumen.²

Abdominal pain, anorexia, nausea, vomiting, fever, dehydration, and abdominal distension are the most typical ascariasis symptoms. Obstructive jaundice is occasionally caused by biliary ascariasis.¹⁴ When there is a large parasite load in the intestine, wandering worms particularly cause gallbladder infestation. The size, sex, and age of the host are related factors.⁷ The affected organ determines how a patient with HBA presents clinically. Acute cholangitis and biliary colic are the two most frequent presentations, both of which cause a dull aching pain in the right upper quadrant.¹⁶ The transit of the worm to the pancreatic duct or obstruction of the common bile duct causes ascariasis-related pancreatitis, which can also result in pancreatic pseudocyst formation.¹⁷ In locations where *Ascaris* is endemic, gallbladder ascariasis is a severe clinical condition that primarily affects young women. Which occasionally has a perforation or manifest as acute cholecystitis.¹⁸

The identification of adult worms that has passed through the anus or any other body orifice, or the identification of AL eggs in the stool, vomitus, sputum or small bowel aspirate under a microscope, is required for a conclusive diagnosis of ascariasis. Due to distinctive appearance of adult worms, imaging is crucial in the diagnosis of both intestinal or hepatobiliary ascariasis.¹⁹ Using ultrasound (US), endoscopic retrograde cholangiopancreatography (ERCP), intravenous cholangiography, or CT scan, AL in the bile ducts (gallbladder) may be demonstrated. Since US is noninvasive, reasonably priced, and widely accessible even in developing nations, it is the preferred diagnostic method. Additionally, it is simple to repeat in order to evaluate the effectiveness of treatment.²⁰ US imaging of AL longitudinally reveals AL as a linear echogenic structure: a central sonolucent line that represents the digestive tract is flanked by two sets of parallel echogenic lines that indicate the body's boundaries. Transverse view reveals that the "ascaris resembles a bull's eye target with an echogenic body margin encircling an inner dot-line sonolucent digestive tract".²¹ The ERCP procedure can be performed to remove worms in addition to helping with duodenal and biliary ascariasis diagnosis. About one-third of patient with HBA are indicated for endoscopic interventional procedures such as worm extraction and biliary drainage, which have a high success rate for worm extraction. It has also little side effects and is quite successful at treating clinical symptoms.²² Inflammatory responses can be found via blood testing. However, due to significant cross-reactivity from infection with other helminthic organisms, antibodies are rarely useful. If HBA is present, a complete blood count may reveal eosinophilia. Depending on the severity of the biliary blockage, liver function tests such as bilirubin, transaminases, gamma GT, and alkaline phosphatase may also be increased. The only specific test is stool examination; however, this is frequently negative.¹⁴

Unless the patients appears with an emergent surgical condition, like our patient did, the treatment protocol for individuals with a diagnosis of HBA should begin with conservative care as the first line of treatment. The patient must kept on nothing per os (NPO), IV fluids, and anthelmintic and anticholinergic drugs must be given. When worms are in the biliary tree, there is no obvious activity against them due to the lack of enterohepatic circulation of the anthelmintics. The worms inside the duct are not killed by the anthelmintics. Therefore, the primary goal of the is to paralyze the parasite within the intestinal lumen rather than to combat those in the biliary tree. Worms living inside the ductal cavity should not do this.⁸ Worms can survive inside the ducts for up to three weeks before moving out into the duodenum. Therefore, under such circumstances, it is unnecessary to rush into an invasive procedure. However, endoscopic interventions may be necessary for worms that remain in the bile ducts for more than three weeks.²²

Similar to this, early-presenting individuals with intestinal ascariasis who has a low-grade fever or no fever, minimal abdominal distension, and modest widespread tenderness might be treated conservatively. At this point, no antihelminthic medication is administered because it would aggravate the obstruction by making the worm bolus bigger.²³ Albendazole (400 mg), mebendazole (500 mg), piperazine and pyrantel pamoate (preferred in the medical treatment of biliary

ascariasis) are the mainstays of medical treatment. These anthelmintic drugs work by preferentially destroying the cytoplasmic microtubules of the nematodes' intestinal cells while sparing the host, which leads to cellular instability and the loss of secretory and absorptive function. As a result, the parasite's golgi apparatus begins to accumulate secretory materials which reduce glucose intake and deplete its glycogen reserves.²⁴ For patients that do not respond to conservative therapy, endoscopic and open surgical methods are best.²⁵

An immediate laparotomy is recommended to control peritonitis in ascariasis patients who came with acute surgical conditions, as our patient.²⁶ HBA is often treated surgically with a combination of parasite removal, cholecystectomy and T-tube drainage. After exploring the CBD for ascariasis, T-tube implantation is advised. According to one study, 19% of patients experienced a recurrence of ascariasis in the CBD following a primary operation. Most individuals who used regular saline with the T-tube in situ had success flushing the worm out of the CBD.⁸

Limitation of the study: Preoperative imaging (ultrasound and/or CT scans) should have been done. However, it was not available at that time.

Conclusion

Ascaris lumbricoides is an unusual cause of gallbladder perforation and choledochogastric fistula, despite the worm's tendencies to probe tiny holes and ulcers. Our patient was diagnosed intraoperatively. The worm may have caused the perforation in our patient by converting a gastric ulcer into a frank perforation with fistulization to the CBD and subsequent blockage of the gallbladder. Finally, we advise all patients with upper abdomen pain in patient populations at risk to have ascariasis in the hepatobiliary system considered as a differential diagnosis.

Abbreviations

CBD, Common bile duct; CT, Computed tomography; ERCP, Endoscopic retrograde cholangiopancreatography; HBA, Hepatobiliary ascariasis; NG, Nasogastric tube; NPO, Nothing per os.

Data Sharing Statement

The authors of this case report are prepared to offer any further details about the case report upon request.

Ethical Clearance

The case report was submitted for the Ethical Board Review and was accepted as a report with strong ethical standards.

Consent

Written informed consent was taken from the patient for publication of this case report and any accompanying images. A copy of the written consent is available for review for the editor-in-chief of this journal on request.

Disclosure

The authors declare that there is no conflicts of interest in this work.

References

1. Charlorin P, Louima O, Pierre GS, et al. *Ascaris lumbricoides* causing peritonitis with multiple intestinal perforations: a case report. In Review; 2021. Available from: <https://www.researchsquare.com/article/rs-940439/v1>. Accessed August 1, 2023.
2. Khuroo MS. Ascariasis. *Gastroenterol Clin North Am*. 1996;25(3):553–577. doi:10.1016/S0889-8553(05)70263-6
3. McCort JJ. *Ascaris* ileus in children. *Radiology*. 2023;70(4):528–531. doi:10.1148/70.4.528
4. Mello CMG, Briggs M, do CF, Venâncio ES, Brandão AB, Queiroz Filho CC. Granulomatous peritonitis by *ascaris*. *J Pediatr Surg*. 1992;27(9):1229–1230. doi:10.1016/0022-3468(92)90795-9
5. Legesse M, Erko B. Prevalence of intestinal parasites among school children in a rural area close to the southeast of Lake Langano, Ethiopia. *Ethiop J Health Dev*. 2004;18(2). doi:10.4314/ejhd.v18i2.9947
6. Azhar M, Sheikh ASF, Khan A, Mustafa S, Shah IA, Hameed B. Hepatobiliary ascariasis complicated by pancreatitis. *J Ayub Med Coll Abbottabad*. 2015;27(2):479–481.
7. Mosawi SH, Dalimi A, Charkhi MA, et al. Gallbladder perforation due to *Ascaris lumbricoides* in a pregnant woman and 6 year old girl from Afghanistan: case report. *Iran J Parasitol*. 2019;14(3):477.

8. Astudillo JA, Sporn E, Serrano B, Astudillo R. Ascariasis in the hepatobiliary system: laparoscopic management. *J Am Coll Surg*. 2008;207(4):527–532. doi:10.1016/j.jamcollsurg.2008.05.020
9. Sharma A, Jariwala P, Kaur N. Biliary ascariasis presenting with gangrenous perforation of the gall bladder: report of a case and brief review of literature. *Trop Doct*. 2018;48(3):242–245. doi:10.1177/0049475518768103
10. Quiroga-Garza A, Alvarez-Villalobos NA, Muñoz-Leija MA, et al. Gallbladder perforation with fistulous communication. *World J Gastrointest Surg*. 2023;15(6):1191–1201. doi:10.4240/wjgs.v15.i6.1191
11. Niemeier OW. Acute free perforation of the gall-bladder. *Ann Surg*. 1934;99(6):922. doi:10.1097/00000658-193499060-00005
12. Refeidi A. Live *Ascaris lumbricoides* in the peritoneal cavity. *Ann Saudi Med*. 2007;27(2):118–121. doi:10.5144/0256-4947.2007.118
13. Gupta S, Kumar S, Satapathy A, Ray U, Chatterjee S, Choudhury TK. *Ascaris lumbricoides*: an unusual aetiology of gastric perforation. *J Surg Case Rep*. 2012;2012(11):rjs008. doi:10.1093/jscr/rjs008
14. Bhattacharya S, Taribagil P, Taribagil S, Bhattacharya V. Common bile duct obstruction due to ascariasis. *Biomed J Sci Tech Res*. 2020;28(2):21388–21392.
15. Darlington CD, Anitha GFS. Ascaridial volvulus: an uncommon cause of ileal perforation. *Iran J Med Sci*. 2018;43(4):432. doi:10.4103/1319-3767.48970
16. Temesgen R, Abebe H, Abera Y. Hepatobiliary and pancreatic duct ascariasis: an unusual cause of obstructive jaundice and severe acute cholangitis. *Int Med Case Rep J*. 2022;281–286. doi:10.2147/IMCRJ.S369442
17. da Bahú GS, Baldissaroto M, Custodio CM, Gralha CZ, Mangili AR. Hepatobiliary and pancreatic complications of ascariasis in children: a study of seven cases. *J Pediatr Gastroenterol Nutr*. 2001;33(3):271–275. doi:10.1097/00005176-200109000-00008
18. Javid G, Wani N, Gulzar GM, Javid O, Khan B, Shah A. Gallbladder ascariasis: presentation and management. *Br J Surg*. 1999;86(12):1526–1527. doi:10.1046/j.1365-2168.1999.01289.x
19. Das CJ, Kumar J, Debnath J, Chaudhry A. *Imaging of Ascariasis - Das - 2007 - Australasian Radiology*. Wiley Online Library; 2023. doi:10.1111/j.1440-1673.2007.01887.x
20. Aslam M, Dore SP, Verbanck JJ, De Soete CJ, Ghillebert GG. Ultrasonographic diagnosis of hepatobiliary ascariasis. *J Ultrasound Med*. 1993;12(10):573–576. doi:10.7863/jum.1993.12.10.573
21. Chawla A, Patwardhan V, Maheshwari M, Wasnik A. Primary ascaridial perforation of the small intestine: sonographic diagnosis. *J Clin Ultrasound*. 2003;31(4):211–213. doi:10.1002/jcu.10152
22. Khuroo MS, Zargar SA, Yattoo GN, et al. Worm extraction and biliary drainage in hepatobiliary and pancreatic ascariasis. *Gastrointest Endosc*. 1993;39(5):680–685. doi:10.1016/S0016-5107(93)70222-9
23. Steinberg R, Davies J, Millar A, Brown R, Rode H. Unusual intestinal sequelae after operations for *Ascaris lumbricoides* infestation. *Pediatr Surg Int*. 2003;19:85–87. doi:10.1007/s00383-002-0880-6
24. Garcia-Espinoza JA, Vásquez-Ciriaco S, Doña-Jaimes R, Aragon-Soto R, Velazco-Budar C, López-Martínez E. Parasitosis in the bile duct, report of 3 cases and literature review. *Rev Médica Hosp Gen México*. 2018;81:18–23. doi:10.1016/j.hgm.2016.06.009
25. Inyang B, Koshy FS, George K, et al. An overview of ascariasis involvement in gallbladder disease: a systematic review of case reports. *Cureus*. 2022;14(12). doi:10.7759/cureus.32545
26. Goyal N, Khurana N. Acute jejunal gangrene with perforation due to *Ascaris lumbricoides*. *Trop Gastroenterol*. 2012;33(1):85–86. doi:10.7869/tg.2012.21

International Medical Case Reports Journal

Dovepress

Publish your work in this journal

The International Medical Case Reports Journal is an international, peer-reviewed open-access journal publishing original case reports from all medical specialties. Previously unpublished medical posters are also accepted relating to any area of clinical or preclinical science. Submissions should not normally exceed 2,000 words or 4 published pages including figures, diagrams and references. The manuscript management system is completely online and includes a very quick and fair peer-review system, which is all easy to use. Visit <http://www.dovepress.com/testimonials.php> to read real quotes from published authors.

Submit your manuscript here: <https://www.dovepress.com/international-medical-case-reports-journal-journal>