

# Holistic Approach of a Leukemic Child Suffering from Oral Mucositis with Coinfections: A Case Report

Novia Tri Hasanah <sup>1</sup>, Tenny Setiani Dewi <sup>2</sup>

<sup>1</sup>Oral Medicine Residency Program, Department of Oral Medicine, Universitas Padjadjaran, Bandung, Indonesia; <sup>2</sup>Department of Oral Medicine, Universitas Padjadjaran, Bandung, Indonesia

Correspondence: Novia Tri Hasanah, Email novia20002@mail.unpad.ac.id

**Abstract:** Oral mucositis (OM) is a life-threatening side effect of chemo-radiotherapy. OM can provide a portal of entry for many microorganisms as coinfections which potentially generate other oral lesions. This case report describes a holistic approach to obtaining the successful treatment of OM with necrotizing ulcerative stomatitis (NUS) and oral candidiasis as coinfections in pediatric acute lymphoblastic leukemia (ALL). A 2-year-8-month-old boy was referred from the Pediatrics Department at Dr. Hasan Sadikin General Hospital with the chief complaint of canker sore and eating difficulty for the past two weeks. He had undergone the twelfth cycle of the last chemotherapy using methotrexate regimen. Extraoral examination revealed anemic conjunctiva, icteric sclera, and dry lips. Well-defined irregular multiple ulcers covered by yellowish to grayish pseudomembranous were found on the upper and lower labial mucosa, right and left buccal mucosa, tongue, palate, and gingiva. Potassium hydroxide (KOH) examination showed fungi in the oral lesions smear. The established diagnosis was OM with NUS and oral candidiasis as coinfections. Debridement was done using chlorine dioxide-zinc and 0.2% chlorhexidine gluconate. We collaborated with the pediatrician who prescribed ceftazidime, meropenem, and fluconazole, and also with parents. The holistic approach is beneficial and important in improving quality of life and supporting the successful treatment of OM with coinfections.

**Keywords:** oral mucositis, coinfections, holistic approach, chemotherapy, leukemia

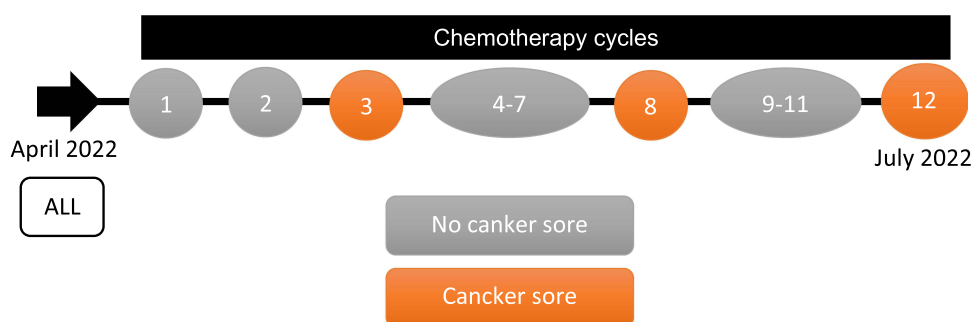
## Introduction

Leukemia is a hematological malignancy that attacks the bone marrow and blood circulation leading to a deficiency of erythrocytes (anemia), platelets (thrombocytopenia), and leukocytes, especially neutrophils (neutropenia). Acute lymphoblastic leukemia (ALL) is the most common malignancy in boys with a peak incidence between 2 and 5 years old.<sup>1</sup> Chemotherapy not only eliminates malignant cells, but also damages healthy cells and causes side effects such as constipation, diarrhea, mucositis, vomiting, and fatigue.<sup>2</sup> In general, mucositis occurs in more than 40% of patients treated with chemotherapy, while the severity varies depending on the therapy factor (regimen) and the patient's condition.<sup>3,4</sup> Ulceration in oral mucositis' (OM) clinical stages can be a portal of entry for microorganisms so coinfections can occur such as necrotizing ulcerative stomatitis (NUS) and oral candidiasis.<sup>5</sup>

The purpose of this case report is to describe the holistic approach to obtaining the successful treatment of OM with coinfections in a pediatric ALL patient. To date, treatment of OM still varies, depending on the symptoms, severity, and underlying condition of patients.<sup>6</sup> Consequently, a holistic approach is required including patient-parents cooperation, and interdisciplinary collaboration between oral medicine specialists and other colleagues, to create a comprehensive treatment.<sup>7</sup>

## Case

A 2-year-8-month-old boy patient was referred from the Pediatrics Department to the Oral Medicine Department of Dr. Hasan Sadikin General Hospital with chief complaints of canker sore and eating difficulty for the past two weeks. His



**Figure 1** The chronological appearance of canker sore during his chemotherapy cycles.

mother said initially painful red spots appeared one week after chemotherapy and worsen. She gave 1 mL of nystatin oral suspension and triamcinolone acetonide three times a day, but the canker sore did not heal.

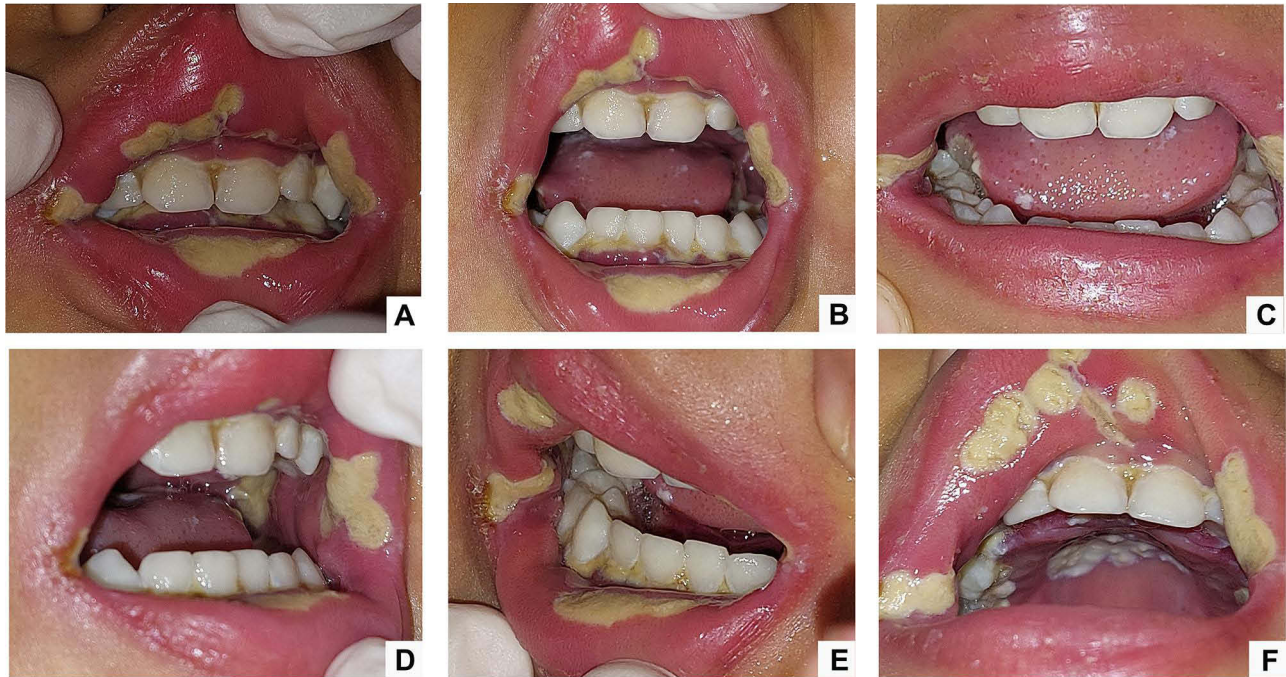
He was diagnosed with ALL on April 2022 and underwent chemotherapy until the twelfth cycle with methotrexate regimen (Figure 1). The thirteenth cycle of chemotherapy was delayed due to low platelet (Table 1), febrile neutropenia, and diarrhea. We also performed a potassium hydroxide (KOH) examination to ensure the diagnosis of oral candidiasis. The result was positive for spore, hypha, and budding cells of fungi.

**Table 1** Laboratory Investigations

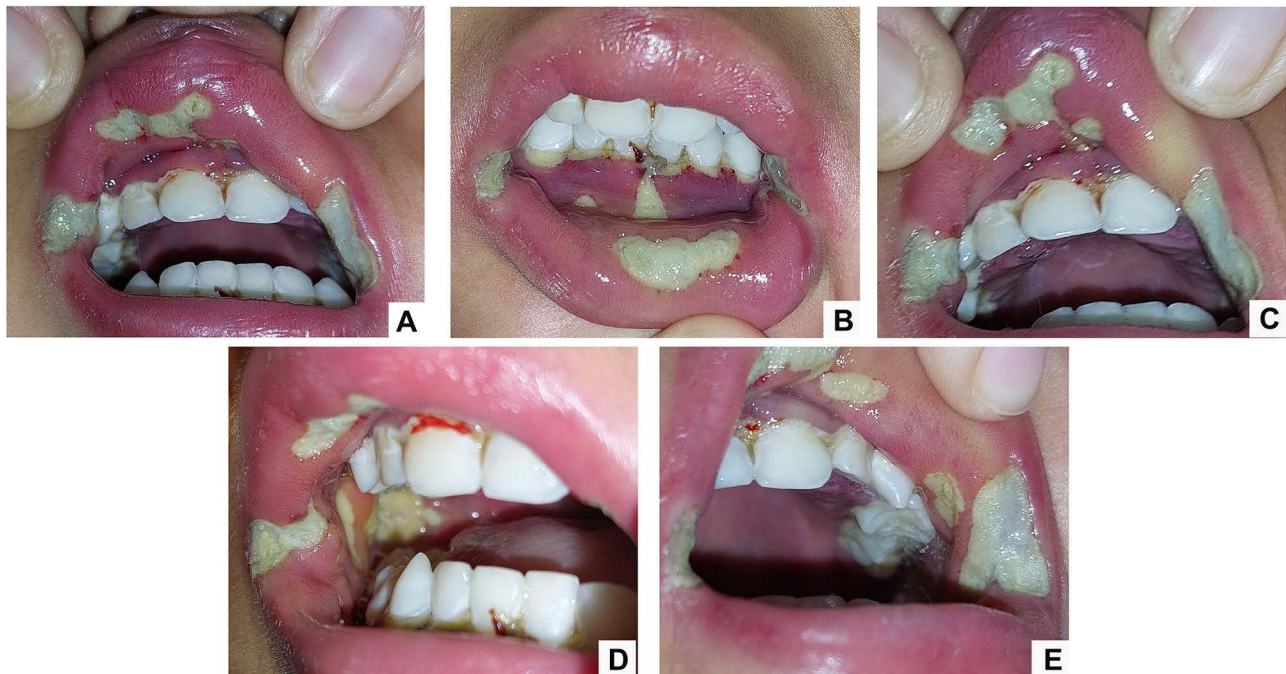
Blood Test (Unit)	Initial Visit	1 Week of Follow-Up	Normal
Hemoglobin (g/dL)	8.9 (L)	12.2	11.5–13.5
Hematocrit (%)	26.3 (L)	36.3	34–40
Erythrocyte ( $10^6/\mu\text{L}$ )	3.39 (L)	4.73	3.9–5.3
Leucocyte ( $10^3/\mu\text{L}$ )	1.08 (LL)	1.73 (LL)	5.5–15.5
Platelet ( $10^3/\mu\text{L}$ )	4 (LL)	113 (L)	150–450
MCV (fL)	77.6	76.7	75–87
MCH (pg)	26.3	25.8	24–30
MCHC (%)	33.8	33.6	31–37
Rod neutrophil (%)	0	0	3–5
Segment neutrophil (%)	0 (L)	6 (L)	27–55
Neutrophil total ( $10^3/\mu\text{L}$ )	0.00 (L)	0.10 (L)	1.31–6.71
CRP quantitative (mg/dL)	31.27 (H)	19.02 (H)	< 0.3
Urea (mg/dL)	14.2	11.2	10.9–35.9
Creatinine (mg/dL)	0.13 (L)	0.11 (L)	0.72–1.25
Sodium (mEq/L)	128 (L)	131 (L)	135–145
Potassium (mEq/L)	2.5 (L)	2.6 (L)	3.5–5.1
Ion calcium (mg/dL)	3.66 (L)	4.04 (L)	4.5–5.6
SGOT (U/L)	152 (H)	23	15–37
SGPT (U/L)	105 (H)	49	16–63

**Abbreviations:** L, low; LL, lower low; H, high.

Extraoral examination revealed anemic conjunctiva, icteric sclera, and dry lips. Intraoral examination (Figure 2) showed 15×5 mm to 20×8 mm of irregular multiple ulcers covered by non-scraped yellowish pseudomembranous with well-defined margin, on the upper and lower labial mucosa, right and left buccal mucosa, tongue, palate, and gingiva. One day after the first visit, the yellowish pseudomembranous became grayish and tended to bleed (Figure 3). He also had hypersalivation and

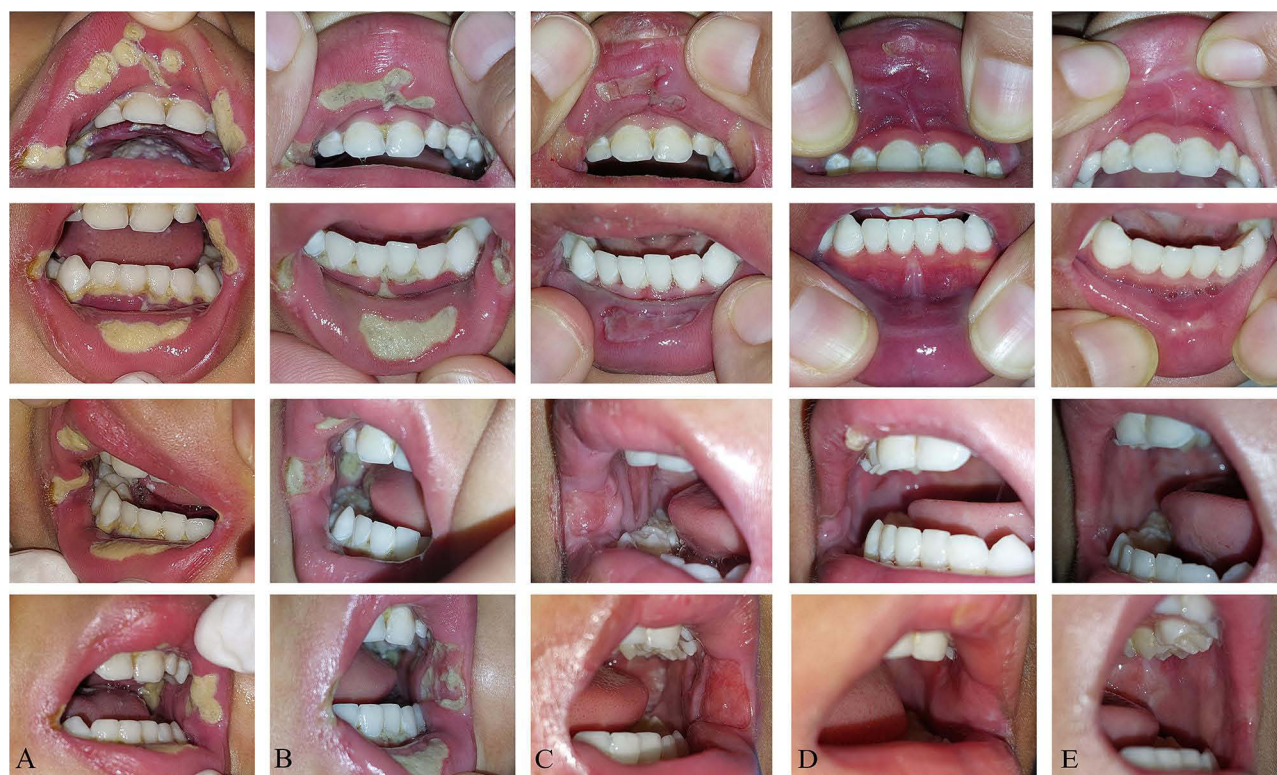

**Figure 2 (A–F)** The clinical features of the first visit showed yellowish pseudomembranous.



**Figure 3 (A–E)** One day after the first visit: Necrotic lesions bleed easily.





**Figure 4 (A–E)** The healing process of oral lesions: **(A)** Initial visit, **(B)** 3 days of follow-up, **(C)** 7 days of follow-up, **(D)** 20 days of follow-up, **(E)** 3 months of follow-up.

halitosis. The established diagnosis was OM grade 3 (WHO), NUS, and oral candidiasis. One week after treatment (Figure 4), he could eat and drink normally because the oral lesions significantly improved. A month later, the oral lesions disappeared but left the scar tissue.

## Case Management

The pharmacological therapy included systemic and topical medications. The systemic medications were proposed by the operator to the pediatrician regarding the administration of the meropenem injection because of the presence of necrotic tissue related to bacterial infection. Other systemic medications were ceftazidime and fluconazole injection. The topical medications included debridement using chlorine dioxide-zinc and 0.2% chlorhexidine gluconate. The 100% petroleum jelly was also applied to moisturize the lips. After the necrotic tissue disappeared, we prescribed hyaluronic acid-aloe vera to fasten the healing process.

The non-pharmacological therapy instruction was given to his mother, including stopping nystatin and triamcinolone acetonide, providing adequate hydration, taking a soft diet intake, and maintaining oral hygiene (brushing teeth with gauze moistened by 0.9% NaCl) two times a day. We also advised sucking ice cubes during the next chemotherapy as a preventive therapy for OM. We did not perform dental management because the dental was still in good condition.

## Discussion

Children undergoing chemotherapy will experience some degree of mucositis up to 80%, although the incidence of OM varies according to the type of cancer, treatment regimen, low body weight, high level of anxiety, vomiting, and previous history of mucositis.<sup>8,9</sup> The severity of OM depends on the factors of therapy (regimen, dose, duration of chemotherapy, and concomitant chemoradiation therapy) and the factors of patient (age, gender, body mass index, poor oral hygiene, presence of dentures, diabetes, oral lesions, malnutrition, neutropenia, deficiency of folic acid and vitamin B12, drugs consumed, salivary hypofunction or xerostomia, and tobacco use).<sup>3,4,10</sup>

The chemotherapy regimen used in this patient was methotrexate. In 2017, Gutierrez-Camino et al found a significant association between the presence of SNP rs10505168 in the miR-2053 sequence and an increased risk of developing OM in children receiving methotrexate treatment for ALL.<sup>11</sup> miRNAs control the expression of genes involved in pharmacokinetic or pharmacodynamic pathways. SNPs within miRNAs can affect miRNA levels and function, and influence target genes in pharmacokinetic or pharmacodynamic pathways.<sup>12</sup> Methotrexate is known to be specifically secreted in saliva, thereby promoting direct OM.<sup>3</sup> Methotrexate is also an antimetabolite that affects the rapid division of normal cells, including oral mucosal epithelial cells, gastrointestinal epithelial cells, and bone marrow cells. Therefore, OM is often the initial clinical feature as a manifestation of methotrexate toxicity.<sup>13</sup>

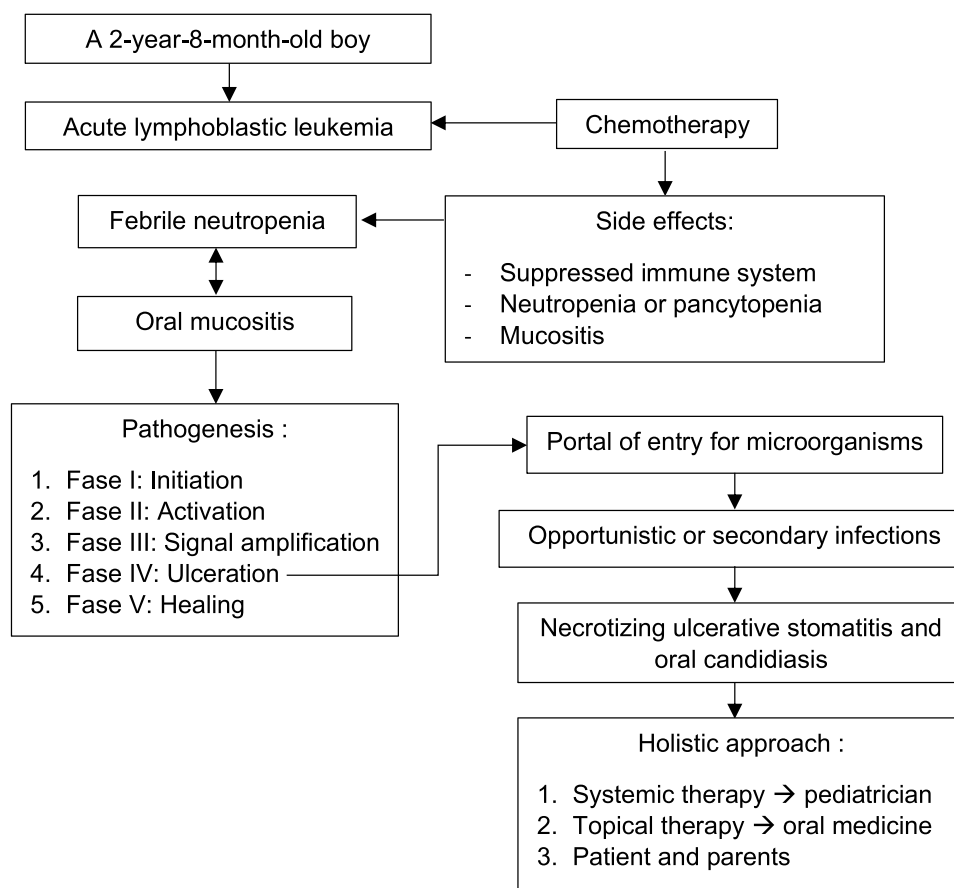
The ulceration phase in OM is the most symptomatic phase for the patient. The products of bacterial metabolism can exacerbate oral mucosal damage and stimulate the release of additional pro-inflammatory cytokines.<sup>3,7,14</sup> According to the literature, the onset of OM began on the third to tenth day after chemotherapy and the lesions could persist for three weeks. The peak of OM occurs on the seventh to fourteenth day and will heal slowly unless it is exacerbated by infection.<sup>8</sup> Oral complaints and lesions in this patient began one week after the twelfth cycle of chemotherapy and persisted until the fourteenth day which worsened due to febrile neutropenia and suppressed immune system. The ulcerative phase of OM can provide a portal of entry for microorganisms and inflammatory products into the bloodstream, thereby contributing to febrile neutropenia.<sup>15</sup> Febrile neutropenia and OM are two interconnected things because the clinical improvement of OM also correlates with neutrophil recovery.<sup>8,15</sup> In addition, OM in the ulceration phase causes disturbances in food intake, oral drug use, and oral hygiene, which can increase the risk of infection.<sup>5</sup> Microbial risk factors also play a role including herpes simplex virus (HSV) type 1, *Candida* species, and non-specific bacterial infections.<sup>8,9</sup> The healing of OM, in this case, was delayed because of the presence of *Candida* infection and bacterial infection (NUS) as coinfections.

Despite numerous studies conducted in recent years, there is no standardized and effective therapy to control this side effect.<sup>6</sup> The management of this case was carried out through a holistic approach of interdisciplinary collaboration between the Department of Pediatrics and Oral Medicine. Systemic therapy was provided by the pediatrician including injections of fluconazole, ceftazidime, and meropenem. Fluconazole is the drug of choice for most *Candida* infections and the most recommended antifungal agent.<sup>16</sup> Ceftazidime is a broad-spectrum antibiotic of the third-generation cephalosporin class with a mechanism of action by binding to penicillin-binding proteins (PBPs) thereby inhibiting peptidoglycan crosslinking during cell wall synthesis which in turn causes bacterial cell lysis and cell death.<sup>17</sup> Similar to ceftazidime, meropenem is also bactericidal which can fight gram-positive, gram-negative, and anaerobic bacteria by binding to PBPs on the bacterial cell wall and inhibiting peptidoglycan cross-linking which in turn causes cell death.<sup>18</sup>

Chlorine dioxide releases oxygen to kill the anaerobic bacteria. It also has antiviral, anti-fungicidal, and antibacterial effects, and maintains a normal pH in the oral cavity, while zinc has an important role in the body's physiological processes, including immune system defense, cell membrane stability, and wound healing by increasing protein and nucleic acid synthesis, as well as increase oxygen transfer.<sup>19,20</sup> The use of chlorhexidine gluconate is intended to produce more potent antimicrobial effect and prevent secondary infections.<sup>3,10</sup> We also gave hyaluronic acid-aloe vera after the necrotic tissue disappeared. Hyaluronic acid is found naturally in the body which is an important part of the extracellular matrix, functions in cell signaling and wound repair which is generally excreted by cells such as fibroblasts and chondrocytes.<sup>21</sup> Aloe vera, according to a study from Muaaz et al, can inhibit several stages of the pathobiology of mucositis.<sup>22</sup> These comprehensive therapies had a significant effect on the improvement of oral lesions within one week. The summary of this case report can be seen in Figure 5. This case report has received approval and full consent from the patient's mother for the publication of data and images. Meanwhile, his mother was satisfied with these treatments. The institution has approved the publication of this case report.

## Conclusion

A holistic approach including collaboration among dentists especially oral medicine specialists, the pediatrician, and the patient-parents, is significantly important to obtain the successful treatment of OM with coinfections. Appropriate therapy also supports an adequate healing process along with optimal nutrition intake.



**Figure 5** The summary of this case report.

## Acknowledgments

The authors thank Universitas Padjadjaran for funding this publication. We also thank the patient, his mother, and the Department of Pediatrics, Faculty of Medicine, Universitas Padjadjaran/Dr. Hasan Sadikin General Hospital for the opportunity to collaborate.

## Disclosure

The authors report no conflicts of interest in this work.

## References

1. Hunger SP, Mullighan CG. Acute lymphoblastic leukemia in children. *N Engl J Med*. 2015;373:1541–1552. doi:10.1056/NEJMra1400972
2. Pearce A, Haas M, Viney R, et al. Incidence and severity of self-reported chemotherapy side effects in routine care: a prospective cohort study. *PLoS One*. 2017;12:1–12. doi:10.1371/journal.pone.0184360
3. Oronsky B, Goyal S, Kim MM, et al. A review of clinical radioprotection and chemoprotection for oral mucositis. *Transl Oncol*. 2018;11:771–778. doi:10.1016/j.tranon.2018.03.014
4. Cinausero M, Aprile G, Ermacora P, et al. New frontiers in the pathobiology and treatment of cancer regimen-related mucosal injury. *Front Pharmacol*. 2017;8:1–16. doi:10.3389/fphar.2017.00354
5. Zecha JA, Raber-Durlacher JE, Laheij AM, et al. The potential contribution of dental foci and oral mucositis to febrile neutropenia in patients treated with myelosuppressive chemotherapy for solid tumors and lymphoma. *Front Oral Heal*. 2022;3:1–9. doi:10.3389/froh.2022.940044
6. Elad S, Cheng KKF, Lalla RV, et al. MASCC/ISOO clinical practice guidelines for the management of mucositis secondary to cancer therapy. *Cancer*. 2020;126:4423–4431. doi:10.1002/cncr.33100
7. Kusiak A, Alicjajereczek-Fossa B, Cichońska D, et al. Oncological-therapy related oral mucositis as an interdisciplinary problem—literature review. *Int J Environ Res Public Health*. 2020;17:2464. doi:10.3390/ijerph17072464
8. Miller MM, Donald DV, Hagemann TM. Prevention and treatment of oral mucositis in children with cancer. *J Pediatr Pharmacol Ther*. 2012;17:340–350. doi:10.5863/1551-6776-17.4.340

9. Elad S, Yarom N, Zadik Y, et al. The broadening scope of oral mucositis and oral ulcerative mucosal toxicities of anticancer therapies. *CA Cancer J Clin.* **2022**;72:57–77. doi:10.3322/caac.21704
10. Basile D, Di Nardo P, Corvaja C, et al. Mucosal injury during anti-cancer treatment: from pathobiology to bedside. *Cancers.* **2019**;11:1–22. doi:10.3390/cancers11060857
11. Gutierrez-Camino A, Oosterom N, Den Hoed MAH, et al. The miR-1206 microRNA variant is associated with methotrexate-induced oral mucositis in pediatric acute lymphoblastic leukemia. *Pharmacogenet Genomics.* **2017**;27:303–306. doi:10.1097/FPC.0000000000000291
12. Gutierrez-Camino A, Umerez M, Lopez-Lopez E, et al. Involvement of miRNA polymorphism in mucositis development in childhood acute lymphoblastic leukemia treatment. *Pharmacogenomics.* **2018**;19:1403–1412. doi:10.2217/pgs-2018-0113
13. Lee HJ, Kwon JS, Choi YC, et al. Methotrexate-induced oral mucositis. *J Oral Med Pain.* **2015**;40:82–87. doi:10.14476/jomp.2015.40.2.82
14. Shetty SS, Maruthi M, Dhara V, et al. Oral mucositis: current knowledge and future directions. *Disease-A-Month.* **2022**;68:101300. doi:10.1016/j.disamonth.2021.101300
15. Zecha JA, Raber-Durlacher JE, Laheij AM, et al. The impact of the oral cavity in febrile neutropenia and infectious complications in patients treated with myelosuppressive chemotherapy. *Support Care Cancer.* **2019**;27:3667–3679. doi:10.1007/s00520-019-04925-8
16. Santos GC, Vasconcelos CC, Lopes AJO, et al. Candida infections and therapeutic strategies: mechanisms of action for traditional and alternative agents. *Front Microbiol.* **2018**;9:1–23. doi:10.3389/fmicb.2018.01351
17. Shirley M. Ceftazidime-avibactam: a review in the treatment of serious gram-negative bacterial infections. *Drugs.* **2018**;78:675–692. doi:10.1007/s40265-018-0902-x
18. Baldwin CM, Lyseng-Williamson KA, Keam SJ. Meropenem: a review of its use in the treatment of serious bacterial infections. *Drugs.* **2008**;68:803–838. doi:10.2165/00003495-200868060-00006
19. Kerémi B, Márta K, Farkas K, et al. Effects of chlorine dioxide on oral hygiene - a systematic review and meta-analysis. *Curr Pharm Des.* **2020**;26:3015–3025. doi:10.2174/1381612826666200515134450
20. Oshvandi K, Vafaei SY, Kamallan SR, et al. Effectiveness of zinc chloride mouthwashes on oral mucositis and weight of patients with cancer undergoing chemotherapy. *BMC Oral Health.* **2021**;21:1–9. doi:10.1186/s12903-021-01706-w
21. Dovedyitis M, Liu ZJ, Bartlett S. Hyaluronic acid and its biomedical applications: a review. *Eng Regen.* **2020**;1:102–113. doi:10.1016/j.engreg.2020.10.001
22. Alkhouli M, Laffouf M, Comisi JC. Assessing the topical application efficiency of two biological agents in managing chemotherapy-induced oral mucositis in children: a randomized clinical trial. *J Oral Biol Craniofacial Res.* **2021**;11:373–378. doi:10.1016/j.jobcr.2021.04.001

## International Medical Case Reports Journal

Dovepress

### Publish your work in this journal

The International Medical Case Reports Journal is an international, peer-reviewed open-access journal publishing original case reports from all medical specialties. Previously unpublished medical posters are also accepted relating to any area of clinical or preclinical science. Submissions should not normally exceed 2,000 words or 4 published pages including figures, diagrams and references. The manuscript management system is completely online and includes a very quick and fair peer-review system, which is all easy to use. Visit <http://www.dovepress.com/testimonials.php> to read real quotes from published authors.

Submit your manuscript here: <https://www.dovepress.com/international-medical-case-reports-journal-journal>