


Urethral Injury After Vaginal Birth and Stress Urinary Incontinence: Bulking Agents are Feasible Options

Marta Barba¹ , Matteo Frigerio² , Tomaso Melocchi¹, Desirée De Vicari¹, Alice Cola²

¹Gynecology and Obstetric Department, University of Milano-Bicocca, Monza, Italy; ²Gynecology and Obstetric Department, Fondazione IRCCS San Gerardo Dei Tintori, Ospedale San Gerardo, Monza, Italy

Correspondence: Marta Barba, University of Milano-Bicocca, ASST Monza, Ospedale San Gerardo, via G.B. Pergolesi, 33, Monza, 20900, Italy, Tel +39 2339434, Email m.barba8792@gmail.com

Introduction and Hypothesis: Lower urinary tract tears after vaginal delivery are a very rare event, estimated to occur in 0.03–0.05% of women and may be associated with severe stress urinary incontinence, due to great reduction of urethral resistance resulting in a significant intrinsic urethral deficit. Urethral bulking agents represent an alternative, minimally invasive anti-incontinence procedure in the management of stress urinary incontinence. Our aim is to present the management of severe stress urinary incontinence in a patient with concomitant urethral tear caused by obstetric trauma using a minimally invasive treatment option.

Methods: A 39-year-old woman referred to our Pelvic Floor Unit for severe stress urinary incontinence. Our evaluation demonstrated an undiagnosed urethral tear involving the ventral portion of the middle and distal urethra, for about 50% of urethral length. Urodynamic evaluation confirmed the presence of severe urodynamic stress incontinence. After proper counseling, she was admitted to mini-invasive surgical treatment with urethral bulking agent injection.

Results: The procedure was completed in 10 minutes and she was successfully discharged home on the same day, and no complications occurred. The treatment resulted in total relief of urinary symptoms, which persists at 6-month follow-up.

Conclusion: Treatment with urethral bulking agent injection represents a feasible mini-invasive option to manage stress urinary incontinence related to urethral tears.

Keywords: urinary incontinence, bulking agents, obstetric tear, pelvic floor ultrasound

Introduction

Stress urinary incontinence (SUI) is defined as any involuntary leakage of urine with activity such as laughing, coughing, and sneezing.¹ The etiology, like other pelvic floor disorders (PFDs), is related to pelvic floor weakening and/or tears, usually due to obstetric trauma. Stress-related urinary leakage may involve serious consequences on quality of life, sexuality, and well-being.² Conservative management involves pelvic floor muscle training, functional electrical stimulation, magnetic stimulation, and vaginal laser therapy.^{3,4} Surgical treatment of SUI is indicated when conservative management fails.⁵ Among surgical techniques, mid-urethral slings are considered the gold standard of treatment, due to their long-term efficacy.^{6,7} However, despite high efficacy and low complication rates, debates have been raised regarding mesh-related adverse sequelae, leading to the 2018 UK ban of midurethral tape.^{8,9} Consequently, alternative anti-incontinence procedures have been evaluated, with a particular interest in the urethral bulking agents (UBAs) as a minimally invasive alternative technique in the management of SUI.¹⁰ The procedure consists of injections of the agent (such as polyacrylamide hydrogel) into the submucosal tissues of the urethra to increase the coaptation of the urethral walls, leading to increased urethral resistance and improved continence. UBAs may be injected by transurethral or paraurethral approaches under urethroscopic control. Three to four injections are performed at 0.5–1 cm distal to the bladder neck in a circumferential distribution. The principal advantages of this surgical strategy are the reduced rate of adverse events, the chance of proposing these procedures to patients with severe comorbidities or with a modified anatomy in which the urethral length is too short to ensure a mid-urethral sling positioning.¹⁰

The latter condition represents a rare cause of SUI and may occur as a consequence of surgery or after delivery. Specifically, lower urinary tract tears after vaginal delivery are a very rare event, estimated to occur in 0.03–0.05% of women.¹¹ Operative vaginal delivery and extensive perineal damage are thought to be related to lower urinary tract injuries.¹² Among them, tears to the middle-distal urethra extended to the external urethral meatus may be associated with severe stress urinary incontinence, due to a great reduction of urethral resistance resulting in a significant intrinsic urethral deficit. The management can be challenging, especially if the lesion is not recognized at the moment of delivery and primary repair is not performed. In particular, secondary urethral reconstruction may be associated with a significant risk of failure and stricture,¹³ and standard sling surgery may not be feasible if the mid urethra is involved in the tear. On the contrary, urethral bulking agents (UBAs) may represent a minimally invasive alternative technique in the management of stress urinary incontinence after urethral tear.¹⁴

With this paper, we aimed to present the management of severe stress urinary incontinence in a patient with concomitant urethral tear caused by obstetric trauma using a minimally invasive treatment option.

Method

We present a case of a 39-year-old woman referred to our Pelvic Floor Unit for severe stress urinary incontinence and deviated urinary stream since the last delivery. She previously had pelvic floor muscle training and functional electrical stimulation without benefits. Our evaluation demonstrated an undiagnosed urethral tear involving the ventral portion of the middle and distal urethra, for about 50% of urethral length (Figure 1). Preoperative sonographic evaluation with an endocavity linear transducer showed an 18mm shortened urethra (Figure 2). Urodynamic evaluation confirmed the presence of severe urodynamic stress incontinence, without detrusor overactivity and voiding dysfunction. After proper counseling, she was admitted to mini-invasive surgical treatment with urethral bulking agent injection. Local IRB approval and written informed consent were obtained from the patient for publication of this case report and any accompanying images.

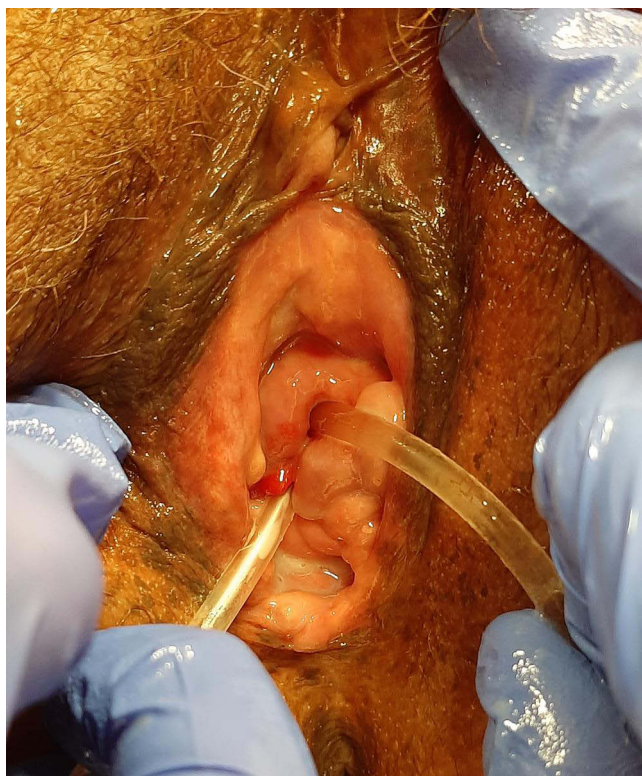

Figure 1 Clinical evaluation demonstrating the urethral damage. One Nelaton catheter is positioned through the former external urethral meatus, while another one demonstrates the tear through the ventral portion of the middle and distal urethra.

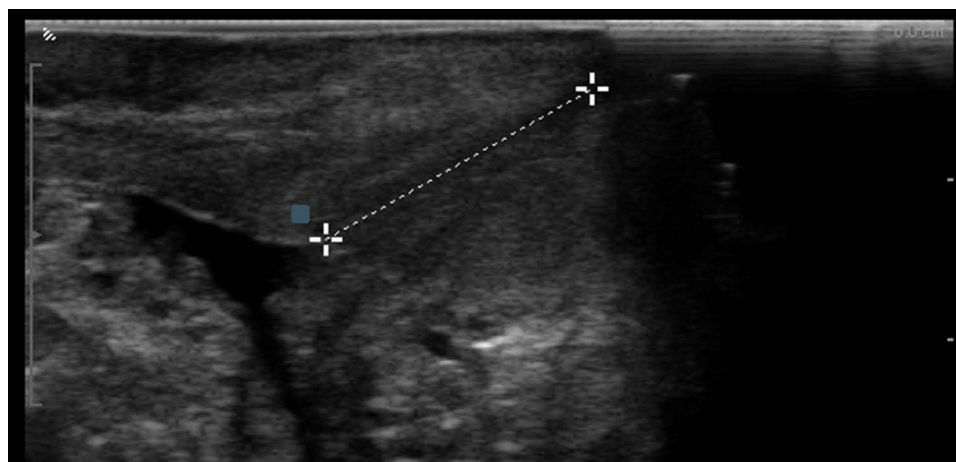


Figure 2 Preoperative transvaginal midsagittal sonographic view of the urethra, using an endocavitary linear probe. Ultrasound evaluation showed a shortened urethra – measuring 18mm – due to an undiagnosed obstetric urethral tear.

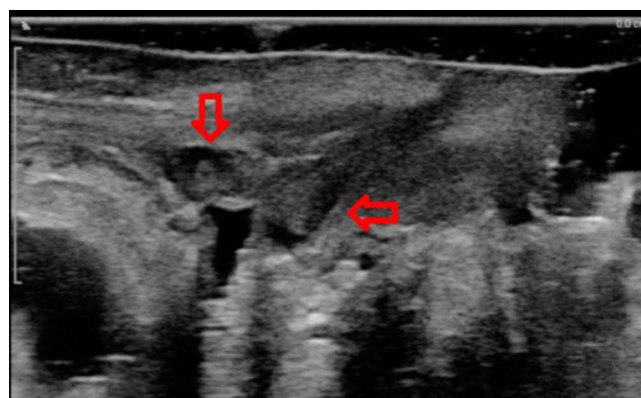


Figure 3 Postoperative transvaginal midsagittal sonographic view of the urethra, using an endocavitary linear probe. Ultrasound evaluation demonstrated the presence of bulking agent locations (arrows) in the proximal urethra.

Results

The patients underwent the injections of polyacrylamide hydrogel into the submucosal tissues at 2, 4, 8, and 10 o'clock 1 cm distal to the bladder neck. The procedure was completed in 10 minutes, and blood loss was negligible. She was successfully discharged home on the same day, and no complications occurred. The treatment resulted in total relief of urinary symptoms, which persists at current follow-up (6 months). Postoperative sonographic evaluation demonstrated the presence of bulking material locations in the proximal urethra (Figure 3).

Discussion

Urethral bulking agents represent a minimally invasive technique in the management of SUI, which can be performed in the office under local anesthesia, on patients with severe comorbidities and have a reduced rate of adverse events. UBAs are rarely used in clinical practice as a first-line option for SUI treatment because of insufficient evidence¹⁵ but its adoption has been suggested principally in women affected by recurrent SUI. A current review reported subjective and quality-of-life success rates between 32.7% and 90% after a period of follow-up between 3 and 24 months. When a follow-up longer than 24 months was evaluated, literature reported a rate of success of 42% (96-month follow-up) and 49% (at a mean of 58-month follow-up).^{16,17} The objective success rates, evaluated through the cough stress test and the 24 h-pad test, resulted between 32.7% and 83.6% at a follow-up between 3 and 24 months, while it was 49% at 58 months.¹⁷

We presented a case of a woman reporting severe SUI with a concomitant obstetrics urethral tear who underwent first-line treatment with the injection of urethral bulking agents. Obstetric trauma is secondary to prolonged or neglected labor with pressure necrosis of the urethra and/or other structures against the pubis. Decreased tissue perfusion can lead to ischemic necrosis and loss of tissue.¹³ In these cases, urinary incontinence is likely to manifest.

Treatment of obstetrics urethral tears is challenging. Outcome data for female urethral reconstruction are limited primarily due to small sample sizes in heterogeneous, qualitative studies that lack consistent outcome measures and have short follow-up. In addition, secondary urethral reconstruction is associated with a potentially greater risk of incontinence and neurosensory dysfunction.¹³ If the mid-urethra is involved in the tear, the gold standard MUS cannot be performed. As a consequence, to induce the coaptation of the urethral walls and consequently to increase urethral resistance with the injection of bulking agents into the submucosal tissues of the urethra, seems to be a minimally invasive alternative surgical option.

Conclusion

To the best of our knowledge, this represents the first reported case of stress urinary incontinence related to an undiagnosed obstetric urethral tear. Treatment with urethral bulking agent injection represents a feasible mini-invasive option to manage stress urinary incontinence related to urethral tears.

Data Sharing Statement

The data that support the findings of this study are available from the corresponding author, upon reasonable request.

Informed Consent Statement

Written informed consent was obtained from the patient for publication of this case report and any accompanying images.

Author Contributions

All authors made a significant contribution to the work reported, whether that is in the conception, study design, execution, acquisition of data, analysis and interpretation, or in all these areas; took part in drafting, revising or critically reviewing the article; gave final approval of the version to be published; have agreed on the journal to which the article has been submitted; and agree to be accountable for all aspects of the work.

Funding

There is no funding to report.

Disclosure

The authors report no conflicts of interest in this work.

References

1. Bo K, Frawley HC, Haylen BT, et al. An International Urogynecological Association (IUGA)/International Continence Society (ICS) joint report on the terminology for the conservative and nonpharmacological management of female pelvic floor dysfunction. *Neurourol Urodyn*. 2017;36:221–244. doi:10.1002/nau.23107
2. Frigerio M, Barba M, Cola A, et al. Quality of life, psychological wellbeing, and sexuality in women with urinary incontinence-where are we now: a narrative review. *Medicina*. 2022;58(4):525. PMID: 35454364; PMCID: PMC9025831. doi:10.3390/medicina58040525
3. Frigerio M, Barba M, Cola A, et al. Flat magnetic stimulation for stress urinary incontinence: a prospective comparison study. *Bioengineering*. 2023;10:295. doi:10.3390/bioengineering10030295
4. Ruffolo AF, Braga A, Torella M, et al. Vaginal laser therapy for female stress urinary incontinence: new solutions for a well-known issue-A concise review. *Medicina*. 2022;58(4):512. PMID: 35454351; PMCID: PMC9028572. doi:10.3390/medicina58040512
5. Rovner ES, Wein AJ. Treatment options for stress urinary incontinence. *Rev Urol*. 2004;6(Suppl 3):S29–47.
6. Braga A, Castronovo F, Ottone A, et al. Medium term outcomes of TVT-abbrev for the treatment of stress urinary incontinence: efficacy and safety at 5-year follow-up. *Medicina*. 2022;58(10):1412. PMID: 36295573; PMCID: PMC9607369. doi:10.3390/medicina58101412
7. Frigerio M, Milani R, Barba M, et al. Single-incision slings for the treatment of stress urinary incontinence: efficacy and adverse effects at 10-year follow-up. *Int Urogynecol J*. 2021;32(1):187–191. PMID: 32902762. doi:10.1007/s00192-020-04499-8
8. Gurol-Urganci I, Geary RS, Mamza JB, et al. Long-term rate of mesh sling removal following midurethral mesh sling insertion among women with stress urinary incontinence. *JAMA*. 2018;320:1659–1669. doi:10.1001/jama.2018.14997

9. Department of Health and Social Care. Update on the Independent Medicines and Medical Devices Safety Review, 10 July 2018: written statement - HCWS841. London: UK Parliament; 2018. Available from: www.parliament.uk/business/publications/written-questions-answers-statements/written-statement/Commons/2018-07-10/HCWS841. Accessed May 8, 2023.
10. Serati M, Braga A, Salvatore S, et al. Up-to-date procedures in female stress urinary incontinence surgery: a concise review on bulking agents procedures. *Medicina*. 2022;58(6):775. PMID: 35744038; PMCID: PMC9227870. doi:10.3390/medicina58060775
11. Muraca GM, Boutin A, Razaz N, et al. Maternal and neonatal trauma following operative vaginal delivery. *CMAJ*. 2022;194(1):E1–E12. PMID: 35012946; PMCID: PMC8800478. doi:10.1503/cmaj.210841
12. Kattan SA. Maternal urological injuries associated with vaginal deliveries: change of pattern. *Int Urol Nephrol*. 1997;29(2):155–161. PMID: 9241541. doi:10.1007/BF02551335
13. Faiena I, Koprowski C, Tunuguntla H. Female urethral reconstruction. *J Urol*. 2016;195(3):557–567. PMID: 26478448. doi:10.1016/j.juro.2015.07.124
14. Smith A, Bevan D, Douglas HR, James D. Management of urinary incontinence in women: summary of updated NICE guidance. *BMJ*. 2013;347:f5170. doi:10.1136/bmj.f5170
15. Kirchin V, Page T, Keegan PE, Atiemo KO, Cody JD, McClinton S. Urethral injection therapy for urinary incontinence in women. *Cochrane Database Syst Rev*. 2017;25:CD003881. doi:10.1002/14651858.CD003881.pub4
16. Mouritsen L, Lose G, Møller-Bek K. Long-term follow-up after urethral injection with polyacrylamide hydrogel for female stress incontinence. *Acta Obs Gynecol Scand*. 2014;93:209–212. doi:10.1111/aogs.12283
17. Serati M, Soligo M, Braga A, et al. Efficacy and safety of polydimethylsiloxane injection (Macroplastique) for the treatment of female stress urinary incontinence: results of a series of 85 patients with ≥ 3 years of follow-up. *BJU Int*. 2019;123:353–359. doi:10.1111/bju.14550

International Journal of Women's Health

Dovepress

Publish your work in this journal

The International Journal of Women's Health is an international, peer-reviewed open-access journal publishing original research, reports, editorials, reviews and commentaries on all aspects of women's healthcare including gynecology, obstetrics, and breast cancer. The manuscript management system is completely online and includes a very quick and fair peer-review system, which is all easy to use. Visit <http://www.dovepress.com/testimonials.php> to read real quotes from published authors.

Submit your manuscript here: <https://www.dovepress.com/international-journal-of-womens-health-journal>