

Objective Assessment of the Long-Term Volumizing Action of a Polycaprolactone-Based Filler

Maria Angelo-Khattar^{1,2}

¹American Academy of Anti-aging Medicine, Dubai, United Arab Emirates; ²Altaderma Clinic, Dubai, United Arab Emirates

Correspondence: Maria Angelo-Khattar, Tel +971 506245494, Email maria.khattar@altaderma.com

Background: The polycaprolactone-based filler, (PCL-1, Ellansé-S), forms part of the recently growing portfolio of biodegradable collagen-stimulating fillers. It is comprised of a suspension of 25–50 micron diameter microspheres of polycaprolactone (PCL) (30%) in a carboxymethyl cellulose (CMC) gel carrier (70%) and has gained popularity due to its long-term volumizing action.

Objective: This study outlines a retrospective case series of nine patients injected with the PCL-1, for volume augmentation in the mid-face. Objective volume calculations were performed with the Canfield Vectra 3D Imaging System at two time points post-implantation, with the objective of determining the longevity of the volumizing effect of the bio-stimulating substance.

Results: A clear increase in volume, between 50–150%, was found in all of the patients at two years, over and above the volume initially injected. All the patients were satisfied with the longevity of the results.

Discussion: The PCL-based filler is believed to afford immediate volume restoration due to the CMC gel component and a long-term action due to neo-collagenesis, induced by the PCL microspheres. The CMC gel is known to dissipate within 6–8 weeks, only to be replaced by new collagen induced by the PCL particles. Thus soft-tissue formation induced by the PCL particles, ultimately leads to a sustained volumizing effect.

Conclusion: The PCL-based filler is shown to have a sustained volumizing effects of at least 2 years duration with clear evidence of increase in volume over and above the volume injected, in all of the cases studied. This is indicative of significant neo-collagenesis induced by the PCL microspheres.

Keywords: polycaprolactone, biostimulant, Vectra 3D

Introduction

The popularity of fillers for soft-tissue augmentation has increased dramatically in recent years. These medical devices offer impressive aesthetic improvements in facial contouring and rejuvenation, previously only achievable with surgery. According to the latest statistics of the American Academy of Plastic Surgeons (ASPS), 3.4 million soft tissue filler procedures were performed in 2020 and the procedure ranked second amongst the top five cosmetic minimally invasive procedures after neuromodulator injections.¹

The current spectrum of soft-tissue fillers is classified as three main types; permanent non-biodegradable fillers (polyacrylamide, polymethyl methacrylate, silicone), the biodegradable hyaluronic acid products and biodegradable collagen-stimulating polymers. Permanent materials are generally not approved by most countries world-wide due to their potential for inducing long-term and mostly irreversible complications. Several of these fillers are associated with delayed persistent granulomas, sometimes many years post implantation.

The hyaluronans are, without a doubt, the most widely used soft-tissue filler substances globally, despite the fact that repeat injections are required to maintain the aesthetic correction. The Hyaluronans are natural compounds and are hence susceptible to metabolism by endogenous hyaluronidase enzyme. Therefore, their longevity has generally been shown to be between 6–12 months. The durability of each hyaluronic acid filler depends upon the extent and type of cross-linkage as well as the concentration and particle size of each specific product. Furthermore, although Hyaluronic acid fillers are of great value in restoring facial volume, they have limited long-term bio-stimulating effects.^{2,3}

In the early 2000's, the search for biodegradable filler substances with good safety profiles and a longer duration of action, resulted in the development of a new generation of collagen-stimulating fillers. Two of these substances, Radiesse (calcium hydroxylapatite filler, Merz aesthetics) and Sculptra (poly-L-lactic acid, Galderma, USA) were FDA approved in 2001 and 2004, respectively. In 2009, a polycaprolactone-based soft tissue filler (Ellansé, Sinclair Pharma, London, UK) obtained CE marking as a Class III medical device and has gained popularity in Europe and many countries worldwide. All three bio-stimulating compounds are particulate substances between 25–50 microns in size that elicit an inflammatory reaction resulting in encapsulation of the particles and the prevention of their migration. The particles induce type I and type III collagen as well as new soft tissue formation, resulting in long-lasting cosmetic correction, which may in some cases persist for well over 2 years.^{4,5}

The composition of the PCL-based filler comprises round smooth PCL microspheres (30% by volume) homogeneously suspended in aqueous carboxymethyl cellulose gel (70% by volume). A range of the PCL-based fillers are produced depending on the chain length (molecular weight) of the polymer and currently PCL-1 (Ellansé-S) and PCL-2 (Ellansé-M) are available as soft tissue fillers. Both CMC and PCL are classified as GRAS (Generally Recognised as Safe) by the FDA (Food and Drug Administration, USA) and have been used for many years as resorbable devices. PCL is a major component of Monocryl™ (Ethicon, Inc; Somerville, New Jersey, USA), a well-known suturing material used in surgery for many years.⁶ PCL is also used in various drug delivery systems such as Capronor™, the biodegradable contraceptive capsule made of PCL containing levonorgestrel.^{7,8}

Both animal and human studies have shown the PCL-filler to be a bio-stimulant. The longevity of the aesthetic effects of PCL-1 and PCL-2 was investigated in a prospective randomised study.⁹ Forty subjects were treated with either of the PCL-based fillers, for the correction of the nasolabial folds. The effects were evaluated with the Wrinkle Severity Rating Scale (WSRS) and/or the Global Aesthetic Improvement Scale (GAIS) by subjects and investigators based on photos, at different time frames post treatment. At 12 months, the efficacy outcomes on the WSRS and GAIS of both PCL-1 and PCL-2 were found to be 90% and 91.3% respectively. At 24 months patient satisfaction was high in both cases at 81.5% for PCL-2 and 72.4% for PCL-1.

The PCL-based filler has also been studied in other areas such as the forehead and hands. Bae et al¹⁰ showed the efficacy on forehead augmentation in 58 Asian subjects up to 24 months post injection. A pilot study on the use of PCL-filler for hand rejuvenation showed a decrease in visible signs of ageing.¹¹

A review of the literature did not reveal any objective volume evaluation to assess the longevity of the aesthetic correction achieved by the PCL-based filler. The study presented is the first to investigate retrospectively the longevity of the PCL-based filler using a 3D imaging system.

Three-dimensional (3D) imaging systems for the face and body are currently employed for research and surgical planning. The Canfield 3D stereophotogrammetric camera and software (Vectra; Canfield Scientific, Fairfield, NJ) is being increasingly employed in computerised volume calculation post breast augmentation, filler injections and cryolipolysis.^{12–15} The imaging system has been shown to be reproducible and reliable and the 3D system measurement show a linear relationship with Magnetic Resonance Imaging.¹⁶

Materials and Methods

This is a retrospective analysis of nine female Caucasian subjects, aged 35–55 years, treated with PCL-based filler (PCL-1) on the malar area of the face. All of the subjects had not previously had any other filler injected into the face and were free from any dermatologic or systemic conditions.

The subjects were all models treated during the Aesthetics Anti-aging Injectables courses conducted by the American Academy of Anti-Aging Medicine (A4M).

Ethical approval for the injection of the subjects during the hands-on training session was obtained from Dubai Healthcare City authority (United Arab Emirates Government Body), prior to the course.

Consent was obtained from the participants for the publication of their images. Analysis of the data was done by the International Director of the A4M (author).

Injection Technique

All subjects receiving filler injections, were pre-treated with an infraorbital anaesthetic nerve block (2% xylocaine +1:80,000 adrenaline). The PCL-based filler was then injected onto the supra-periosteal plane in the malar area on both sides of the face, with a 22 Gx50mm blunt-tipped cannula.

Imaging

The Vectra 3D Imaging system (Canfield Imaging Systems, Fairfield, N.J) was used for all pre-op and post-op photos. The system contains six cameras and captures images in 180 degrees. Standardized full face 2D and 3D images are generated. The high resolution 3D images produced by the Vectra software can be used for both qualitative volume visualisation and quantitative volume measurements. Standardized full-face 2D and 3D digital surface imaging were taken of the nine models at baseline and then at two time points after injection. The first set of images post treatment was taken between 9–19 months and the second set of images was taken at 24 months. Data from the nine models were analysed by importing the baseline and the post treatment images into the Vectra mirror analysis 3D software. The mid-face region was selected in each case and highlighted as the area to be measured. Change in mid-face volume was computed by registering each of the post-treatment images against the baseline image. All volume measurements were recorded in millilitres.

Furthermore, qualitative volume visualization of the degree of contour change was made possible with a colour distance map. (see [Figure 1](#)).

Results

All of the patients were satisfied with the longevity of their results and none of the patients experience any treatment emergent adverse events.

Written informed consent for publication of the images and details was obtained from the patient in each case.

Qualitative Data

[Figure 1](#) is representative of colour distance maps indicating a qualitative change in volume over time. The colour scale is shown whereby green is baseline and any increase in volume manifests incrementally as yellow and red.

[Figure 1](#) represents a 38-year-old subject who had been injected with a total volume of 1.0cc of PCL-1 on both malar areas. The yellow and intense red colours are indicative of volume increase from baseline, seen at one year and then two years post treatment.

Quantitative Data

[Table 1](#) shows the total volume of PCL filler injected for each of the patients. Unfortunately, the time of first assessment was not consistent for all the models as they did not abide by the 1-year time frame requested for the first post operative photo. Although we therefore cannot extrapolate information from the first time point volume measurement, we can clearly see from the data that in all the cases, the volume at first assessment was greater than that originally injected.

Fortunately, the time of second assessment was consistently at 2 years post-treatment, since the models were offered further complimentary treatments if they appeared for evaluation at that time. A clear increase at the two year time point is evident of between 50–150% over baseline ([Table 1](#)). The variation in percentage increase may be explained by inter-individual differences in mounting a collagen response. This may be explained by differences in patient's health status, age and lifestyle.

Discussion

There are 12 types of collagens found in human skin, of which types I and III are the most important. Type I collagen fibres, which are the most abundant components of the extracellular matrix, are of high tensile strength and impart force

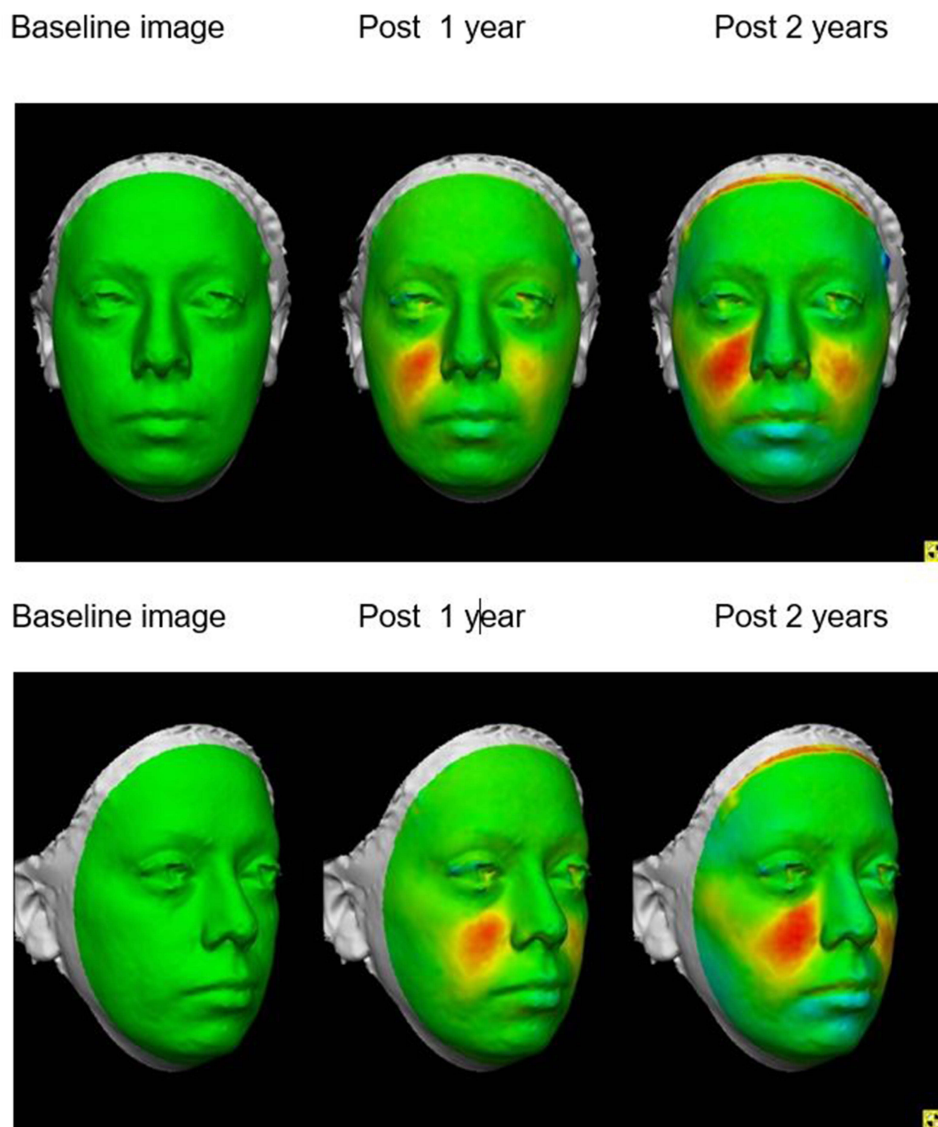


Figure 1 Frontal and profile colour distance maps of 38-year old patient injected with a total volume of 1.0cc of PCL- filler both malar areas.

and resilience to the skin.¹⁷ It is important to note that Type I collagen has a very long half-life of 15 years¹⁸ and hence, any procedure which induces the production of this type of collagen, imparts long lasting anti-aging effects.

Currently, only three compounds have been classified as collagen stimulating fillers, namely PLLA, CaHA and PCL. These agents predominantly owe their volumizing action to the induction of new soft tissue, namely collagen types III and I. The efficacy of these bio-stimulating agents in inducing neo-collagenesis and new soft tissue formation is contingent upon an inherent property of the polymer and the persistence of the bio-stimulant in the tissue to allow for long-term fibroblast activation. Of the three collagen stimulating agents, only PCL and PLLA have been consistently shown to have long-term clinical efficacy whereas CaHA, histologically shown to induce type I and III collagen synthesis, shows great discrepancies in the literature regarding the duration of clinical effect, ranging anywhere from only 6 to 24 months with several studies demonstrating limited clinical efficacy^{19–25} with the filler. A recent objective evaluation of the longevity of the CaHA-based filler in human subjects, using quantitative 3D evaluation, has shown a clear decline in volume of 65–96% over five months.²⁵ Considering the long half-life of type I collagen, it stands to reason that any bio-stimulating filler should ultimately be replaced by endogenous soft tissue, resulting in long-term clinical efficacy. Hence treatment with an effective bio-stimulating substance, should in the least result in persistence of

Table I Total Volume in Malar Areas of Patients at Two Time Points Post Injection

Patient Code	Age	Total Volume Injected (cc)	Time of 1st Assessment (Months)	Volume at 1st Assessment (cc)	Time of 2nd Assessment (Months)	Volume at 2nd Assessment (cc)	Percentage Increase 24 Months (%)
A	42	1	19	2.93	24	1.9	90
B	40	1	9	1.2	24	2.0	100
C	35	1	12	2.6	24	2.5	150
D	37	1	17	2.4	24	1.8	80
E	44	2	16	5.0	24	3.0	50
F	40	2	14	5.4	24	5.0	150
G	46	2	12	2.2	24	5.0	150
H	39	2	11	3.4	24	4.8	140
I	37	2	12	4.7	24	3.8	90

Note: *All participants were white female patients.

the injected volume or ideally an increase in volume, over and above the amount injected. Hence the biostimulating effects of CaHA seem to be short-lived. On the other hand, there is substantial evidence for the fact that the other biostimulating agents, PLLA and PCL have long lasting clinical effects.

PLLA has been shown to have a volumizing action of between 2 to 3 years.^{26–32} PLLA is a biodegradable and biocompatible polyhydroxyacid that does not augment the skin directly but has an indirect effect due to neocollagenesis.^{31,32} When injected into the tissue, the particles of PLLA degrade over time, only to be replaced by the patients' own collagen, a process that persists for up to 25 months.^{31,32} Typically repeat injections of PLLA are required, every 6–8 weeks, to induce an effective clinical response. Normally at least 3–4 sessions are required in most cases.

Unlike PLLA, the PCL-based filler, offers both an immediate increase in volume, due to the CMC gel component, and a sustained effect due to collagen stimulation. In most cases, only one session of the PCL-base filler is sufficient for effective volume augmentation. The PCL microspheres have been shown to persist in the tissue for over twenty-one months post injection resulting in primary collagen type I formation.^{9,33,34}

Various studies have demonstrated the collagen stimulating effects of PCL. Implantation of PCL-1 and PCL-2 in rabbits stimulated the formation of new collagen around the microspheres. Biopsies of tissue stained with Picrosirum red showed type III and type I collagen present at 9 months post implantation and then predominantly type I collagen was found around the microspheres at 21 months post implantation.^{9,34,35} In a pilot study by Kim and Van Abel,³⁵ two patients willing to undergo temple lifting surgery, were injected in the temporal area with the PCL-filler and biopsies were taken at 13 months post-injection. Histological analysis revealed collagen type III and type I formation around the microspheres. In a later study, Kim³⁶ investigated the effect on dermal thickness of injections of diluted PCL-filler. Thirteen patients with thin skin each received a single injection of 3cc of diluted PCL (0.5cc) in the dermis of the forehead, anterior cheek, and temple, however, the right temple was spared to act as an intra-individual control. At one year, patients underwent temple lifting surgery, during which time ultrasound measurements were performed to assess skin thickness and skin biopsies were taken. The mean thickness of facial skin at one year was found to increase by 21%. Immunohistochemistry revealed many fibroblasts and foreign body giant cells as well as evidence of neovascularisation with new capillaries forming around the microspheres. PCL-induced type I collagen and elastin fibres, were present at six months post implantation.

Previous studies have estimated the duration of action of PCL-1 as being at least 18 months.^{9–11,33–36} This has now been corroborated by the quantitative data presented in this retrospective study, which shows a clear and definite increase in volume of 50–150%, over baseline at two years. The significant augmentation induced by PCL-1 over and above the

volume of filler initially injected indicates the stimulation of high levels of type I collagen. Hence extrapolating from the fact that Type I collagen has a long half-life, we may assume that the volume augmentation with PCL-1 should persist well over the 2 year time frame. There is no doubt that further objective studies are warranted to assess the longevity of the clinical effect of the filler and whether or not soft-tissue augmentation continues beyond two years. Furthermore, the limitation of this study is the small sample size and a larger scale prospective study is warranted to further investigate these findings.

These findings imply that a conservative approach should be adopted with respect to the volume injected for correction of the face with the PCL-based filler, to allow for the significant augmentation that may occur with time. This may pose a disadvantage for use of this filler as under-correction is required and ultimately, the final aesthetic correction may not be predictable solely on the basis of the volume injected.

Conclusion

Polycaprolactone is a proven biostimulant as shown by histological evaluation. The objective volume assessments performed with the Canfield Vectra 3D analysis system, showed a clear increase in volume with time at two years post implantation. This significant volume augmentation can only be explained by the powerful neo-collagenesis induced by the PCL microspheres.

Disclosure

The author reports no conflicts of interest in this work.

References

1. American Society of Plastic Surgeons (ASPS). Plastic surgery statistics report; 2020. Available from: <https://www.plasticsurgery.org/documents/News/Statistics/2020/plastic-surgery-statistics-report-2020pdf>. Accessed November 1, 2022.
2. Keen MA. Hyaluronic acid in dermatology. *Skinmed*. 2017;15(6):441–448.
3. Lee W, Hwang S-G, Oh W, et al. Practical guidelines for hyaluronic acid soft-tissue filler use in facial rejuvenation. *Dermatol Surg*. 2020;46(1):41–49. doi:10.1097/DSS.0000000000001858
4. Breighaupt A, Fitzgerald R. Collagen stimulators poly-L-lactic acid and calcium hydroxyl apatite. *Facial Plast Surg Clin North Am*. 2015;23(4):459–469. doi:10.1016/j.fsc.2015.07.007
5. De Melo F, Nicolau P, Piovano L, et al. Recommendations for volume augmentation and rejuvenation of the face and hands with the new generation polycaprolactone-based collagen stimulator (Ellanse®). *Clin Cosmet Investig Dermatol*. 2017;10:431–440. doi:10.2147/CCID.S145195
6. Bezwada RS, Jamolkowski DD, Lee IY, et al. Monocryl suture, a new ultra-pliable absorbable monofilament suture. *Biomaterials*. 1995;16(15):1141–1148. doi:10.1016/0142-9612(95)93577-Z
7. Ma G, Song C, Sun H, Yang J, Leng X. A biodegradable levonorgestrel-releasing implant made of PCL/F68 compound as tested in rats and dogs. *Contraception*. 2006;74(2):141–147. doi:10.1016/j.contraception.2006.02.013
8. Woodward SC, Brewer PS, Moatamed F, Schindler A, Pitt CG. The intracellular degradation of poly(epsilon-caprolactone). *J Biomed Mater Res*. 1985;19(4):437–444. doi:10.1002/jbm.820190408
9. Moers Carpi, MM, Sherwood, S. Polycaprolactone for the correction of nasolabial folds: a 24-month, prospective, randomised, controlled clinical trial. *Dermatol Surg*. 2013;9:457–463.
10. Bae B, Lee G, Oh, S. Safety and long-term efficacy of forehead contouring with a polycaprolactone-based dermal filler. *Dermatol Surg*. 2016;42(11):1256–1260.
11. Figueredo VM. A five patient prospective pilot study of a polycaprolactone based dermal filler for hand rejuvenation. *J Cosmet Dermatol*. 2013;12(1):73–77.
12. Garibyan L. Three-dimensional volumetric quantification of fat loss following cryolipolysis. *Lasers Surg Med*. 2014;46():75–80. doi:
13. Lowe P, Lowe NJ. Three-dimensional digital surface imaging measurement of the volumizing effect of injectable Poly-L-lactic acid for nasolabial folds. *J Cosmet Laser Ther*. 2011;13:87–94.
14. Killaars RC, Preub MLG, deVos NJP. Clinical Assessment of breast volume: Can 3D imaging be the gold standard?. *Plast Reconstr Surg Glob Open*. 2020;8:e3236.
15. Landau MJ, Kim JS, Gould DJ. Vectra 3D imaging for quantitative volumetric analysis of the upper limb: A feasibility study for tracking outcomes of lymphedema treatment. *Plast Reconstr Surg*. 2018;141:80e–84e.
16. DeMenzes M, Rosati R, Ferrario VF, Sforza, C, et al. Accuracy and reproducibility of a 3-dimensional stereophotogrammetric imaging system *J Oral Maxillofac Surg*. 2010;68:2129–2135.
17. Lin J, Shi Y, Men Y, et al. Mechanical roles in of oriented collagen fibers. *Tissue Engineering part B Reviews*. 2020;26(2):116–128. doi:
18. Verzijl N, DeGroot J, Thorpe SR, Bank RA. Effect of collagen turnover on the accumulation of advanced glycation end products. *J Biol Chem*. 2000;275 50 :39027–29031.
19. Simunovic F, Schlager S, Montanari M. Prospective 3D analysis of facial soft tissue augmentation with calcium hydroxylapatite. *J Cosmet Laser Ther*. 2017;19:283–289.
20. Loghem JV, Yutskovskaya YA, Werschler WP, et al. Calcium hydroxylapatite: over a decade of clinical experience. *J Clin Aesthet Dermatol*. 2015;8:38–49.

21. Emer J, Sundaram H, et al. Aesthetic applications of calcium hydroxylapatite volumizing filler: an evidence-based review and discussion of current concepts: (part 1 of 2). *J Drugs Dermatol*. 2013;12():1345–1354.
22. Tzikas TL. A 52-month summary of results using calcium hydroxylapatite for facial soft tissue augmentation. *Dermatol Surg*. 2008;34 1 :S9–S15.
23. Sadick SN, Katz EB, Roy D. A multicenter, 47-month study of safety and efficacy of calcium hydroxylapatite for soft tissue augmentation of nasolabial folds and other areas of the face. *Dermatol Surg*. 2007;33:S122–S126.
24. Jacovella PF. Use of calcium hydroxylapatite (Radiesse®) for facial augmentation. *Clin Interv Aging*. 2008;3:161–174.
25. Angelo-Khattar M. Objective evaluation of the longevity of a calcium hydroxylapatite-based filler (Radiesse). *J Clin and Cosmet Dermatology*. 2021;5(2):1–5.
26. Butterwick K, Lowe, NJ. Injectable poly-L-lactic acid for cosmetic enhancement: learning from the European experience. *J Am Acad Dermatol*. 2009;61():281–293.
27. Lorenc ZP. Techniques for the optimization of facial and nonfacial volumization with injectable poly-L-lactic acid. *Aesthetic Plast Surg*. 2012;36:1222–1229.
28. Levy RM, Redbord, KP, Hanke, CW. Treatment of HIV lipoatrophy and lipoatrophy of aging with poly-L-lactic acid: a prospective 3-year follow-up study. *J Am Acad Dermatol*. 2008;59:923–933.
29. Lowe NJ, Maxwell, CA, Lowe, P. Injectable poly-L-lactic acid: 3 years of aesthetic experience. *Dermatol Surg*. 2009;35 1 :344–349.
30. Vleggar D. Facial volumetric correction with injectable poly-L-lactic acid. *Dermatol Surg*. 2005;31:1511–1517.
31. Narins RS, Baumann L, Brandt FS. A randomized study of the efficacy and safety of injectable poly-L-lactic acid versus human-based collagen implant in the treatment of nasolabial fold wrinkles. *J Am Acad Dermatol*. 2010;62:448–462.
32. Gogolweskin S, Jovanovic M, Perren SM. Tissue response and in vivo degradation of selected polyhydroxyacids: polylactides (PLA), poly(3-hydroxybutyrate) (PHB), and poly(3-hydroxybutyrate-co-3-hydroxyvalerate) (PHB/VA). *J Biomed Mater Res*. 1993;27():1135–1148.
33. Christen MO, Vercesi, F. How a Well-Known and Futuristic Polymer Has Become an Innovative Collagen-Stimulator in Esthetics. *Clin, Cosmetic and Invest Dermatol*. 2020;13:31–48.
34. Nicolau PJ, Marijnissen-Hofsté JM, et al. Neocollagenesis after injection of a polycaprolactone based dermal filler in a rabbit. *EJAMEd*. 2013;3 1 :19–26.
35. Kim JA, Van Abel, D. Neocollagenesis in human tissue injected with a polycaprolactone-based dermal filler. *J Cosmet Laser Ther*. 2015;17 2 :99–101.
36. Kim J. Changes in dermal thickness in biopsy study of histologic findings after a single injection of polycaprolactone-based filler into the dermis. *Aesthet Surg J*. 2019;39 12 :NP484–NP494.

Clinical, Cosmetic and Investigational Dermatology

Dovepress

Publish your work in this journal

Clinical, Cosmetic and Investigational Dermatology is an international, peer-reviewed, open access, online journal that focuses on the latest clinical and experimental research in all aspects of skin disease and cosmetic interventions. This journal is indexed on CAS. The manuscript management system is completely online and includes a very quick and fair peer-review system, which is all easy to use. Visit <http://www.dovepress.com/testimonials.php> to read real quotes from published authors.

Submit your manuscript here: <https://www.dovepress.com/clinical-cosmetic-and-investigational-dermatology-journal>