

Recurrent Arthritis Caused by *Brucella melitensis* in a Chinese Adult: A Case Report

Wensheng Zhang, Yao Zhang, Jie Wang , Rui Ma, Qiang Zhang

Department of Orthopedics, Beijing Ditan Hospital, Capital Medical University, Beijing, People's Republic of China

Correspondence: Qiang Zhang, Email zhangdtzq@sina.com

Background: Brucellosis is an endemic systemic infectious disease, the most common complication is bone and joint involvement. Sacroiliac joint infections and spinal joint infections commonly affect adults, but ankle infections are extremely rare. We report a case of recurrent ankle arthritis caused by *Brucella melitensis* (*B. melitensis*).

Case Presentation: A 50-year-old Chinese male presented to a local hospital with right ankle pain and limited mobility 23 months ago and underwent a synovectomy of the ankle. Specimen culture revealed brucellosis infection in sheep. The patient came to the department of Orthopaedics of our hospital 18 months ago because his symptoms did not improve. The patient's blood culture of bacteria was negative, the serum Rose-Bengal Plate Agglutination Test was positive, and his erythrocyte sedimentation rate (ESR) and C-reactive protein (CRP) levels were significantly elevated. Joint synovial fluid of right ankle was extracted by joint aspiration and sent to the laboratory for real-time polymerase chain reaction (Real-time-PCR) examination, the results showed that there was *B. melitensis* in the synovial fluid. We concluded that the patient had recurrent *Brucella* ankle arthritis and was treated with doxycycline (0.1 g po bid), rifampicin (0.6 g po qd) and cefotaxime-sulbactam (2.25 g ivgtt q8h) for six weeks during hospitalization. When the patient was discharged, the symptoms were mostly relieved and the inflammatory indicators returned to normal. At following-up 18 months later, the patient had no discomfort in the right ankle and all inflammatory markers were normal.

Conclusion: *Brucella* ankle arthritis is a rare but serious complication of adult brucellosis. Clinical manifestations and imaging examinations revealed no obvious specificity. In order to prevent ankle deformities, the dead bone of the ankle should be removed and the joint space cleaned and antibiotic therapy should be administered.

Keywords: brucellosis, *Brucella* arthritis, ankle arthritis, synovitis

Background

From 2013 to 2018, a total of 282,264 cases of brucellosis were reported in China, and more than 95% of the cases were reported by northern Hospitals, Chinese Center for Disease Control (CDC) and other institutions.¹ Brucellosis, also known as waveform fever or Maltese fever, is a zoonotic disease.² Human brucellosis is a systemic infection that can affect any organ or system. Musculoskeletal involvement is one of the most common sites, and brucellosis involves bones and joints (osteojoints) between 10% and 85% of the time. Osteoarticular involvement includes spondylitis, sacroiliitis, and peripheral arthritis. The most common bone joint in children is mono-articular arthritis, mainly in the knee and hip. However, in adults, spondylitis and sacroiliitis are the most common.³ Ankle arthritis in adults is extremely rare, and its main clinical manifestations are ankle pain and limited movement, no significant difference from other bacterial arthritis clinical symptoms. This often leads to clinical misdiagnosis or missed diagnosis. We present a rare case of *Brucella* ankle arthritis.

Case Presentation

A 50-year-old Chinese male presented to a local hospital with right ankle pain and limited mobility 23 months ago and underwent a synovectomy of the ankle. Specimen culture revealed brucellosis infection in sheep. The patient came to the department of Orthopaedics of our hospital 18 months ago because his symptoms did not improve. His case history indicated that he had worked in a Sheep farm for 9 months. We, therefore, suspected that he might have acquired *Brucella* infection through ingestion

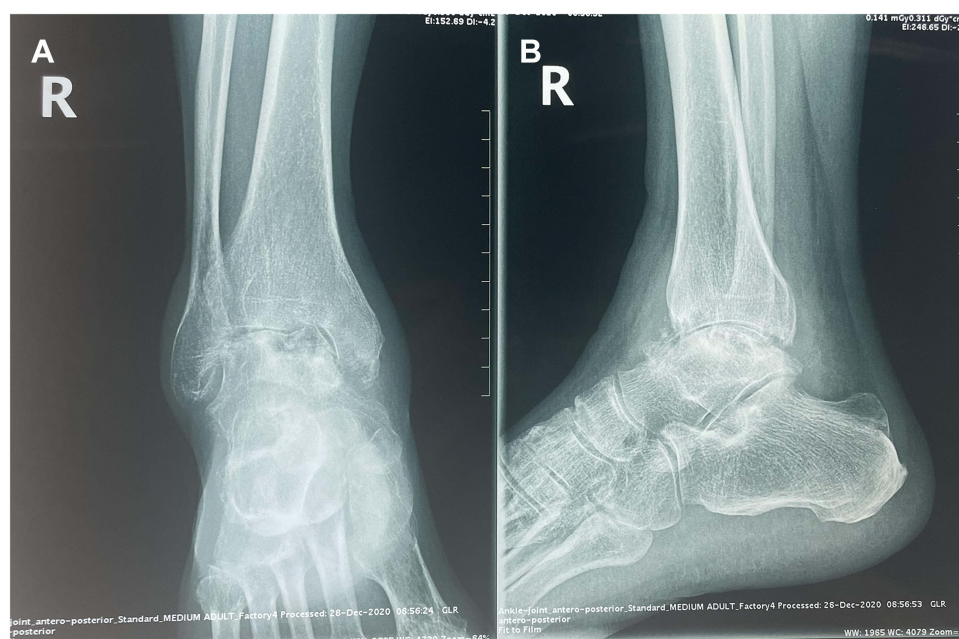


Figure 1 X-Ray examination of the patient on admission. **(A and B)** Coronal and sagittal radiographs demonstrated collapsed articular surfaces and narrowed joint spaces in the talus bone.

or contact with injured skin. A 37°C temperature, no sweating, weight loss, and no personal or family history of tuberculosis were all present on admission. Physical examination showed significant tenderness on the lateral side of the right ankle without fever. Blood flow to right toe is good, right ankle varus pressure test is positive. Laboratory tests were as follows: Hemoglobin (Hb) 136 g/L, Red blood cell count (RBC) $4.25 \times 10^{12}/L$, White blood cell (WBC) $10.09 \times 10^9/L$ accompanied by neutrophil elevation, Platelet $363 \times 10^9/L$, Erythrocyte sedimentation rate (ESR) 31 mm/h, C-reactive protein (CRP) 32 mg/L. Rose-Bengal Plate Agglutination Test (RBPT) was positive.

Anteroposterior and lateral X-ray of the right ankle showed arrowed joint spaces (Figure 1A and B). CT showed multiple cysts were noted below the articular surface of the right ankle, and the articular surface of the talus collapsed (Figure 2A–D). MRI showed the right ankle joint space was significantly narrowed, the articular surface was coarse, the articular cartilage was thinned, the talus articular surface collapsed, and multiple cysts were found in the subchondral bone (Figure 3A–D). Joint synovial fluid of right ankle was extracted by joint aspiration and sent to the laboratory for Real-time PCR examination, and the results showed that there was *B. melitensis* in the synovial fluid (Figure 4). The HE staining of ankle fluid revealed inflammatory cell infiltration, while acid-fast staining was negative (Figure 5A and B). We concluded that the patient had recurrent *Brucella* ankle arthritis and was treated with doxycycline (0.1 g po bid), rifampicin (0.6 g po qd) and cefotaxime-sulbactam (2.25 g ivgtt q8h) for six weeks during hospitalization. ESR and CRP levels declined significantly after drug treatment, returning to normal levels of 17.00 mm/h and 7.88 mg/L, respectively.

The right ankle movement of the patient was basically normal at discharge, and the pain was significantly reduced. Laboratory tests after drug treatment showed erythrocyte sedimentation rate (ESR) and C-reactive protein (CRP) levels of 17.00 mm/h and 7.88 mg/L, respectively, significantly decreased and returned to normal. At following-up 18 months later, the patient had no discomfort in the right ankle and all inflammatory markers were normal. RBPT was negative.

Discussion and Conclusions

The most common cause of *Brucella* arthritis is blood transmission.⁴ Between 18% and 60% of patients with brucellosis develop osteoarthritis.⁵ The type of bone and joint involvement in brucellosis mainly depends on the age of the patient, with sacroiliac joint and spinal disease predominating in adults, and knee and ankle joint infection in children and minors.⁶

Brucella ankle arthritis were more commonly affected in children and young adults, while middle-aged and elderly patients are rarely affected.^{7–9} In Turkey, Iran, and other regions, studies have shown, Iran and other regions, the most

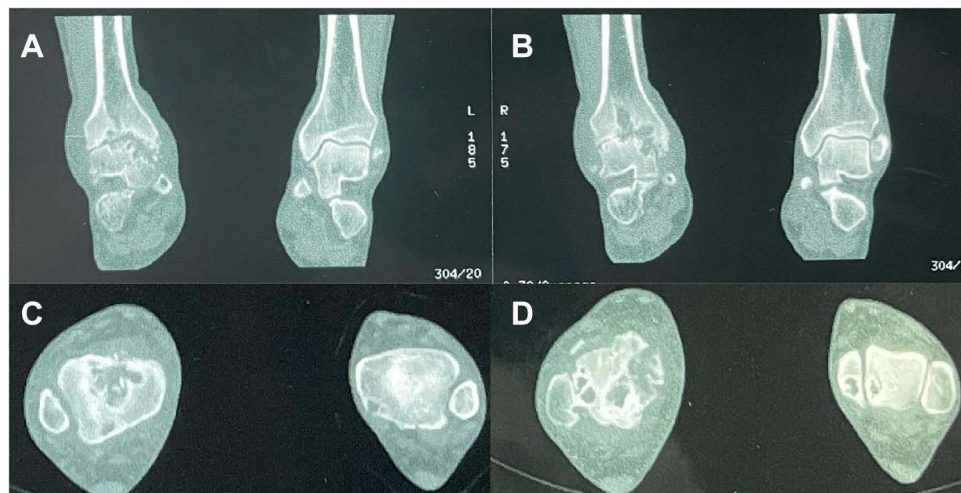

Figure 2 CT examination of the patient on admission. (A and B) Coronal CT showed bone destruction at the lower part of the right tibia, and the articular surface of the right talus collapsed. (C and D) Axial CT showed multiple cystic bone destruction below the articular surface of the right ankle, with obvious destruction of the medial malleolus.

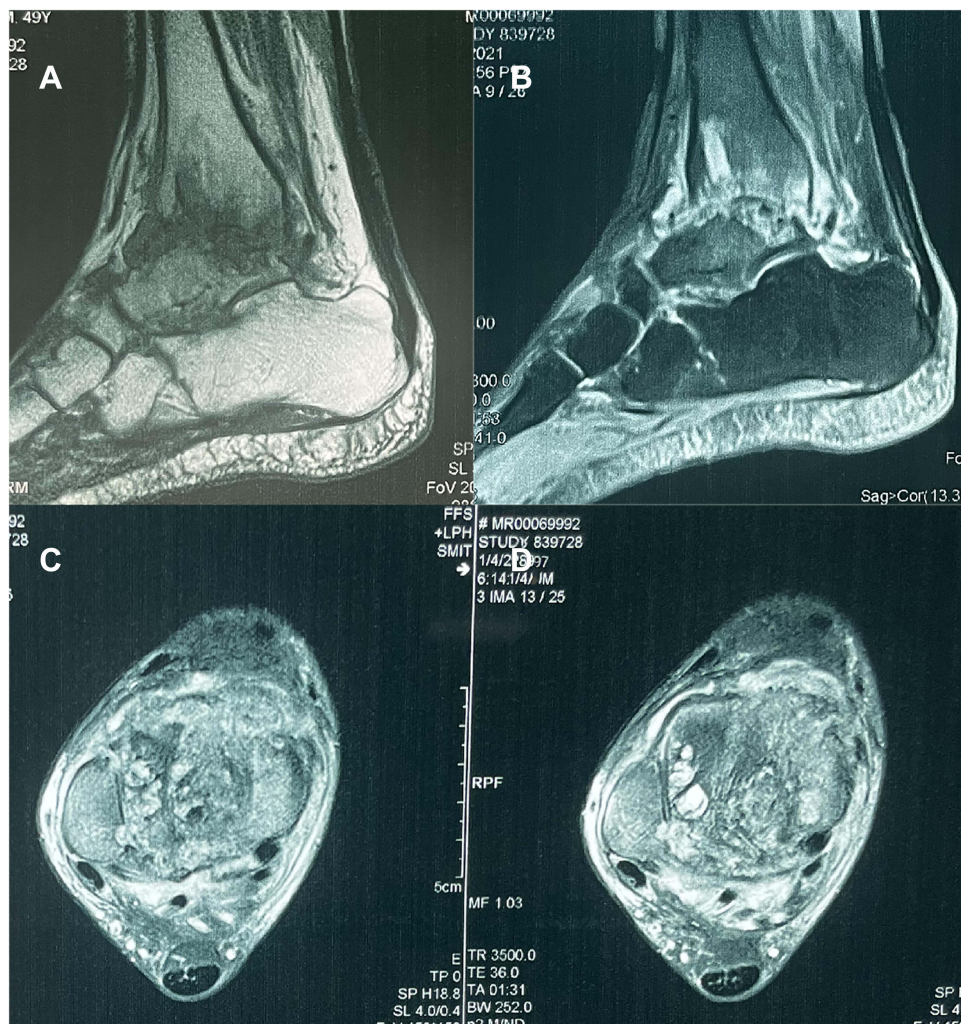


Figure 3 MRI examination of the patient on admission. (A and B) Sagittal T1T2-weighted image shows an abnormal signal, a narrowing of the right ankle joint, and coarse articular surfaces. (C and D) Axial image shows erosion and destruction of the medial and medial malleolus of the talus, with multiple cystic changes.

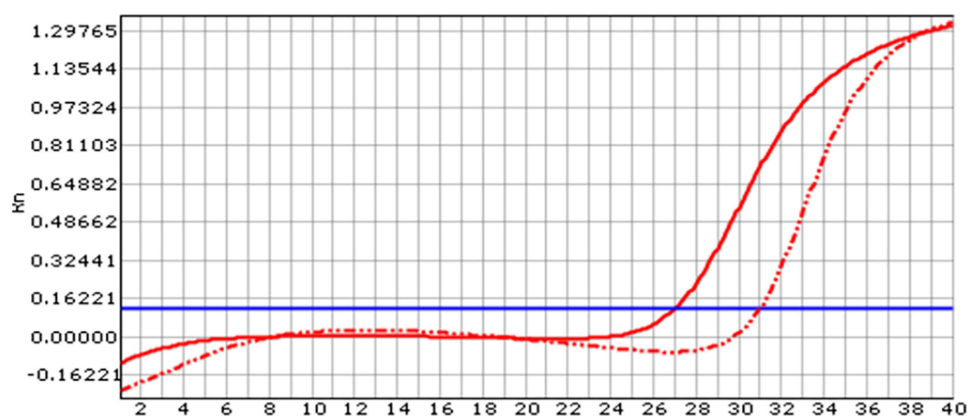


Figure 4 *Brucella melitensis* was detected by real-time PCR, real-time PCR showed that the DNA content of *Brucella melitensis* (Dotted red line) increased in 27 cycles.

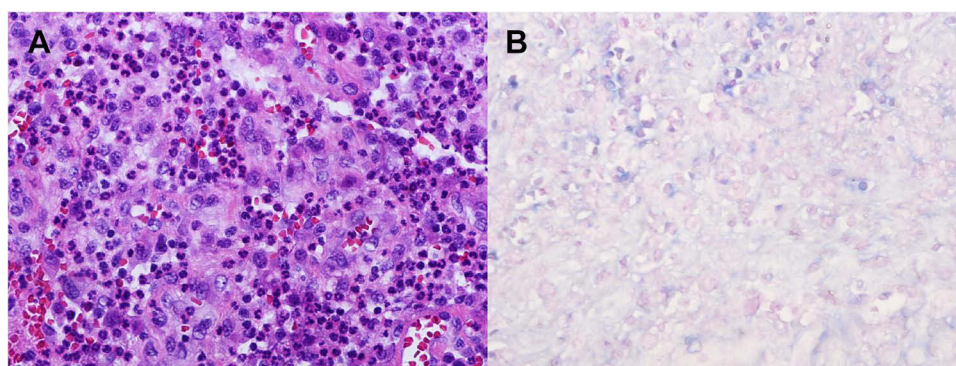


Figure 5 Pathological staining of right ankle joint effusion and inflammatory tissue. (A) Inflammatory cell infiltration was seen by HE staining. (B) Acid-fast staining was negative.

common bone and joint manifestation of brucellosis in adults is sacroiliac arthritis, and the most common manifestation in children is single joint arthritis (usually hips and knees).¹⁰ Brucellosis spondylitis is the most common bone and joint complication of adult brucellosis patients in China.¹¹ It has not been reported in China that *Brucella* ankle arthritis occurs.

Pain and limited ankle movement are common symptoms of *Brucella* ankle arthritis. Since *Brucella* ankle arthritis is rare, its clinical symptoms are non-specific, and negative laboratory results have been reported in chronic cases, it is difficult to diagnose.¹² In patients with histories of exposure to cattle and sheep or from areas where *Brucella* is endemic, clinicians should be highly suspicious of *Brucella* infection. In imaging, *Brucella* ankle arthritis does not appear characteristic, making diagnosis more challenging. Inflammation of the joints associated with brucellosis ranges from acute to subacute, usually less severe than in acute suppurative arthritis.¹³ Early joint imaging did not reveal any pathological findings because the disease is synovial in nature. In spite of this, MRI results alone cannot predict the cause of infection, since they are not specific for *Brucella* ankle arthritis. Soft tissue swelling and narrowing of joint spaces were seen on X-ray in advanced cases.¹⁰ There is a low incidence of destructive arthritis in brucellosis, and treatment may not stop further bone destruction, possibly because irreversible cartilage damage has occurred.¹⁴ In patients with brucellosis, ESR and CRP levels are often elevated, but they are nonspecific. Brucellosis is diagnosed with *B. Melitensis* cultured from blood or tissue specimens, but the positive rate is low.¹⁵ As a screening method for *Brucella* infection, RBPT is often used to identify *B. Melitensis* infection.¹⁶ Brucellosis can be diagnosed using Real-time PCR, which has relatively high sensitivity.¹⁷

The recommended drug treatment for brucellosis includes a combination of two or three antibiotics. These are prescribed according to whether the disease is complex or not. The appropriate combination of antibiotics should be

selected according to the patient's condition. The triple therapy recommended by the World Health Organization (WHO), doxycycline (0.1 g bid), rifampicin (0.6 g qd) and streptomycin (1 g qd) may be most effective if given within 6 months of disease onset.¹⁸ To prevent *Brucella* osteoarthritis from occurring or recurring, the sustained treatment of 2–3 courses of 2 weeks each is recommended; however, blood tests and liver and kidney function should be monitored during the course of treatment.¹⁹ Aside from medication, surgical goals include disinfecting and decompressing the joint as soon as possible to maximize function after healing. In order to treat *Brucella* ankle arthritis surgically, necrotic bone, synovial membrane, and joint space need to be cured. It is generally considered to be a good choice to treat infectious ankle arthritis with ankle arthrodesis.^{20,21} In some cases, ankle arthrodesis may not be the first choice.

In our case, the patient had recurrent *Brucella* ankle arthritis after necrotic bone removal. After irrigating the joint space and receiving antibiotic treatment, the patient's symptoms were significantly relieved, the inflammatory markers returned to normal, and the patient was able to walk after discharge. After 18 months of follow-up, there was no obvious discomfort and the function returned to normal. Our case is characterized by the following points: 1. Middle-aged and elderly patients rarely suffer from *Brucella* ankle arthritis; 2. It has not been reported in China that *Brucella* ankle arthritis occurs; 3. Arthritis caused by brucellosis is rarely destructive; 4. In this case, the patient did not undergo an ankle arthrodesis; however, medications helped him regain normal function.

Brucella ankle arthritis complicated is a rare but serious complication of brucellosis in adults. There are no obvious specific features on clinical and imaging examination. Early diagnosis and treatment can prevent the occurrence of knee joint deformity or pathological fracture. In our opinion, the key to treating osteoarthritis is to scrape away necrotic bone, synovium, and clear the joint space. Patients can return to normal function with the help of postoperative anti-infection therapy. If necessary, ankle arthrodesis may be performed.

Abbreviations

B. Melitensis, *Brucella melitensis*; RBPT, Rose-Bengal Plate Agglutination Test; ESR, Erythrocyte sedimentation rate; CRP, C-reactive protein; Real-time PCR, Real-time polymerase chain reaction; MRI, Magnetic resonance imaging; WHO, World Health Organization; CDC, Chinese Center for Disease Control.

Data Sharing Statement

All data and materials are available with the first author.

Ethics Approval and Consent to Participate

The Ethics Committee of the Beijing Ditan Hospital of Capital Medical University approved the study.

Consent for Publication

The patient provided written informed consent for publication of these case reports and accompanying images.

Author Contributions

All authors made a significant contribution to the work reported, whether that is in the conception, study design, execution, acquisition of data, analysis and interpretation, or in all these areas; took part in drafting, revising or critically reviewing the article; gave final approval of the version to be published; have agreed on the journal to which the article has been submitted; and agree to be accountable for all aspects of the work.

Funding

This study did not receive any funding.

Disclosure

The authors declare that they have no competing interests in this work.

References

1. Li S, Chen QL, Yin WW, et al. Diagnosis status of Brucellosis in China from 2013 to 2018. *Dis Surveill*. 2019;34:1053–1057.
2. Franc KA, Kreck RC, Häsler BN, Arenas-Gamboa AM. Brucellosis remains a neglected disease in the developing world: a call for interdisciplinary action. *BMC Public Health*. 2018;18:125. doi:10.1186/s12889-017-5016-y
3. Hou SY, Zhang T, Huang Q, et al. Status quo and prospect of intervention research on brucellosis arthritis. *Nurs Res China*. 2018;32(17):2665–2668.
4. Moreno E, Barquero-Calvo E. The role of neutrophils in brucellosis. *Microbiol Mol Biol Rev*. 2020;84(4):e00048–20. doi:10.1128/MMBR.00048-20
5. Flury D, Behrend H, Sendi P, et al. Brucella melitensis prosthetic joint infection. *J Bone Jt Infect*. 2017;2(3):136–142. doi:10.7150/jbji.18408
6. Sanaei Dashti A, Karimi A. Skeletal involvement of Brucella melitensis in children: a systematic review. *Iran J Med Sci*. 2013;38:286–292.
7. Mousa AR, Muhtaseb SA, Almudallal DS, Khodeir SM, Marafie AA. Osteoarticular complications of brucellosis: a study of 169 cases. *Rev Infect Dis*. 1987;9(3):531–543. doi:10.1093/clinids/9.3.531
8. Zamani A, Kooraki S, Mohazab RA, et al. Epidemiological and clinical features of Brucella arthritis in 24 children. *Ann Saudi Med*. 2011;31(3):270–273. doi:10.4103/0256-4947.81543
9. Elzein FE, Sherbeeni N. Brucella septic arthritis: case reports and review of the literature. *Case Rep Infect Dis*. 2016;2016:4687840. doi:10.1155/2016/4687840
10. Geyik MF, Gur A, Nas K, et al. Musculoskeletal involvement of Brucellosis in different age groups: a study of 195 cases. *Swiss Med Wkly*. 2002;132(7–8):98.
11. Zhang T, Liu H, Yang C, et al. Three cases of brucellar spondylitis with noncontiguous multifocal involvement. *World Neurosurg*. 2020;139:608–613.
12. Roushan MH, Marashi S, Moulana Z. Polymerase chain reaction-based assays for the diagnosis of active and relapsed cases of human brucellosis. *Am J Trop Med Hygiene*. 2016;95:1272–1276. doi:10.4269/ajtmh.16-0344
13. Franco MP, Mulder M, Gilman RH, et al. Human brucellosis. *Lancet Infect Dis*. 2007;7(12):775–786. doi:10.1016/S1473-3099(07)70286-4
14. Remide A, Dirim MB. Musculoskeletal brucellosis. *Semin Musculoskelet Radiol*. 2011;15(05):470–479. doi:10.1055/s-0031-1293493
15. Bozgeyik Z, Aglamis S, Bozdag PG, et al. Magnetic resonance imaging findings of musculoskeletal brucellosis. *Clin Imaging*. 2014;38(5):719–723. doi:10.1016/j.clinimag.2014.04.007
16. Faddoul L, Azar R, Haddad A, et al. The importance of blood culture and serology for Brucellosis diagnosis and treatment. *J Infect Dev Countries*. 2018;12(2.1):19S. doi:10.3855/jidc.10120
17. Li M, Zhou X, Li J, et al. Real-time PCR assays for diagnosing brucellar spondylitis using formalin-fixed paraffin-embedded tissues. *Medicine*. 2018;97(9):e0062. doi:10.1097/MD.00000000000010062
18. World Health Organization. Brucellosis in humans and animals. Geneva: World Health Organization; 2006. Available from: <https://apps.who.int/iris/handle/10665/43597>. Accessed September 27, 2019.
19. Ministry of Health, PRC. Guidelines for diagnosis and treatment of Brucellosis (Trial). *Infect Dis Inform*. 2012;25(06):323–324+359.
20. Andriopoulos P, Tsironi M, Deftereos S, et al. Acute brucellosis: presentation, diagnosis, and treatment of 144 cases. *Int J Infect Dis*. 2007;11(1):52–57. doi:10.1016/j.ijid.2005.10.011
21. Suda AJ, Richter A, Abou-Nouar G, et al. Arthrodesis for septic arthritis of the ankle: risk factors and complications. *Arch Orthop Trauma Surg*. 2016;136(10):1343–1348. doi:10.1007/s00402-016-2520-y

Infection and Drug Resistance

Dovepress

Publish your work in this journal

Infection and Drug Resistance is an international, peer-reviewed open-access journal that focuses on the optimal treatment of infection (bacterial, fungal and viral) and the development and institution of preventive strategies to minimize the development and spread of resistance. The journal is specifically concerned with the epidemiology of antibiotic resistance and the mechanisms of resistance development and diffusion in both hospitals and the community. The manuscript management system is completely online and includes a very quick and fair peer-review system, which is all easy to use. Visit <http://www.dovepress.com/testimonials.php> to read real quotes from published authors.

Submit your manuscript here: <https://www.dovepress.com/infection-and-drug-resistance-journal>